

Endodontic treatment of primary teeth in the general dental practice

Author_ Dr Robert Teeuwen, Germany

	Total		1 VitA		2 Dev/MoA		3 MoA		4 r.c.f./Fist		5 r.c.f. kons		Total 3–5		Total 2–5	
	n	%	n	%	n	%	n	%	n	%	n	%	n	%	n	%
Total	559		460		29		37		22		11		70		99	
Author	216	38,6	170	37,0	11	37,9	14	37,8	19	86,4	2	18,2	35	50,0	46	46,5
Assistant Doctor	343	61,4	290	63,0	18	62,1	23	62,2	3	13,6	9	81,8	35	50,0	53	53,5
no-shows after treatment	66	11,8	47	10,2	8	27,6	7	18,9	2	9,1	2	18,2	11	15,7	19	19,2
without no-shows	493		413		21		30		20		9		59		80	
Extractions	71	14,4	55	13,3	1	4,8	7	23,3	5	25,0	3	33,3	15	25,4	16	20,0
0–23 months	17	23,9	11	20	–		2	28,6	3	60,0	1	33,3	6	40,0	6	37,5
≥ 24 months	54	76,1	44	80	1		5	71,4	2	40,0	2	66,7	9	60,0	10	62,5
Failure	28	5,7	18	4,4	5	23,8	3	10,0	1	5,0	1	11,1	5	8,5	10	12,5
0–23 months	22	78,6	14	78	4	80,0	2	66,7	1		1		4	80,0	8	80,0
≥ 24 months	6	21,4	4	22	1	20,0	1	33,3	–		–		1	20,0	2	20,0

Table I N2-therapy of primary teeth 1992–1998.

1 VitA = vital amputation = pulpotomy;

2 Dev/MoA = mortal amputation post devitalisation;

3 MoA = mortal amputation of gangrenous teeth; only the pulp-chamber is filled by N2;

4 r.c.f./Fist = root-canal filling with artificial fistulation;

5 r.c.f. kons = root-canal filling, conservative treatment).

The most common endodontic treatment of primary teeth is pulpotomy, which is used in the case of carious, iatrogenic or traumatic damage of the pulp. As prerequisite for such a procedure, the patient has to be free of clinical symptoms, according to the DGZMK.¹ As per UK Guideline² and Weisshaar,³ this condition is still met in cases of temporary discomfort or short, spontaneous pain.

Various materials are used for pulpotomy and pulpectomy. The standard preparation for pulpotomy is still Formocresol—19% formaldehyde, 35% cresol, 15% glycerine, 31% distilled water—used in a 1:5 dilution. Weisshaar³ reported that 92.4% of paediatric dentists in Canada and 76.8% of paediatric dentists worldwide used Formocresol for pulpotomy in 1989. While there have always been objections to the use of formaldehyde, Tagger and Tagger⁴ state that Formocresol pulpotomy assists the retention of primary teeth and outperforms any other current method.

In their 2002 statement, the DGZMK advised using calcium hydroxide—Ca(OH)₂—for pulpotomy.¹ The 2006 UK Guideline however considers this treatment inappropriate.² Furthermore, the UK Guideline emphasised that pulpotomy with 15.5% ferric sulphate (Astringent, Ultradent) is as effective as a five-minute treatment with Formocresol. However, ferric sulphate only acts haemostatically when applied to the bleeding pulp stump for 15 seconds. Subsequently, ferric sulphate is removed from the pulp cavity and zinc oxide-eugenol is directly applied to the root canals. The UK Guideline cites a study that achieved 55% internal resorption—as with Ca(OH)₂—and 71% obliteration of the root canal radiologically with this pulpotomy method.² Peng *et al.*⁵ demonstrated equivalent results in a meta-analysis of 11 studies that compared Formocresol and ferric sulphate pulpotomies. The ferric sulphate pulpotomies demonstrated a clinical success rate of 78 to 100% and a radiological success of 42 to 97%. For inclusion

The Business of Dentistry



INTERNATIONAL DENTAL
EXHIBITION AND MEETING
April 20 - 22, 2012

Now Open for Exhibiting Applications

"IDEM Singapore 2010 has proven to be a more successful outing for us as compared to the 2008 event. We have already secured at least three major projects and we're expecting to bring these to fruition in the next three to six months!"

Mr. Sthen Boisen, General Manager South Asia
KaVo Dental Asia-Pacific Pte Ltd

"IDEM Singapore 2010 has surpassed the results of 2008. It is a good platform for networking, allowing me to connect with key contacts from a wide range of dental segments. I will certainly be back in 2012."

Tran Van Thuan, President
Denmedico, Vietnam

Endorsed by



Supported by



Held in



Mr. Adrian Sng / Ms. Ziqi Zielinski
Koelnmesse
Tel: +65 6500 6700
Fax: +65 6294 8403
idem-singapore@koelnmesse.com.sg

In cooperation with

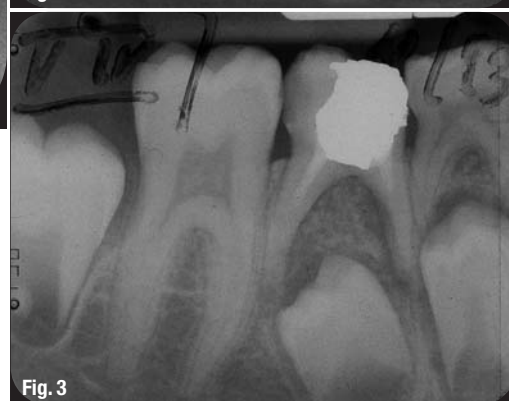
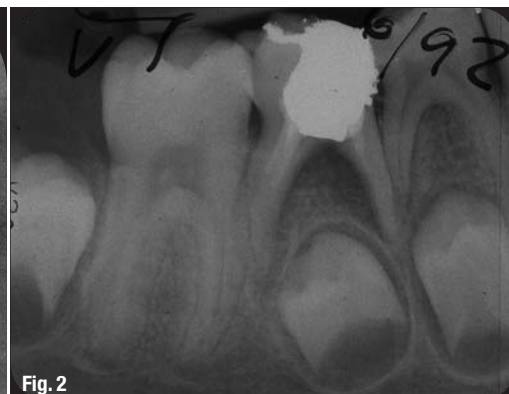
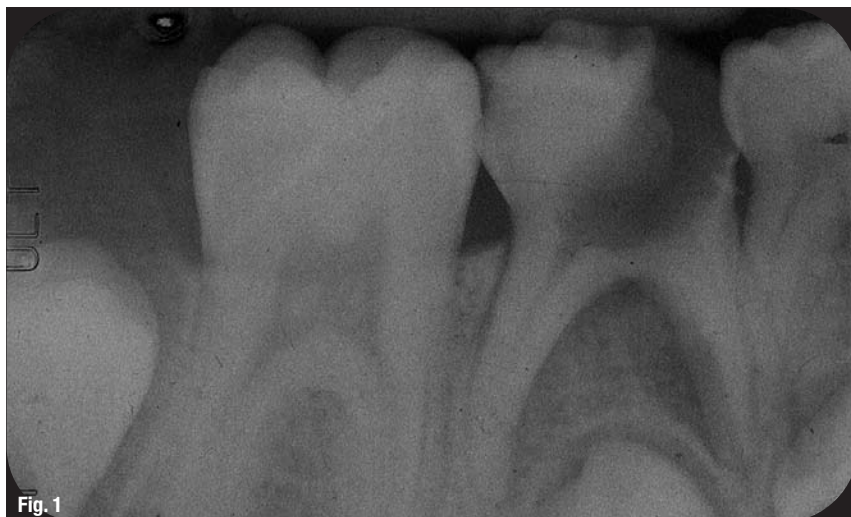Organizers



Singapore Dental Association





Figs. 1–4 11-year-old patient. Treatment of the lower gangrenous second primary molar.

Fig. 1 19.06.1992: Ante treatment.

Fig. 2 19.06.1992: X-ray control of the incomplete r.c.f.

Fig. 3 12.10.1993: Follow-up X-ray after 16 months.

Fig. 4 19.06.1992: Fistulation through the gum.

in the analysis, the teeth were required to have remained *in situ* for at least 12 months in order to avoid the inclusion of early failures in the baseline studies.

According to Einwag,⁶ the 90 to 100% clinical success rate of pulpotomies using N2 Endodontic cement (Ghimas) is the same as that achieved using the five-minute Formocresol technique, which is not surprising owing to their similar composition. Prior to the EU certification of 14 June 1998, N2 contained 7% formaldehyde, which was subsequently reduced to 5%.

Bürkle⁷ reported a low technical sensitivity and good clinical results for all aldehyde-containing materials, such as Formocresol, glutaraldehyde and N2.

Materials and method

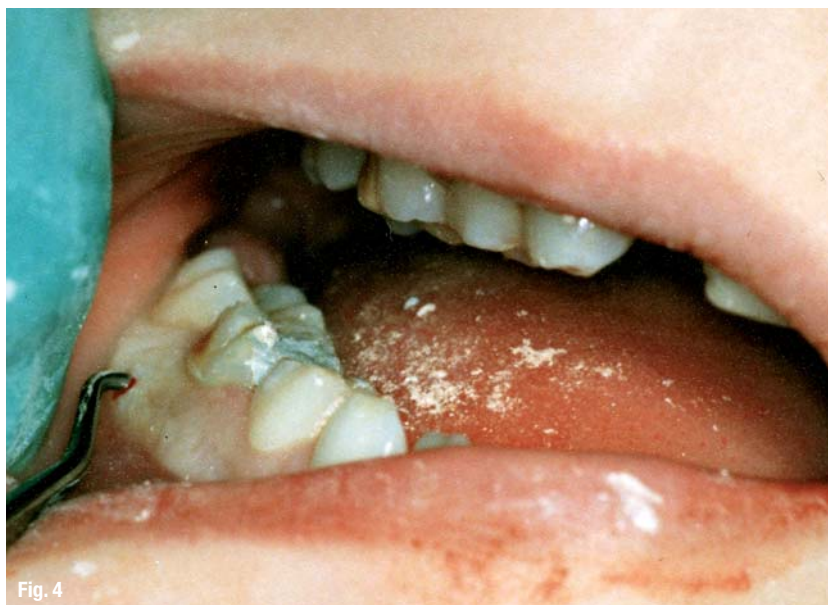A prerequisite for treatment was the restorability of the respective teeth. An exclusion criterion was

increased mobility without advanced root resorption. In accordance with these, the following endodontic treatments between 1992 and 1998 were recorded. X-rays were only routinely available for mortal amputations and root-canal treatments of gangrenous primary teeth. Where possible, follow-up X-rays of the latter were taken.

Vital amputations (pulpotomies), mortal amputations and root-canal fillings were performed using the root-canal filling material N2 under relatively dry conditions. For the root-canal filling, N2 powder and N2 liquid were mixed to a creamy consistency and applied near the apex following preparation using a manual reamer or mechanical HERO 642 endodontic files (MICRO-MEGA).

For vital or mortal amputations, N2 was mixed to a relatively solid consistency. First, deep carious defects were removed with an excavator. The remaining caries was excavated using a thick spherical bur without water-cooling, followed by cavity preparation with elimination of the coronal pulp using a turbine.

Frequently, the remaining pulp bleeds from the canals. Light bleeding can be disregarded, but N2 must be firmly applied to the cavity for several minutes in the case of heavier bleeding. Owing to the formaldehyde level, the bleeding can be stopped relatively quickly. The blood-soaked N2 is then removed from the cavity and replaced with freshly mixed N2 of a solid consistency.



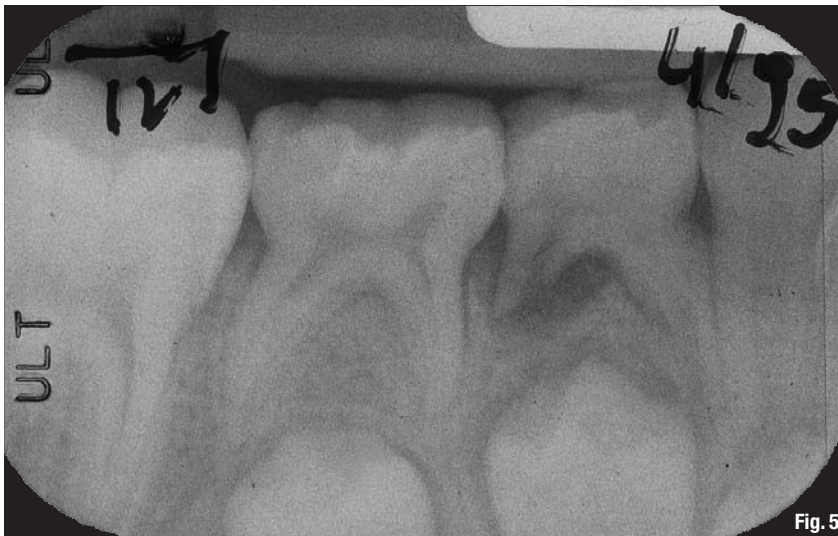

Fig. 5

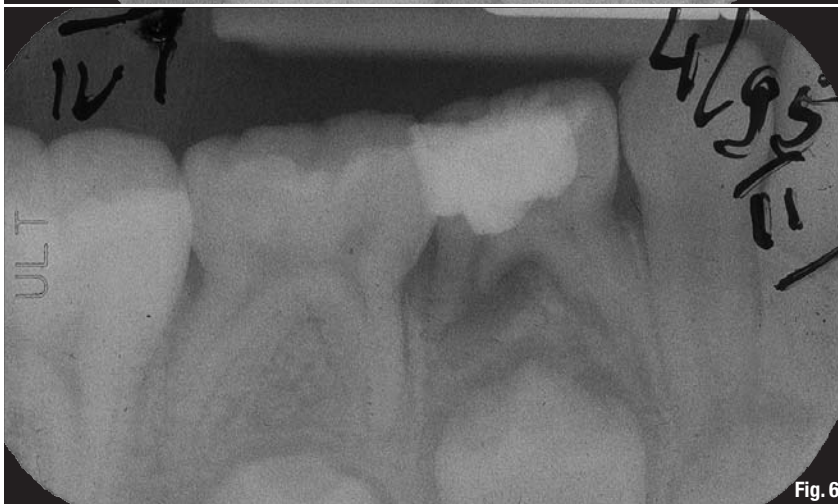

Fig. 6

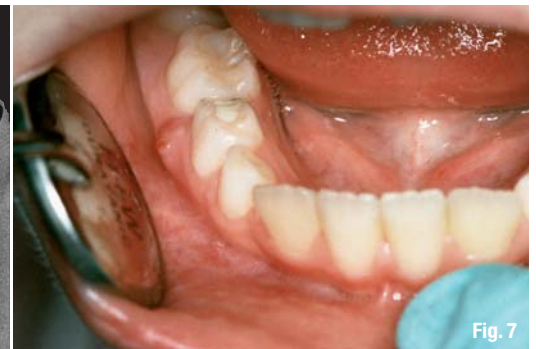

Fig. 7

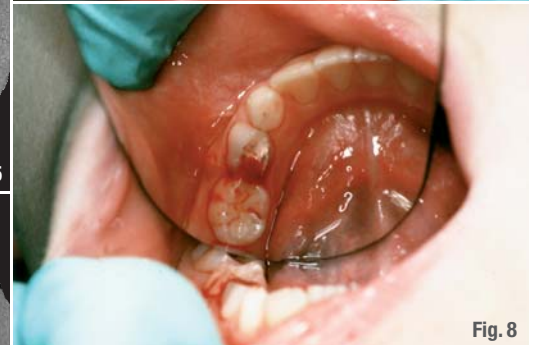

Fig. 8

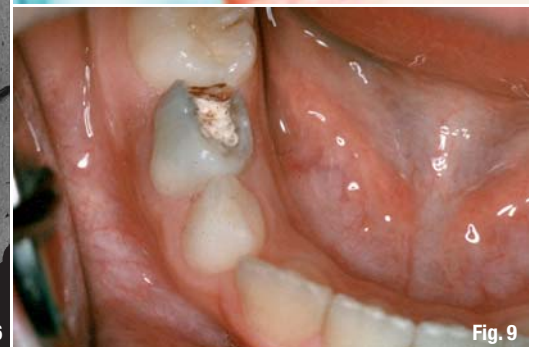

Fig. 9

The mortal amputations were attributed partly to Toxavit-devitalisation and partly to treatment of gangrenous teeth. Devitalised teeth were treated in the same manner as vital teeth. Gangrenous teeth were treated with different methods. Simple mortal amputations were performed in a manner similar to a vital amputation. Root-canal fillings (partial or complete) were simply filled with paste. In some cases, the roots were finished through artificial fistulation, which was done interradicularly—mostly with a Cavit lifter through the mucosa—and in a few cases after the mucosa had been shifted with a turbine bur.

All endodontic measures, including the fillings, were performed in one appointment. Additional visits were only necessary when massive bleeding occurred, when a composite filling was required and in devitalisation cases. In the first two cases, the cavity was filled with excess N2 or with zinc oxide-eugenol following N2 application. N2 application and immediate amalgam sealing of the cavity without lining materials is still the most time-saving method. In exceptional cases, stainless-steel crowns served as definitive restoration.

Results

A total of 559 primary teeth were treated endodontically between 1992 and 1998. I treated about 39% of these myself. Pulpotomies were conducted on 460 primary molars, 29 to Toxavit devitalisation with subsequent mortal amputation was performed on 29 primary molars. Of the 70 gangrenous primary molars treated, 37 were treated by simple mortal amputation. In 22 cases, root filling or mortal amputation was followed by artificial fistulation. Root-canal treatment of 11 gangrenous primary molars was performed without fistulation. The following gives the average age of the patients who underwent a pulpotomy:

maxillary first molar: 7 years, 6 months
 maxillary second molar: 7 years, 5 months
 mandibular first molar: 6 years, 6 months
 mandibular second molar: 6 years, 6 months

After treatment, 11.8% ($n = 66$) of the young patients did not return to the practice, which left only 88.2% of the original patient group ($n = 493$) for

Figs. 5–9 13-year-old patient.
 Treatment of the lower gangrenous first primary molar.

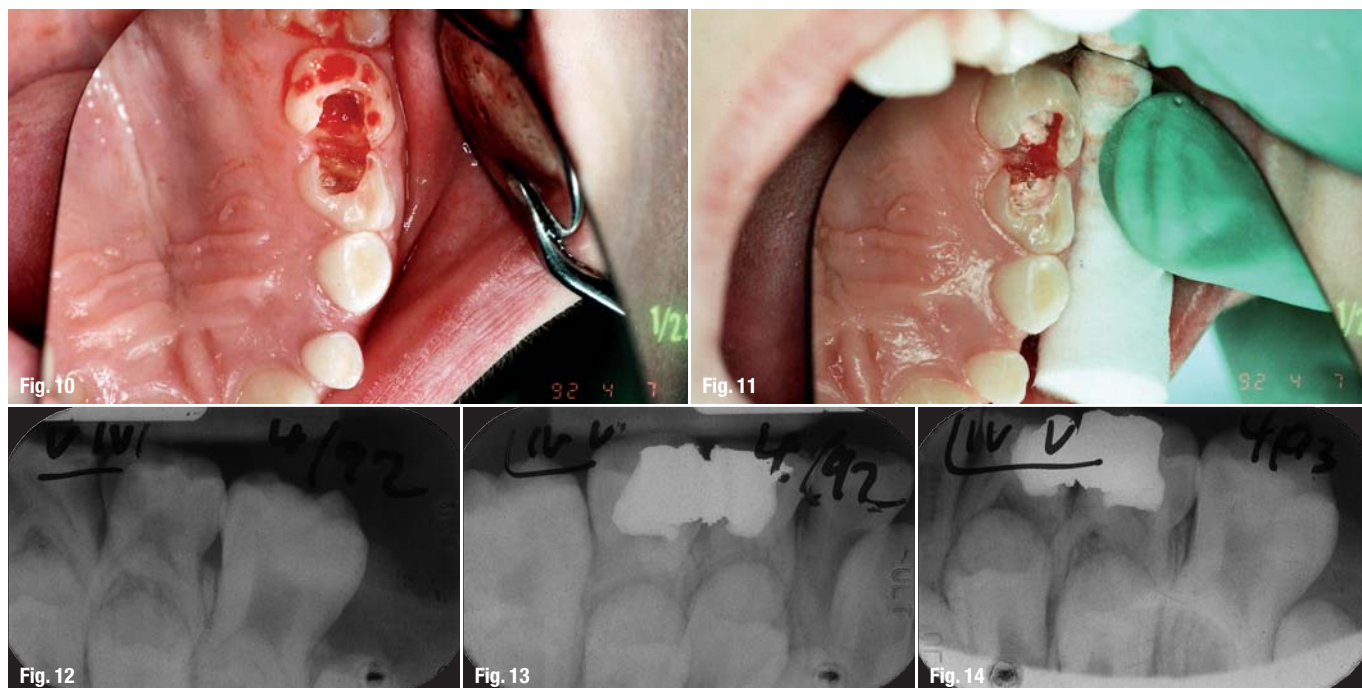
Fig. 5 11.04.1995: Ante treatment.

Fig. 6 11.04.1995:
 Post mortal-amputation.

Fig. 7 11.04.1995:
 Natural fistula represented.

Fig. 8 11.04.1995:
 Bleeding of the pulp, pulp-chamber completely filled by N2.

Fig. 9 17.04.1995:
 Fistula has disappeared (05.01.1996: panoramic X-ray shows treated tooth still in situ; 30.01.1997: file-card shows permanent first premolar erupted).



Figs. 10–14 10-year-old patient.
Pulpotomy of upper first and
second primary molar.

Fig. 10 07.04.1992:
Post cavity-preparation:
slight bleeding of first molar,
moderate bleeding of second molar.

Fig. 11 07.04.1992:
Post N2-application.

Fig. 12 07.04.1992: Ante treatment.

Fig. 13 07.04.1992:

Post treatment (N2, Amalgam-filling).

Fig. 14 15.04.1993:

12 months after vital-amputation.

observation in the practice. During the observation period, clinical failure (pain, swelling and fistulas) was registered in 5.7% ($n = 28$) of the patients. The symptoms of clinical failure occurred within 23 months after treatment in 78.6% of patients ($n = 22$). In one patient, these symptoms occurred only several hours after devitalisation followed by mortal amputation. Of the extractions done, 76.1 per cent ($n = 54$) occurred 24 months or more post-treatment. Problems with tooth eruption or enamel damage to the permanent teeth were not observed.

In summary, we observed that the number of extractions and failures in the observation period was twice as high in necrotic teeth when comparing vital amputation with treatment of gangrenous teeth (column 1 compared to column 3 to 5 in Table I).

Discussion

The number of young patients that did not return to the dental practice after treatment may be attributed to the discomfort of the treatment. However, the DMS III (Third German Oral Health Study) found a social attachment to the dentist ("always the same dentist") as high as 92.5% in 12-year-old patients in West Germany in 1997.⁸ It is possible that a significant number of those who did not return were clinical failures, prompting the patients' parents to consult another dentist, but this is rather unlikely.

Huber⁹ analysed 179 N2 vital amputations in 105 patients and documented a failure rate of 9.5%. The age of tooth loss corresponded to the average age of premolar eruption. The N2 pulpotomies had a low

failure rate of 4.4% in this study. This was confirmed by Einwag, who gives the clinical success rate of N2 pulpotomies as 90 to 100%.⁶

Although not documented in detail in this study, pain anamnesis appears to be insignificant in determining the success of a N2 pulpotomy. Acute exacerbations, as often observed following pulpotomy with $\text{Ca}(\text{OH})_2$, almost never occurred after N2 pulpotomy. Against this background, it is incomprehensible that German universities continue to favour $\text{Ca}(\text{OH})_2$ pulpotomies. The UK Guideline is a step ahead in this respect.²

It is important for the dental practice that the outcome of the treatment be guaranteed, that both the young patient and the dentist be comfortable with one another, that the treated tooth remains *in situ* until development of the permanent teeth and that the erupted permanent teeth are not damaged.

Dental practitioner Garry¹⁰ aptly expresses the use of N2 in endodontic treatment of primary teeth, which reflects my personal opinion: "When endodontic treatment is recommended for primary teeth, the concept 'careful selection of cases' is often used to warn the practitioner against treating gangrenous teeth. The technique herein does not require 'careful selection' for treatment [...]. The goal of endodontic intervention on primary teeth is not to obtain radiographic images which meet standards used in treating adult teeth, but to retain deciduous teeth as long as possible as entities and space maintainers."

Editorial note: A list of references is available from the publisher.

_contact

roots

Dr Robert Teeuwen
Berliner Ring 100
52511 Geilenkirchen
Germany

E-mail:
robteeuwen@t-online.de



2010

GREATER NEW YORK DENTAL MEETING

**FREE
REGISTRATION***

**MEETING DATES:
NOVEMBER 26 -
DECEMBER 1**

**EXHIBIT DATES:
NOVEMBER 28 -
DECEMBER 1**



86th
Annual Session

The
Largest
Dental
Convention/
Exhibition/
Congress
in the
United
States

**Free registration
before November 26*

Please send me more information about...

- ☐ Attending the Greater New York Dental Meeting
☐ Participating as a guest host and receiving free CE
☐ I speak _____ and am willing to assist international guests
enter language




Name _____

Address _____

City, State, Zip/Country Code _____

Telephone _____ E-mail _____

Fax or mail this to:
Greater New York Dental Meeting or
visit our website: www.gnydm.com for more information.



For More Information:
Greater New York Dental Meeting™
570 Seventh Avenue - Suite 800
New York, NY 10018 USA
Tel: +1 (212) 398-6922
Fax: +1 (212) 398-6934
E-mail: info@gnydm.com
Website: www.gnydm.com