

# Removal of a fractured instrument: Two case reports

Author\_ Dr Rafaël Michiels, Belgium

Fractured instruments pose a challenge to every endodontist. The difficulty in the retrieval of these instruments ranges from surprisingly easy to downright impossible. The clinical outcome of cases with fractured instruments depends on several factors, such as the position of the instrument in the canal, the type of material, the instrument size and canal anatomy.<sup>1</sup> Failure in retrieval of the fractured instrument does not automatically result in failure of the case.<sup>2</sup> One can still try to bypass the instrument, choose a surgical approach, or even wait and see. However, if we bear 'nothing ventured, nothing gained' in mind, then we should always at least try to retrieve the fractured instrument.

## Case I

A 27-year-old female patient was referred to our practice. She was in good health and had an American Society of Anesthesiologists (ASA) score of 1. The patient had some mild clinical symptoms on tooth #30 due to apical periodontitis. She had been told, by the referring dentist, that there was a fractured instrument in her tooth and that the instrument had to be removed first in order to allow for decent retreatment.

Before starting with the treatment, a new diagnostic radiograph was taken. In this case, the diag-

Fig. 1 Diagnostic radiograph, showing two separated instruments in the mesial root.

Fig. 2 A modified Gates-Glidden bur used for creating a plateau above the instrument.

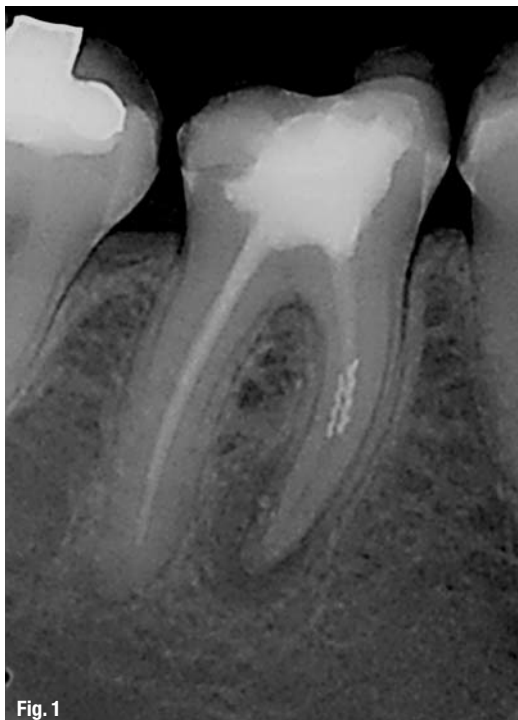

Fig. 1




Fig. 2



Under the patronage of  
**H. H. Sheikh Hamdan Bin Rashid Al Maktoum**  
Deputy Ruler of Dubai, Minister of Finance  
President of the Dubai Health Authority



**“Delivering Science & Technology”**

**DUBAI  
2011**



**1-3  
February**

Dubai International  
Convention &  
Exhibition Centre

**UAE INTERNATIONAL  
DENTAL CONFERENCE &  
ARAB DENTAL EXHIBITION**

**“Where Oral Health Professionals Meet”**

Supported by



- Keep up to date with the newest developments and techniques in dentistry through a series of lectures and specialized courses
- Enhance your dental practice with various management and clinical workshops
- Learn the optimal prevention and treatment services in the field of dental traumatology
- Visit 20,000 sqm. of exhibition space and explore the latest innovations and business practices
- Enjoy a panoramic view from Burj Khalifa, the world's tallest tower
- Ride the Metro and see Dubai !



[www.aeedc.com](http://www.aeedc.com)

Organised by



Strategic Partner



Supported by



**INDEX® Conferences & Exhibitions Organisation Est.**

P.O. Box: 13636 | Ibn Sina Bldg. #27 Block B, Office 203, Dubai Healthcare City | Dubai - United Arab Emirates  
Tel: +971 4 3624717 | Fax: +971 4 3624718 | E-mail: [aeedc@index.ae](mailto:aeedc@index.ae) | Website: [www.index.ae](http://www.index.ae)



Fig. 3

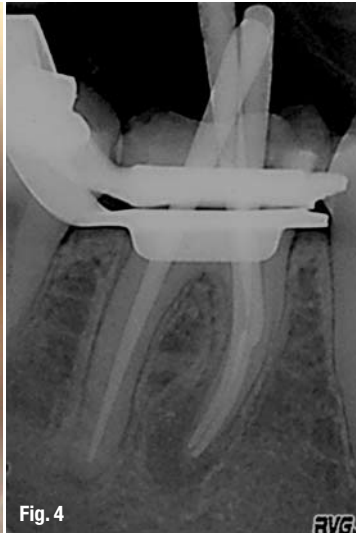


Fig. 4

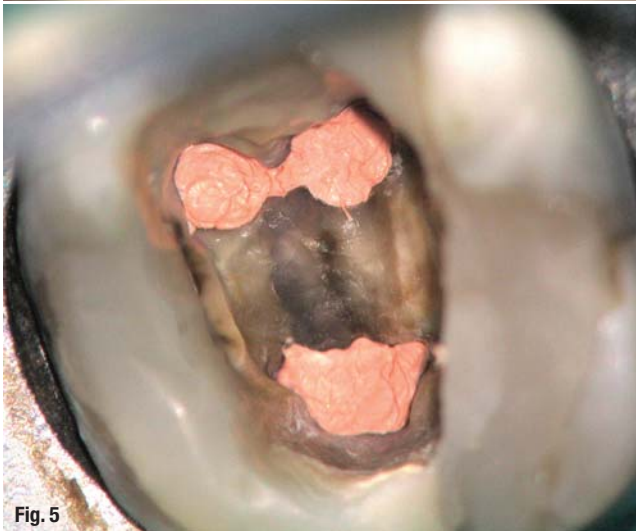


Fig. 5

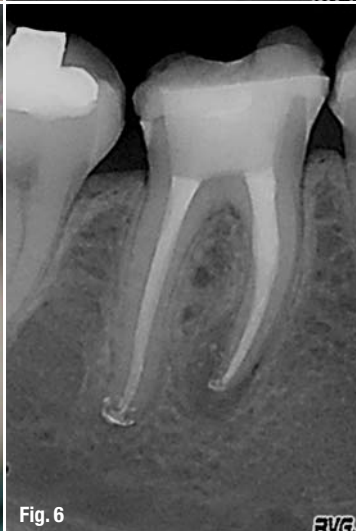

Fig. 6

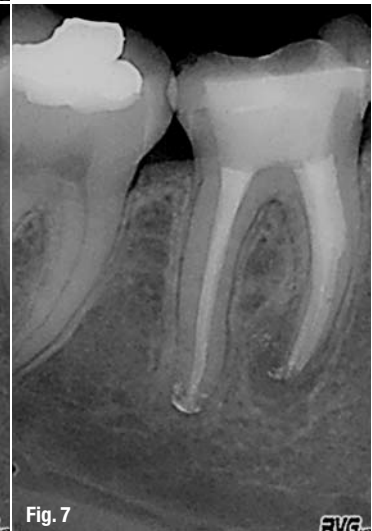

Fig. 7

the time being and made a new appointment. Calcium hydroxide paste (UltraCal XS, Ultradent) was put into the coronal part of the mesial canals and the tooth was sealed with glass-ionomer cement (Fuji IX GP Fast, GC) and a cotton pellet.

During the next visit, the tooth was again isolated and opened. The calcium hydroxide paste was removed, using 10 % citric acid and passive ultrasonics with the IRRISAFE tip (Satelec). Again, ultra-

**Fig. 3**\_One of the separated instruments.  
**Fig. 4**\_Gutta-percha cone fitting.  
**Fig. 5**\_The pulp chamber after obturation with gutta-percha.  
**Fig. 6**\_Final radiograph (parallel).  
**Fig. 7**\_Final radiograph (angled).

nostic radiograph (Fig. 1) showed not one but two broken instruments in the mesial root. Thereafter, the tooth was isolated with the rubber dam and the coronal filling was removed. Straight-line access was established, as this is imperative in order to be able to reach and see the fractured instruments. Gates-Glidden burs (DENTSPLY Maillefer) were used to enlarge the mesial orifices coronally.

After reaching the instrument in the mesio-buccal canal, I modified a size 3 Gates-Glidden bur by removing the tip of the bur (Fig. 2). In this manner, one gains an aggressive bur that allows one to create a platform above the instrument. At this moment, the instrument could be clearly visualised (Fig. 3). Ultrasonics were then used to loosen the fragment. ProUltra tips (DENTSPLY Maillefer), both zirconium nitride and titanium, were used for this purpose.

One-and-a-half hours after starting the treatment, the fragment had been loosened but was still stuck in the canal. We decided to leave it in place for

ultrasonics were used to retrieve the instrument. After five minutes, the fragment in the mesio-buccal canal was removed. Another five minutes later, the instrument in the mesio-lingual canal was also removed. While removing the instrument in the mesio-buccal canal was very time-consuming, removing the instrument from the mesio-lingual canal was surprisingly easy. This clearly highlights the above-mentioned difficulty range of instrument retrieval.

After the removal of both instruments, working length was determined in both mesial canals with the electronic apex locator (Root ZX Mini, Morita). A glide path was established and the mesial canals were initially shaped with a ProTaper S1 (DENTSPLY Maillefer). Copious irrigation was performed using 3% sodium hypochlorite. Next, the gutta-percha in the distal canal was removed with a size 25.06 ProFile (DENTSPLY Maillefer), which was rotated at 500rpm in an X-smart Easy endodontic motor (DENTSPLY Maillefer). No chemical was required for gutta-percha softening. The canals walls were



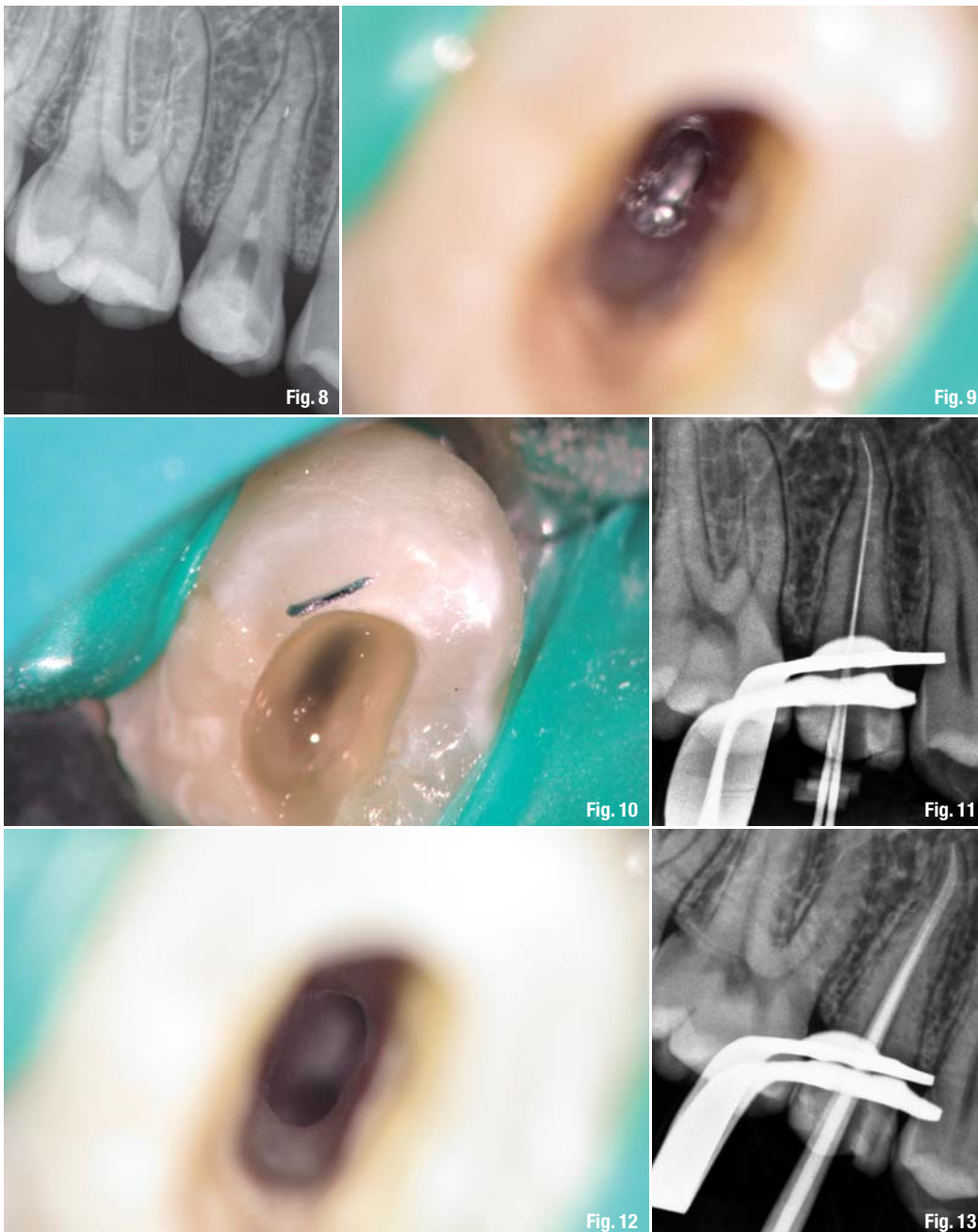
scraped with Micro-Debriders (DENTSPLY Maillefer) in order to remove the last remnants of gutta-percha. All canals were shaped to a size 40.06 ProFile. Final apical shaping was performed with K-Flexo-files (DENTSPLY Maillefer). Smear-layer removal was carried out by irrigating the canal with 10% citric acid. A final wash of the canal was performed with sterile saline. Tapered gutta-percha cones were then fitted (Fig. 4) and tug-back was confirmed. Topseal (DENTSPLY Maillefer) was used as a root-canal sealer.

Obturation was performed according to the continuous wave of condensation technique with the Elements Obturation Unit (SybronEndo). After

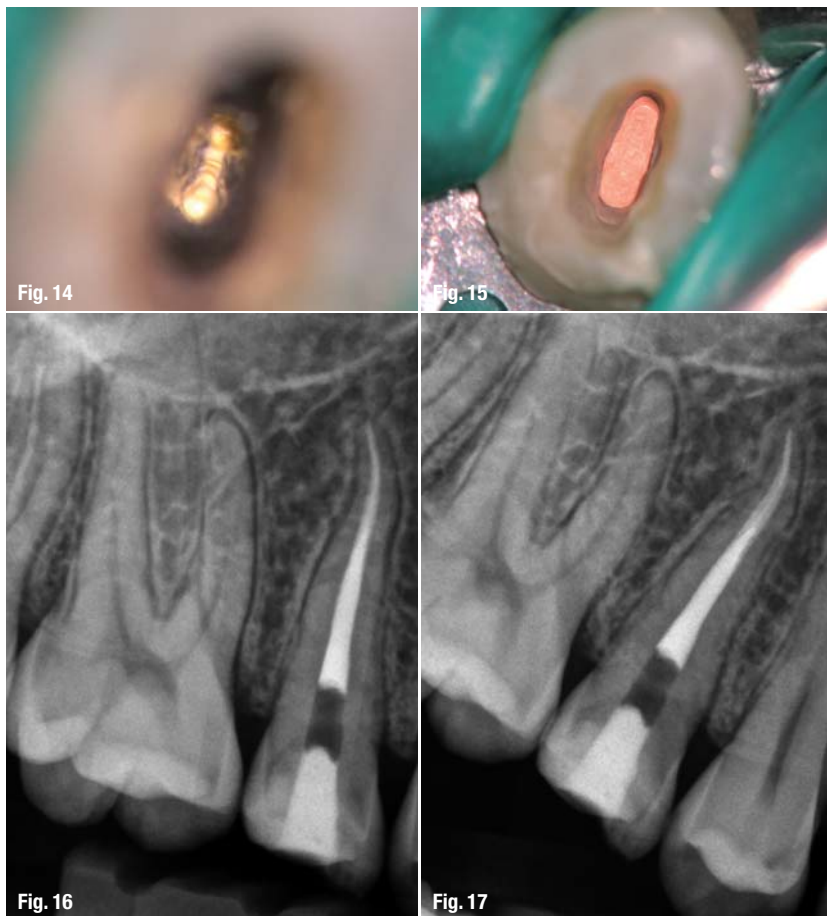
obturation (Fig. 5), a temporary restoration of glass-ionomer cement was placed (Fuji IX GP Fast). Final radiographs (Figs. 6 & 7) were taken, both parallel and angled. The radiographs show two completely separated mesial canals; hence, instrument removal in both canals was favourable. The prognosis of this case was good and the patient was referred to her general dentist for a definitive coronal restoration.

### Case II

A 19-year-old male patient was referred to our practice. He was in good health and had an ASA score of 1. The referring dentist had fractured a small instrument—most likely a size 10 or 15 K-file,



**Fig. 8** Diagnostic radiograph, showing the separated instrument at approx. 5 mm from the apex.  
**Fig. 9** The separated instrument.  
**Fig. 10** The separated file after retrieval.  
**Fig. 11** Working length determination.  
**Fig. 12** Deep apical split.  
**Fig. 13** Gutta-percha cone fitting.



**Fig. 14** Apical obturation with gutta-percha.  
**Fig. 15** The pulp chamber after complete obturation with gutta-percha.  
**Fig. 16** Final radiograph (parallel).  
**Fig. 17** Final radiograph (angled).

according to his referral letter—while performing root-canal treatment on tooth #4. The root-canal treatment was necessary because of a trauma that the patient suffered. The buccal cusp had fractured and the pulp was exposed.

A new diagnostic radiograph (Fig. 8) was taken, which showed the fragment approx. 5 mm from the apex. The tooth was isolated with a rubber dam and access was gained through the temporary restoration, which was placed by the referring dentist.

After opening, the remnants of calcium hydroxide paste were removed with 10% citric acid and passive ultrasonics. The fractured instrument could be visualised immediately (Fig. 9), because the canal was very large in the middle and coronal part. This allowed a very conservative and tissue-saving approach. Given the position in the canal and the shape of the canal, a deep apical split of the canal was suspected. After probing with small K-files, a patent palatal was confirmed.


The instrument was fractured in the buccal canal. A titanium ProUltra tip #8 (DENTSPLY Maillefer) was used to loosen the instrument. In the meantime, copious irrigation with 5% sodium hypochlorite was performed.

The fractured instrument was retrieved (Fig. 10) and after determining working length (Fig. 11), shaping with rotary nickel-titanium instruments (Twisted Files, SybronEndo) was started. Both canals were shaped to a size 25.08 Twisted File. The master apical file was kept small due to the deep split (Fig. 12) and the tension felt while shaping, thus minimising new instrument fracture. Apical finishing was carried out with size 25 K-flexofiles. Smear-layer removal was performed with a rinse of 10 % citric acid. A final wash of the canal was carried out with sterile saline. Tapered gutta-percha cones were then fitted and tug-back was confirmed (Fig. 13). Topseal was used as a root-canal sealer. Both canals were obturated according to the continuous wave of condensation technique with the Elements Obturation Unit. After obturation (Figs. 14 & 15), a temporary restoration in glass-ionomer cement was placed together with a cotton pellet, which was soaked in an alcohol and chlorhexidine mixture first and then air-dried after it had been placed in the access cavity. Final radiographs (Figs. 16 & 17) were taken, both parallel and angled. The prognosis of this case was good and the patient was referred to his general dentist for a definitive coronal restoration.

**Conclusion**

In the end, removal of a fractured instrument can be very difficult and it may take a long time to accomplish. Dr Marga Ree once said on the ROOTS forum that she was being taught that endodontics is all about the three Ps: Passion, Persistence and Patience. This hits the nail right on the head as far as instrument retrieval is concerned.

*Editorial note: A list of references is available from the publisher.*

<b>_about the author</b>	<b>roots</b>
	<p><b>Dr Rafaël Michiels</b> graduated from the Department of Dentistry at Ghent University, Belgium, in 2006. In 2009, he completed the three-year postgraduate programme in Endodontics at the University of Ghent. He works in two private practices limited to Endodontics in Belgium. He can be contacted at <a href="mailto:rafael.michiels@gmail.com">rafael.michiels@gmail.com</a> and via his website <a href="http://www.ontzenuwen.be">www.ontzenuwen.be</a>.</p>

# FORUM **FDM** DENTAL MEDITERRÁNEO

BARCELONA • 7-9 ABRIL 2011

Palacio de Congresos • Fira de Barcelona

# 2011

**Encuentros Profesionales  
y Exposición Industrial**

***Professional Meeting and  
Dental Trade Show***



PUNTEX  
Eventos

organiza:

[www.puntex.es](http://www.puntex.es)