

Treatment of oral leukoplakia with a 980 nm diode laser

Dr Maziar Mir, Prof. Norbert Gutknecht, Dr Masoud Mojahedi, Germany;
Dr Jan Tunér, Sweden & Dr Masoud Shabani, Iran

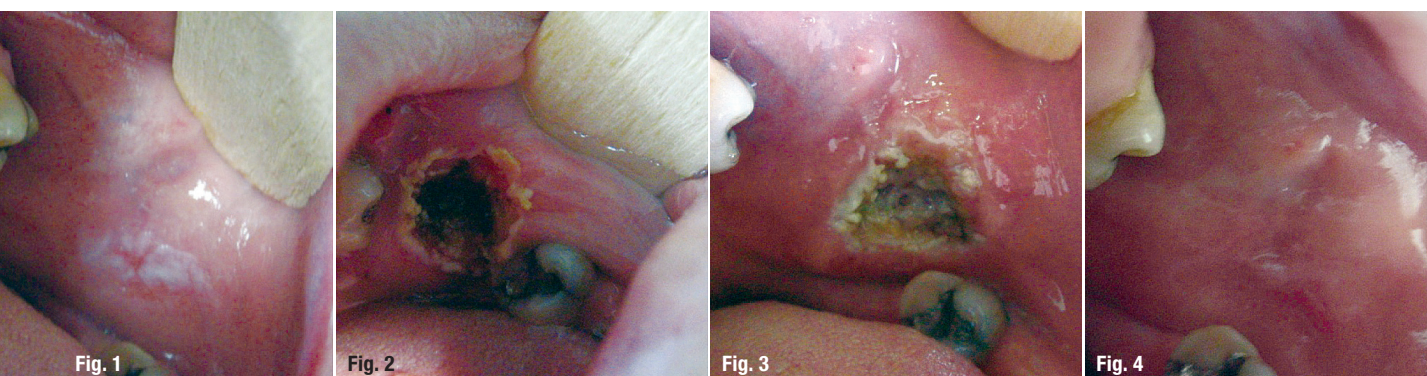


Fig. 1: Oral leukoplakia was diagnosed pre-op. **Fig. 2:** Clinical situation immediately after surgery. **Fig. 3:** Clinical situation one day after surgery. **Fig. 4:** Clinical situation at follow-up one month after surgery.

Leukoplakia is a common precancerous lesion of the oral cavity. It is defined as “a predominantly white lesion of the oral mucosa that cannot be characterised as any other definable lesion”.^{1–3} Clinically, leukoplakias are divided into homogenous (a thin, flat and uniform white plaque with at least one area that is well demarcated, with or without fissuring) and non-homogeneous lesions that are characterised by the presence of speckled or erythroplakic and nodular or verrucous areas.⁴ Various non-surgical treatments (including the use of carotenoids [beta-carotene, lycopene]; vitamins A, C and K; fenretinide; bleomycin; photodynamic therapy) and surgical treatments (including cryosurgery, electrocautery, laser ablation) have been reported.⁵ This article presents successful results of oral leukoplakia treatment with a 980nm diode laser.

Case report

A 55-year-old female patient with a white discoloration of her buccal mucosa that had been diagnosed as oral leukoplakia was referred for treatment with laser. The patient's medical history showed no systemic medical problems, no allergies, no prescribed medications or drugs that the patient was taking and no history of past surgical procedures, which was why the patient did not need to be referred for medical consultation. The oral and maxillofacial examination of the patient revealed no

temporomandibular joint dysfunction, myofascial disturbances or parafunctional habits. The patient maintained good overall dental hygiene. In terms of the clinical findings, there was white pigmentation on the buccal mucosa that was flat, well demarcated and painless for the patient. Based on these observations, oral homogenous leukoplakia was diagnosed (Fig. 1). Laser-assisted surgery with a 980nm diode laser was recommended to the patient as a treatment approach.

Procedure

After completion of the consent form, the operation area was anaesthetised through infiltration with 2% lidocaine with 1:80,000 adrenaline (1.8ml; Darou Pakhsh Pharmaceutical). The patient's information, such as the examination sheet and the completed consent form, was reviewed. The controlled area was defined and laser signs were properly displayed to secure the operating room. The eye protection (safety glasses) of the patient, her guardian and the assistant was checked. The patient's mouth was then rinsed with a 0.2% chlorhexidine oral rinse (Shahre Daru Pharmaceutical) for a duration of one minute. Then the oral leukoplakia was removed by means of a high-power diode laser (GIGAALASER). The laser was set to contact mode and the following parameters: wavelength of 980nm, power of 1.5W, 400µ fibre, initiated fibre and continuous wave.

After the procedure

The patient was advised to keep the area around the surgical site as clean as possible. She was also told to avoid foods and liquids that may have irritated the sensitive tissue and made it painful to eat. If necessary, over-the-counter analgesics were to be taken. The laser settings were documented in the patient's medical file.

Immediately after surgery, excellent oral leukoplakia removal was observed, with no bleeding, no carbonisation and no char (Fig. 2). The patient did not experience any discomfort and was satisfied. The first post-operative follow-up was scheduled one day after the procedure. As expected, healing was progressing well and there were no signs of swelling or pain (Fig. 3). At the follow-up after one month, a successful outcome was clinically observed (Fig. 4).


Discussion

Diode lasers are used extensively in many dental practices.⁶ Laser-tissue interaction with a high-power diode laser is based on photothermal effects.⁷ According to Nammour et al., the removal of a minimum of 1 mm in lesion depth and 3mm of surrounding healthy tissue can lead to the highest treatment success rate.⁸ Natekar et al. argue that diode laser or carbon dioxide laser surgery seems to be more effective than cryotherapy.⁹ Monteiro et al. report favourable experiences regarding oral leukoplakia surgery with an Er:YAG laser.¹⁰ The 980nm wavelength has low tissue penetration, which can be advantageous for removing superficial structures and protecting surrounding healthy tissue. Laser surgery of oral leukoplakia may be helpful in reducing malignant transformation of lesions. However, each patient should be aware of the recurrent nature of the lesion, which is why periodic monitoring is mandatory.^{11,12} Removing oral leukoplakia

through laser surgery is usually a quick procedure that typically does not result in bleeding, pain (in most cases) or oedema. Moreover, there is usually no need for analgesics, since lasers have analgesic effects on tissue. Since oral leukoplakia lesions tend to transform into malignant lesions, this procedure is traditionally classified as an advanced laser procedure.

Conclusion

The use of a 980nm diode laser following the treatment protocol which is described in this article has proven to be a successful alternative for treating patients with homogenous leukoplakia. Given the recurrent nature of the lesion, however, long-term follow-up appointments should be considered mandatory for the patient and should be taken seriously by the treating clinician.



about the author

Dr Masoud Shabani is a lecturer at the Department of Community Dentistry at the School of Dentistry of the Ardabil University of Medical Sciences in Ardabil in Iran.

contact

Dr Masoud Shabani

Department of Community Dentistry
School of Dentistry
Ardabil University of Medical Sciences
Ardabil, Iran
m.shabani@arums.ac.ir



AD

BECOME AN AUTHOR

for laser — international magazine of laser dentistry

Interdisciplinary and close to the market



www.oemus.com



Become part of a successful network and benefit from a wide reach and high level of awareness

Your benefits:

- author's profile at ZWP online
- specimen copies
- offprints
- speaking engagement*

Please contact Mr. Georg Isbaner:
g.isbaner@oemus-media.de
Phone: +49 341 48474-123

*according to the required profile

