

Facial swelling caused by infected teeth

Dual wavelengths for immediate healing

Dr Imneet Madan, UAE

Primary teeth retain their position in children's mouths until they reach the age of 10 to 12, when molars exfoliate. Until then, it is vital for primary teeth to stay cavity-free and in a healthy condition. A mindset that we encounter quite commonly is that primary teeth do not necessarily need to be treated, as they are to fall out anyway. Yet, the contrary is true: it can be argued that primary teeth play a vital role in paving the way towards healthy permanent dentition.

They have an important purpose and are of great significance for children. They contribute to a harmonic cosmetic smile, building children's self-confidence as a consequence—and, of course, they are vital for creating beautiful childhood photographs. Furthermore, primary teeth serve as natural placeholders for permanent teeth to erupt in the right position. Besides that, they are vital for digestion, since properly chewed food is digested better. Primary teeth are also important for the jaws to develop properly. Additionally, they help children to express themselves verbally, and they keep children from developing parafunctional habits, such as tongue thrusting or mouth breathing. Given these vital functions of primary teeth, it is by all means necessary to retain them and to refrain from premature extractions.

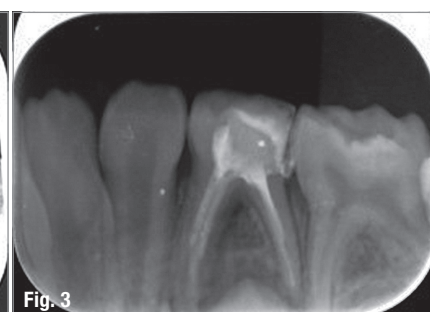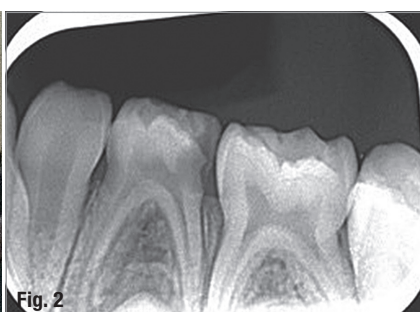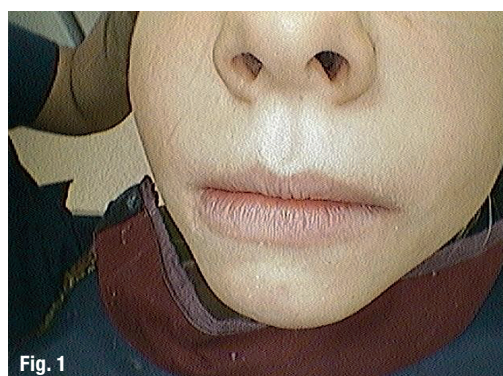
When dental health is compromised and the resulting conditions remain untreated, there is a strong possibility that permanent teeth will erupt into an unhealthy den-

tal environment, thus, compromising overall health. Good oral hygiene and well-maintained primary teeth, however, allow permanent teeth to erupt in a healthy fashion. Chronic untreated caries is the primary cause of long-standing infections. It goes without saying that the best mode of management is to prevent the onset of the condition in the first place. However, if dental decay and the associated condition are already present in a patient and have reached the stage of chronic infection in the periapical area, which in turn results in facial swelling, it is mandatory to consider treatment options.

Chronic irreversible pulpitis is one of the primary causes of facial swelling, gingival infections, and abscesses. Untreated primary molars with gross decay allow for bacteria to enter and accumulate inside the pulp, leading to the death of the pulp as a consequence. This is referred to as necrosed or non-vital pulp. Bacteria feed on pulp contents and produce exudate that seeps into the facial spaces, often leading to face swelling.

Case reports

This article will depict two cases in which facial swelling was caused by grossly decayed molars in children. In both cases, laser-assisted root canal therapy was suggested as an alternative to extraction in order to retain the teeth. Both children were under periodic follow-up at the time of writing.



Case 1—Fig. 1: Clinical situation at first appointment with swelling visible. **Figs. 2 & 3:** Intraoral radiographs taken prior to treatment.

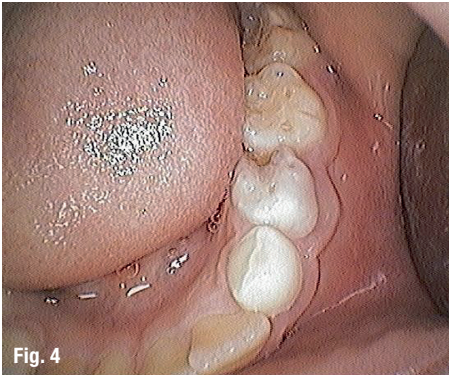


Fig. 4

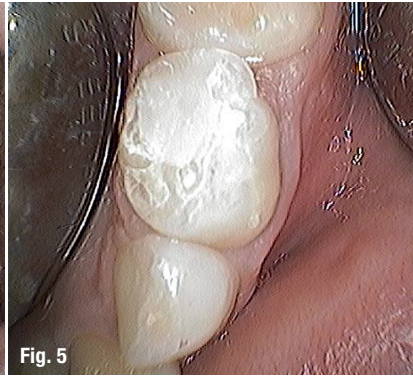


Fig. 5

Case 1—Figs. 4 & 5: Intraoral examination revealed Grade II mobility of tooth #74 and a periapical infection caused by carious decay.

Case 1

An 8-year-old girl presented with the left half of her face swollen (Fig. 1). She complained about pain when chewing and continuous discomfort. The child showed mild symptoms of fever. Upon intraoral examination, it was found that tooth #74 had Grade II mobility and periapical swelling was present (Figs. 2 & 3). Intraoral periapical radiographs showed a widening of the periodontal ligament in the periapical area (Figs. 4 & 5). The tooth was tender to percussion and the child was in discomfort owing to infection and swelling extending up to the lower jaw. In this case, the submandibular swelling was primarily caused by long-standing carious decay that extended into the pulp, resulting in a periapical infection.

Case 2

A 4-year-old boy came to our surgery with his face swollen in the area around a maxillary right posterior tooth (Fig. 6). The swelling extended from the upper right cheek to his ears and lower eyelids. The boy had a fever and he had not slept well the night before the appointment. Upon intraoral examination, it was noted that tooth #54 had Grade I mobility and that it had an old filling. Intraoral periapical radiographs (Figs. 7 & 8) and the medical history of the patient revealed that a deep filling with indirect pulp capping had been done approximately five months before, in August 2018. At the time the filling was done, dental decay had been in close proximity to the nerve, but the procedure was carried out nonetheless.

Before the treatment

Treatment options

Two options were proposed for treating the compromised primary tooth. The first approach would involve tooth extraction followed by the insertion of a space maintainer. The second option was laser-assisted root canal therapy. Yet, a successful treatment outcome could not be guaranteed with this option. In the case of a reinfection, the first option would have to be seriously considered. Scientific research has shown that bacteria remains in the root canals to a depth of up to 1,000µm. Conventional root canal therapy is able to clean canals up to this depth. With laser-assisted treatment, however, canals can be cleaned to a depth of 600–800µm. The two treatment options, as well as the associated costs, were explained to the parents. In both cases, the parents opted for the laser-assisted root canal therapy.

Informed consent

Owing to the nature of the pathology, only an uncertain prognosis could be made. The parents understood that, in the case of failure, the teeth would need to be extracted. The treatment costs for both approaches were thoroughly explained to them. Consent forms for the approach that was agreed on were completed and signed.

Treatment sequence

Dental behaviour management

In Case 1, the girl was able to cope very well with only basic behaviour manage-

BECOME AN AUTHOR

for ceramic implants
—international magazine of ceramic implant technology

Interdisciplinary and close to the market



www.oemus.com

Fax:
+49 341 48474-290

☐ Yes, I want to become an **author** for ceramic implants—international magazine of ceramic implant technology. I would like to submit an article on the following topic:

Please send back your fax form or contact

Mr **Georg Isbaner**: g.isbaner@oemus-media.de

Phone: +49 341 48474-123

Last Name, First Name

Street, ZIP, City

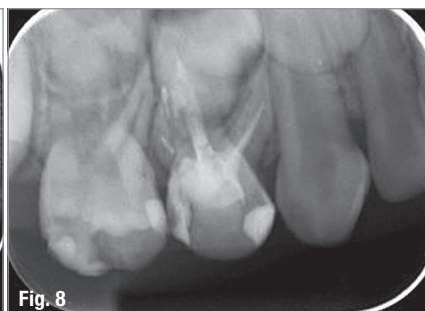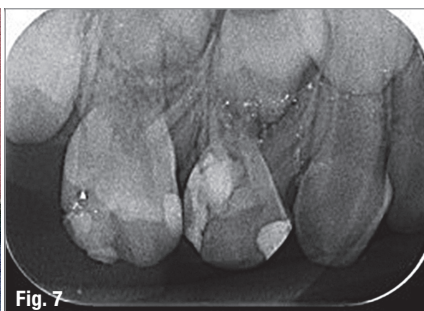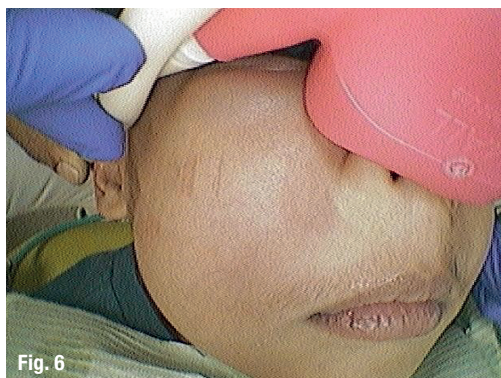Phone, E-Mail

Stamp

laser 2/19

OEMUS MEDIA AG

Holbeinstraße 29 · 04229 Leipzig · Germany
Phone: +49 341 48474-0 · info@oemus-media.de



Case 2—Fig. 6: Swelling extended from the upper right cheek to the patient's ears and lower eyelids. **Figs. 7 & 8:** Intraoral radiographs taken prior to treatment.

ment techniques, whereas in Case 2, conscious sedation with nitrous oxide was needed (Fig. 9). Paediatric dentistry revolves majorly around how we communicate and present the individual treatment steps to children that are about to be treated. Surgical terms should be euphemised and communicated in a child-friendly manner. For instance, a nasal mask can be referred to as “happy air”, a laser as “popping light”, caries as “sugar bugs”, a dental cavity as “hole”, a cotton roll as “tooth pillow”, irrigating the canals as “washing the sugar bugs”, obturation as “putting cream in the tooth” and applying tooth filling material as “closing the hole”.

Neurolinguistic programming

In the cases described here, neurolinguistic programming was used as a way to obtain the children's attention and cooperation and to have them follow deep-breathing instructions. In combination with conscious sedation through nitrous oxide, neurolinguistic programming works well for calming down children ahead of treatment. In both cases, treatment started already at the first appointment owing to severe swelling. The procedure began five minutes after administering sedation in Case 2. The amount of administered nitrous oxide was slowly increased to 55%. During treatment, a movie was shown overhead for the purpose of distracting the children. Since both children were able to listen attentively after the treatment, the steps for the next visit were commu-

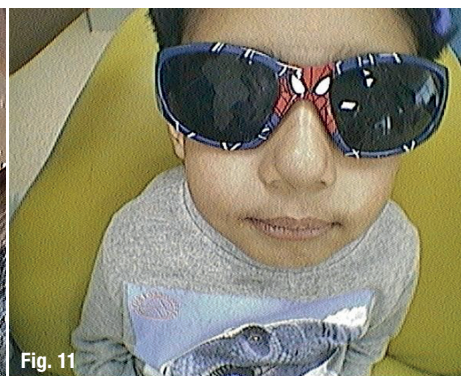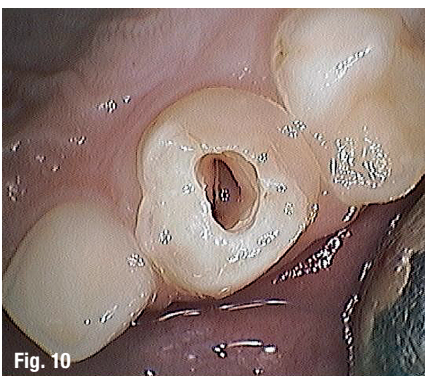
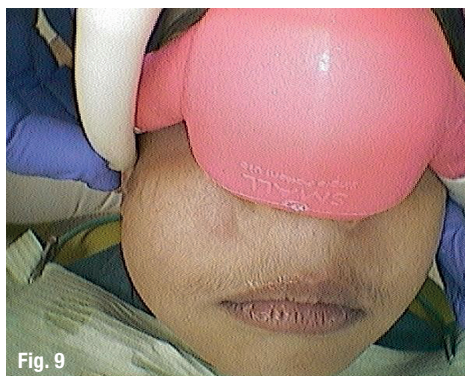nicated to them. Before leaving the practice, they were given a small reward for behaving well and listening attentively during the appointment, which hopefully had a positively reinforcing effect.

Nitrous oxide

Nitrous oxide, commonly known as “laughing gas”, was administered in order to relax the receptors. It has an analgesic or anxiolytic effect, which causes temporary depression of the central nervous system. It is absorbed rapidly and remains relatively insoluble in any tissues in the body. At the end of the procedure, 100% oxygen is used to flush out the nitrous oxide. There is minimal impairment of bodily reflexes.

Surgical procedure

The Er,Cr:YSGG laser, with the MX7 tip, was directed to the occlusal surface and set to the following parameters: 2,780nm, 3.75W, 25Hz, water 80 and air 60. Rotary instruments were used to enlarge the canals up to ISO #35. Intermittent irrigation with saline and chlorhexidine was done. For sterilising the canals initially, the Er,Cr:YSGG laser, with the RFT2, was set to 2,780nm, 1.25W, 50Hz, water 24 and air 34. Paper points were then used to dry the canals. A diode laser in continuous wave mode was then used, set at 940nm, 1.5W, 2mm/second, four to five turns in circular motion. At that point, an open dressing was put on to the site.



Case 2—Fig. 9: Nitrous oxide was used to calm the patient down. **Fig. 10:** The filling in tooth #54 was removed. **Fig. 11:** The procedure was completed after three appointments.

At the second appointment, two days later, the open dressing was removed. The canals were re-irrigated with saline and chlorhexidine. Both erbium and diode lasers were used to sterilise the radicular and periapical areas. In Case 1, the canals showed no bleeding and were completely dry. Zinc oxide eugenol obturation was carried out, followed by a base filling with dental cement (GC Fuji IX GP, GC) and composite filling on top. In Case 2, since the swelling had not regressed completely, it was decided to place a temporary filling first (Fig. 10).

In Case 1, the procedure was completed after two appointments, whereas in Case 2, it was complete after three (Fig. 11). There was no need to prescribe antibiotics post-operatively. Periodic follow-up appointments were scheduled for both patients, with the first starting three months after the treatment. Stainless-steel crowns were prospectively planned in the case of no further reinfections.

Discussion

Microbiology of periapical infections

The microbiology of fistulas is complex. The deep areas around the periapical region are low in oxygen, allowing only anaerobic bacteria to dwell there. They cause pain, swelling, tenderness and exudation of pus. A high prevalence of *Enterococcus* species and *Porphyromonas gingivalis* is found in the necrotic pulp of 2- to 5-year-old children. *P. gingivalis* has been found to affect about 27 % of primary teeth. *Prevotella nigrescens*, *Prevotella intermedia* and *Porphyromonas endodontalis* also contribute to the infectious processes inside the pulp. *Fusobacterium nucleatum* too is a bacterium that contributes to an increase of the earlier-mentioned symptoms. *Enterococcus faecalis*, *P. gingivalis* and *F. nucleatum* are found in extensive numbers, especially in fistulas related to primary teeth. It is because of the complex nature of the primary root canal microbiology that conventional treatment supported only with antimicrobials often is not completely successful.

Reasons for complicated infections in primary teeth

Primary teeth diagnosed with chronic gross decay have a high chance of recurring infections. There are certain factors that compromise the health of primary tooth root canals. For a start, there is the anatomical root configuration. Variations in the root canal anatomy of primary teeth can complicate dental treatment. Primary teeth have flat ribbon-shaped canals with multiple lateral canals that often cannot be properly sealed after treatment. Also, these lateral canals accommodate bacteria in their deep ends. Roots in primary teeth are in a constant state of resorption due to eruptive forces from the underlying permanent teeth. This leads to a steady ingress of bacteria. Moreover, canal openings in the apical delta contribute to bacteria spreading even further. Another factor compromising the health of root canals of primary teeth is the complex resident bacterial flora. As stated earlier, scien-

tific research suggests that bacteria are found at a depth of up to 1,000 µm in the root canals.

Benefits of laser-assisted treatment


Conventional irrigants used in pulpectomy penetrate canals to a depth of about 100 µm. Penetrating a depth between 500 µm and 1,000 µm, lasers of different wavelengths can be considered a valuable treatment alternative. They permanently destroy the microbial cell membrane, thus, stopping any further growth. As laser allows for such a deep reach, there is a higher possibility of bacterial lysis. After laser-assisted treatment, clinical symptoms should have ceased to exist and radiographs should show no signs of treatment failure.

Conclusion

Laser-assisted endodontic treatment in compromised primary teeth has come a long way. When this treatment is suggested as an alternative approach to dental extraction, most parents tend to opt for this treatment, since they understand that early loss of primary tooth can lead to numerous complications later in life. In addition, dental extraction is most certainly more psychologically challenging for a child.

Editorial note: References can be provided by the author upon request.

about the author



Dr Imneet Madan is a UAE-based dentist specialising in paediatric dentistry and laser dentistry. She obtained an MSc in Lasers in Dentistry from the Aachen Dental Laser Center at RWTH Aachen University in Germany. In addition, she is a coach in neurolinguistic programming, a psycho-communicative approach, and has Six Sigma Green Belt certification.

contact

Dr Imneet Madan

Laser Pediatric Dentist
NLP Coach
Six Sigma Green Belt
MDS (Pediatric Dentistry)
MSc (Laser Dentistry, AALZ, RWTH Aachen University)
Children's Dental Center, Dubai
Villa 1020 Al Wasl Road
Umm Suqeim 1, Dubai
United Arab Emirates
Phone: +971 506823462
imneet.madan@yahoo.com
www.drmichaels.com

