

Comparing various implant designs and surfaces

A clinical study

Authors_Dr Roy Leshem¹, David Leshem², Israel

_Abstract

A clinical study of various types of Hi-Tec Implants (Herzlia, Israel)—uncoated titanium thread implants & push-in cylinder implants, coated with either TPS or hydroxyapatite (HA) surfaces, used by a surgical team in various surgical procedures. The purpose of the study was to find whether the design or coating of implants has any effect on the success rate and integration of the implant in different procedures. The study did not indicate any statistical significance in the success rate of the different implants in the different types of procedures: simple implantology, sinus lift procedures, bone augmentation and immediate extraction sites.

comparison between HA and TPS coated cylinder implants have been documented.³ Use of implants varies in different procedures, and comparisons between the success rate in different procedures including placing implants immediately in to fresh extraction sites is documented^{4,5,6} as well as success rate in different locations.⁷

The objective of the study was to present the success rate of fixtures of different designs and surfaces used in complex implant procedures, implants placed in internal sinus lift procedures (Figs. 1a–b), implants placed in lateral sinus lift procedures (Figs. 2a–b) bone augmentations, implants placed including grafting of buccal defect (Figs. 3a–d), and implants placed simultaneously with teeth extractions (Figs. 4a–d), all performed by one team.

_Introduction

Various implant designs and implant coatings are in wide use and success rates are of the various designs and surfaces are well documented. Success rate comparison between HA coated and non coated threaded implants^{1,2} as well as

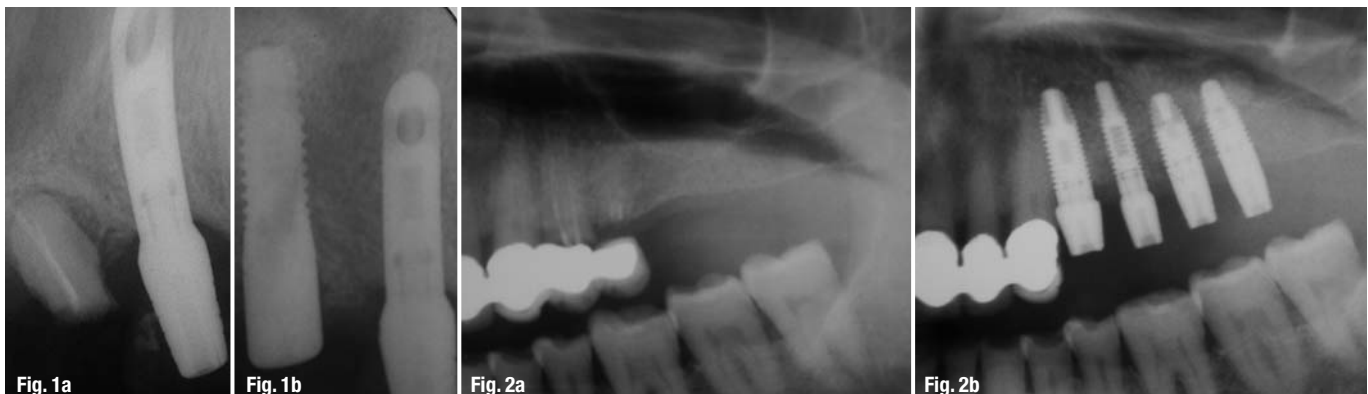The retrospective study was conducted on patients treated at the Maxillary Facial Dept. of the Meir Hospital, Kfar Saba Israel, and comprised of 144 implants consequently placed over a period of 4 years in 44 patients with partial or complete eden-

Fig. 1a_Alveolar bone height 1 mm to sinus, before extracting second premolar.

Fig. 1b_13 mm 4.2 thread implant placed with closed technique sinus augmentation.

Fig. 2a_Alveolar bone height 3 mm to sinus.

Fig. 2b_11.5 mm 5.0 thread implants placed with closed technique sinus augmentation.



It's Time for a ReThink: High Quality at factory-direct Prices



Spectra-System
Six application-specific implants
All-in-One Package: €115



Hexagon



Zimmer® Dental*
Legacy 1 Line
Legacy 2 Line
Legacy 3 Line
Implant: from €100



Tri-Lobe



Nobel Biocare™*
RePlant Line
RePlus Line
ReActive Line
All-in-One Package: from €115



Octagon



Straumann*
SX-Plant Line
All-in-One Package: €145

All-in-One Package: includes implant, abutment, cover screw, healing collar, comfort cap and transfer

**In times of financial constraints –
look for innovation with the best value!**

Implant Direct sets new standards with high-quality implants with low prices and value added All-in-One™ Packaging for only 115 Euro per implant, including the corresponding prosthetic components. Besides the unique Spectra System, we offer compatible implant systems to Nobel Biocare™, Straumann and Zimmer® Dental. Make a decision today and choose a path of smart solutions and considerably more profit.

*Registered trademarks of Straumann, Zimmer® Dental and Nobel Biocare™



Tollfree Infoline: 00800 4030 4030
www.implantdirect.eu
Europe's No. 1 Online Provider for Dental Implants



**Implant
Direct™**

simply smarter.

Distribution of implants regarding sex and jaw			
Jaw	Female	Male	Total
Maxilla	44	36	80
Mandible	29	35	64
Total	73	71	144

Tab. 1

Distribution of implants regarding type of endulism & jaw				
Jaw	Complete edentulous	Multiple missing teeth	Single missing teeth	Total
Maxilla	20	55	5	80
Mandible	30	30	4	64
Total	50	85	9	144

Tab. 2

Distribution of implants by types of anesthesia			
Anesthetic	General	Local	Total
Maxilla	33	47	80
Mandible	10	54	64

Tab. 3

implants (Smooth-Fit, Hi-Tec Implants, Herzlia, Israel).

Titanium Plasma Spray Coated cylinder shape Implants (Smooth-Fit, Hi-Tec Implants, Herzlia, Israel). 3.75 and 5.00 uncoated Self-Tapping Thread Titanium Implants (Self Thread, Hi-Tec Implants, Herzlia, Israel). The coated fixtures were made of surgical titanium alloy, coated with 50 microns layer of hydroxyapatite or titanium plasma spray and have a 1 mm polished (uncoated) collar from the neck of the implant. The uncoated thread implants were made of surgical titanium alloy with acid etched surface. Various length implants were used.

The patient underwent routine medical, dental and radiographic assessment (including panoramic radiography) and was evaluated to determine whether the procedure was feasible and if positive, the treatment procedure was planned. Each patient was counseled concerning the nature of the treatment, and a comprehensive consent form was signed.

Surgical placement of the implants was based on the following procedure: The patient was placed under local or general anesthesia. Depending upon the site of the intended procedure, a mid-crestal incision was made, and a flap was lifted exposing the underlying bone. An osteotomy was performed with internal irrigated drills using sterile physiological water. The implant was inserted into the prepared site and the flaps were closed by sutures. During this four year period surgeries were performed on 44 patients: 26 women and 18 men.

Stage II was performed under local anesthetic 3–6 months after Stage I.

This entailed opening a flap, exposing the cover screw and replacing it with a Titanium 3 mm or 5 mm Healing Cap (Hi-Tec Implants, Herzlia, Israel).

Fig. 3a_Buccal defect connecting to the socket of first premolar with 2.0 mm remaining of buccal wall.

Fig. 3b_Placing 4.2 mm Tapered Self Thread Implant.

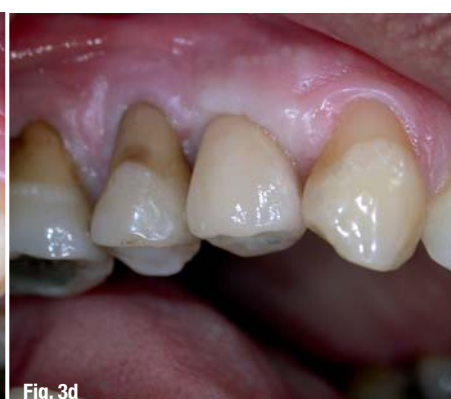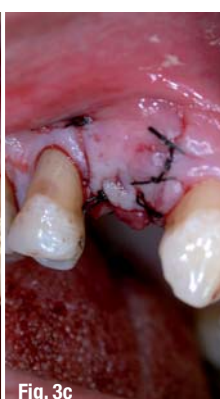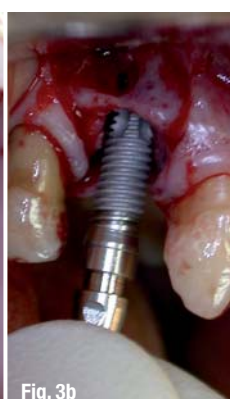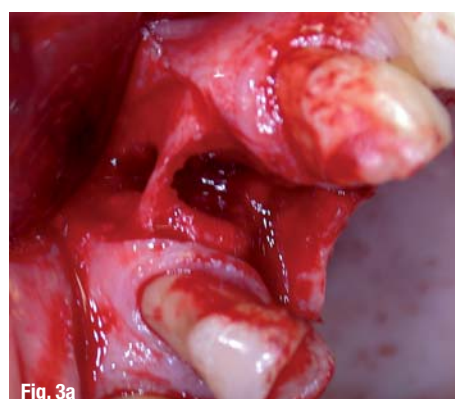Fig. 3c_Complete closure after augmentation of buccal defect and socket.

Fig. 3d_Final restoration with Zirconium Abutment.

tulous. Five implants failed (3.47 %), two in the maxilla (2.81 %) and three in the mandible (4.10 %).

Materials and Methods

The study consists of 144 consequently placed 3.50 mm hydroxyapatite-coated cylinder shape



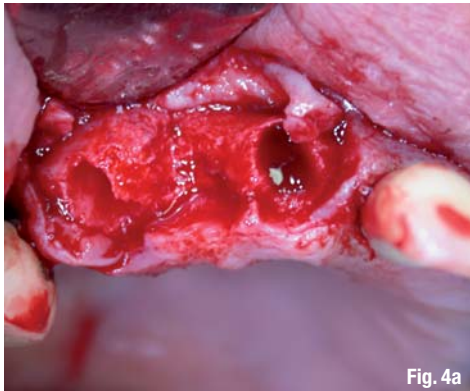


Fig. 4a

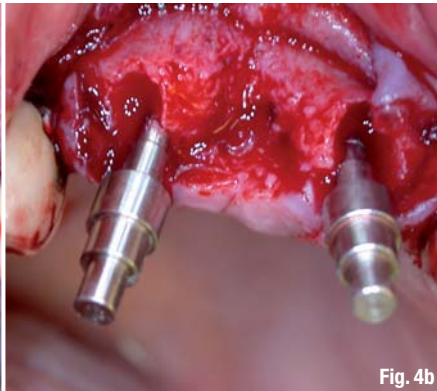


Fig. 4b

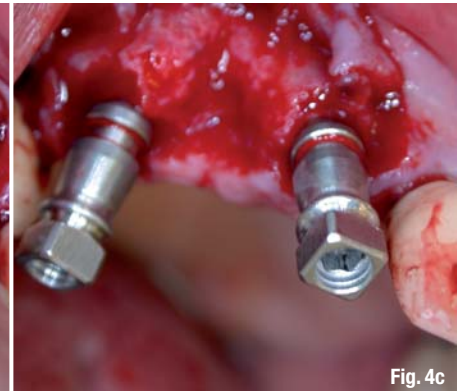


Fig. 4c

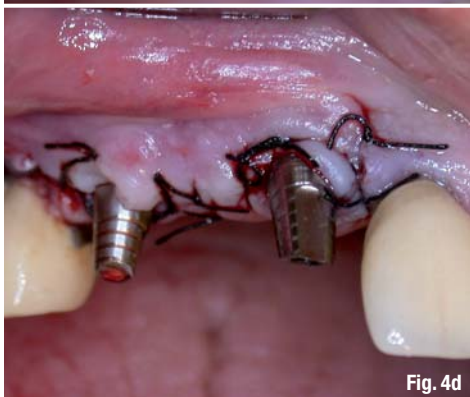


Fig. 4d

13 mm implant located in anterior maxilla was placed in a resorbed narrow ridge (2 mm). One 13 mm implant, placed in the anterior mandible, immediately after the extraction of a contaminated fractured tooth. No specific pattern regarding fixture size could be observed.

All types of implants used in the sinus lift procedures presented a 100 % success rate. Four Implants were lost in immediate extraction sites, in resorbed bone sites, and poor bone quality, all lost implants were threaded non-coated implants, statistical significance was not substantiated. Using Pearson's Chi Square test a statistically significant association was found between the three types ($p = 0.04$)

Fig. 4a_Extraction of central incisor and canine.

Fig. 4b_Paralleling tools in extraction sites.

Fig. 4c_Two 3.75 mm Tapered Self Thread Implant placed in the fresh sockets.

Fig. 4d_Abutments placed on implants for immediate provisional restoration.

Results

There were no dropouts of patients during the follow-up stages. Prior to performing the prosthesis, the implant site was evaluated to determine osseointegration. Five implants 3.47% were recorded as failures during the follow-up period. Two of the failed implants, 2.81 %, were in maxilla and three of the implants, 4.10 %, in the mandible. Failed implants were present in five patients. The distribution of the failed implants regarding sex, jaw type, presented in the following table.

Two of the failing implants were identified and removed during Surgical Stage II and one was lost during preparation of temporary restoration. Two of the lost implants, posterior maxilla and posterior mandible, were 10 mm long. Three of the lost implants (anterior maxilla and anterior mandible, were 13 mm long.

One of the failed implants (anterior maxilla) was placed in the site of bone augmentation and associated with a jaw splitting procedure during Stage I surgery, followed up by using a temporary full denture and commented in protocol at the time of implant placement.

Failures were related to:

One 10 mm implant located in poor bone quality of posterior maxilla in an extraction site. One 10 mm implant located in posterior mandible. One

Discussion

The results of the study present 3.47 % failure rate (five implants). This is a most favorable result taking into consideration that many of the implants were placed in most unfavorable sites including those with bone defects, unhealed bone extraction sites, sinus lift procedures, bone grafting sites, ridge augmentation and implants placed in extremely narrow ridges.^{4,5,6} Implants lost were correlated to the posterior zone due to poorer bone quality,⁷ narrow ridge and other unfavorable conditions. Posterior maxilla and mandible bone structure is less condensed and therefore the ability of firm osseointegration of the implant is reduced.

Distribution of implant length

	8 mm	10 mm	13 mm	16 mm	Total
HA Smooth Fit	0	0	3	4	17
TPS Smooth Fit	0	12	33	18	63
Self Thread	0	22	42	0	64

Tab. 4

Distribution of implant placement combined with bone grafting or sinus lift

	Self Thread	TPS SmoothFit	HA Smooth	Fit Total
Bone graft	26	9	1	46
Sinus lift	6	22	7	35
Total	32	31	18	81

Tab. 5

Implant sites must therefore be evaluated prior to surgery and high risk sites should be bone grafted prior to inserting the implant in order to reduce the occurrence of early and late failures. Naturally should the necessity arise, the surgeon must be skilled in all the different procedures. One fixture that was considered successful during Stage II was found to be mobile during abutment connection. This raises the theory that in poor bone quality, opening and tightening of the healing screw can damage newly formed bone which will consequently resorb and lead to implant mobility.

Distribution of implants placed in immediate extraction site

Self Thread	TPS Smooth Fit	HA Smooth Fit
16	4	0

Tab. 6

The study did not find any statistical correlation between the success rates of different procedures to the types of implants used.

_References

1. A comparison of hydroxyapatite (HA) – Coated threaded, HA – coated cylindric, and titanium threaded endosseous dental implantsd. Jeffcoat MK, et al. Int J Oral Maxillofac Implants. 2003 May-Jun;18(3):406–10.
2. A comparison of hydroxyapatite-coated Micro-Vent and pure titanium Swede-Vent implants. Evian CI. Int J Oral Maxillofac Implants. 1996 Sep-Oct;11(5):639–44.
3. A 5-year comparison of hydroxyapatite-coated titanium plasma-sprayed and titanium plasma-sprayed cylinder dental implants. Jones JD, et al. Oral Surg Oral Med Oral Pathol Oral Radiol Endod. 1999 Jun;87(6):649–52.
4. Immediate or early placement of implants following tooth extraction: review of biologic basis, clinical procedures, and outcomes. Chen ST, Wilson TG Jr, Hämmerle CH. Int J Oral Maxillofac Implants. 2004;19 Suppl:12–25.
5. Survival of immediately provisionalized dental implants placed immediately into fresh extraction sockets. Schwartz-Arad D, Laviv A, Levin L. J Periodontol. 2007 Feb;78(2):219–23.
6. Placement of hydroxyapatite-coated implants into fresh or recent extraction sites. Raymond AY. Dental Clinics of North America. 1992; Jan;36(1):97–115.
7. Implant zones of the jaws: implant location and related success rate. Tolstunov L. J Oral Implantol. 2007;33(4): 211–20.

Distribution of failed implant with regard to jaw, sex & location

Jaw Type	Female	Male	Posterior	Anterior
Maxilla	2	0	2	0
Mandible	2	1	1	2
Total	4	1	3	2

Tab. 7

Distribution of lengths of failed implants

	10 mm	12 mm	16 mm	Total
TPS Smooth Fit 3.5	0	0	0	0
HA Smooth Fit 3.5	0	0	0	0
Self Thread 3.75	1	3	0	4
Self Thread 5.00	1	0	0	1
Total	2	3	0	5

Tab. 8

Placing implants in poor quality bone in posterior areas and sites with complications increase the risk failure rate. It is even more crucial when the bone is not able to provide initial stability for implants or if the preparation has a fractured wall on one side or more. No considerable difference was noticed in the success rate when the implant placement was combined with bone grafting or bone grafting with sinus lifting.

_contact
implants
Dr Roy Leshem DMD

1 Maskitstreet
Herzlia, Israel
E-mail: hitecimp@netvision.net.il

¹ Private practice, Herzlia, Israel

² Head of Pediatric & Craniofacial Plastic Surgery,
The Tel Aviv Sourasky Medical Center, Israel.

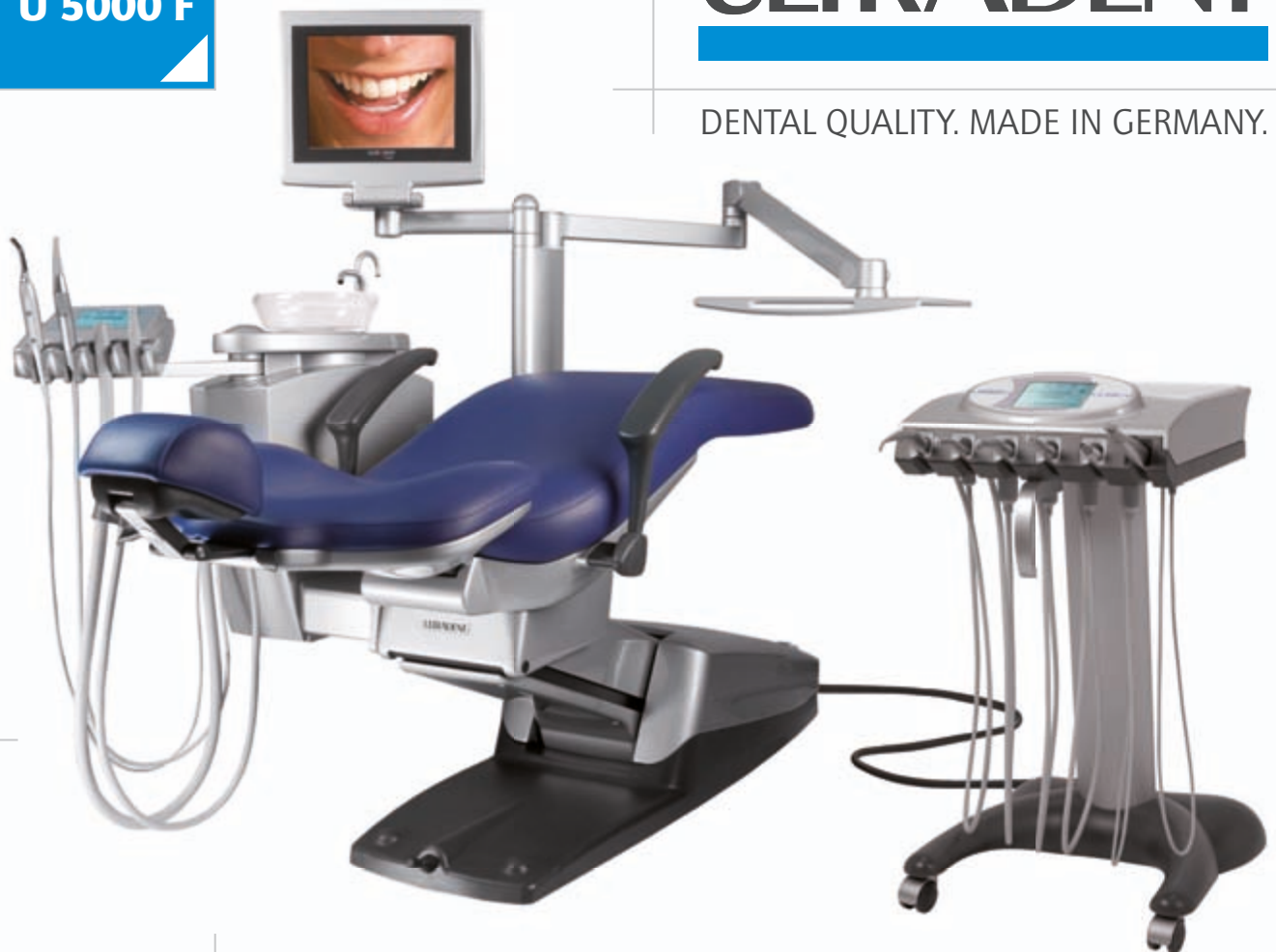PREMIUM
CLASS
U 5000 F

ULTRADENT

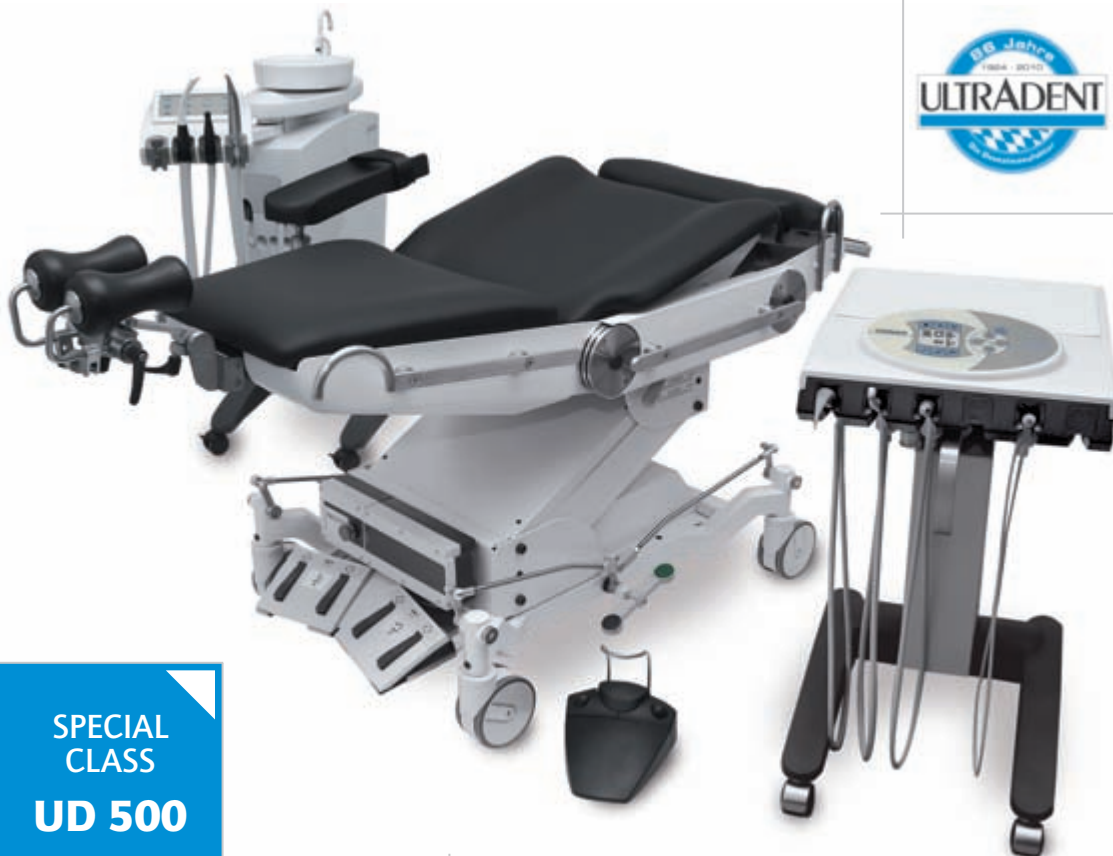DENTAL QUALITY. MADE IN GERMANY.



You
deserve
PERFECTION.



More
safety.
**More
comfort.**



You
deserve
INNOVATION.

SPECIAL
CLASS
UD 500

New
standards.
**New
goals.**

ULTRADENT Dental-Medizinische Geräte GmbH & Co. KG
Germany - 85649 Brunnthal • Eugen-Sänger-Ring 10
Fon: +49 89/420 992-70 • Fax: +49 89/420 992-50

www.ultradent.de