

# The periodontal pocket

## Alternative treatment with the Er:YAG laser and PRF

Dr Fabrice Baudot, France

### Introduction

Developments in our knowledge in the fields of biology, microbiology, tissue engineering<sup>1</sup> and technological progress have motivated the proposal of new therapeutic approaches and new surgical protocols to treat periodontal diseases. Periodontal diseases are chronic inflammatory pathologies resulting from an imbalance between the oral microbial flora and the patient's defence systems.<sup>2,3</sup> They are characterised by the presence of periodontal pockets, which are actually open wounds in a septic environment. The treatment of periodontitis consists of managing the risk factors of the imbalance and, in particular, of ensuring the disappearance of its chronic inflammatory wounds, which are the periodontal pockets.<sup>4</sup> The fundamental therapeutic concept for treating these wounds is simple: they must be cleaned so that they heal. A minimally invasive Er:YAG laser-assisted protocol is proposed here, as a supplement to conventional instrumentation, to transform these chronic inflammatory wounds into clean surgical wounds. Platelet-rich fibrin (PRF) is used to protect these wounds and stimulate healing (Figs. 1 & 2).

### The periodontal pocket: A chronic inflammatory wound

The pockets represent the progression front of the pathology. They are the site of an aggressive and complex microbial proliferation which induces a cascade of inflammatory reactions, leading to the tissue destruction of the periodontium.<sup>5</sup> All of these events occur in a confined space relatively inaccessible to oral hygiene and produce an inflammatory infiltrate within the periodontal pocket. An acquired inflammatory reaction turns chronic because the presence of pathogenic agents is permanent and continually renewed in this open space. The inflammatory infiltrate is located in the internal layer of the gingival margin of the periodontal pocket. The epithelium of the pocket is completely destroyed by the proteolytic enzymes induced by the inflammatory reaction and allows the microbiota to pass and penetrate the tissue (and beyond), representing a chronic inflammatory infiltrate.<sup>6</sup>

In order to stop the progression of this inflammatory state, the infiltrate must be specifically eliminated and the periodontal pocket must be cleaned;<sup>6,8</sup> thus, the chronic

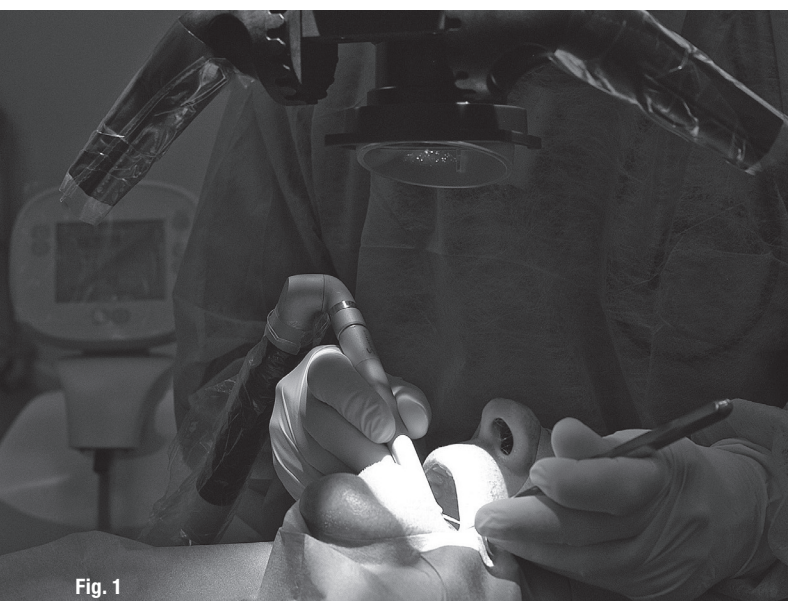

Fig. 1




Fig. 2

**Figs. 1 & 2:** The Er:YAG laser and PRF synergy with the use of optical aids in the microsurgical treatment of periodontal pockets, a therapeutic breakthrough in the treatment of periodontitis.

inflammatory wound becomes a clean surgical wound which will be able to heal.<sup>9</sup> The pathogenic agents and the local risk factors are eliminated. The acquired immune reaction resulting from the persistence of pathogenic agents will disappear, allowing healing and tissue reconstruction. In this simple therapeutic concept, natural healing will be stimulated by a tissue engineering procedure consisting of protecting the clean periodontal wounds using PRF pellets. To maintain and optimise the healing potential of the periodontium, which is considerable, the surrounding vascular and tissue structures should be preserved. It is for this reason that minimally invasive periodontal cleaning protocols are favoured for the cleaning of the periodontal pockets.

### The Er:YAG laser: A microsurgical cleaning tool

There are numerous mini-invasive protocols for cleaning the deep periodontium: PPT,<sup>10</sup> ITM,<sup>11</sup> MPPT,<sup>12</sup> SPPT,<sup>12</sup> SFA<sup>13,14</sup>. The protocol proposed here is becoming part of the family of minimally invasive surgical protocols.<sup>15</sup> It is performed entirely with optical aids of a minimum of 3.5x magnification. The hard wall of the periodontal pocket is traditionally cleaned using ultrasound with micro-inserts and under visual control. The Er:YAG laser is used to eliminate the inflammatory infiltrate on the internal part of the marginal gingiva and on the bone. It also allows fine decontamination of the radicular surface after the elimination of calculus using ultrasound.<sup>16</sup> The Er:YAG wavelength (2,940nm) has the principal characteristic of being significantly absorbed by water.<sup>17</sup> This physical property gives it minimally invasive clinical effects. The energy delivered by the beam to the targeted tissue is massively absorbed by the first cellular layers, which are significantly hydrated in human tissue. This irradiation causes vaporisation of the first tissue layers. The Er:YAG laser acts on the surface through tissue micro-ablation. Since the energy is massively absorbed at the surface, there is no transmission of this energy to deeper levels, thus the risk of increased temperature in the neighbouring tissue structures is almost zero. The thermal alteration layer from Er:YAG radiation is between 5 and 50µ.<sup>18</sup>

The impact of the Er:YAG beam with matter generates a shock wave. This is the second clinical effect of the Er:YAG laser: the photoacoustic effect. Generated in a confined space (the periodontal pocket), this shock wave causes intense agitation of the irrigating solution and contributes to the destabilisation of biofilm and flushing of the cleaned space.<sup>19,20</sup> This photoacoustic effect takes place in the three dimensions of the space being treated and in the zones which are completely inaccessible to conventional instrumentation, such as root furcations or deep angular pockets. The Er:YAG laser realises its full potential where conventional instrumentation reaches its limits. The Er:YAG laser constitutes a key element in the

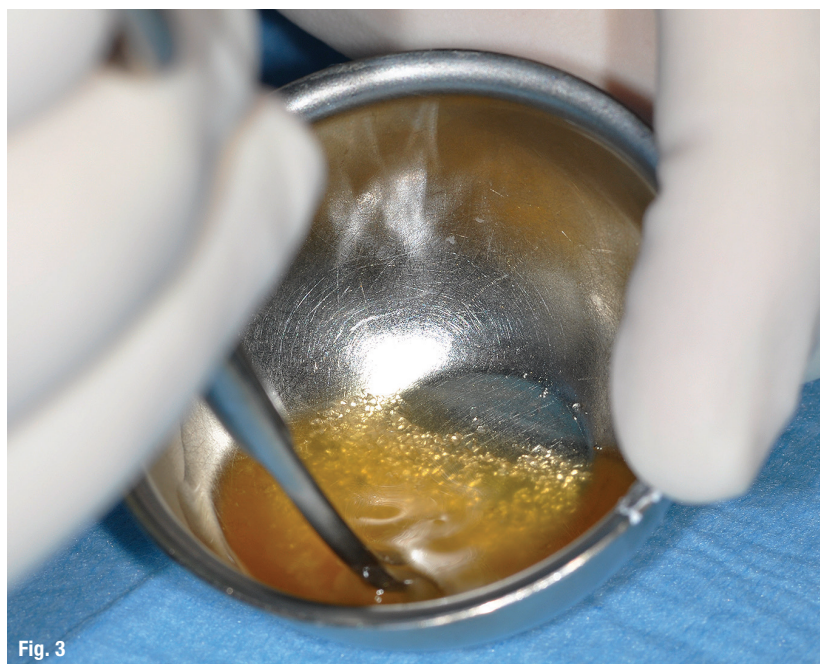


Fig. 3

**Fig. 3:** The serum from the pellet provides chemotactic factors, growth factors, stem cells and all of the immune cells which will contribute to and stimulate healing.

microsurgical cleaning protocol proposed here. It acts selectively on the various tissues of the periodontal pocket. There is in fact a water load gradient within the different tissues treated. The selective aspect of the Er:YAG laser lies in the fact that the beam will primarily eliminate the most hydrated tissue and will do so with micrometric precision. Thus, using the appropriate settings of the laser energy beam,<sup>21</sup> the inflammatory tissue and the biofilm will be destroyed while leaving the healthy and less hydrated tissue (gingiva, ligament, bone and dental structures) intact.

### Description of the Er:YAG laser-assisted microsurgical cleaning protocol

The Er:YAG laser is not a therapy on its own. It is a microsurgical tool used as a supplement to conventional instrumentation to optimise scaling and root planing in the cleaning of the deep periodontium.<sup>15</sup> Its use in this protocol allows a flapless surgical intervention. The protocol proposed here is based on the approach which Yukna already described in 1976.<sup>22</sup> The Er:YAG laser is used to descend layer by layer via tissue micro-ablation along the internal wall of the gingival pocket in order to selectively remove the inflammatory infiltrate. It uses the natural pathway created by the pathology. No healthy tissue is detached or removed. This process involves cleaning the wound under visual control through a space of about 1 mm throughout the full depth of the pocket and to the bone. Once the inflammatory tissue has been removed, visual access to the calculus is improved and it



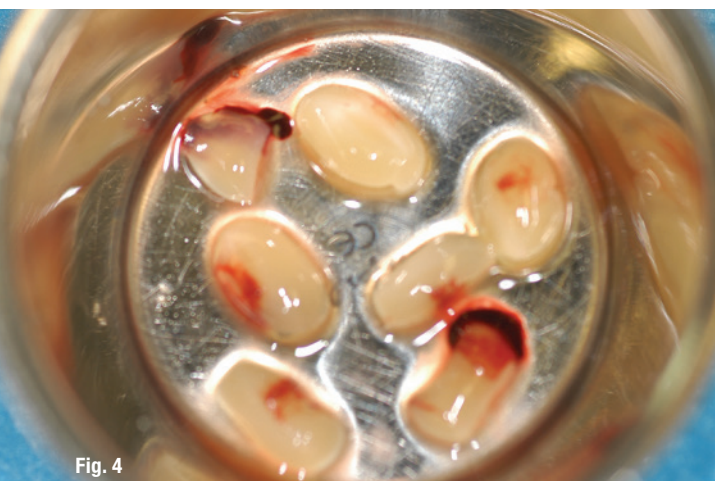

Fig. 4



Fig. 5

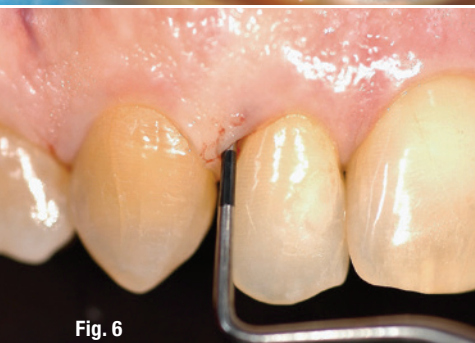

Fig. 6

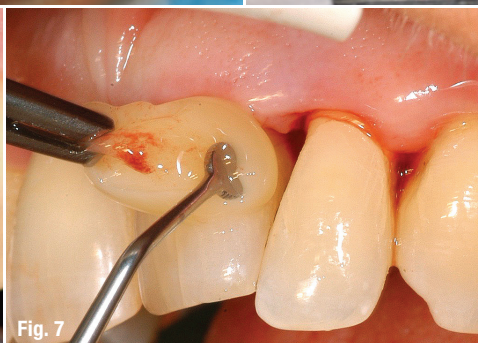

Fig. 7

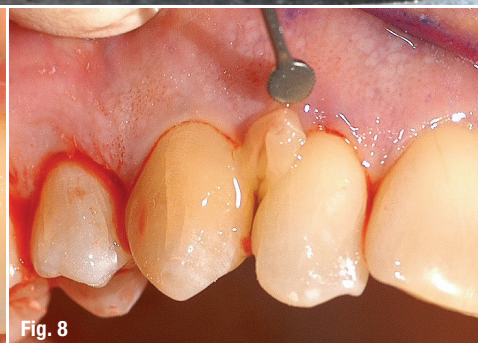

Fig. 8

**Figs. 4–8:** The plasma pellets are cut into pieces calibrated to the periodontal pockets to be filled. They will be compressed *in vivo*. Minimally invasive treatment of the periodontal pockets up to 8–9 mm and filling with autogenic plasma inserted into the space cleaned with the Er:YAG laser.

can be removed conventionally. The laser is once again used at the end of the protocol to decontaminate the root surface and flush the periodontal pocket. Komatsu clearly demonstrated that the Er:YAG laser, compared with the use of conventional curettes, allowed postoperative bacteraemia to be significantly reduced.<sup>23</sup> The bactericidal effects of the Er:YAG laser allow one to go further than conventional instrumentation in the cleaning of periodontal pockets.<sup>18</sup>

### PRF: Protection of the wound and stimulation of healing

Periodontal wounds cleaned according to the Er:YAG laser-assisted protocol will be protected by pellets of blood plasma. PRF will constitute a protective barrier for the periodontal pocket and stimulate its healing.<sup>24</sup> The collagen present in the PRF will serve as a matrix for the cellular bridging necessary for the tissue reconstruction

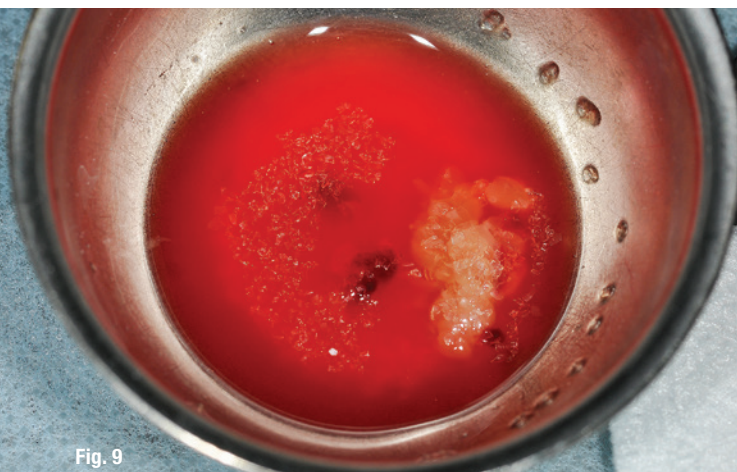

Fig. 9

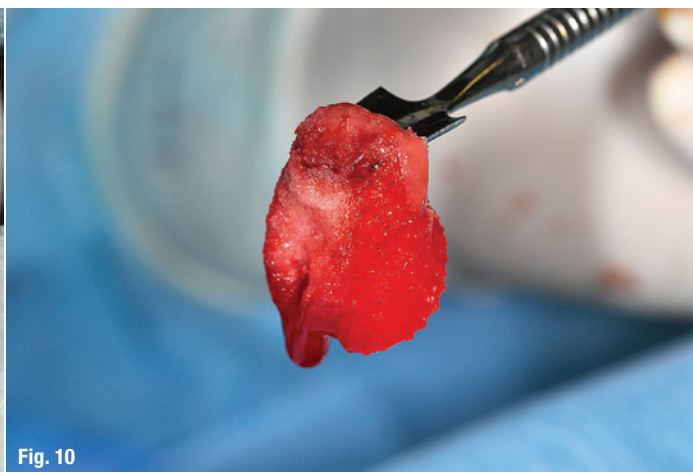

Fig. 10

**Figs. 9 & 10:** Mixture of PRF and bioglass; the coagulum formed is very ergonomic to handle.

process.<sup>25</sup> The plasma will also protect the wound from microbial invasion through closure, which it ensures, and the concentration of the immune cells it contains. The high platelet concentration in the PRF pellet will improve the coagulation mechanisms, thus contributing to the stabilisation of the blood clot, which is the first fundamental step in proper healing. The serum from the pellet will provide chemotactic factors, growth factors, stem cells and all of the immune cells which will contribute to and stimulate the healing process (Fig. 3).<sup>26,27</sup> PRF is used alone or added to a resorbable filling material after deep cleaning of the periodontal pockets. In the protocol proposed here, the plasma pellets are not compressed in a membrane *ex vivo*. They are cut and stored in a pellet to be calibrated to the space to be protected and are compressed *in vivo* in the periodontal pocket to fill it.

The recommendations are fairly specific: PRF is used alone in pockets measuring 3–5 mm and without any angular lesions (Figs. 4–8). PRF, in combination with filling material, is used in pockets greater than 6 mm, and in angular and crateriform lesions (Figs. 9–12). For cases involving filling, the material used is a bioglass, which demonstrates perfect adaptation to this type of protocol. This material, which is very ergonomic in its surgical handling, has the characteristic of being synthetic and resorbable, resorbing slowly to accompany the natural bone remodelling. When resorbed, it releases bacteriostatic components, thus limiting bacterial contamination. The material is mixed with whole plasma pellets (not compressed in a membrane) which are cut in a bowl. The mixture is packed into the pockets for filling, taking care to fill the entire space without excessive pressure on the material. Once filled, the pocket is protected at the surface by a pellet of plasma alone to ensure closure and cellular bridging at the surface.

Postoperatively, the patient is advised not to perform mouth washing to avoid destabilising the pellets and to allow the natural healing process to proceed. It is not necessary to administer significant amounts of antiseptics because the concentrated immune cells present in the plasma ensures the antimicrobial protection of the initial stages of healing. The tissue reconstruction which is going to take place will help create a protective barrier effect. In this protocol, patients are re-evaluated two months postoperatively (Fig. 13). At this stage, the disappearance of more than 80% of pockets measuring 4 mm or greater was noted. Healing continues for six to eight months.<sup>15</sup> It is accompanied by a programme of strict periodontal maintenance, which is often assisted by the Er:YAG laser, during which the residual pockets close up once again. In this minimally invasive approach, which allows pockets of up to 8–9 mm in depth to be treated, it is thus possible to reduce the need for an intervention with a surgical flap to access the deep periodontium to 2–3%.

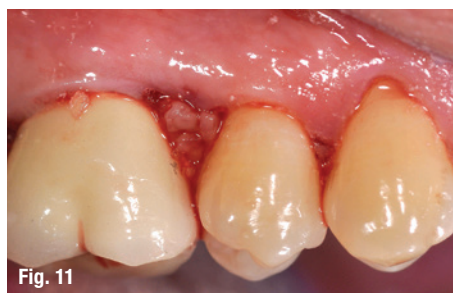

Fig. 11

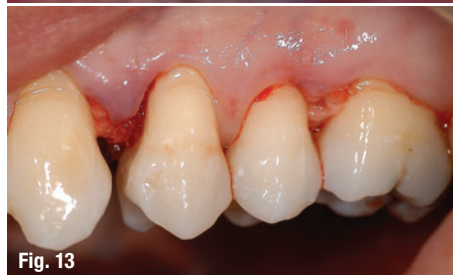

Fig. 13

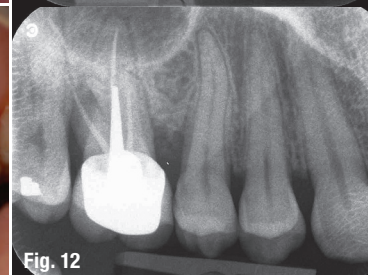
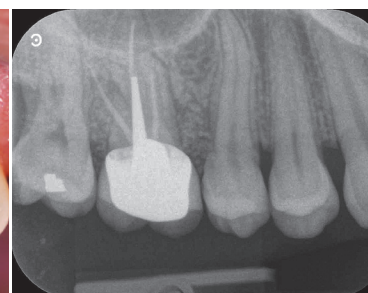

Fig. 12

**Figs. 11 & 12:** Clinical and radiographic views of a PRF–bioglass filling.  
**Fig. 13:** Immediate post-op clinical views of the small pellets inserted into the pockets.

## Conclusion

The synergy between the Er:YAG laser used with optical aids and the application of PRF for the treatment of the chronic inflammatory wounds which are the periodontal pockets is the result of technology and better knowledge regarding microbiology and tissue engineering. This progress allows us to push the boundaries imposed on us by conventional protocols. The operative protocol is simplified and optimised to be accessible to a greater number of therapists.

## about the author



**Dr Fabrice Baudot** is a French dentist specialised in periodontics and implantology. He currently leads a practice that is specialised in laser-assisted microsurgery. His therapeutic approach is always based on minimally invasive surgery. Dr Baudot is frequently invited to speak at international dental conferences, and he is the author of numerous scientific publications.

## contact

**Dr Fabrice Baudot**  
 Impasse des Trois Pointes 65  
 34980 Saint-Gély-du-Fesc, France  
 Phone: +33 4 99060060  
 dr.baudot34@orange.fr



Author details