


# implants

international magazine of oral implantology



## research

The dos and don'ts in the handling of PRF

## case report

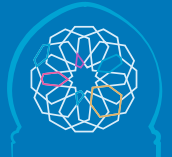Peri-implant bone regeneration  
through laser decontamination

## industry

The next generation biomaterial  
for soft-tissue augmentation



IT'S SIMPLE TO BE A  
**WINNER**



MIS GLOBAL  
CONFERENCE

May 14-17, 2020  
Marrakech  
Morocco



**PROVEN SUCCESS MEETS ENHANCED  
STABILITY. MAKE IT SIMPLE**

The biological stability and predictable esthetics of the SEVEN, combined with the extensive research and development process have given the SEVEN a potential advantage in soft tissue preservation and growth as well as an array of restorative benefits. Learn more about the SEVEN implant system and MIS at: [www.mis-implants.com](http://www.mis-implants.com)

MIS<sup>®</sup>  
**SEVEN<sup>®</sup>**



**Dr Rolf Vollmer**

First Vice President and Treasurer of DGZI



## Join **DGZI** on the track for success

With a 50-year history, the German Association of Dental Implantology (DGZI) represents a practice-oriented and evidence-based approach to implantology in Germany. DGZI always keeps pushing boundaries in this particularly innovative field of dentistry. We place an overarching focus on actively supporting our practising colleagues and dental technicians by offering a wide range of special training courses. I can proudly say that DGZI is one of the best internationally networked German expert societies for dental implantology, boasting more than registered 4,000 members in Germany alone and more than 13,000 cooperating members in 66 countries abroad. In addition, the annual meeting of DGZI is considered a definite highlight and it is fair to say that it has become an integral part of the annual schedules of numerous clinicians from all around the globe.

With more than 300 holders of the DGZI specialist in oral implantology certification, our expert society can recommend a vast number of highly qualified clinicians who continue to break the mould every single day in their dental practices. Thanks to our close ties to universities and research facilities we can implement the latest findings effortlessly into their daily practice. Fully recognised by the "Konsensuskonferenz Implantologie" (a joint initiative of German professional associations involved in dental implantology), the one-year DGZI implantology curriculum is the base for the practitioner. It features an innovative e-learning concept, which consists of regularly updated compulsory and optional modules, and is now offered in English too. The DGZI implantology curriculum is a state-of-the-art beacon of education for young aspiring dentists looking to delve deeply into the specialist field that is oral implantology.

In 2019 the American Board of Oral Implantology (ABOI) in the US decided to make the ABOI/ID Diplomate examination available for experienced dental practitioners internationally. The ABOI has an independent examination committee chartered by the American Academy of Implant Dentistry (AAID), the official US partner of DGZI. Now, especially graduates of the DGZI implantology curriculum, as well as holders of both Expert in Dental Implantology and DGZI Specialist in Oral Implantology certification can take this examination to become an ABOI/ID Diplomate in addition to the already gained credentials. DGZI can offer individual training and/or preparatory seminars for those wishing to pursue this prestigious certification on request.

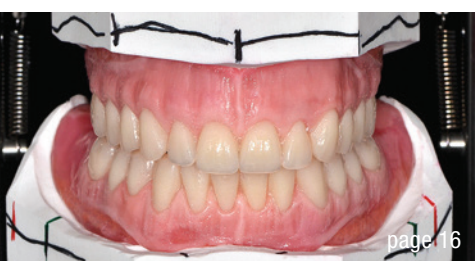Last but not least we should not forget our endeavours in publishing: The German language *Implantologie Journal* and the English language *implants—international magazine of oral implantology*. The former is DGZI's personal member journal and delivered to our German DGZI members, oral surgeons, prosthodontists and dental technicians on a monthly basis. The latter, with a circulation of 10,000 copies and four issues every year, is popular in over 90 countries around the world.

I wish you a great and interesting time reading this first 2020 issue of *implants—international magazine of oral implantology*.

Yours,

A handwritten signature in black ink, appearing to read 'Rolf Vollmer'.

Dr Rolf Vollmer



Cover image courtesy of  
TBR Dental Group  
[www.tbr.dental](http://www.tbr.dental)



## editorial

Join **DGZI** on the track for success 03  
Dr Rolf Vollmer

## research

The dos and don'ts in the handling of **PRF** 06  
Prof. Shahram Ghanaati, Dr Sarah Al-Maawi, Dr Eva Dohle & Dr Torsten S. Conrad

Success rate of dental implants in **heavy smokers** 12  
Drs Branislav Fatori & Inge Schmitz

## case report

Implant-retained **overdenture** on a very **thin** bone ridge 16  
Drs Nicola Alberto Valente, Murali Srinivasan & Nicole Kalberer

**Peri-implant** bone regeneration through **laser** decontamination 22  
Prof. Wilfried Engelke, Dr Christian Engelke, Dr Victor Beltrán & Dr Marcio Lazzarini

Sixteen years of **follow-up** after insertion of a Z1 implant 28  
Dr Virgilio Masini

## industry

The **next generation** biomaterial for soft-tissue augmentation 32

## practice management

Feedback done **right** 34  
Andrea Stix, MSc, MBA

## interview

**Reshaping** implantology 36

The **link** between oral disease and **oxidative stress** 38

## news

manufacturer news 40

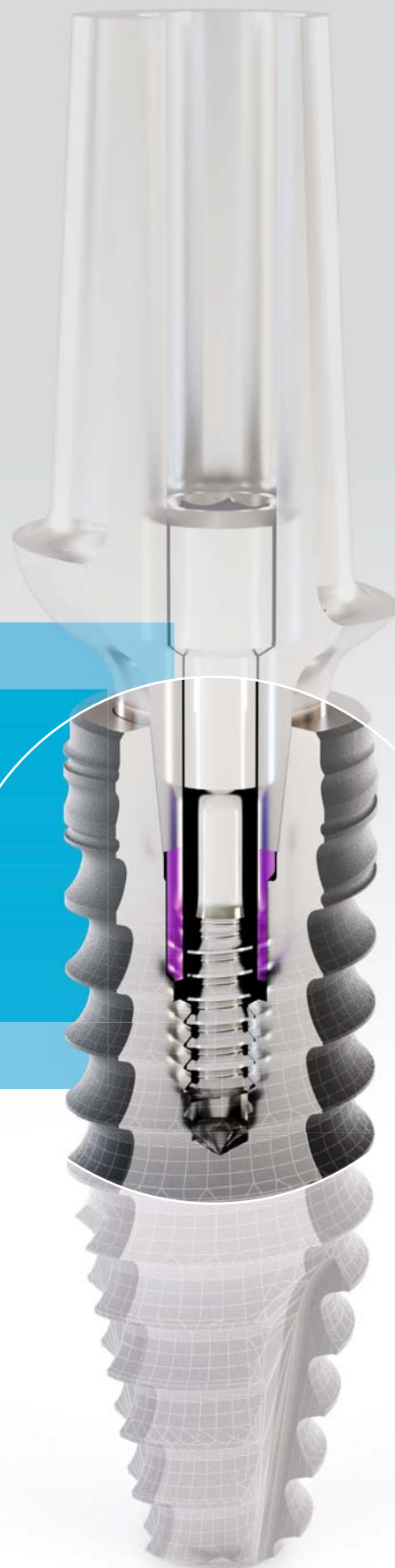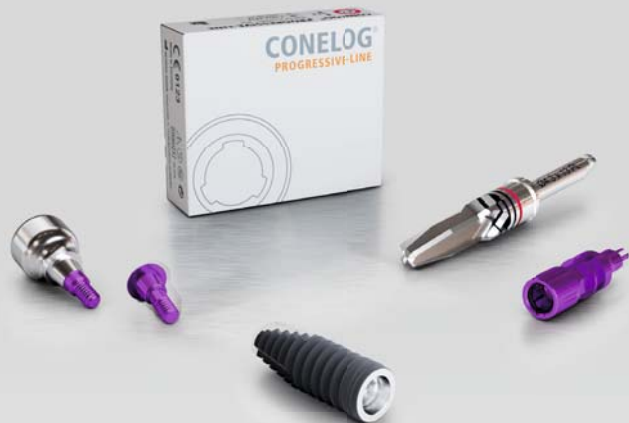news 44

## about the publisher

imprint 50

TRULY CONICAL PRECISION

**CONOLOG<sup>®</sup>**  
SYSTEM



## CONOLOG<sup>®</sup> PROGRESSIVE-LINE conical performance<sup>1,2</sup> at bone level

### Precise conical connection

- long conus for reduced micromovements
- superior positional stability in comparison to other conical systems<sup>1,2</sup>
- easy positioning with excellent tactile feedback
- integrated platform switching supporting the preservation of crestal bone

[1] Semper-Hogg, W, Kraft, S, Stiller, S et al. Analytical and experimental position stability of the abutment in different dental implant systems with a conical implant-abutment connection Clin Oral Invest (2013) 17: 1017

[2] Semper Hogg W, Zulauf K, Mehrhof J, Nelson K. The influence of torque tightening on the position stability of the abutment in conical implant-abutment connections. Int J Prosthodont 2015;28:538-41

# The dos and don'ts in the handling of PRF

Prof. Shahram Ghanaati, Dr Sarah Al-Maawi, Dr Eva Dohle & Dr Torsten S. Conrad, Germany

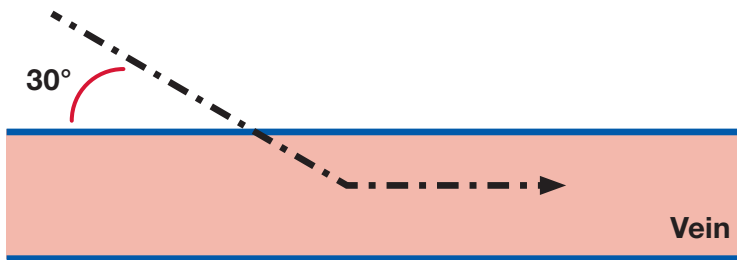


Fig. 1: Visualisation of the puncture direction during blood collection.

**Autologous blood concentrates**, and platelet-rich fibrin (PRF) in particular, are increasingly used today to support wound healing and regenerative processes.<sup>1</sup> PRF is made from the patient's own peripheral blood without the addition of anticoagulants. A solid or liquid PRF matrix can be obtained through a single centrifugation process, depending on the collection tube that is used.<sup>2</sup> Through this centrifugation process, the blood components are separated according to the centrifugal force used. The red blood cells move towards the bottom of the tube.<sup>3</sup> The platelets and leucocytes are concentrated in the upper layer, the remaining fibrin matrix. Thus, this autologous blood concentrate, which also contains further plasma proteins, is capable of actively releasing different growth factors such as vascular endothelial growth factors (VEGF), epidermal growth factors (EGF), or platelet-derived growth factors (PDGF) over a relatively long period of time (up to fifteen days).<sup>4,5</sup> These growth factors play a key role in the support of wound healing and regenerative processes, since they contribute to the formation of new vessels, epithelialisation and the stimulation of further regener-

ative cells.<sup>6,7</sup> The composition and bioactivity of PRF depends primarily on the centrifugal force that is used during centrifugation.<sup>3</sup>

Several recent studies have demonstrated the influence of the centrifugal force on the composition and bioactivity of the obtained PRF.<sup>8-12</sup> It has been shown that the application of a low centrifugal force for accumulation leads to a significantly higher number of platelets and leukocytes in PRF compared to a medium or high centrifugal force.<sup>3,10</sup> Growth factors are released in a similar way. PRF matrices that are prepared with a low centrifugal force release significantly higher concentrations of different growth factors (such as VEGF, PDGF, EGF, TGF- $\beta$ 1) compared to PRF matrices that are prepared using a higher centrifugal force.<sup>8-12</sup> As a result, the so-called Low-Speed Centrifugation Concept (LSCC) was introduced, which aims at standardising the production of blood concentrates and enabling reproducible treatment protocols or clinical results.<sup>3</sup> This article will particularly focus on the technical aspects of the clinical application and handling of PRF. The tubes used for the production of PRF have been specifically developed for this particular purpose. Depending on the clinical indication, two different variants of PRF matrices exist. PRF tubes with a glass surface promote coagulation. During centrifugation, a solid PRF matrix is formed. In contrast, the coagulation process can be slowed down by means of plastic-coated tubes. Accordingly, coagulation is slowed down during centrifugation. At room temperature, a PRF matrix remains liquid for about thirty minutes after centrifugation until it eventually coagulates.

| Protocol                 | RPM (x 100) | Duration (min) | Centrifugal force (x G) |
|--------------------------|-------------|----------------|-------------------------|
| High concentration RCF   | 2,400       | 8              | 710                     |
| Medium concentration RCF | 1,200       | 8              | 177                     |
| Low concentration RCF    | 600         | 8              | 44                      |

RCF, relative centrifugal force; RPM, revolutions of the centrifuge per minute.

Table 1: Visualisation of the different LSCC protocols (Low-Speed Centrifugation Concept for a centrifuge with a radius of 110 mm).


## Blood collection

For the production of PRF the patient's own venous blood is required, which is taken from the peripheral veins after the patient has been fully briefed on the procedure. This blood collection is a routine method and is particularly used in diagnostics. The blood collection should be carried out according to the guidelines of the World Health Organization (WHO).<sup>13</sup> In order to find a suitable puncture site, the anatomical position of the peripheral veins should first be palpated. For this purpose, the vena mediana cubiti, which is located in the antecubital fossa (inner bend of the elbow), is ideally suited. Gloves must be worn and the tourniquet must be placed approximately 5 cm above the puncture site of the vein, which must be disinfected with a skin antiseptic according to the manufacturer's instructions. A butterfly needle is then inserted into the vein at an angle of 30° to the skin surface (Fig. 1). To avoid completely piercing through the vein, the angle should be

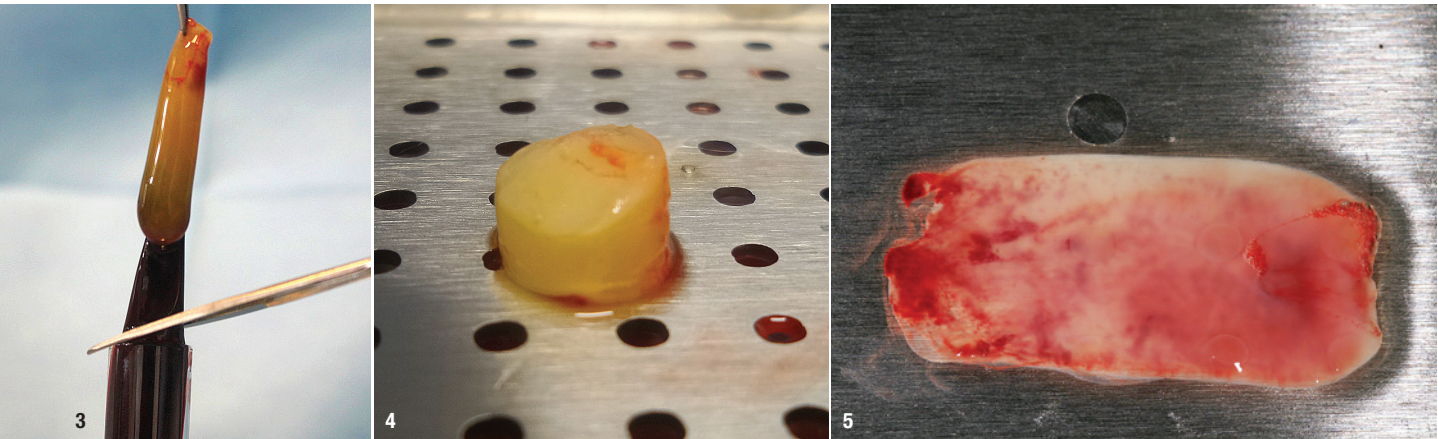
flattened once the vein has been hit. The vacuum system of the PRF tube then fills the tube with venous blood until an amount of 10 ml is reached and the blood supply can be stopped automatically. After loosening the tourniquet tube, the butterfly cannula can be removed. Subsequently, sufficient pressure should be exerted on the puncture site with a sterile swab in order to avoid secondary bleeding underneath the skin.

## Centrifugation

In order to avoid early physiological coagulation of the blood, the PRF tubes must be centrifuged quickly after blood collection in a dedicated centrifuge that stands on a table nearby in the same treatment room. Through centrifugation, a separation process is triggered, which sediments cells and/or biomolecules from a suspension (i.e. blood), depending on the relative centrifugal force and the size, shape and density of the vari-



**Fig. 2:** Balance pattern of the centrifuge when loading two, three, four and six tubes. Centrifugation of five, seven, nine or eleven tubes is not possible. For this purpose, an additional tube filled with water must be used.



**Fig. 3:** Separating the red phase from the solid PRF phase. **Fig. 4:** A PRF plug. **Fig. 5:** A thinly pressed PRF matrix.

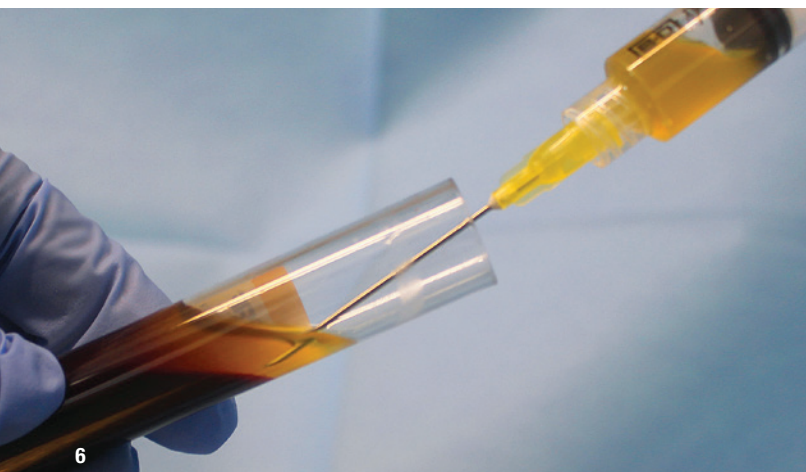
ous suspension components. The relative centrifugal force (RCF) represents the centrifugal force as a multiple of the Earth's gravity and is often expressed as the value G. Moreover, it is a decisive factor for the resulting concentration of the sedimented cells and biomolecules in PRF. The value G indicates exactly the force required for an optimal centrifugation of a corresponding suspension (in this case blood) to obtain the desired sediment (in this case PRF) as final product, and allows the calculation of the necessary speed of the centrifuge rotor for a corresponding tube and centrifuge.

For centrifuges where only the rotational speed (revolutions of the centrifuge per minute, RPM) can be set, the RCF or the necessary G-value must first be calculated by means of a fixed formula. The relation between rotational speed (RPM) and RCF depends on the size of the rotor ( $r$  = radius of rotation = distance between the axis of rotation and the bottom of the tube). Here, the following formula is used for conversion:<sup>14</sup>  $RCF = 1.12 \times \text{radius} \times (\text{RPM}/1,000)^2$ . The relative centrifugal force required for PRF production using the established LSCC

is given in Table 1 and should be set on the centrifuge according to the clinical indication ( $r = 110\text{mm}$ ). In general, the centrifuge should be placed on a stable and even fundament. When loading the centrifuge with the blood-filled tubes, it is imperative to ensure that any imbalance is eliminated. This means that the tubes must be placed inside of the rotor in such a way that the weight of the tube placed exactly opposite the other is identical (Fig. 2). If the number of tubes is uneven, a tube filled with the equivalent volume (such as sodium chloride, for example) must be added to compensate for the weight.

### Processing of PRF

Immediately after centrifugation, the tubes are carefully removed from the centrifuge and transferred to an appropriate tube holder. Owing to the applied RCF and depending on the size, shape and density of the blood components, only two phases can now be visually identified: a red phase at the bottom of the tube, which contains mainly erythrocytes and a PRF phase on top of it, filling up the upper part of the tube. In the case of solid PRF, which is obtained by centrifuging the blood in the red PRF tubes, these two phases coagulate very quickly. In order to separate the solid PRF matrix from the red lower phase, it is recommended to first separate the two phases roughly by cutting them with scissors. In concrete terms, this means carefully lifting up the upper phase of solid PRF with sterile tweezers (the lower red phase is lifted as well) and then roughly separate the two phases in the upper part of the red phase (Fig. 3). The PRF phase (with remains of the red phase) is then transferred into a dedicated PRF box provided for this particular purpose. This PRF box, which has been specially developed for various PRF indications, consists of a stainless-steel container with a self-weighted lid and a large and small stamp. In this box, the remaining parts of the red phase can now be removed from the PRF phase by carefully wiping it off with a blunt object (such as a closed pair of scissors). Thereafter, solid PRF matrices can be further



**Fig. 6:** Separating liquid PRF from the red phase by means of a syringe.



Conical? Parallel?

# *copa*SKY!

The unique hybrid connection for sophisticated restorations!

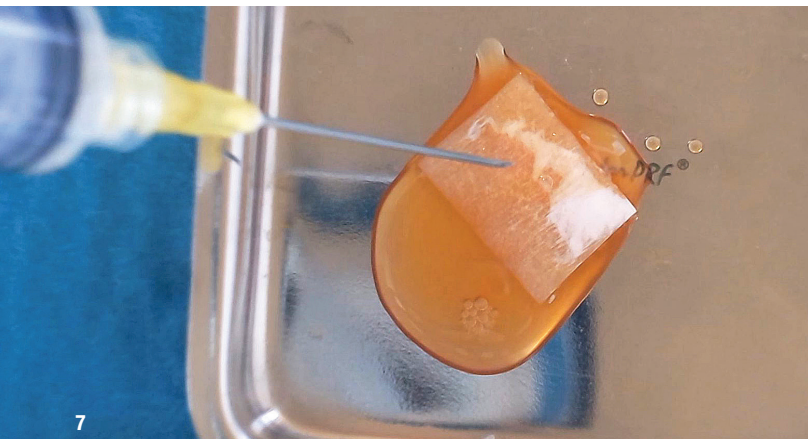


Photo: © Getty Images

Leading in Immediate Restoration – powered by physiological Prosthetic!

DENTAL INNOVATIONS  
SINCE 1974

bredent  
group



**Fig. 7:** Biologising a collagen-based matrix with liquid PRF.


processed either into a PRF plug (Fig. 4) or into a thinly pressed PRF matrix (Fig. 5), depending on the clinical indication. For PRF application in the extraction sockets of wisdom teeth, the fibrin clot is placed in the containers in the box, which are specifically provided for this very indication, and carefully compressed with the small stamp until the appropriate size of the PRF plug is reached.

In order to process PRF into a thinly pressed matrix, the fibrin clot is carefully placed on the grid of the PRF box and processed into a pressed PRF matrix using the self-weighted lid of the PRF box. This pressed PRF matrix can then, for example, be placed as a wound cover on the surgical sites where autologous palatal soft-tissue transplants have been removed to support the wound healing process. In addition, it can be used during implant surgeries as a support of the mucosal flap. As opposed to the earlier-described solid PRF, which is produced through centrifugation in glass tubes, the two phases of the blood remain liquid at first for a few minutes if centrifugation is done with plastic tubes. The production of liquid PRF opens up the possibility of further PRF applications in the field of regenerative medicine, such as the combination of PRF with bone grafting materials and collagen membranes. The upper, still liquid PRF phase is carefully removed from the remaining lower red phase using a syringe. A 5 ml syringe with a long and wide 21-gauge cannula is best suited for this purpose (Fig. 6). It is recommended that the tube is slightly tilted so that the boundary between the two phases can be seen more easily. In this way as much liquid PRF as possible can be extracted from the tube, without extracting too much of the red phase. With a liquid matrix, the wetting of the biomaterial surface can be carried out in a reproducible fashion. In contrast, based on the preliminary results of the ongoing clinical studies, it is no longer recommended to cut up a solid PRF matrix and mix the obtained pieces with bone grafting material in order to create so-called sticky bone. Current research findings indicate that this can lead to a loss of volume, since the fibrin is resorbed

after 10 to 15 days, facilitating the formation of cavities in the augmentation sites as a result.

In order to biologise biomaterials of different classes and origin, such as bone grafting materials and collagen-based membranes (allogeneic, xenogeneic, synthetic), they can be combined with solid or liquid PRF. Here, biomaterials that do not trigger a foreign body reaction should ideally be used. With the help of PRF it is possible to biologise or functionalise these biomaterials, since they themselves do not have any bioactive components, but serve only as a mere scaffold. The functionalisation of biomaterials with endogenous cells, plasma and growth factors that are found in great concentration in PRF should lead to an improved integration of the biomaterial in certain defects and, as a consequence, to an increased regenerative capacity. When combining PRF with bone grafting material and collagen-based membranes, PRF in liquid form should be used. In order to biologise and stabilise these bone grafting materials or membranes, liquid PRF collected in the syringe is drizzled onto them, which also simplifies clinical handling (Fig. 7).

*A comprehensive list of references can be obtained from the authors.*



## about the author



Frankfurt am Main-based **Prof. Shahram Ghanaati** is a specialist in maxillofacial surgery and oncology. In 2013, he was appointed Director of the University Cancer Center of the Frankfurt University Hospital. He is the Senior Physician and Deputy Director of the Department of Oral and Maxillofacial Plastic Surgery of the Frankfurt University Hospital. In

addition, he is the Director of the research laboratory FORM-Lab (Frankfurt Orofacial Regenerative Medicine).


## contact

**Prof. Shahram Ghanaati**  
Universitätsklinikum Frankfurt  
Theodor-Stern-Kai 7  
60590 Frankfurt am Main, Germany  
Phone: +49 69 6301-3744  
shahram.ghanaati@kgu.de





# The unique Tissue Level Implant with Zirconia Collar



Aesthetic gingival area

Zirconia collar

Gingival integration & Osseointegration

Bone area

Pure Titanium body

## Z1<sup>®</sup> Implant

Giving you confidence in implantology.

### Proven Technology

- ✓ 98.6%\* success rate
- ✓ Pure Titanium and Y-TZP Zirconia
- ✓ Suitable for all prosthetic solutions

### Proven clinical outcomes for patient safety

- ✓ Anti-bacterial shield
- ✓ Ideal in fresh extraction sockets
- ✓ Immediate aesthetic result

### Proven economics for a profitable implant practice

- ✓ Reduced chairtime
- ✓ Practice development
- ✓ Patient satisfaction

### Proven surgical protocols for a simplified workflow

- ✓ Only 1 surgery
- ✓ No healing abutment
- ✓ Visibility of the connection



Find us online  
[www.tbr.dental](http://www.tbr.dental)

 **TBR**<sup>®</sup>  
Unique, like your smile

# Success rate of dental implants in heavy smokers

## A longitudinal study

Drs Branislav Fatori & Inge Schmitz, Germany

### Objective

The failure rate of dental implants is reported to be higher in smokers than in non-smokers. The aim of the study described in this article was to compare the success rate of 721 dental implants inserted in 181 smokers with given reports in the literature. In our study, implants from one factory were used and the implants were inserted by one surgeon to exclude individual factors. In order to increase the success rate for dental implants inserted in

smokers, a specific protocol was established in our dental surgery. In the following, the results of two patients are reported in detail.

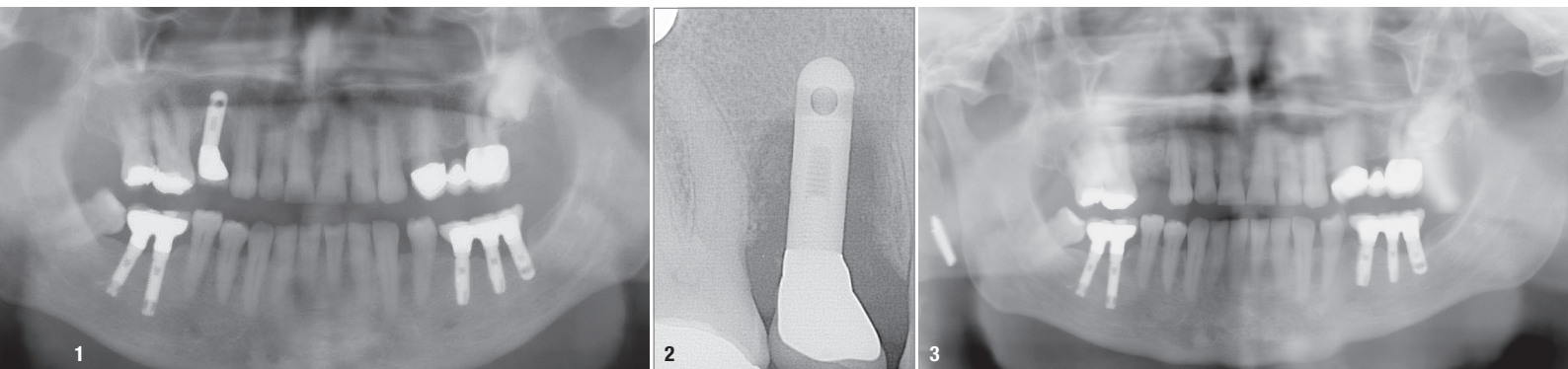
### Introduction

In general, smoking is reported to increase implant failure and favour peri-implantitis. One possible mechanism that might lead to increased failure rates is a lowering of the blood flow and direct adverse effects on the osteoblasts. If smokers are treated with implants, good bone quality is required. In our study, bone augmentation procedures were necessary in 62 of the cases.

With our study, we set out to investigate whether there is a significantly enhanced risk of implant failure due to the increased number of cigarettes smoked per day. Though smoking is a risk factor for implant failure, it is not considered an absolute contra-indication. When implant treatment is planned, the patient's smoking history should first be obtained, including the duration, the intensity (past and present), the present status of smoking, the number of cigarettes smoked each day and whether there is any notable passive smoking. Here, the surgeon has to rely completely on the correctness of the information provided by the patient. To achieve a satisfactory result regarding implant survival, a number of different

| Diameter (mm) | Length (mm) | No.        | Successful | Failed    |
|---------------|-------------|------------|------------|-----------|
| 3.70          | 8.00        | 4          | 4          | 0         |
| 3.75          | 10.00       | 182        | 167        | 15        |
| 3.75          | 12.00       | 200        | 182        | 18        |
| 3.75          | 14.00       | 1          | 1          | 0         |
| 3.30          | 12.00       | 38         | 35         | 3         |
| 4.10          | 8.00        | 2          | 2          | 0         |
| 4.10          | 10.00       | 101        | 88         | 13        |
| 4.10          | 12.00       | 193        | 177        | 16        |
| <b>Total</b>  |             | <b>721</b> | <b>656</b> | <b>65</b> |

Table 1a



Case 1—Fig. 1: The 54-year-old female patient had an extreme periodontal defect at tooth #44 with bone loss at the apical side. Fig. 2: Radiographic close-up. Fig. 3: Final result.

| Jaw   | Regions | No. |
|-------|---------|-----|
| Upper | 17–14   | 48  |
|       | 13–11   | 149 |
|       | 21–23   | 151 |
|       | 24–27   | 64  |
| Lower | 47–44   | 150 |
|       | 43–41   | 9   |
|       | 31–33   | 9   |
|       | 34–37   | 141 |

Table 1b

factors have to be taken into consideration, such as bone type and quality, bone density, placement and location of the inserted implants (Tables 1a & b), the patient's personal situation, health risks and unrelated diseases, such as diabetes.<sup>1</sup>

### On smoking

Smoking tobacco reduces leucocyte activity. It has an influence on blood vessels and reduces the body's healing capacity and osseointegration of dental implants. Smoking has a direct influence on osteoblastic function.<sup>2</sup> The exact mechanism by which smoking compromises wound healing is still unknown. Smoking enhances the risk for ingress of bacteria which may cause peri-implantitis. It is hypothesised that nicotine and chemicals contained in tobacco smoke induce a state of oxidative stress in the tissue (gingiva and alveolar bone) around implants.<sup>3,4</sup> Abstinence from smoking should be extended to at least eight weeks after

the implantation in order to promote osseointegration.

### Materials and methods

We assessed 181 patients (97 women and 121 men with an average age of 49.2 years) with 721 implants. In detail, 384 bone-level implants, 289 bone-level tapered implants and 48 tissue-level implants were inserted (Table 2). The implants were classified according to their location in the upper and lower jaws. As for the smoking history of the patients, the number of cigarettes smoked per day ranged from 20 to 60 cigarettes.

### Surgical technique

Implant placement was performed under local anaesthesia (40mg of Dexamethasone, intramuscular; ratiopharm) after premedication with antibiotics. The osteotomy was extended gradually according to the intended implant diameter. After carrying out the incision, the oral cavity was cleaned and necrotic or inflammatory tissue was removed. The osteotomy sites were prepared with a sequential order of drills, as recommended by the manufacturer. Implants were inserted in the prepared osteotomy sites at an insertion torque of 45 Ncm.

### Postoperative treatment

Postoperative periapical radiographs were taken, which confirmed the accuracy of the implant placement. Postoperative medication included antibiotics. Digital radiographic images were taken



## Shortest Implants – Longest History.

## Think Short!

For more than 30 years Bicon® short implants are unchanged in clinical use.

According to the 11<sup>th</sup> European Consensus Conference (EuCC) 2016 in Cologne, provided the specific treatment parameters are observed, the use of short, angulated or diameter-reduced implants in sites with reduced bone volume can be a reliable treatment option, given the risks associated with the use of standard-dimension implants in combination with augmentation procedures.

For more Information:

**Bicon Europe Ltd.**

Dietrichshoehe 2

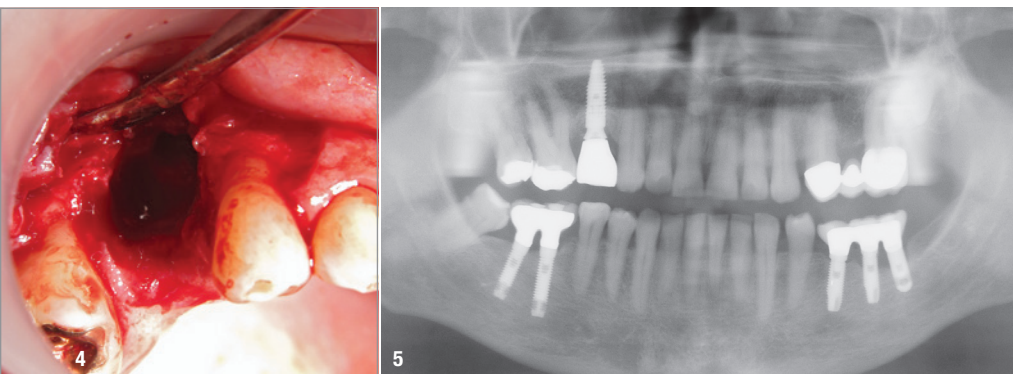
55491 Buechenbeuren

Germany

Phone +49 (0)6543 818200

germany@bicon.com

[www.bicon.de.com](http://www.bicon.de.com)



**Case 2—Fig. 4:** Defect situation after explantation and guided bone regeneration in a 67-year-old male patient who smoked 42 cigarettes per day and suffered bone loss 27 years after implantation. **Fig. 5:** Implant with a new crown.



**bicon**  
DENTAL IMPLANTS

| Type                  | Diameter (mm) | Length (mm) | No. |
|-----------------------|---------------|-------------|-----|
| Bone-level            | 3.30          | 8           | 0   |
|                       | 3.30          | 10          | 0   |
|                       | 3.30          | 12          | 47  |
|                       | 3.75          | 8           | 9   |
|                       | 3.75          | 10          | 43  |
|                       | 3.75          | 12          | 62  |
|                       | 4.10          | 8           | 18  |
|                       | 4.10          | 10          | 94  |
|                       | 4.10          | 12          | 92  |
|                       | 4.10          | 14          | 7   |
|                       | 4.80          | 8           | 4   |
|                       | 4.80          | 10          | 4   |
|                       | 4.80          | 12          | 4   |
| Bone-level tapered    | 3.30          | 8           | 0   |
|                       | 3.30          | 10          | 0   |
|                       | 3.30          | 12          | 29  |
|                       | 3.75          | 8           | 4   |
|                       | 3.75          | 10          | 48  |
|                       | 3.75          | 12          | 97  |
|                       | 4.10          | 8           | 19  |
|                       | 4.10          | 10          | 39  |
|                       | 4.10          | 12          | 50  |
|                       | 4.10          | 14          | 3   |
|                       | 4.80          | 8           | 0   |
|                       | 4.80          | 10          | 0   |
|                       | 4.80          | 12          | 0   |
| Tissue-level          | 3.30          | 8           | 0   |
|                       | 3.30          | 10          | 0   |
|                       | 3.30          | 12          | 6   |
|                       | 3.75          | 8           | 0   |
|                       | 3.75          | 10          | 0   |
|                       | 3.75          | 12          | 0   |
|                       | 4.10          | 8           | 8   |
|                       | 4.10          | 10          | 9   |
|                       | 4.10          | 12          | 22  |
|                       | 4.10          | 14          | 0   |
|                       | 4.80          | 8           | 0   |
|                       | 4.80          | 10          | 0   |
|                       | 4.80          | 12          | 0   |
| Tissue-level ROX-CERA | 3.30          | 8           | 0   |
|                       | 3.30          | 10          | 0   |
|                       | 3.30          | 12          | 0   |
|                       | 4.10          | 8           | 0   |
|                       | 4.10          | 10          | 1   |
|                       | 4.10          | 12          | 0   |
| Tissue-level WP       | 4.80          | 8           | 0   |
|                       | 4.80          | 10          | 0   |
|                       | 4.80          | 12          | 2   |

Table 2

at the time of surgery, after 24 hours and one month later in order to evaluate the success of the implant treatment. Inflammatory processes were found in 24.1% of the patients. If necessary, augmentation was done by means of NanoBone (Artoss), Geistlich Bio-Oss bone substitute and Geistlich Bio-Gide membranes (both Geistlich Biomaterials).

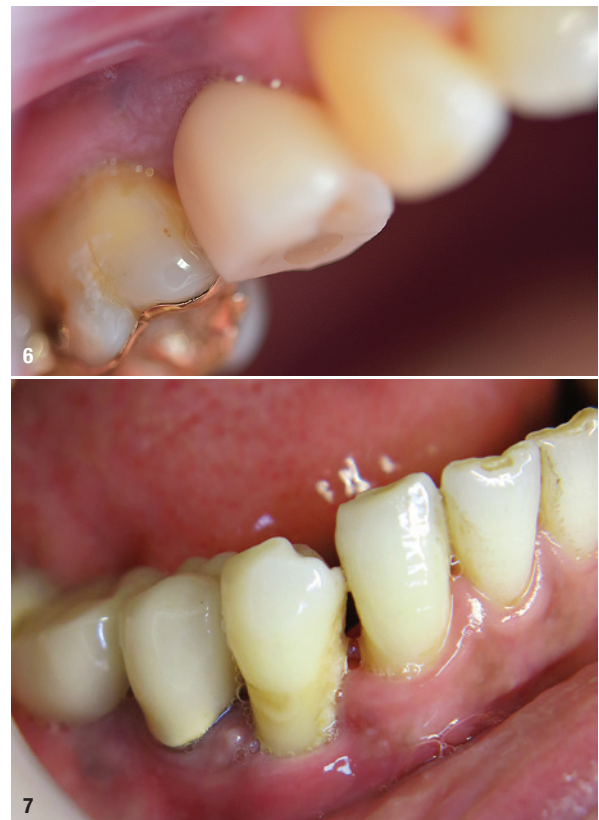### Indication for implants

The indications for inserting implants in our study were as follows:

- treatment of the edentulous jaw;
- single-tooth replacement;
- treatment of larger interdental gaps; and
- free-end situation.

### Results

Of the 721 implants inserted, 65 implants failed. Conclusively, the success rate was at 90.98%, which is lower compared with our previous study on non-smokers, in which the success rate was 98.70%.<sup>2</sup> In the group of failed implants, most of them (75.4%) were lost two to four weeks after implant placement owing to a lack of osseointegration. Peri-implantitis occurred in 20% of the failed implants. This could be traced back to poor oral health and plaque formation. In 4.6% of the cases,



Case 2—Fig. 6: Cemented crown *in situ*. Fig. 7: Final result.

peri-implantitis occurred between one and three years after implant placement owing to mechanical issues after bone loss. There was no correlation to be found between implant length and diameter and the implant failure rate, and neither did we find a correlation between the number of cigarettes smoked and the implant failure rate.

## Discussion

As established earlier, the failure rate of dental implants in smokers is higher than in non-smokers, which is due to lack of early osseointegration and the occurrence of peri-implantitis. Peri-implantitis was obvious in 62 cases included in our study. Failed osseointegration was the main reason for implant failure. However, in conclusion, it must be stated that the results we obtained were excellent.

Dental implant therapy is a treatment of choice for treating patients with missing teeth. However, certain conditions, such as smoking, hypertension and diabetes, have a negative influence on the success of dental implants. Nicotine is found to cause osteoclastic changes. Based on the cases described here and the results in other patients, it can be concluded that today good results can be obtained in heavy smokers. It is difficult to evaluate the role of a single risk factor such as smoking regarding positive treatment outcomes of dental implants, since many patients have additional co-risk factors, including diabetes, advanced age or low bone density. In addition, there is great variance in smoking behaviour regarding the actual number of cigarettes smoked per day and the years for which a patient has been smoking. Furthermore, the location of implants, placed in either the maxilla or the mandible, may have an influence on osseointegration success. Marginal bone loss around implants placed in smokers is more pronounced in the maxilla. Implant failure may vary with implant location in connection to the quality and quantity of the alveolar bone in which the implant is placed. The alveolar bone varies in terms of mineral density, microarchitecture and trabecular bone thickness.

In the relevant literature, it is reported that smoking of more than 30 cigarettes per day and for a duration of longer than ten years promotes implant failure. There is little data available, however, on passive smoking and ex-smokers in this regard.

## Summary and outlook

The risk of implant failure increases with increasing number of cigarettes smoked per day. We found a correlation between heavy smoking and implant loss. Smoking influences the survival rate of dental implants. Thus, patients should be educated thoroughly and be advised to discontinue the habit before implant placement can be carried out.

*Conflict of interest: Dr Inge Schmitz declares that she has no conflict of interest.*

*Acknowledgement: Dr Branislav Fatori would like to express his gratitude to DENTAL RATIO, and to Ulf Henschel in particular, for the technical support and the donation of implants. In addition, he would like to thank Dr Walter Gerike from Artoss in Rostock, Germany, for his long-standing support.*


All images: © Branislav Fatori



## about the authors



**Dr Branislav Fatori** has more than 41 years of experience in implantology and has placed more than 8,000 implants. He was trained at prominent clinics in Germany, the US, Sweden, Serbia and Switzerland. In addition, he has worked as a long-term training consultant for professional societies and implant manufacturers.



**Dr Inge Schmitz** has worked at the Institute of Pathology of the Ruhr-University Bochum in Germany since 1990. Her main interests are implant dentistry, stents, electron microscopy and osteology. She studied biology at the Ruhr-University Bochum and completed her PhD in anatomy at the University of Essen in Germany in 1989.

## contact

### Dr Branislav Fatori

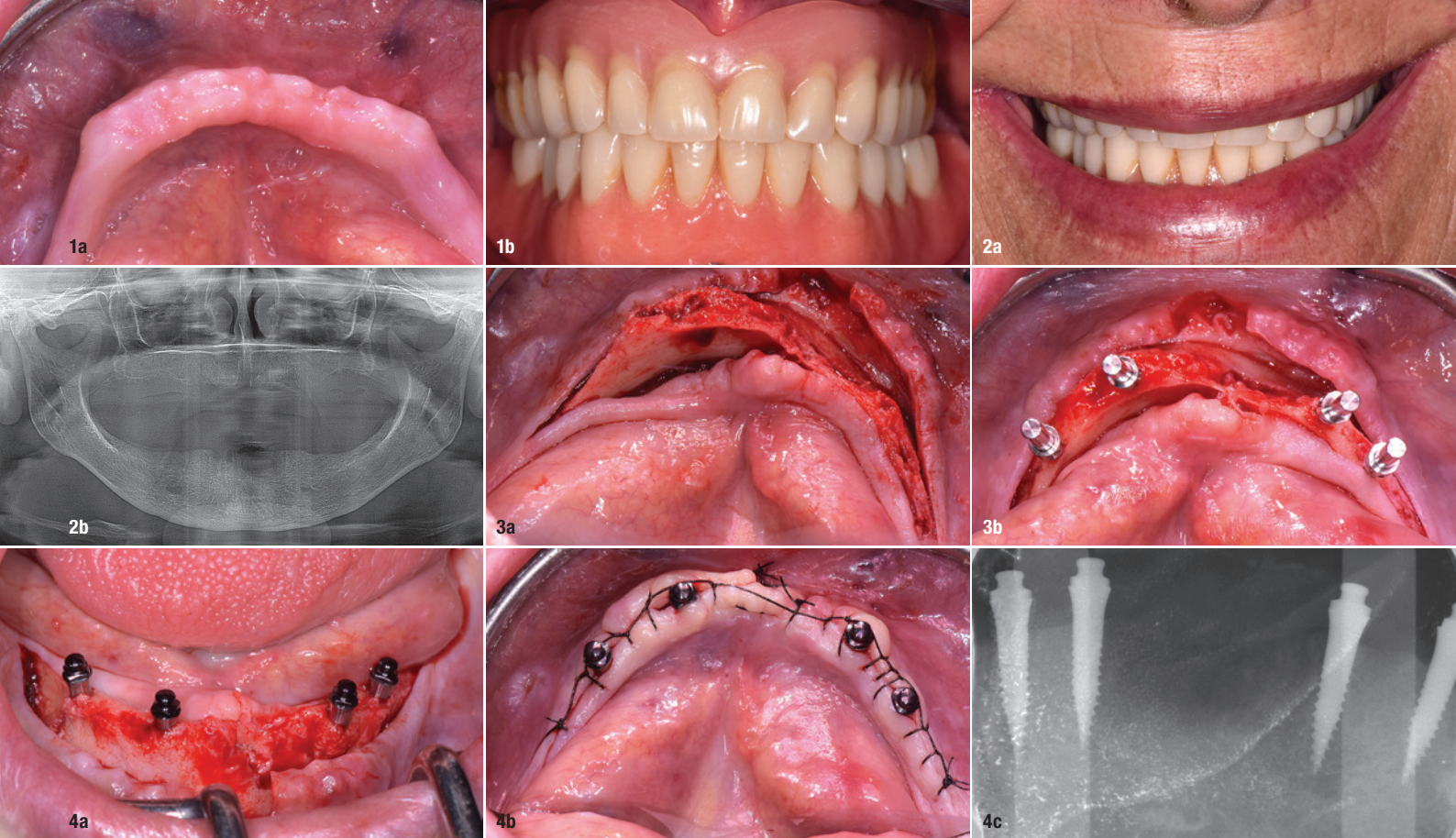
Rolandstraße 11  
45128 Essen, Germany  
Phone: +49 201 82188890  
info@fatori.de



### Dr Inge Schmitz

Georgius Agricola Stiftung Ruhr  
Institut für Pathologie  
Ruhr-Universität Bochum  
Bürkle-de-la-Camp-Platz 1  
44789 Bochum, Germany  
inge.schmitz@rub.de





**Fig. 1a:** Occlusal view before the treatment showing a very thin ridge. **Fig. 1b:** Frontal view of the ill-fitting mandibular denture. **Fig. 2a:** Frontal view of the initial clinical situation. **Fig. 2b:** Preoperative radiograph. **Fig. 3a:** A flap was raised to obtain a clear view of the underlying bone. **Fig. 3b:** Preparation of the four implant sites. **Fig. 4a:** Placement of the four implants. **Fig. 4b:** The flap was closed with a 4/0 polyamide continuous suture. **Fig. 4c:** Radiograph taken immediately after surgery.

# Implant-retained overdenture on a very thin bone ridge

Drs Nicola Alberto Valente, Murali Srinivasan & Nicole Kalberer, Switzerland

## Initial situation

A healthy 60-year-old female patient with no medical history presented at our clinic with a non-fitting full mandibular denture. Her chief complaints at this point included the lack of retention of her mandibular denture and poor aesthetics, coupled with difficulty in chewing and embarrassment at social events. The treatment plan comprised the rehabilitation of jaw function and aesthetics with a new set of dentures, including a conventional maxillary complete denture (CD) and a mandibular implant-supported overdenture (IOD) retained by four implants. For standard implants, the ridge would have had to be reduced by a vertical osteotomy in order to gain thickness and to reach the wider portion of basal bone. However, this would cause both a loss of height and a reduction

in vestibule depth, which would be unfavourable for the rendition of the prosthesis (Figs. 1 & 2). After evaluating the patient's motivation, the decision was made to use the new Straumann® Mini Implants (2.4mm diameter) with the integrated Optiloc® retention system for a new denture supported by four implants. The implants were planned for placement in the regions 34, 32, 42 and 44. Due to the very limited width of the ridge, open flap surgery was planned in order to place the implants safely under direct vision.

## Surgical procedure

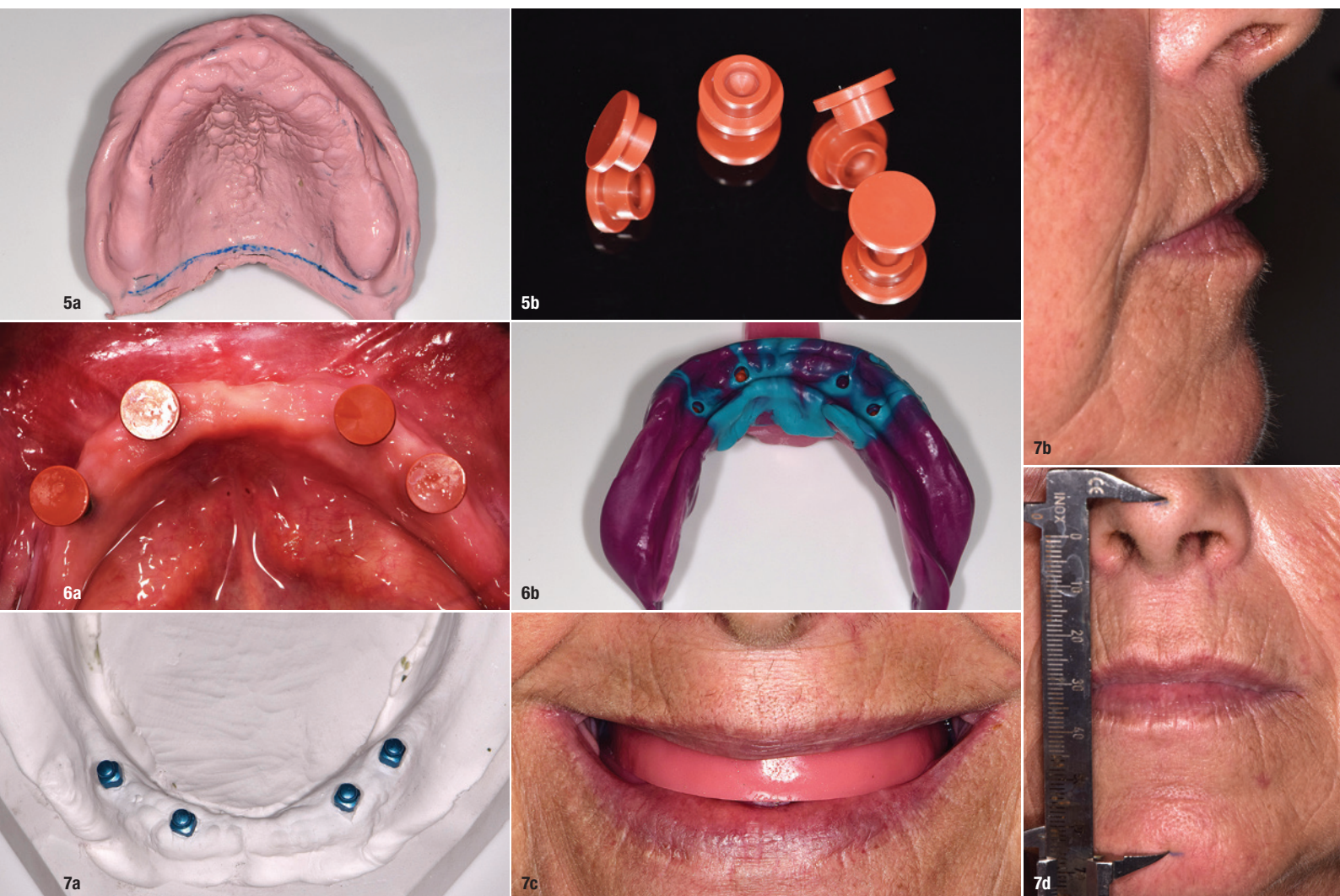
After a careful crestal incision, keeping the edge of the blade always in contact with the thin bone ridge, a central release incision was performed. The flap was raised



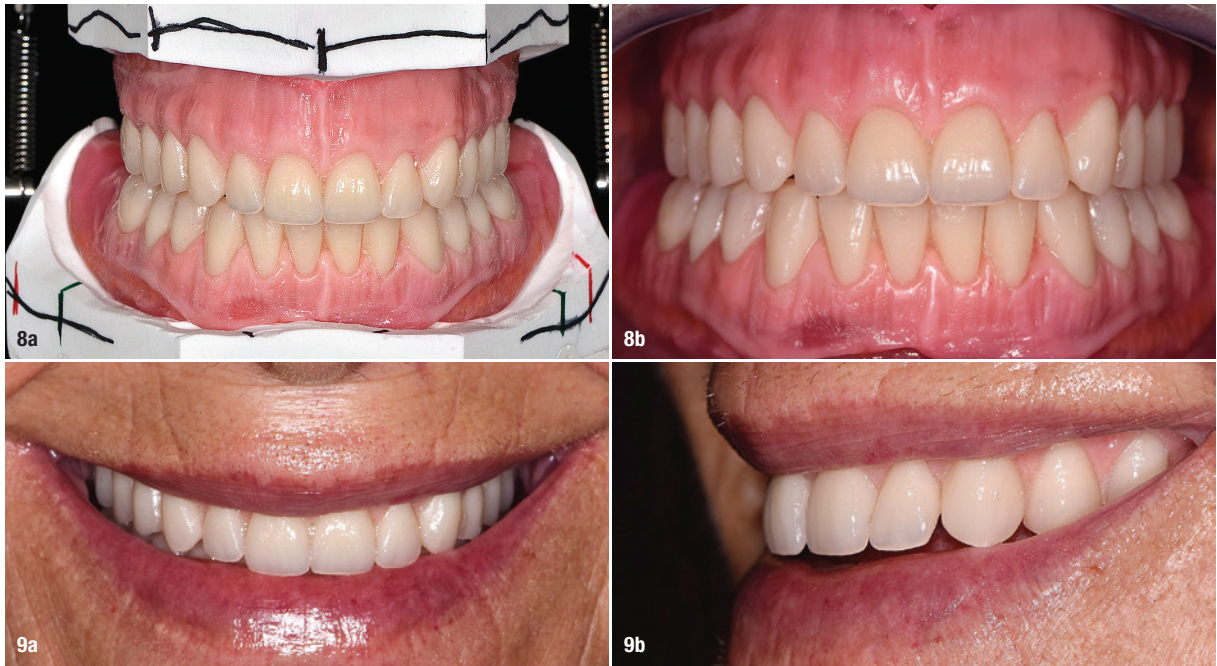to obtain a clear view of the underlying bone (Fig. 3a). In the area of the left incisor, the ridge appeared to be too thin for implant placement, probably owing to a previous cystic lesion. The implant that had initially been planned in region 32 was therefore moved to region 33. For the implants in regions 42 and 34, the site was prepared sequentially with the needle drill (1.6mm diameter) and the pilot drill (2.2mm diameter), while only the same needle drill was used for the implants in regions 44 and 33. During the preparation of the implant sites, parallelism was verified at all times through the parallel posts (Fig. 3b). Finally, the four implants were placed in the respective sites, initially using the vial caps and then inserted and stabilised with the Optiloc® ratchet adapter and the ratchet itself (Fig. 4a). The flap was closed with a 4/0 polyamide continuous suture (Figs. 4b & c). Owing to the thin bone crest, immediate loading was avoided by grinding resin from the existing prosthesis in order to prevent contact with the transgingival part of the implants during the healing phase.

### Prosthetic procedure

After a healing period of six weeks, the patient was referred to the Division of Gerodontology and Removable Prosthodontics at the University Clinic of Dental Medicine in Geneva in Switzerland for the final rehabilitation of her completely edentulous maxilla and mandible, with the Straumann® Mini Implants placed in the latter. During the first consultation, preliminary impressions were taken using an irreversible hydrocolloid impression material. Simultaneously, the patient's conventional mandibular CD was relined using a functional impression tissue conditioning material for better interim retention. In the maxilla, a conventional impression was taken using a customised impression tray, enabling a mucodynamic border moulding followed by a mucostatic final impression using zinc oxide eugenol impression material. In the mandible, the Optiloc® impression/fixation matrices were placed on the Optiloc® before a mucodynamic impression was taken with an elastomeric polyvinyl siloxane



**Figs. 5 & 6:** A mucodynamic impression was taken. **Fig. 7a:** The master models were prepared using the Optiloc® analogues and standard techniques. **Figs. 7b–d:** Aesthetic teeth exposure was ensured (b), the occlusal planes were checked (c), and the vertical dimension of occlusion was defined (d).

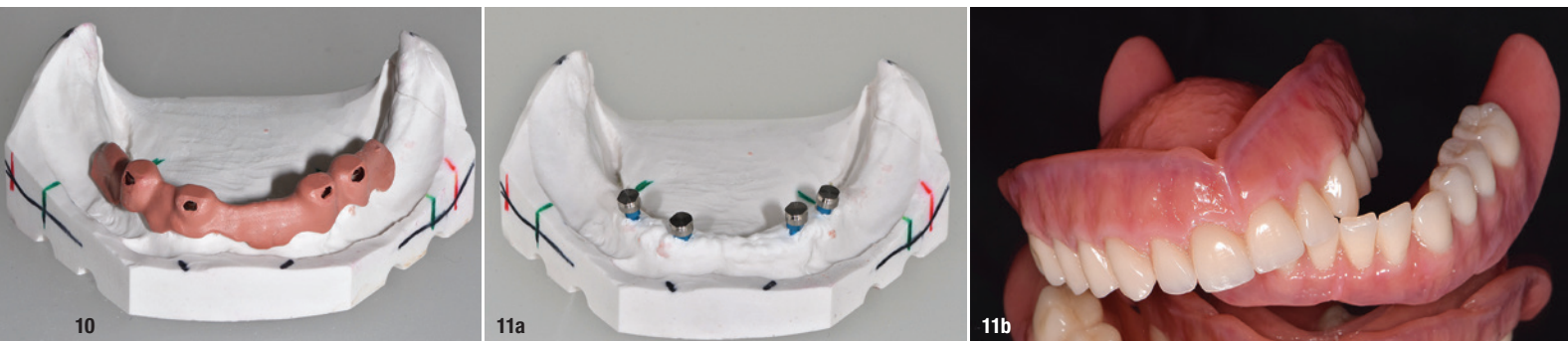

**Fig. 8a:** Final bite registration was performed. **Fig. 8b:** Photographs of the patient's natural dentition helped in preparing the final teeth set-up. **Figs. 9a & b:** The final set-up was checked during try-in.

(PVS) impression material (Figs. 5 & 6). The preparation of the master models and corresponding wax rims and all subsequent laboratory works were carried out in the Swiss-based dental laboratory Zahnmanufaktur Zimmermann und Mäder in Bern using the Optiloc® analogues and standard techniques (Fig. 7a). The next clinical steps included verification of the upper and lower lip support (ensuring aesthetic teeth exposure), checking the occlusal planes, defining the vertical dimension of occlusion, and final bite registration (Figs. 7b–d).

Communication with the dental laboratory using photographs of the patient's natural dentition was a key factor for successfully preparing the final teeth set-up (Figs. 8a & b). During try-in, the final set-up was checked for lip support, occlusal planes, teeth exposure and occlusal contacts (Figs. 9a & b). Moreover, the patient

was able to suggest modifications and give her consent before the final prostheses were prepared. To prevent fractures and ensure the longevity of the mandibular IOD, a polyether ether ketone (PEEK) reinforcement was incorporated in the final prosthesis (Fig. 10). The new conventional maxillary CD and mandibular IOD on the Optiloc® retention system was then finalised in the dental laboratory, placing the Optiloc® housings and processing inserts on all Optiloc® model analogues and following the usual manufacturing procedures. The dental laboratory delivered the completed maxillary CD and mandibular IOD (Figs. 11a & b). During the final consultation, the appropriate retention inserts (low force) Optiloc® were selected and inserted into the housings using the Optiloc® retention insert placement tool (Figs. 12 & 13). The completed conventional maxillary CD and mandibular IOD were then inserted into the patient's mouth, and



**Fig. 10:** A PEEK reinforcement was incorporated in the final prosthesis. **Figs. 11a & b:** The dental laboratory delivered the completed maxillary CD and mandibular IOD.

# Making the difference together

Women and men, young and old that have lost their teeth place their trust in you to restore their happiness and quality of life. It is your detailed planning, careful surgery, unique restorations and individual follow-ups that let them experience the confidence and joy of smiling again.

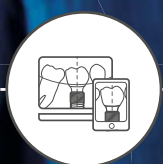So whatever challenges you face, you can count on us to develop solutions, concepts and processes that help you in your daily work, help you build your practice and your team so that you can achieve the best results for your patients.



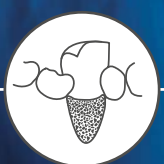Comprehensive solutions




Professional and business development



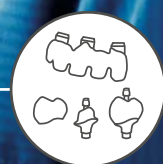Digital planning



Regenerative



Implant systems



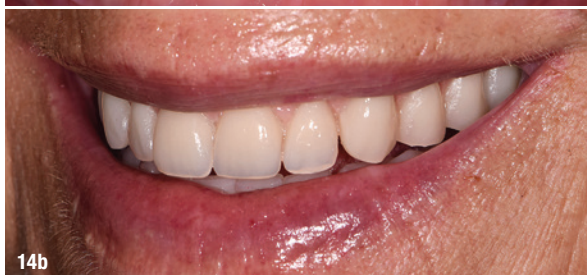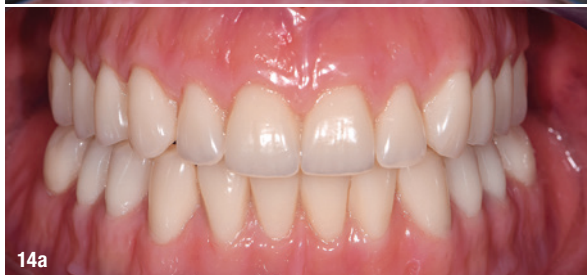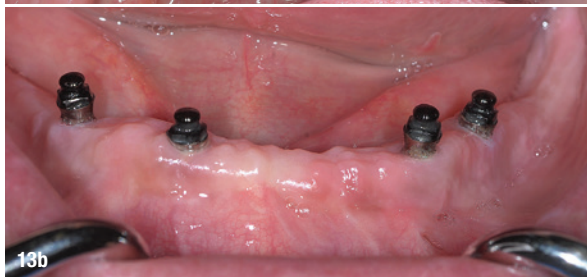
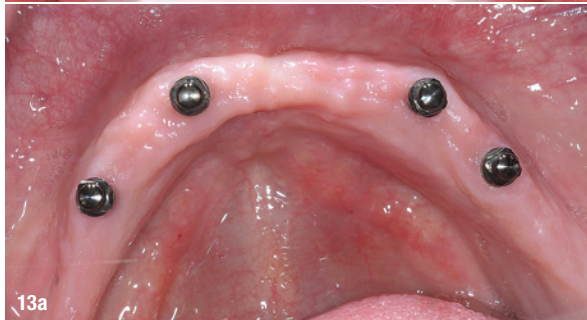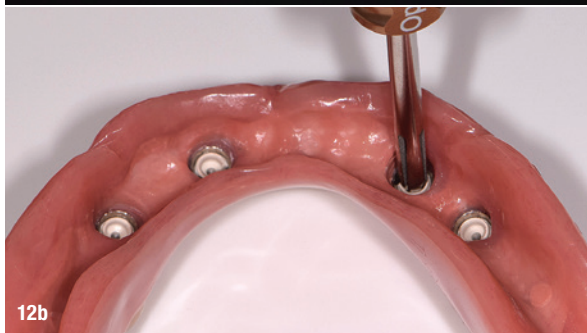Restorative

Follow Dentsply Sirona Implants



[dentsplysirona.com/implants](https://dentsplysirona.com/implants)

 **Dentsply  
Sirona  
Implants**



**Figs. 12a & b:** Retention inserts (low force) Optiloc® were selected and inserted into the housings using the Optiloc® retention insert positioning tool. **Figs. 13a & b:** Occlusal and frontal view at the final consultation. **Figs. 14a & b:** Frontal view of the inserted completed conventional maxillary CD and mandibular IOD.

final post-insertion and denture hygiene instructions were given to the patient (Figs. 14a & b).

### Conclusion

The case was successfully handled. The patient was highly satisfied and reported increased functional comfort and social confidence. The use of four 2.4 mm diameter Straumann® Mini Implants to support a mandibular overdenture has proved to be a reliable technique, which guaranteed satisfactory results both for the operator and the patient in a case where traditional techniques with larger diameter implants were not possible.

*Editorial note: The surgical procedures were performed by Dr Nicola Alberto Valente and prosthetic procedures by Dr Nicole Kalberer supervised by Dr Murali Srinivasan.*

### about the author



**Dr Nicola Alberto Valente** graduated in dentistry from the University Cattolica del Sacro Cuore of Rome, Italy. He completed his Master of Science in Oral Sciences and his specialty program in periodontics at the State University of New York at Buffalo, NY, USA. He is a Diplomate of the American Board of Periodontology and has had an ITI

Scholarship from the University of Geneva, Switzerland. He has worked as Chef de Clinique in the Unit of Oral Surgery, Service of Maxillofacial Surgery of the University Hospitals of Geneva, University of Geneva until 2019. He will start his new duties as Clinical Assistant Professor at the State University of New York at Buffalo in 2020.

### contact

**Dr Nicola Alberto Valente**  
 University at Buffalo  
 School of Dental Medicine  
 250 Squire Hall, 3435 Main Street  
 Buffalo, NY 14214, USA  
[www.dental.buffalo.edu](http://www.dental.buffalo.edu)

Author details



# PRECISE 3D IMAGING

Show what you're made of—with precision from *PreXion*.

## EXPLORER PreXion3D

In 2019 the Japanese technology group *PreXion* successfully introduced their new CBCT system *PreXion3D EXPLORER*. Especially developed for European and US markets, the high-performance system allows for an extraordinary combination of the most precise imaging, great picture detail, low radiation exposure, safe diagnostics and digital planning, covering the entire range of indications in modern dentistry.

Show what you're made of—  
with precision from *PreXion*.

Arrange a free  
training session **NOW**.

(Phone: +49 6142 4078558 | [info@prexion-eu.de](mailto:info@prexion-eu.de))



**PreXion (Europe) GmbH**

Stahlstraße 42-44 · 65428 Rüsselsheim · Germany

Phone: +49 6142 4078558 · [info@prexion-eu.de](mailto:info@prexion-eu.de) · [www.prexion.eu](http://www.prexion.eu)



# Peri-implant bone regeneration through laser decontamination

## Endoscopic paracrestal tunnel technique

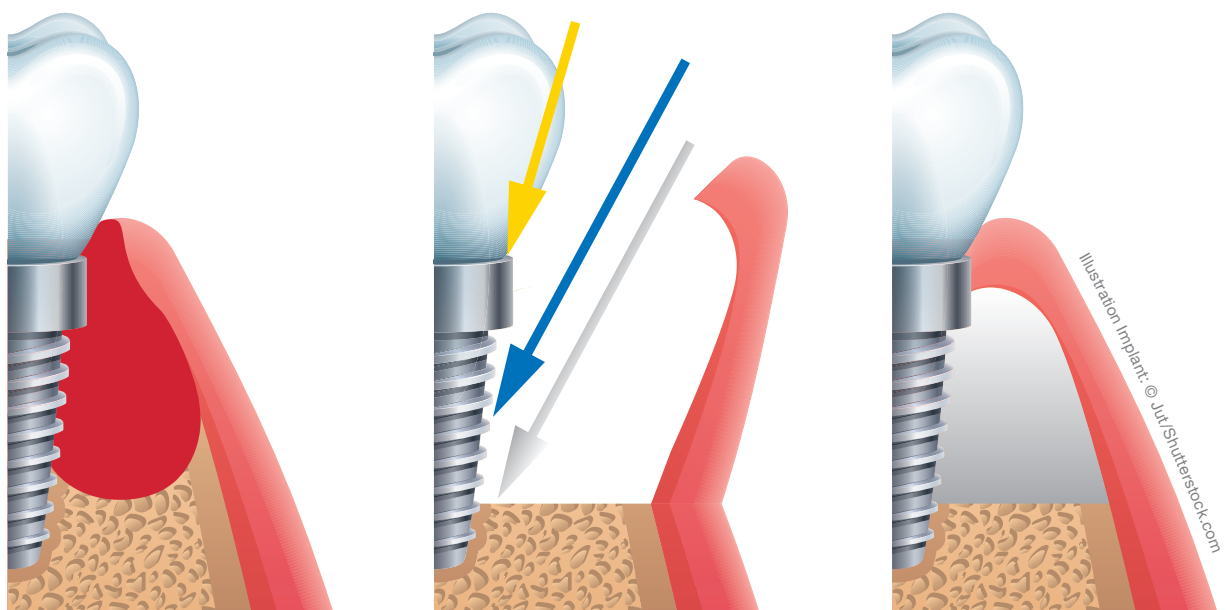
Prof. Wilfried Engelke, Dr Christian Engelke, Germany;  
Dr Victor Beltrán, Chile & Dr Marcio Lazzarini, Germany

### Introduction

The recently published S3 guidelines of the German Association of Oral Implantology (DGI) and the German Society of Dentistry and Oral Medicine (DGZMK) state that peri-implant infections can be categorised into peri-implant mucositis and peri-implantitis.<sup>1</sup> In peri-implant mucositis, only the supracrestal soft-tissue interface is involved; in peri-implantitis, the bony implant site is also involved.<sup>2</sup> Smoking is the main risk factor for peri-implant mucositis, but it is likely that there are further contributing factors, such as cement residue, diabetes mellitus and sex.<sup>2</sup> The development of peri-implantitis is particularly favoured by a history of periodontal disease, smoking and interleukin-1 polymorphism.<sup>4,5</sup> The main diagnostic criterion for distinguishing peri-implantitis from peri-implant mucositis is the lack of reversibility of the condition. Peri-implantitis can be characterised by putrid secretion,

increasing probing depth, pain and radiographic bone resorption. Implant loosening requires a high degree of bone resorption in the case of peri-implantitis. Microbiological tests are rather unspecific regarding peri-implant mucositis and peri-implantitis.

The goal of non-surgical peri-implantitis therapy is to eliminate the clinical signs of the infection. In addition to a partial or complete reduction in bleeding on probing (BOP), an effective therapy should lead to a reduction in the depth of periodontal pockets.<sup>6</sup> To date, deep peri-implant pockets have not been clearly defined, but in most cases, a probing depth of less than 6mm is considered a treatment success.<sup>7</sup> There are various treatment protocols used for non-surgical therapy: procedures for biofilm removal, antiseptic therapy and adjuvant antibiotic therapy. Surgical peri-implantitis treatment includes surface decontamination, adjuvant resectional therapy and, if necessary,



**Fig. 1a:** Open surgical peri-implantitis therapy with basal stemmed flap: application and operating direction of the laser for sulcular decontamination (yellow), implant surface decontamination (blue) and bone decontamination (white).

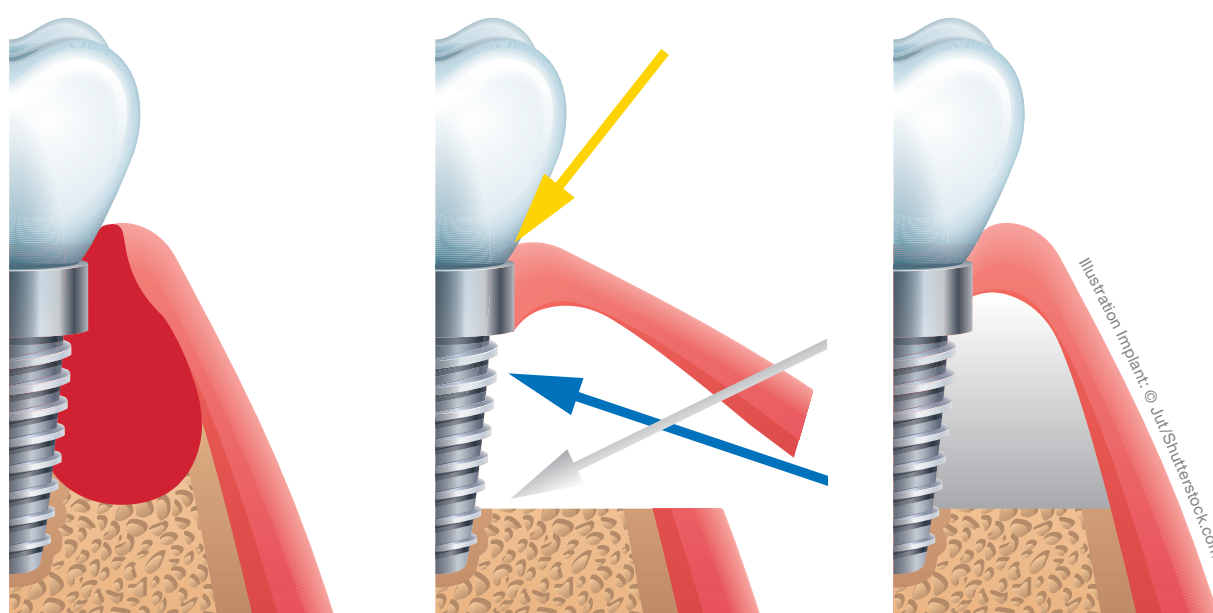
adjuvant augmentative therapy. Surface decontamination by means of a modified ultrasonic system (hydroxyapatite suspension) led to a comparable reduction in mucosal bleeding and probing depth after six months to mechanical debridement using carbon fibre or titanium curettes.<sup>8</sup> After an observation period of 12 months, BOP values increased again, especially in initially deep pockets.<sup>9</sup> In conventional flap surgery for surface decontamination, the use of special decontamination methods (e.g. 980nm diode laser, carbon dioxide laser, chlorhexidine digluconate and cetylpyridinium chloride) did not lead to significantly better clinical or radiographic results than in the respective control groups, in which air polishing, chlorhexidine solutions and placebo solutions were used.<sup>10,11</sup>

The clinical effectiveness of an adjuvant augmentative measure for flap surgery alone (titanium curettes and surface conditioning with 24% ethylenediaminetetraacetic acid and covered wound healing for six months) was investigated in a prospective clinical study using a porous titanium granulate for treating intraosseous defect components.<sup>12</sup> After the primarily covered wound healing, a very high exposure rate was observed in both groups (control group: 12/16; test group: 13/16). After 12 months, both procedures showed a comparable reduction in probing depth and only minor improvements in peri-implant bleeding values. However, in the test group, a significantly higher decrease in radiographic translucency in the intraosseous defect area, as well as an increase in implant stability, was observed.<sup>12</sup> For advanced, complex defect configurations, surgical augmentative and resectional procedures were combined as part of an implantoplasty procedure. An implantoplasty was aimed at smoothing the macro- and microstructure of the implant body in

areas outside the physiological barrier of current augmentation procedures. Augmentation (xenogeneic bone substitute material of bovine origin and a barrier membrane) was carried out only in the area of intraosseous defects, whereby the adjacent implant surfaces were preserved in their original structure, and these surfaces were decontaminated before augmentation. Over an observation period of four years, combination therapy after open wound healing led to a clinically relevant reduction in BOP and ST values. A difference between the two investigated decontamination methods was not observed.<sup>13</sup>

In summary, it is not possible at this point to clearly determine which protocol should be preferred, based on current literature. In the case of surgical therapy, granulation tissue should first be entirely removed. The decontamination of exposed implant surfaces should be of central importance. Mechanical procedures (for reducing biofilm) and chemical procedures (for reducing and inactivating biofilm) are often combined. At this point in time, the additional benefit of peri- and/or postoperative antibiotic therapy cannot be assessed. Analogous to the guideline for perioperative antibiotic prophylaxis, a supportive once-off administration can be done as part of surgical peri-implantitis therapy. After decontamination, augmentative measures can lead to a radiographically detectable filling of intraosseous defect components. It should be noted that all surgical therapy approaches involve a high risk of postoperative mucosal recession. Soft-tissue augmentation can be performed to stabilise the peri-implant mucosa.<sup>14</sup>

In addition to these general explanations based on the guidelines, a number of techniques have been described



**Fig. 1b:** Surgical peri-implantitis therapy with closed endoscopic paracrestal tunnel technique: application and operating direction of the laser for sulcular decontamination (yellow), implant surface decontamination (blue) and bone decontamination (white).





# CURAPROX

# PERIOPPLUS+

 SWISS PREMIUM ORAL CARE



while perfusing the tunnel with a sterile sodium chloride solution. The gingival cuff could be mobilised towards the occlusal plane via a high vestibular periosteal slit. Granulation tissue was removed and the implant surface decontaminated under direct endoscopic vision without irrigation. Decontamination was done with a GaAlAs laser set at 1W and at a wavelength of 809nm (Fig. 3). The exposure time was 20 seconds. Four repetitions in contact mode were enough to produce sterile conditions.<sup>20</sup> After filling the defect with tricalcium phosphate ceramic and locally obtained autogenous bone particles, the minimally invasive access was closed with two button sutures. The postoperative medication consisted of an analgesic (paracetamol, 500mg, if necessary) and a single dose of antibiotic (clindamycin, 600mg). The postoperative course was inconspicuous, and the augmentation height showed that the defect had been completely regenerated. In the re-entry to expose the implant after four months, a complete bony covering of the implant could be observed vestibularly (Fig. 4). The prosthetic restoration was performed by the family dentist.

### Discussion

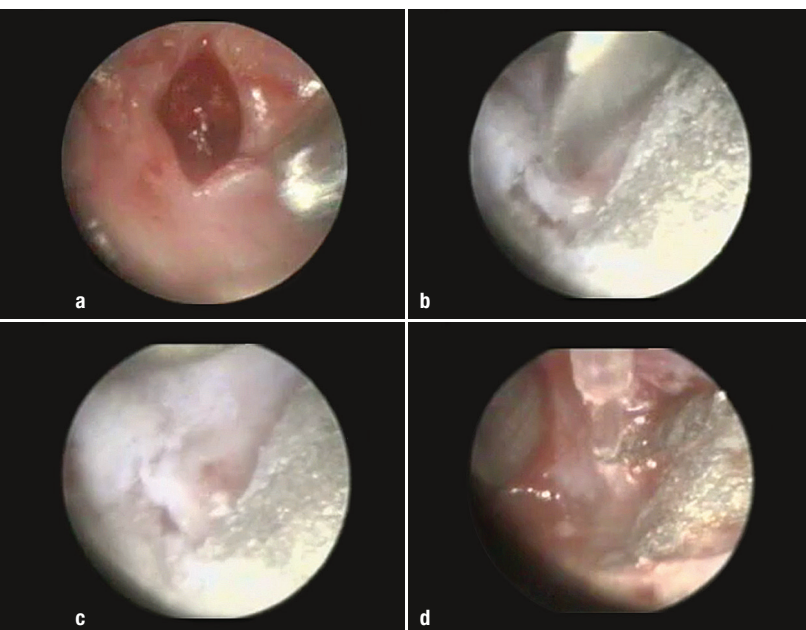
The concept of microsurgical peri-implant bone regeneration using the tunnel technique complies with the DGI/DGZMK guidelines and has two significant advantages: firstly, the cervical gingival cuff around the implant is preserved, and secondly, augmentation material can be securely positioned in a zone of optimal perfusion through the local periosteum. This significantly reduces the risk of postoperative recession and promotes bone regenera-

tion. Support immersion endoscopy allows a minimally invasive approach away from the implant. The different types of support and irrigation shafts allow preparation under immersion. Blood and secretion are immediately removed by the irrigation flow and do not interfere with the preparation of the operation site. After exposure of the infected part of the implant surface inside the tunnel, laser decontamination should be done in an aerobic environment, reducing heat generation and, thus, allowing for targeted decontamination. Using intermittent irrigation, the operating field can be freed from detritus and secretion at any time. Finally, surface decontamination is done in the open operation area. The size of the tunnel entrance and its localisation can be reduced to such an extent that large-area detachment of the flap and basal flap extension by periosteal slitting can be avoided without compromising visualisation of the contaminated implant surface.

Bleeding in the tunnel can be stopped by means of vasoconstrictors or direct laser coagulation so that an optically perfect assessment of the critical parts of the bone pockets is possible using support immersion endoscopy. Removal of granulation tissue with a laser has the advantage that a low-bleeding preparation technique facilitates the precision of the subsequent steps significantly. This advantage of the endoscopic technique can also be used for tunnel procedures in primary bone augmentation, allowing reliable intraoperative quality control of the microsurgical measures even without flap reflection. If dealing with fixed implants, it is not advantageous to remove the superstructure before the operation, since the operating direction is apical. Removal should only be carried out in pathological situations, for example inaccuracies in fit. In the case of extensive interdental or oral defects, multiple tunnelling sessions might be necessary. Their indication should be clarified beforehand by means of 3D imaging. In the case that is described in this article, 3D diagnosis was not desired by the patient. Based on the extensive experience of the authors with the described procedure, it can be stated that the tunnelling of apicoapproximal peri-implantitis is advantageous for the majority of referred peri-implantitis cases and that the frequency of dehiscence may be significantly reduced by modifying the approach.

The recommended treatment sequence for the peri-implantitis therapy described in this article is as follows:

- Granulation tissue is first removed completely.
- The implant surfaces exposed in the tunnel are safely decontaminated.
- After decontamination, suitable augmentative procedures are performed for radiographically detectable filling of intraosseous defects. The choice of suitable procedures depends on the clinician's experience. The use of bone block grafts can also be considered if the tunnel entrance is wide enough.



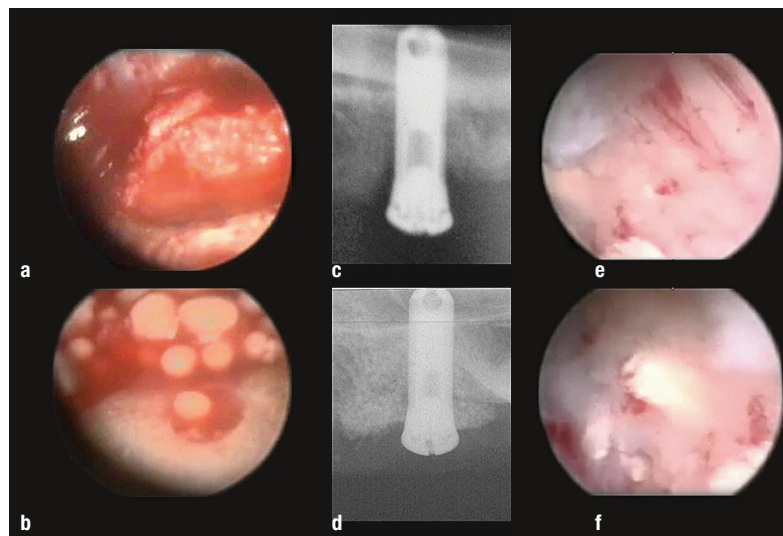
**Fig. 3:** Intra-op situation: mucosal incision away from implant (a), vestibular mucosa (b), laser fibre in the fundus of the bone pocket (immersion) (c), decontamination of the bone pocket (without immersion) (d).

In all surgical therapy approaches without preservation of the cervical peri-implant gingival cuff, there is a high risk of postoperative mucosal recession. Only through systematic comparative investigations of the influence of soft-tissue surgery with and without preservation of the cervical gingival cuff can solid data be obtained in order to adequately evaluate the influencing parameters. The microbial analysis of implant surfaces shows a significant relation between peri-implant infections and the number of microorganisms on the surface. Therefore, laser treatment units should be considered for treating such cases owing to their inherent and well-documented disinfection potential. The visually controlled implant surface decontamination with a laser has a clear advantage over the closed application of a laser in the periodontal pocket, since clinically problematic areas can be treated with better visualisation. In addition, carbonised tissue and necroses can be easily and safely ablated during surgery. Up to this point, surface smoothing of the implant was usually not necessary owing to the augmentation in the closed tunnel procedure, as regeneration was aimed for. The re-entry image shows that regenerate had formed on the initially exposed and visibly contaminated rough implant surface, effectively preventing recession.

Guiding the laser fibre via an apical tunnel entrance allows for the cervical gingival cuff on the implant to be altered as little as possible. The procedure described in this article can also be used on implants prior to their definite exposure if it becomes apparent that the cervical vestibular bone lamella is insufficiently dimensioned and requires secondary augmentation. In addition, apical tunnel access can be gained in all stages of a prosthetic restoration without changing the soft-tissue situation in contact with the superstructure. The tunnel boundaries should be fashioned in such a way that outflow of the augmentation material is prevented and the placement of the augmentation material is gradually controlled endoscopically. In this context, form stability of the augmentation material, as recommended by manufacturers of biomaterials such as GUIDOR easy-graft (Sunstar Suisse), is very important. If followed, a certain overcontouring in the crestal area can be achieved. The relocation of tissue required for this is determined by the particular type of defect. With concave alveolar ridges, the restoration up to overcontouring of the original ridge volume can mostly be easily achieved. In some cases, however, the coronal relocation of the soft-tissue cover should be supported by a basal periosteal slit.

### Conclusion

Practitioners who consider using the described technique can safely assume that the minimal invasiveness of the procedure is highly appreciated by patients. Furthermore, the number of postoperative complaints is considerably lower compared with those with open procedures.



**Fig. 4:** Intra-op situation: augmentation with autologous bone material (a) and tricalcium phosphate augmentation material (b). Radiographic findings: pre-op (c) and post-op site (d) on the tooth film, clear filling of the defect. Re-entry after four months: implant surface covered by bone (e) with residue of bone replacement material (f).

In order to finally assess the clinical value of this procedure with regard to compliance and the postoperative healing period, however, extensive, preferably prospective, randomised studies are required.



### about the author



**Prof. Wilfried Engelke** is a Germany-based dentist specialised in oral surgery and implantology. He is head of the DZOI "Curriculum Implantologie". In 1996, he was appointed Professor and since then, he has been giving lectures not only at the Medical Faculty of the University of Göttingen, but at Universities all around the globe.

### contact

**Prof. Wilfried Engelke**  
 Allerberg 15  
 37130 Gleichen, Germany  
 wengelke@med.uni-goettingen.de



# Sixteen years of follow-up after insertion of a Z1 implant

Dr Virgilio Masini, Italy

In the following case report, Italy-based oral surgeon Dr Virgilio Masini describes how the advantages of a titanium implant with a zirconia collar can ensure long-lasting function and aesthetics.

In 2003, a 40-year-old female patient presented with a removable prosthesis in the region of tooth #24, which had been extracted the year before owing to a fracture (Fig. 1). Treatment options for restoring region #24 with a fixed solution were discussed with the patient, who wanted a more comfortable alternative to the removable restoration that she had. The patient decided to have a dental implant placed and restored with a metal–ceramic prosthesis in order to avoid damaging the two adjacent teeth. A radiograph was taken to assess whether the pa-

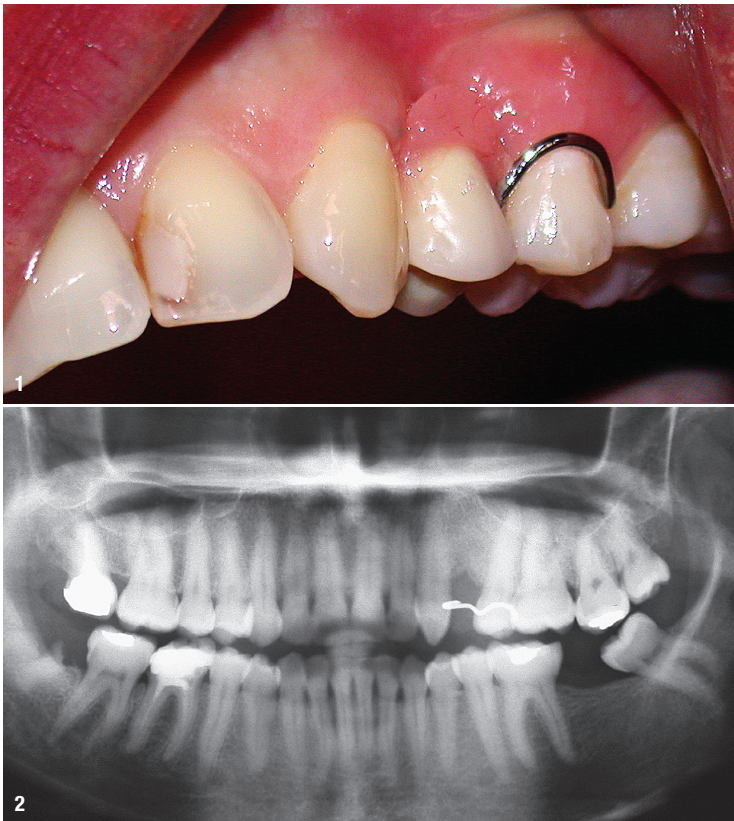tient had adequate width and height of bone for implant placement (Fig. 2). This revealed that, as a result of the fracture of the extracted tooth #24, the patient had lost a large part of the buccal bone plate. The radiograph also showed that the patient had retained the residual root of tooth #48. To ensure sufficient quality and quantity of buccal bone, it was decided that the residual root of tooth #48 would be extracted at the same time as implant placement in region #24, and the bone surrounding the tooth root would be used as part of a guided bone regeneration (GBR) procedure. To maintain the hard and soft tissue more coronally, a 13 x 4 mm Z1 implant (TBR Dental) with a zirconia collar height of 3 mm was planned for.

## Implant placement

The surgical aspect of treatment began with the extraction of the residual root in the region of tooth #48. At the same time, fragments of bone from the surrounding area of the surgical site were extracted and mixed with hydroxyapatite of equine origin. Once the extraction site had been closed and sutured together, a delayed implant placement protocol was followed for region #24. This involved making an incision in the gingiva and raising a flap to expose the buccal bone. The hole was then drilled before the implant was placed successfully at soft-tissue level and a cover screw fitted (Fig. 3). At this point, GBR was performed using the fragments of the bone taken from the surrounding area of tooth #48 (Fig. 4), which were placed on the buccal bone of the implant site and covered with a resorbable collagen membrane (Fig. 5) that was fixated with a micro screw. A radiograph was taken to confirm that the implant was positioned correctly (Fig. 6), and the patient was given appropriate post-surgery care instructions.

## Implant restoration

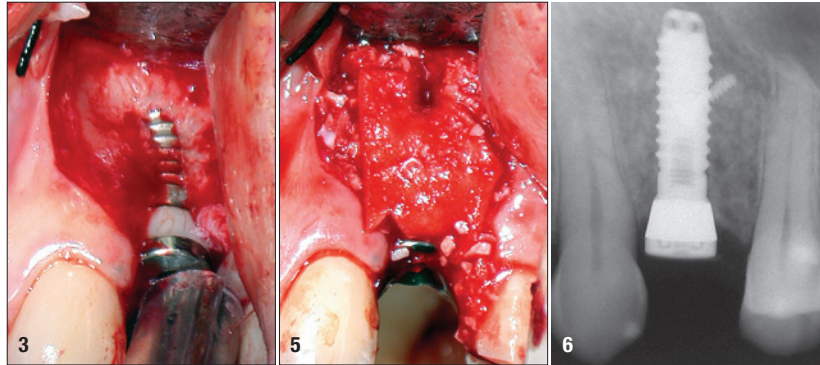
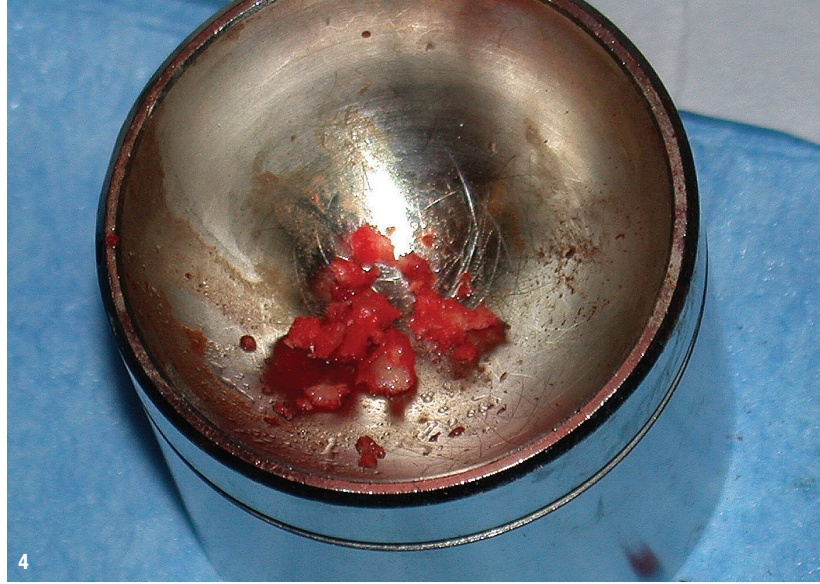Six months after placement, the implant was reviewed and found to be stable. The patient had experienced a slightly prolonged period of post-surgical oedema, but this had been effectively controlled with non-steroidal anti-inflammatory medication. As a result, the soft-tissue was pink and healthy and there were no signs of inflammation (Fig. 7). The implant was restored with a straight



**Fig. 1:** Removable prosthesis in the region of tooth #24. **Fig. 2:** Panoramic radiograph prior to implant surgery.

stock titanium abutment and a metal–ceramic crown. In cases of a classic fixed prosthesis and healed tissue—where the overflow of cement can easily be controlled—I always prefer to use cement-retained restorations, unless the height of the prosthesis is low and there is a risk of de-cementation. It is widely known that excess cement is one of the main causes of peri-implantitis.<sup>1</sup> Screw-retained restorations are my preference for full-arch restorations and cases of immediate loading, even for single crowns.

To further optimise the aesthetic result in this case, the implant was loaded with the final restoration after a soft-tissue management protocol. This was carried out by making an incision and raising an apically positioned flap to increase the amount of attached gingiva at the surgical site (Figs. 8 & 9). At this time, the micro screw was removed and it was confirmed that the GBR procedure had indeed been successful. The surgical site was then sutured together. The soft tissue was effectively managed by the zirconia collar of the Z1 implant and the cover screw, which meant that a temporary restoration was not necessary. A metal–ceramic crown was used in this case owing to my lack of experience with zirconia crowns at the time. However, if this case presented today, a zirconia crown would have been chosen to restore the im-



**Fig. 3:** Implant placed in region #24. **Fig. 4:** Material preparation for the guided bone regeneration. **Fig. 5:** Placement of the guided bone regeneration material. **Fig. 6:** Radiograph of the implant in region #24.

AD



**EACim congress \ April 25, 2020**  
**Hotel Le Plaza \ Brussels**

**Theme : LARGE RECONSTRUCTION WITH CERAMIC IMPLANTS**

Chairman: Prof. Carlo Maiorana and the participation of:

Pr. Eric Rompen Dr. Alexander Volkmann Dr. Paul Petrunaro Dr. Andrea Enrico Borgonovo Dr. Sammy Noubissi Pr. Marcel Wainwright Dr. Saurabh Gupta



\ Conferences in English with simultaneous translation into French \

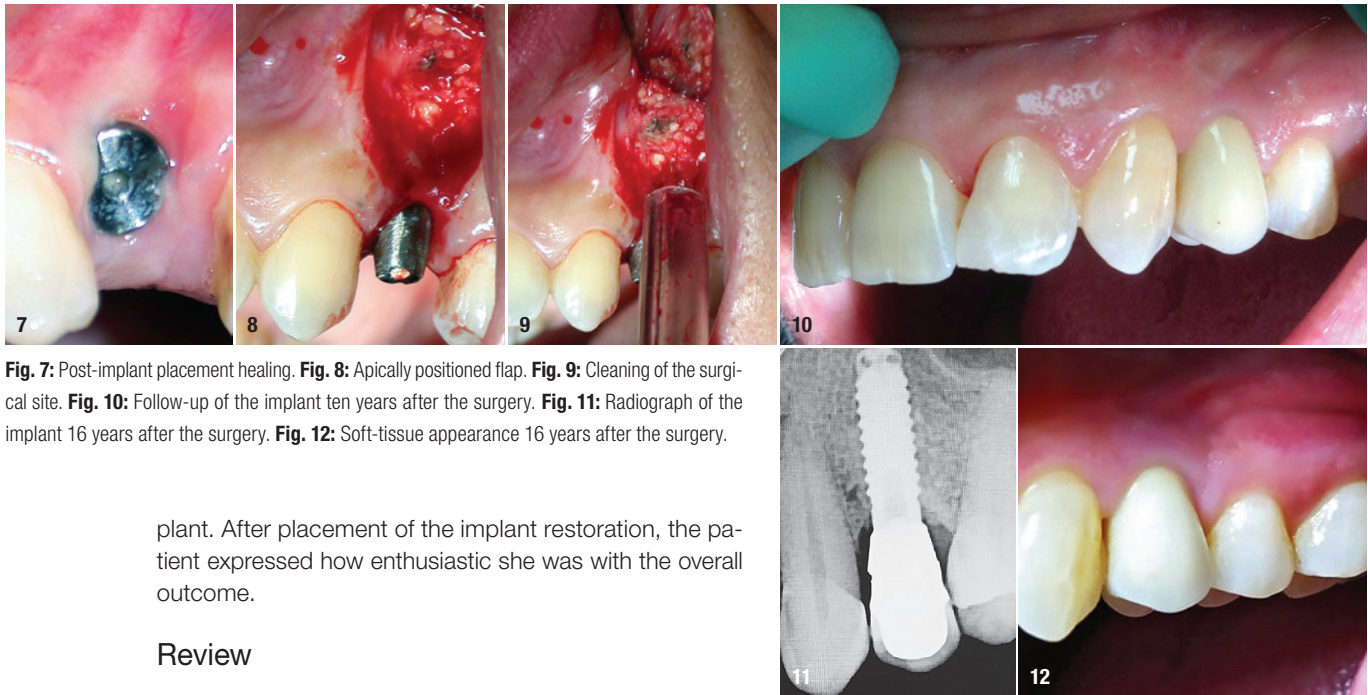
**Optional : pre-congress workshop: "DIGITAL WORKFLOW AND CERAMIC IMPLANTS"**

**Friday, April 24 from 2:00 pm to 5:30 pm**

**ONLINE REGISTRATION**

**eacim-ceramic-implantology.com**

Information: info@cosyn.eu \ Phone : + 32 477 41 32 98



**Fig. 7:** Post-implant placement healing. **Fig. 8:** Apically positioned flap. **Fig. 9:** Cleaning of the surgical site. **Fig. 10:** Follow-up of the implant ten years after the surgery. **Fig. 11:** Radiograph of the implant 16 years after the surgery. **Fig. 12:** Soft-tissue appearance 16 years after the surgery.

plant. After placement of the implant restoration, the patient expressed how enthusiastic she was with the overall outcome.

### Review

During a routine check-up in 2013, the implant was reviewed. The patient was very happy with the final result and remains a regular patient of the practice. The gingiva around the implant was pink and the papilla had also been maintained so that the implant restoration demonstrated aesthetics and function similar to those of the natural teeth (Fig. 10). The zirconia collar of the Z1 implant had encouraged optimal healing of the soft tissue around the implant to create an excellent emergence profile. It also eliminated the risk of the titanium components becoming visible through the gingiva. Sixteen years after the surgery, the implant was reviewed again and the final outcome remained unchanged. A radiograph showed that there was minimal bone resorption and that the implant was stable (Fig. 11). The soft tissue also appeared healthy and there was no difference between the implant restoration and the surrounding natural teeth (Fig. 12).

### Discussion

Prior to implant placement, the patient in this case had experienced bone loss as a result of the fracture of the extracted tooth #24. However, the zirconia collar of the Z1 implant was able to stabilise the soft tissue coronally at the implant site, a result that had improved over time. The benefits of the Z1 implant are mainly aesthetic, as it helps manage the soft tissue and improves plaque control. Indeed, zirconia surfaces demonstrate a lower affinity to bacteria compared with titanium.<sup>2</sup> The Z1 implant system is my implant of choice in cases in which I want to maintain the soft tissue and avoid bone augmentation (for instance, in the case of immediate post-extraction implants with moderate loss of the buccal bone plate). In the molar area of patients who have difficulty controlling plaque, I also prefer to position the implant edge at tis-

sue level or even slightly supragingivally. This case ultimately demonstrates that choosing a top-quality implant solution can help ensure that patients benefit from an outstanding, long-lasting restoration that is highly aesthetic and functional.



### about the author



**Dr Virgilio Masini** graduated in medicine and surgery with honours from the Sapienza University of Rome in Italy in 1982 and specialised in dentistry with honours at the University of Rome Tor Vergata, Italy. He has a special interest in implantology. For three years, Dr Masini attended the Maxillofacial Surgery Complex Operational Unit at the University Cattolica del Sacro Cuore in Rome. Dr Masini has also taught in the master of oral surgery and implantology programme at the Gabriele d'Annunzio University of Chieti–Pescara, University of Naples Federico II, Sapienza University of Rome and Vita-Salute San Raffaele University in Milan, Italy.

### contact

**Dr Virgilio Masini**  
Via Piave 7  
00187 Rome, Italy  
Phone: +39 06 8540759  
www.odontoiatriadrmadini.it



Premium Partner  
**camlog**

Premium Partner  
**straumann**group

Premium Partner  
**Geistlich**  
Biomaterials

Premium Partner  
**Dentsply**  
Sirona

# VISIONS IN IMPLANTOLOGY



3<sup>RD</sup> FUTURE CONGRESS FOR  
DENTAL IMPLANTOLOGY

50 Years – From single Implant to digital Workflow

50<sup>TH</sup> DGZI INTERNATIONAL  
ANNUAL CONGRESS

**6–7 November 2020**

Maritim Hotel & Congress  
Centrum Bremen

**WWW.OEMUS.COM**

OEMUS MEDIA AG · Holbeinstraße 29 · 04229 Leipzig · Germany · Phone: +49 341 48474-308 · Fax: +49 341 48474-290 · event@oemus-media.de

**DGZI**  
Deutsche Gesellschaft für  
Zahnärztliche Implantologie e.V.

# The **next generation** biomaterial for soft-tissue augmentation

OEMUS MEDIA, Germany



On 17 January 2020, Camlog DACH organised the first NovoMatrix™ expert round table in Wimsheim, Germany. At this meeting, the clinicians involved in the pre-launch phase, gathered to exchange and discuss their experiences with the new biomaterial. After the presentation of the clinical and pre-clinical studies performed by Dr Gerhard Iglhaut (Germany) and Dr Edward Pat Allen (USA), the experts split in six groups to share and discuss their clinical experience. Each round table focussed on one of the following indications: gain of keratinised tissue, recession coverage, or augmentation of soft tissue around implants. The meeting was considered a great success by the participants. The content and structure of the meeting was regarded as highly scientific and was appreciated by the experts.

The following fundamental messages could be extracted from the expert round table: the exceptional handling characteristics and contoured shape are well suited for soft-tissue augmentations around teeth and implants, root recession coverage, and are designed to be used with different surgical techniques, to reduce time for product trimming, and to make intraoperative placement easier and more predictable. There was a consensus that additional clinical testing is needed, including long-term follow-up and further clinical studies with NovoMatrix™. However, very good healing could already be seen in early stages.

For over 20 years, LifeCell™, an Allergan affiliate and leading global medical technology company, has been developing in-

**Fig. 1:** The participants of the recently held NovoMatrix™ expert round table with the Camlog team.





**Fig. 2:** Dr Gerhard Iglhaut (Germany), a pioneer in the use of NovoMatrix™, at the expert round table.

novative products for the use in a wide range of applications. BioHorizons and Camlog have joined forces with LifeCell™ to bring NovoMatrix™, the next generation of soft-tissue augmentation material, into dentistry.

### About NovoMatrix™

NovoMatrix™ is an acellular dermal matrix consisting of tissue-engineered porcine material. It is a breakthrough in xenogeneic processing ensuring a structurally intact, undamaged scaffold that supports cell and microvascular ingrowth. The proprietary tissue processing allows for rapid revascularisation, cell repopulation and minimal inflammation. The product comes in a pre-hydrated and ready-to-use state and offers a true alternative to autogenous soft-tissue grafts and current products on the market.

### Indications and clinical evidence

When choosing a biomaterial, there is a strong demand in clinical practice for predictable outcomes. The NovoMatrix™ indications include guided tissue regeneration procedures in recession defects for root coverage, localised gingival augmentation to increase keratinised tissue around teeth and alveolar ridge reconstruction for prosthetic treatment. Dr Edward Pat Allen, one of the pioneer users of the novel biomaterial, says: “NovoMatrix™ graft exhibits uniform physical characteristics and great surgical handling, enhancing its ease of use in the tunnelling technique. This results in an excellent clinical outcome with minimal postoperative swelling and inflammation.”

After his workshop held at Osteology Barcelona last year, Dr Gerhard Iglhaut said about NovoMatrix™: “By using connective tissue grafts in the past, we had great outcomes and predictable results. But for the patients, the wound on the pallet was the most compromising challenge. We tried using new materials to avoid harvesting from the pallet, to have a second wound. And today

we have an acellular dermal matrix with porcine materials in Europe that overcomes this challenge. It is solid and it’s a little smoother, so in a minimally invasive tunnelling technique it helps us to slip it in and to suture it properly to residual tissue, which could be a challenge with connective tissue grafts.”

The national prelaunch is currently being implemented in EU countries taking into consideration the take-home messages learnt from the expert round table. As of yet, February 2020, over 100 key opinion leaders are already using NovoMatrix™ and they are exciting about the preliminary clinical results.

### About BioHorizons and Camlog

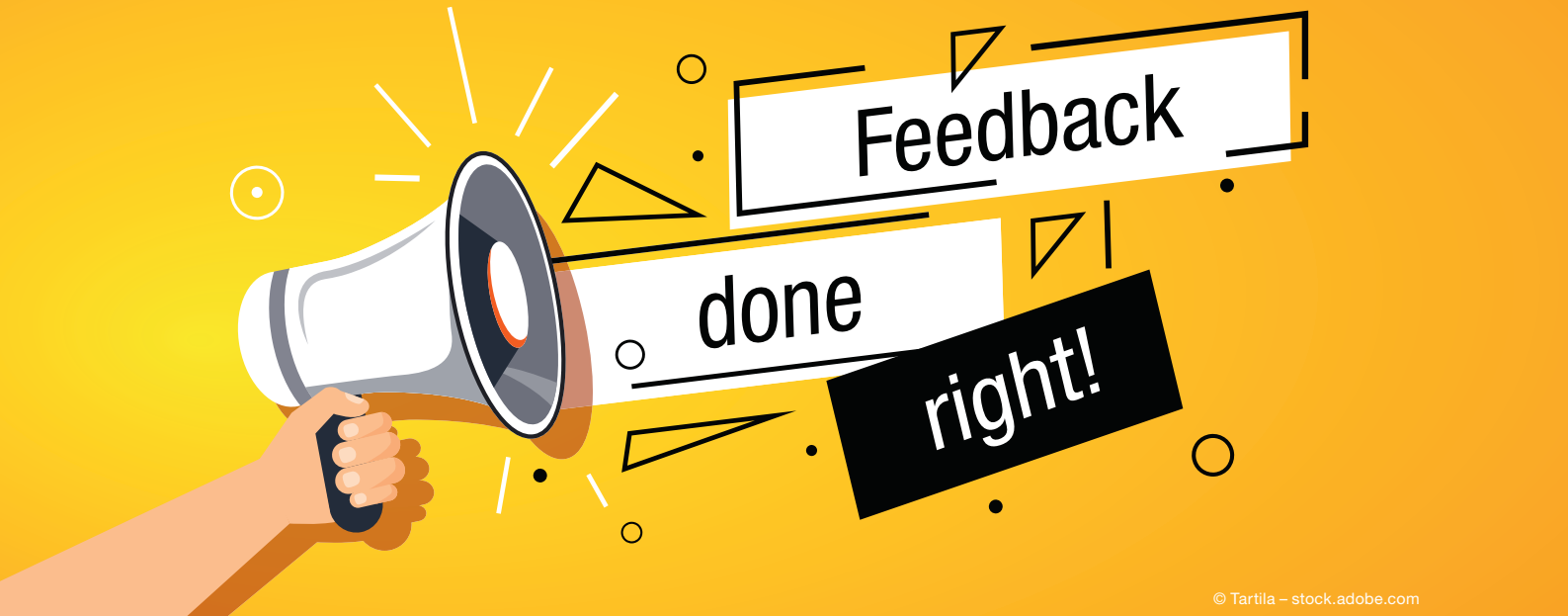BioHorizons and Camlog are leading suppliers of premium dental implant systems, restorative components, a comprehensive line of biologic products and digital solutions. They are committed to developing evidence-based and scientifically proven products, as well as continuous education according to highest standards. For more information, visit [www.biohorizonscamlog.com](http://www.biohorizonscamlog.com).

*Editorial note: References can be obtained from Camlog and BioHorizons upon request.*

### contact

#### **Branislav Kostadinov**

Senior Product Manager Biomaterials Europe  
BioHorizons Camlog  
[branislav.kostadinov@camlog.com](mailto:branislav.kostadinov@camlog.com)



© Tartila – stock.adobe.com

Andrea Stix, MSc, MBA; Germany

**In order to avoid** stress and disharmony in the daily work routine and to appear professionally as a team to the outside world, clear communication with one another is important. Reciprocal feedback is therefore of vital importance in order for communication in the dental practice to be as simple, appreciative and smooth as possible. What needs to be taken into account in this regard will be highlighted in this article.

### Feedback is important


Why we need feedback is explained by American social psychologists Joseph Luft and Harry Ingham in a model that sets out conscious and unconscious personality and behavioural traits. Their Johari Window, a combination of the psychologists' first names, is divided into quadrants and shows the differences in self-perception and perception by others. The open quadrant relates to what one reveals about oneself and what is known or visible to others. This includes external characteristics such as appearance, manners or even physical reactions, as well as internal attitudes and behaviour. The hidden quadrant is what a person knows about himself or herself, that is, things that he or she is aware of, but either unknowingly does not make available to others or consciously hides from them. The blind quadrant is everything that a person conveys and is perceived by the recipient without the sender being aware of it. Others thus recognise behaviours and characteristics that one does not perceive in oneself. Only through constructive feedback can information be moved from the blind quadrant to the open quadrant. It also allows reflection on things that we unconsciously keep from others. Feedback is an effective instrument to support colleagues or employees in their personal development. Unfortunately, the potential of this

powerful tool often remains unexploited in many companies.

### What is feedback?

The term “feedback” refers to a response to or assessment of a person’s behaviour. It is a central process by which a reaction is conveyed. With feedback, we inform someone about how we perceived and experienced his or her behaviour. In this way, we invite the other person to employ metacommunication, that is, to talk about his or her behaviour. The most common feedback error is criticism of personality traits—and that is exactly what turns feedback into ridicule. Discussion in this manner of one’s personality—which cannot be changed—is insulting and abusive, and no good or fruitful outcome can come from it. Authentic feedback, however, always aims at a positive change in behaviour; it is constructive and supportive. Feedback complements self-perception through external assessment and external perception. Feedback can

**Johari Window (Joseph & Harry Ingham, 1995)**  
*Conscious and unconscious personality and behavioural traits*



make visible how one's own behaviour has an effect on or is received by the other person, how a situation or performance is assessed or what potential for improvement exists. Correctly used, feedback can therefore be extremely valuable. In everyday professional life, it is almost indispensable for the further development of one's behaviour.

## Differentiation from praise

Praise is usually not very specific, such as "you did a good job", "I am very pleased with you" or "keep up the good work". Praise is therefore positive feedback which, owing to a lack of specificity, does not bring about any lasting change. Praise might be very important in daily interaction—but giving feedback is essential.

## Giving feedback

Giving constructive feedback has to be learned because, if applied incorrectly, it can have the opposite effect to that intended. Ideally, feedback should follow a methodical framework—feedback rules. The feedback should help the recipient to reflect on his or her behaviour in order to better assess its effect on others and to modify his or her behaviour if necessary. Feedback must be conveyed in a particular form in order to be fully effective.

## Feedback rules

In order for feedback to have a motivating effect and to encourage one to develop oneself further as a consequence, it is important to follow the ten golden rules of feedback. The context especially is of vital importance: feedback is particularly effective if it is given promptly. Feedback should never take place according to fixed times. It makes much more sense to give constructive feedback as relevant things—whether positive or negative—arise.

## Receiving feedback

Receiving feedback is also something that has to be learned. Most people initially react defensively to feedback and this is just what must be avoided. Constructive feedback is valuable because it reduces our blind spot. Explaining or justifying oneself immediately after receiving feedback would be counter-productive. Furthermore, feedback is not debatable. Even if one perceives the situation differently to the feedback received, it shows in a very appreciative way how one's behaviour affects others. The giver of the feedback must always intend to trigger a positive outcome—regardless of whether it concerns something negative that needs to be improved or something positive that needs to be reinforced. If one is not receptive to feedback, one is unlikely to receive authentic feedback. Hence: LISTEN. TAKE IT IN. SAY THANK YOU.

## Rules for constructive feedback:

1. Give feedback only in an emotionally relaxed state. This will help you to stay objective and avoid strong emotional reactions.
2. Is your counterpart receptive to feedback? Is feedback desired? Ask for feedback!
3. Separate statements about behaviour from statements about personality traits! In this way, you can avoid affronting the person and increase the probability that your feedback will be well received. IMPORTANT: Behaviour must be clearly separated from identity. There must be no moral judgement, generalisation or interpretation.
4. If you have negative things to communicate, also express your positive experiences, perceptions and feelings.
5. Give very specific feedback. Use concrete examples of the behaviour to which your feedback relates.
6. Observation: Describe only what is visible and objective for all.
7. Perception/effect: Make sensory statements and name your own (emotional) reaction to the recipient of feedback. Say what and how something has affected you: "It affects me ...".
8. Express yourself exclusively using "I": "I have seen ...", "I have noticed ...", "I feel ...".
9. Recommendation/wish: Address specific criteria for desirable behaviour so that your feedback is useful for future situations. "I recommend ...", "I would like ...", "I would like it if ...".
10. Be brief and only convey as much as your counterpart can take in.

In teams, feedback should always be given directly to the intended recipient.

## about the author



Germany-based **Andrea Stix** is a consultant for communication strategies. She is a coach in practice marketing and is specialised in personality diagnostics. She currently works as strategic consultant for CAMLOG.

## contact


**Andrea Stix, MSc, MBA**  
Strategic consulting  
CAMLOG Distribution GmbH  
Phone: +49 7044 9445-733  
andrea.stix@camlog.com



# Reshaping implantology

## New solution to reduce guesswork of site preparation

Nobel Biocare, Switzerland



When it comes to innovations in implant dentistry, the refinement of site preparation has fallen behind the advancements of implant design. Prof. Stefan Holst, Vice President of Premium Implants at Nobel Biocare and co-author of an original research study with Stanford University on the OsseoShaper™ design and biological benefits, describes some of the challenges presented by conventional drilling protocols and explains how this new device has been designed to overcome these problems.

### Prof. Holst, what is the new OsseoShaper™ device?

The OsseoShaper™ is a completely new approach to site preparation that addresses some challenges of conventional drilling protocols. Instead of using high-speed drills to create an osteotomy, the OsseoShaper™ gently 'shapes' it in a controlled way. It has been developed as part of our recently announced Nobel Biocare N1™ implant system.

### Site preparation protocols have hardly changed in over 50 years. What inspired you to focus on such well-established methods?

Our very first step in developing a new implant system was to examine every stage of implant treatment based on our 50 years' clinical experience. What are

the main challenges clinicians have? How can we try to avoid more errors? How can we optimise workflows? It became clear that drilling protocols can be improved, both practically and biologically. So, we funded new basic research

to better understand the biology of bone healing, which is relevant to early integration and long-term performance. With this refined understanding, we could engineer features that embrace biology before even a single prototype of OsseoShaper™ was made. This approach has made this new and exciting technology possible.

### How did that research influence the design?

Research at Stanford University showed how conventional high-speed drilling creates heat, causing bone cell death around the osteotomy,<sup>1</sup> and that this Zone of Death leads to bone resorption and remodelling. The common way to reduce heat is water irrigation. However, this has another drawback—it washes away the bone chips that can speed up peri-implant bone formation, which can help early osseointegration and stability. This is why we developed the OsseoShaper™ to operate at slow speed; it reduces the Zone of Death compared to a high-speed protocol and eliminates the need for water irrigation.<sup>1</sup> The OsseoShaper™ has also been designed for bone chips to remain inside the

**Fig. 1:** In most cases, site preparation for the N1™ implant system involves only two surgical steps: creating depth and angulation with the OsseoDirector™, then shaping the osteotomy with the OsseoShaper™. The OsseoShaper™ creates an implant site that reflects the macro-design of the N1™ implant.

**Fig. 2:** The OsseoShaper™ has also been designed for bone chips to remain inside the osteotomy.



Direct

Shape

Place

**OsseoDirector™ OsseoShaper™ Nobel Biocare N1™ implant**

osteotomy, and the benefits of this have already been shown in preclinical data.<sup>1</sup>


#### What kind of practical problems are associated with conventional drilling protocols?

Bone quality and quantity are unique in every patient. Decision making can be challenging, and we know that clinicians sometimes deviate from manufacturers' recommendations and modify the drill sequence to their own preference and judgement. So, we realised that modifying the site preparation procedure could help them make these important decisions and avoid guesswork—especially given that the fastest growing segment of clinicians offering implants place just 20–50 per year. We wanted an instrument that respects the need for ease of use, that provides a gauge to indicate bone quality and creates an implant site that reflects the shape of the implant. Site preparation should be an integral part of the implant system.

#### How does the OsseoShaper™ help clinicians take decisions when preparing the osteotomy?

The OsseoShaper™ torques determine surgical steps, so it reduces guesswork and decision making. This is made possible by the very slow rotation speed of 50rpm and no irrigation. Secondly, the implant site reflects the macro-design of the N1™ implant, enabling ideal stress distribution to the surrounding bone and implant stability for early and immediate loading.<sup>2</sup> Finally, in most cases,

the site preparation involves only two surgical steps: first creating the crucial depth and angulation with the OsseoDirector, then shaping the osteotomy with the OsseoShaper. We now have two years' clinical experience with this concept and, so far, almost 80% of all implants could be placed with just two site preparation steps.<sup>3</sup>



2

#### Have clinicians using the Nobel Biocare N1™ implant system seen any other benefits?

Absolutely. Clinicians have told us that patients really appreciate the reduced noise and vibration compared to conventional drilling.<sup>4</sup> So, patient comfort is greatly increased. And, for the clinicians, the low speed of site preparation gives them much greater control over this process.

*Author's note: The OsseoShaper™ is part of the Nobel Biocare N1™ implant system, introduced at the Global Symposium 2019 held in Madrid, Spain. For more information, visit [nobelbiocare.com/N1](http://nobelbiocare.com/N1).*

#### contact

**Nobel Biocare Services AG**  
P.O. Box  
8058 Zurich Airport, Switzerland  
Phone: +41 43 2114200  
[www.nobelbiocare.com](http://www.nobelbiocare.com)



Literature

# The **link** between oral disease and **oxidative stress**



“The link between oral disease and oxidative stress is still not that widely known.”

**Dr Lenka Banasova** runs her own dental centre, Pearl Dental, in the Slovakian capital of Bratislava, where she focusses on periodontics and implant dentistry. Most importantly, however, she is one of the few dentists to touch on the largely neglected topic of oxidative stress and its relevance to the fields of periodontology and implantology. In this interview, she explains how natural antioxidants—as contained in CURAPROX Perio Plus+—can improve therapy.

**Dr Banasova, could you explain to our readers what oxidative stress is?**

Oxidative stress is an imbalance of free radicals and antioxidants in the body, which can lead to cell and tissue damage. On the one hand, this occurs naturally and plays a role in the ageing process. The body's natural immune response can trigger oxidative stress temporarily. This type of oxidative stress causes mild inflammation that goes away after the immune system fights off an infection or repairs an injury. On the other hand, a large body of scientific evidence suggests that long-term oxidative stress contributes to the development of a range of chronic conditions. Such conditions include cancer, diabetes, heart disease, atherosclerosis, Parkinson's disease, periodontitis and many other diseases.

**Are there ways to avoid or reduce oxidative stress?**

Several risk factors contribute to oxidative stress and excess free radical production. These can include diet,

lack of exercise, smoking, alcohol consumption, certain conditions, such as obesity, medications, and environmental factors, such as pollution and radiation. While you can't completely avoid exposure to free radicals, you can make lifestyle choices regarding your diet, exercise, environment and so on to help keep your body in balance and prevent damage and disease. And this includes your oral health as well—and, I would say, patients are still not aware enough of how important oral health is for their general health. During recent years, we have seen a rise in oral disease related to oxidative stress.

**How familiar is the average dental professional with oxidative stress, though? Is it considered during diagnosis or treatment?**

All dentists know that oral health is an important aspect of overall well-being and that numerous systemic conditions and diseases have oral origins, but I think the link between oral disease and oxidative stress is still not that widely known. To give you an example: saliva acts as the first line of defence against free radicals through antioxidants, and in the event of an infection, increased generation of free radicals means they outnumber antioxidants to initiate oxidative stress. However, I have noticed that there are more and more studies and articles in the area of medicine and also in the field of dentistry that are mentioning oxidative stress. During diagnosis, patients' general condition and potential oxidative stress causes should be considered. Smoking for example is regarded

as one of the most significant risk factors for the development of periodontitis, as it can affect the alveoli, resulting in tooth loss, but it can also increase oxidative stress. And in the end, it is a risk factor that can be eliminated.

**Are you familiar with bioflavonoids and the role they can play in oral health?**

Bioflavonoids are natural sources of medicine and have antibacterial and anti-inflammatory or antioxidant properties. They neutralise viruses by stimulating white blood cells and lymphocytes and produce interferon, thereby stimulating the immune system. They are widely used in dentistry as an additional treatment after professional care, and they have many clinical benefits in other medical fields too.

**Perio Plus+ for instance contains CITROX, which is a mix of different bioflavonoids that act as antioxidants. Do you see potential for CITROX or other antioxidants in oral health products?**

CITROX is an antimicrobial whose components consist of soluble bioflavonoids derived from citrus fruits. Many recent studies have demonstrated that CITROX is effective in inhibiting the growth of a range of bacteria, such as *Aggregatibacter actinomycetemcomitans* and *Porphyromonas gingivalis*, the main actors in pathogenic flora in patients with periodontitis.

I see CITROX's potential as an addition to oral health products, and it is already being used in this way. However, it does not replace professional care. There has to be a proper protocol on treating the periodontitis by a dental professional first. Products containing chlorhexidine with other antioxidants are the best supplements to help patients reduce oral bacteria at home—of course, according to the dentist's instructions. When we treat periodontitis properly and the patient is compliant at home, the combination of providing optimal oral hygiene and these antimicrobial agents allows for a massive decrease in harmful bacteria in the oral cavity, an improvement of periodontal status and the stabilisation of oral health. As such, markers of oxidative stress can be reduced rapidly.

**contact**

**Dr Lenka Banasova**

Stromova 54  
83101 Bratislava, Slovakia  
lenkabanasova@hotmail.com

AD



Celebrate with ICD in Nagoya...and experience the wonders of Japan

The International College of Dentists' **CENTENNIAL FINALE**

November 11-13, 2020 Nagoya, Japan



International Council and Committee Meetings



Welcome Reception Garden Restaurant Tokugawaen



Symposium on ICD Humanitarian & Educational Programs



Magnificent Gala



International Induction Ceremony



Nagoya Tokyu Congress Hotel



Pre & Post Congress Tours Exclusively for ICD Registrants



For more information:  
icd100.org





bredent  
group

bredent medical

## Highest primary stability—now with conical-parallel connection

The new copaSKY implant line from bredent is particularly distinguished by the stable and retrievable conical-parallel-walled interface, which enables easy removal of the prosthetics. The unique neck design and short implant-abutment connection also allows ultrashort implants. Due to the deposition of bone chips on the backtaper, a subcrestal implant position can also be selected. copaSKY uses the same surgical tray as all other SKY implants. And the enhanced prosthetic offering one connection that fits all diameters of implants, simplifying storage and reducing inventory. The material of choice is BioHPP, which provides a natural chewing sensation and built-in shock absorber effect to

protect implants. Also new is the form-fit connection for bolted bridge components. The high accuracy of fit directs the lateral load directly onto the abutment, i.e. the risk of screw loosening and fractures is greatly reduced. The integrated angled screw channel provides excellent aesthetic results when transversally threaded.

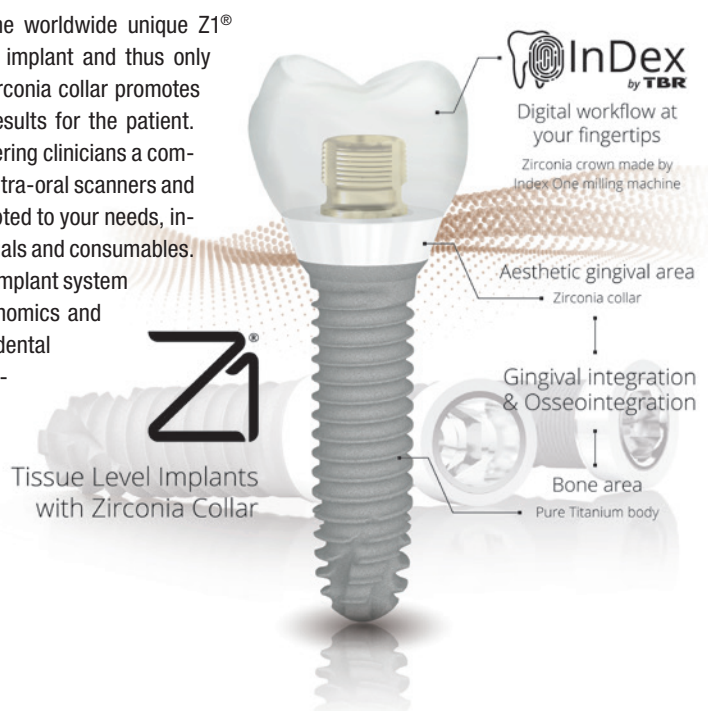**bredent medical GmbH & Co. KG**  
**Weißenhörner Straße 2**  
**89250 Senden, Germany**  
**[www.bredent-implants.com](http://www.bredent-implants.com)**

TBR Dental

## Tissue-level implant and digital workflow

Combining a titanium body and a zirconia collar, the worldwide unique Z1<sup>®</sup> implant offers many advantages. It is a tissue-level implant and thus only one surgical procedure is required. In addition, the zirconia collar promotes soft-tissue healing and provides optimal aesthetic results for the patient. With the launch of its new range Index, TBR is now offering clinicians a complete digital workflow: from the scanning phase with intra-oral scanners and CBCT devices to the milling phase with machines adapted to your needs, including suitable CAD/CAM software, associated materials and consumables. The virtuous combination of implantology with the Z1 implant system and the Index digital workflow ensures optimal ergonomics and shorter chair times, which is essential in the daily dental practice. Combine superior aesthetics and digital design with Z1 implants and TBR CAD/CAM Index dental solutions today!

**TBR Dental Group**  
**24, impasse René Couzinet**  
**31500 Toulouse, France**  
**[www.tbr.dental](http://www.tbr.dental)**





CAMLOG

## New implant line providing confidence in the field of immediacy

In close collaboration with practising surgeons, CAMLOG has developed a new implant line to meet the demands for shorter treatment times, earlier prosthetic restoration, and fewer sessions. The PROGRESSIVE-LINE implant is suitable for all indications. The outer geometry of the new implant line, which is available for both CONELOG® and CAMLOG® connections, is geared to facilitate the implementation of treatment concepts such as immediate placement and restoration. The PROGRESSIVE-LINE is coupled with highly efficient protocols for the implant bed preparation in all bone types. Well thought-out features of this apically tapered implant, prove to be particularly advantageous in soft bone. Threads down to the apex make PROGRESSIVE-LINE ideal for immediate implantation and a coronal anchorage thread helps to master complex situations in reduced bone height. Additional features encompass a broadened thread height with strongly engaging threads, and flexible drill protocols which allow to adapt the stability according to the needs of the treatment plan. In addition, advanced drill designs offer efficient implant site preparation in dense bone—without requiring additional tools or a tap.



**CAMLOG**  
**Biotechnologies GmbH**  
**Margarethenstr. 38**  
**4053 Basel, Switzerland**  
**www.camlog.com**

AD

## SUBSCRIBE NOW!

ceramic implants—international magazine of ceramic implant technology

Interdisciplinary, transparent & market orientated



ONLINE SUBSCRIPTION HERE



www.oemus-shop.de

## Fax: +49 341 48474-290

I would like to subscribe for the following journals:

- ceramic implants—international magazine of ceramic implant technology 2 issues p.a. € 30\*
- implants—international magazine of oral implantology 4 issues p.a. € 44\*

Terms & Conditions: The subscription may be cancelled in written form without due justification within 14 days of order by contacting OEMUS MEDIA AG, Holbeinstraße 29, 04229 Leipzig, Germany. Dispatching notification in good time will suffice. The subscription is automatically extended by another twelve months if it is not cancelled in written form 6 weeks prior to the end of the reference period.

\* All prices include VAT, shipping and handling.

\_\_\_\_\_  
Last Name, First Name

\_\_\_\_\_  
Company

\_\_\_\_\_  
Street, ZIP, City, Country

\_\_\_\_\_  
E-mail

\_\_\_\_\_  
Credit Card Number

\_\_\_\_\_  
Expiration Date

\_\_\_\_\_  
Security Code

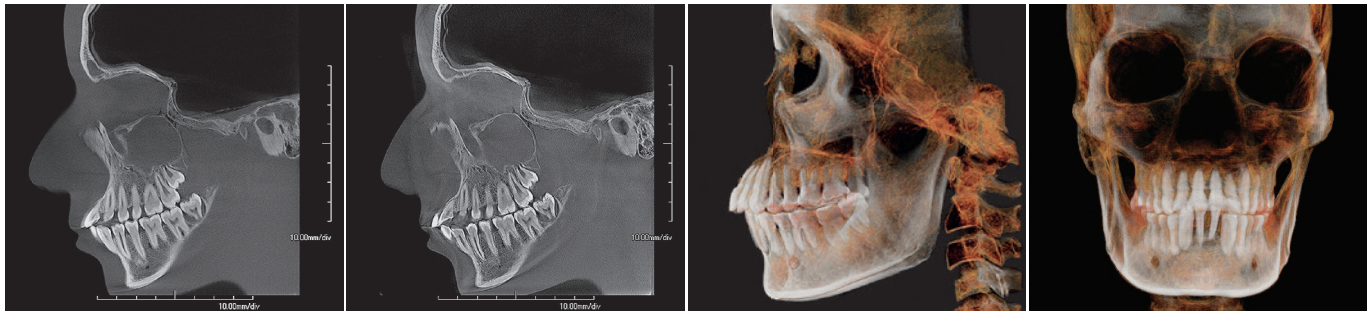
Stamp

\_\_\_\_\_  
Signature

implants 1/20

PreXion

## Superior 3D image quality with low radiation exposure



100µm voxel size.

74µm voxel size (PreXion3D EXPLORER).

3D image with a 150 x 160 mm field of view.

With many 3D-imaging systems today, good image quality is usually accompanied by high radiation exposure. Developed specifically for the European and US-American market, the new CBCT system PreXion3D EXPLORER offers the highest possible image quality at the lowest possible radiation levels. With a specifically controllable pulse generator, radiation is generated only when necessary to achieve the highest imaging quality. For a 20-second-long scan in ultra-HD 3D-mode, radiation exposure is only between 4.4 and 5.8 seconds. For a 10-second-long scan in standard scan 3D-mode, it is a mere 3.2 seconds. The small voxel size enables a more detailed representation of even the finest hard and soft tissue structures in ultra-high definition. The short image reconstruction times

ensure a seamless workflow. The PreXion3D EXPLORER convinces with easy handling and extensive planning programmes that cover the entire range of indications. With the 3D-analysis function, fields of view (FOV) sizes of 50 x 50, 150 x 80 and 150 x 160 mm can be generated, offering numerous flexible diagnostic options for oral surgery, implantology, periodontology, endodontics, orthodontics, and general dentistry.

**PreXion (Europe) GmbH**  
**Stahlstraße 42**  
**65428 Rüsselsheim, Germany**  
**[www.prexion.eu](http://www.prexion.eu)**

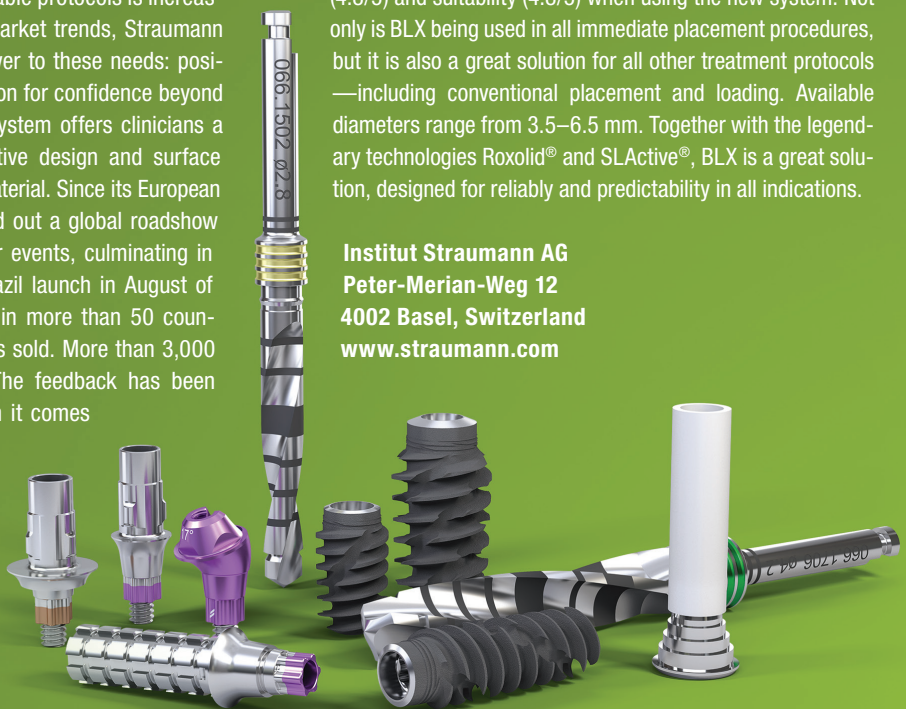Straumann

## BLX gains vast initial traction

Today, the demand for short and reliable protocols is increasingly growing. Always in line with market trends, Straumann set out to create a tailor-made answer to these needs: positioned as “the next-generation solution for confidence beyond immediacy,” the new BLX implant system offers clinicians a valuable tool that combines innovative design and surface technology with high-performance material. Since its European debut at IDS 2019, Straumann rolled out a global roadshow involving local launches and premier events, culminating in a successful North America and Brazil launch in August of 2019. The system is now available in more than 50 countries with over 150,000 BLX implants sold. More than 3,000 clinicians are already using BLX. The feedback has been incredibly positive, particularly when it comes to primary stability. Research into 615 cases found overall user satisfaction to rate at 4.5 out of 5. In addition, a study of practitioner attitudes at 12 dental practices reported high user satisfaction for primary stability (4.6/5), efficiency

(4.8/5) and suitability (4.8/5) when using the new system. Not only is BLX being used in all immediate placement procedures, but it is also a great solution for all other treatment protocols—including conventional placement and loading. Available diameters range from 3.5–6.5 mm. Together with the legendary technologies Roxolid® and SLActive®, BLX is a great solution, designed for reliability and predictability in all indications.

**Institut Straumann AG**  
**Peter-Merian-Weg 12**  
**4002 Basel, Switzerland**  
**[www.straumann.com](http://www.straumann.com)**



## Curaden

# Chlorhexidine, but not as you know it

CURAPROX Perio Plus+ is a pioneering range that is chlorhexidine, but not as you know it. The secret ingredient? CITROX. Research at Cardiff University has shown the unique synergy between chlorhexidine and CITROX—a natural agent extracted from bitter oranges that inhibits microorganisms known to cause infections in the oral cavity.

CITROX reduces chlorhexidine side effects such as taste disturbance and irritation, and its substantivity is prolonged by natural polylysine. The mouthwash comes in different chlorhexidine concentrations, ranging from 0.05 to 0.09 per cent for adequate treatment. The gel and toothpaste are perfect for localised treatment of wounds, infections or implant complications. Perio Plus+ products also contain hyaluronic acid, which supports tissue regeneration. Perio Plus+'s taste makes all the difference. A fresh

mint flavour minimises taste disturbance enhances patient compliance. Perio Plus+ contains no alcohol or sodium lauryl sulphate. For more info, visit [www.perioplus.com](http://www.perioplus.com).

**Curaden Germany GmbH**  
**Industriestr. 2–4**  
**76297 Stutensee, Germany**  
**[www.curaden.de](http://www.curaden.de)**

## Dentsply Sirona Implants

# Versatility with the Astra Tech Implant System EV



Dentsply Sirona Implants continues to deliver innovation, versatility and clinical benefits in implant dentistry, based on the needs of customers and centred around well-documented and clinically proven implant systems. With the latest product development, the Astra Tech Implant System—one of the most well-documented implant systems in the market today, documented in over 1,000 publications in peer-reviewed journals—just got even better: Astra Tech Implant EV has a revised implant design change that comes with significant advantages—with a deeper implant thread design apically, it is easier to reach preferred primary stability and the handling experience is enhanced for easy installation. With

this new change in design properties also comes the new name—Astra Tech Implant EV. The new implant line will be available in Europe in early 2020. Dentsply Sirona Implants continually strives to increase the application of implant therapy, based on science and without compromising safety and efficacy.

**Dentsply Sirona Implants**  
**Aminogatan 1**  
**41321 Mölndal, Sweden**  
**[www.dentsplysirona.com/implants](http://www.dentsplysirona.com/implants)**

## Bicon

# More than just an alternative to sinus lift and augmentation

The plateau design, which has been clinically proven for 35 years, and the self-locking tapered implant–abutment connection are the most important success factors of the popular Bicon SHORT Implant™ system. While screw implants can cause bone loss under unfavourable conditions, experts associate the so-called “plateau anchors” with possible bone gain. The plateau design, which offers at least 30 per cent more bone surface than comparable screw implants, makes all the difference. Studies indicate that the unique Bicon design favours the formation of mature lamellar Haversian bone. In addition, the biomechanical advantages of the plateaus optimise lateral force distribution, which supports bone preservation. The self-locking, bacteria-proof connection and the integrated platform-switching additionally promote the long-term success of the system in terms of function and aesthetics. With implant lengths of 5, 6, 8, and 11 mm, Bicon serves the entire range of indications in daily implant dentistry.



**Bicon**  
**501 Arborway**  
**Boston, MA 02130, USA**  
**[www.bicon.com](http://www.bicon.com)**





Register now!



Programme



## Ceramic implants—state-of-the-art Discussed in May in Berlin

The sixth Annual Meeting of the International Society of Metal Free Implantology (ISMI) will be held on 8 and 9 May 2020 in the Steigenberger Hotel Am Kanzleramt in Berlin, Germany. An internationally renowned team of speakers will craft a high-rate scientific programme. Dr Dominik Nischwitz, ISMI President and Scientific Director of the event, comments: “[...] the success of our international endeavours is underlined by the fact that the International Academy of Ceramic Implantology is the official partner of our conference.” Held under the theme “Ceramic implants – State of the art”, the two-day event will kick off on Friday

**ISMI** | INT. SOCIETY  
OF METAL FREE  
IMPLANTOLOGY




with two pre-congress symposia, involving the live streaming of a surgery. The highlight of the first congress day will be the ISMI White Night, held in the Beletage of the renowned borchardt in the heart of Berlin, where participants and speakers will be able to wind down in an informal atmosphere. Saturday will then be dedicated to scientific lectures. On both congress days the lectures will be simultaneously translated from German to English and vice versa.

**Source: OEMUS MEDIA AG**

## TV linked to sugar consumption and Rotten teeth in children

A new study discovered that young people are a third more likely to eat sugary foods (33%) and significantly more likely to have decaying teeth (39%), if they watch over 90 minutes of television each day. More than one in two (53%) children watching television for more than 90 minutes a day have some form of tooth decay. Youngsters who eat sugary foods while watching TV are also more than twice as likely to have decaying teeth than those who choose to avoid them. Dr Nigel Carter OBE, CEO of the Oral Health Foundation, believes there needs to be a change in the snacking culture around television: “There is a clear relationship between the time children spend watching television and how much sugar they are consuming. As a population, our children are having too much sugar too often and it is leading to unacceptable rates of tooth decay.” The study, titled “The influence of television on the food habits of schoolchildren and its association with dental caries” can be accessed online at [doi.org/10.1002/cre2.244](https://doi.org/10.1002/cre2.244).



© backup\_studio – stock.adobe.com

**Source: Oral Health Foundation**

## The 2020 Oral Reconstruction

# Global Symposium in New York City

From 30 April to 2 May 2020, the 2020 Oral Reconstruction Global Symposium will be held under the theme “20/20 Vision” at the iconic Marriott Marquis hotel in New York City. Organised by a joint European–American scientific committee, the event is an opportunity for dental professionals to learn about the latest treatment options from a global perspective while having a fun time with their colleagues in the heart of Manhattan. The internationally renowned line-up of over 40 speakers promises to cover a vast range of contemporary issues in implant dentistry and tissue regeneration. The programme will also include 16 breakout sessions on numerous dental topics, such as the digital workflow, immediate full-arch treatment, platelet-rich fibrin applications, hard- and soft-tissue grafting, immediate implant placement and temporisation, and prevention of peri-implant diseases. The sessions will be held in English, German, Spanish and Chinese. Visit [www.orfoundation.org/globalsymposium](http://www.orfoundation.org/globalsymposium) for more information on the event.

**Source: Oral Reconstruction Foundation**



## The 2020 Nobel Biocare Global Symposium

# To be held in Las Vegas

From 16 to 18 April 2020 the Nobel Biocare Global Symposium will be held in Las Vegas, NV, USA. Empowered by a combination of expert knowledge and innovative solutions that are elevating patient care, the event will be a unique opportunity for dental professionals to explore the future of dental implantology and digital dentistry. Dental professionals will be offered a great opportunity



to discover the latest in implant solutions, in addition to learning from some of the best clinicians in the world. The dynamic programme brings together more than 60 key experts from different fields of dental implantology and digital dentistry, offering several interactive podium discussions and engaging hands-on workshops. Also featured will be Envista's KaVo Kerr and Ormco brands including solutions such as CBCT digital imaging, powerful clinical and treatment software, clear aligners, and everything dentists need for a complete digital workflow. For more information, visit [nobelbiocare.com/symposia](http://nobelbiocare.com/symposia).

**Source: Envista**

## Bicon Digital Poster Competition: Register now and

# Win a trip to Boston

On the occasion of the Bicon World Congress 2020 on 12 and 13 June, 2020 in the Czech capital of Prague, Bicon is organising a Digital Poster Competition for the first time. Among other prizes, the winners will receive a trip to Boston, MA, USA, to the headquarters of the implant system manufacturer specialising in ultra-short implants. In addition, some of the best posters will be presented in short lectures in Prague and subsequently published in *implants—international magazine of oral implantology* (OEMUS MEDIA AG). The latter has been published for over twenty years in almost 100 countries worldwide. Bicon users are therefore invited to register for the “Digital Poster Presentation” at [bicon.dpp.online/landing](http://bicon.dpp.online/landing). A digital user account will then be created, where the poster data can be uploaded by the authors themselves. The prerequisite for successful participation in the Digital Poster Presentation is of course participation in the Bicon World Congress in Prague ([prague2020@bicon.com](mailto:prague2020@bicon.com)).

**Source: Bicon Europe Ltd.**

Register now!



DGZI supports practitioners in

## Becoming ABOI/ID Diplomates



In 2019 the American Board of Oral Implantology (ABOI) in the US decided to make the ABOI/ID Diplomate examination available for experienced dental

practitioners internationally. The ABOI has an independent examination committee chartered by the American Academy of Implant Dentistry (AAID), the official US partner of DGZI. The DGZI board has defined the necessary conditions. Graduates of the "DGZI Curriculum Implantology", as well as holders of both "Expert in Dental Implantology" and "Specialist in Oral Implantology" certification are now eligible to apply for this examination to become ABOI/ID Diplomates. DGZI can offer its support on request in preparing for the written and oral examination through a preparatory seminar, in which situations similar to an examination are played through and specific contents for the oral examination are conveyed. The

preparation for the written examination is based on our English language "Guide Book Implantology", which helps applicants to comfortably prepare for the examination via distance e-learning. The e-learning preparation can be started at short notice at any time. The first oral preparatory examination date is scheduled for the 50<sup>th</sup> International Annual Congress of DGZI, which will be held

on 6 and 7 November in Bremen, Germany, and to which you are cordially invited. The examinations will take place one day ahead of the congress, on 5 November 2020. If you are interested in this new offer, please contact Dr Rolf Vollmer (First Vice President and Treasurer of DGZI) for more information via e-mail at [info.vollmer@t-online.de](mailto:info.vollmer@t-online.de).

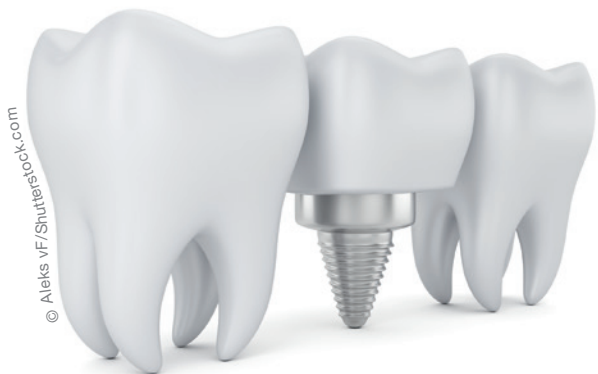Source: DGZI



Survival rates of

## Short implants investigated

Researchers from Miguel Hernandez University in Elche, Spain, evaluated the survival rates of 4x6 mm implants in fresh extraction sockets. The study involved 261 patients who had undergone implant surgery. The team analysed 167 single implants with a follow-up of over five years. The survival rate was 97.6% (98.8% in the mandible and 95% in the maxilla). The main cause of implant failure was found to be peri-implantitis (PI), which accounted for 69.2% of failures. The study found that for implants placed in sites



where horizontal regeneration had been performed (total of 46 implants), the survival rate was 100%. It was found that the survival rate of short implants is comparable with that of standard-length implants in the short and medium term. The authors note that the placement of immediate implants post-extraction is a risk factor for survival. The study, titled "Prospective study of 535 Astra 6 mm short implants with 1 to 9 years of follow up" can be accessed online at [onlinelibrary.eao.org](http://onlinelibrary.eao.org).

Source: EAO

PerioTrap—a highly specific

## Substance against periodontitis

Periodontitis is one of the most common infectious diseases in the world today. Under the leadership of Dr Mirko Buchholz, a team of researchers from the Fraunhofer Institute for Cell Therapy and Immunology in Halle (Saale) in Germany has now developed a highly specific antibiotic against the disease. According to Dr Buchholz, the active compound is effective in two ways: it can only be absorbed by the pathogens and it also only works on them. The active compound does not target the rest of the organism and thus fewer reserve antibiotics are needed. In this way, the new drug makes a major contribution to fighting the risk of multi-resistant germs. The effect of the substance is based on the blocking of an enzyme, which is required for the "nutrition" of the bacterium, and on a specific transport mechanism for iron. It has already been patented by the start-up company "PerioTrap

PerioTrap

MOLECULAR TROJAN HORSES  
SELECTIVE ANTIMICROBIALS  
FOR THE TREATMENT OF  
PERIODONTITIS



Pharmaceuticals". They are currently looking for investors in order to lead the product from the preclinical phase to market entry.

Source: Univations GmbH/Investforum Startup-Service

# ISMI

# INT. SOCIETY OF METAL FREE IMPLANTOLOGY



The innovative specialist society for modern metal-free implantology

## Become a member now!

### Advantages



#### Public relation work

Benefit from a strong community that supports your practice marketing through their public relation measures.

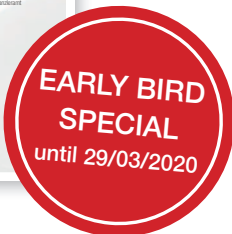#### Society's website including member profiles

Use the individualised member homepage and profit from a personal profile which ISMI provides free of charge to all active members. The patient platform of ISMI offers information for patients as well as a "dentists search & find" option and connects patients to the individual member homepages.



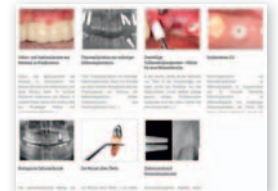#### Congress participation discount

Come and join us! Attend the Annual Congress of ISMI in Berlin on 8 and 9 May 2020 and receive further education provided by our partners for reduced participation fees for all ISMI members.



#### Online specialist archive

Get exclusive access to ISMI's comprehensive online archive. Discuss with experts and colleagues all questions concerning metal-free implantology and enjoy free access to the online archive and its subject-related training videos and case reports.




#### Newsletter

The ISMI newsletter informs you of the latest scientific trends, products, and events. It also provides user reports as well as a wide range of information and tips on the subject of metal-free implantology.

#### Specialist magazine

As a member of ISMI, your membership fee includes a subscription of the independently published English magazine "ceramic implants—international magazine of ceramic implant technology". Published twice a year, the magazine offers specialist articles and event reports as well as industry- and science-related news from the international world of metal-free implantology. In addition "ceramic implants" provides information on companies and their newest products.



ISMI e.V. Office Leipzig  
Holbeinstraße 29 | 04229 Leipzig | Germany  
Phone: +49 800 4764-000 | Fax: +49 800 4764-100  
office@ismi.me | www.ismi.me

Become a member now!





The Presidents of the ADA and FDI lent their organisations' support to the global launch of the College Centennial.

### The ICD expands

## Its educational initiatives

The International College of Dentists' (ICD; 12,000 members in 122 countries), advocates for humanitarian and educational oral health initiatives worldwide. The ICD and Washington University Dental Alumni Association offer annual scholarships to dental students, demonstrating concern about high dental education costs. Three inaugural scholarships of \$2,500 were awarded in 2019. ICD's Get Smart About Antibiotics programme raises awareness and shares resources about the global public health issue of antibiotic resistance, including a video that provides a free Continuing Education credit. ICD maintains key partnerships with the US Centers for Disease Control and Prevention and other entities to share critical data. The ICD has been honouring the world's leading dentists since 1920™ and celebrates its Centennial in 2020. Centennial events are taking place globally, concluding November in Japan with an international induction ceremony, gala banquet and humanitarian symposium. For more information, go to [www.ICD100.org](http://www.ICD100.org).

Source: ICD

### Second EACim Congress

## To take place in Brussels

Those who were not able to attend last year's congress of the European Academy for Ceramic Implantology (EACim) in Paris can already look forward to this coming spring: on Saturday, 25 April 2020, the second congress of the EACim will take place at the hotel Le Plaza in Brussels in Belgium. The congress, chaired by Prof. Carlo Maiorana from the University of Milan in Italy, will be held under the guiding theme "Large Reconstruction with Ceramic Implants" and comprise various lectures from internationally recognised speakers. In addition, one day ahead of the main congress, on

Friday, 24 April, there will be an optional workshop titled "Digital Workflow with Ceramic Implants" which interested participants can attend. The manufacturing companies bredent medical, CAMLOG, Nobel Biocare, Zeramex, ZiBone and Z-Systems will be supporting the congress as industry partners. More information on this year's event and the registration possibilities can be found online at [www.eacim-ceramic-implantology.com](http://www.eacim-ceramic-implantology.com).

Source: EACim



**EACim congress \ April 25, 2020**  
Hotel Le Plaza \ Brussels

Theme : **LARGE RECONSTRUCTION WITH CERAMIC IMPLANTS**

**ONLINE REGISTRATION**

[eacim-ceramic-implantology.com](http://eacim-ceramic-implantology.com)

Information: [info@cosyn.eu](mailto:info@cosyn.eu) \ Phone : + 32 477 41 32 98



# BECOME AN AUTHOR

for implants—international magazine of oral implantology



www.oemus.com

Interdisciplinary, transparent & market orientated



Become part of a successful network and benefit from a wide reach and high level of awareness

Please send back your fax form or contact Mr **Georg Isbaner**:  
g.isbaner@oemus-media.de  
Phone: +49 341 48474-123



## Fax: +49 341 48474-290

Yes, I want to become an **author** for implants—international magazine of oral implantology. I would like to submit an article on the following topic:

---

Yes, I want to become an **author** for ceramic implants—international magazine of ceramic implant technology. I would like to submit an article on the following topic:

---

\_\_\_\_\_  
Last Name, First Name

\_\_\_\_\_  
Street, ZIP, City

\_\_\_\_\_  
Phone, E-mail

Stamp

implants 1/20

# Congresses, courses and symposia



## 6<sup>th</sup> Annual Meeting of ISMI

8–9 May 2020  
Berlin, Germany  
[www.ismi-meeting.com](http://www.ismi-meeting.com)



## ITW World Symposium

14–16 May 2020  
Singapore  
[www.iti.org/worldsymposium2020](http://www.iti.org/worldsymposium2020)



## Bicon World Congress 2020

12–13 June 2020  
Prague, Czech Republic  
[www.biconprague.com](http://www.biconprague.com)



## DGZI International Annual Congress

6–7 November 2020  
Bremen, Germany  
[www.dgzi.de](http://www.dgzi.de)



## AAID Annual Conference

11–14 November 2020  
Atlanta, GA, USA  
[www.aid.com/Annual\\_Conference/](http://www.aid.com/Annual_Conference/)

# implants

international magazine of oral implantology

## Imprint

### Publisher

Torsten R. Oemus  
[oemus@oemus-media.de](mailto:oemus@oemus-media.de)

### CEO

Ingolf Döbbecke  
[doebbecke@oemus-media.de](mailto:doebbecke@oemus-media.de)

### Members of the Board

Jürgen Isbaner  
[isbaner@oemus-media.de](mailto:isbaner@oemus-media.de)

Lutz V. Hiller

[hiller@oemus-media.de](mailto:hiller@oemus-media.de)

### Chief Editorial Manager

Dr Torsten Hartmann  
(V. i. S. d. P.)  
[hartmann@dentalnet.de](mailto:hartmann@dentalnet.de)

### Editorial Council

Dr Rolf Vollmer  
[info.vollmer@t-online.de](mailto:info.vollmer@t-online.de)

Dr Georg Bach

[doc.bach@t-online.de](mailto:doc.bach@t-online.de)

Dr Suheil Boutros

[SMBoutros@aol.com](mailto:SMBoutros@aol.com)

### Editorial Office

Georg Isbaner  
[g.isbaner@oemus-media.de](mailto:g.isbaner@oemus-media.de)

Johannes Liebsch

[j.liebsch@oemus-media.de](mailto:j.liebsch@oemus-media.de)

### Executive Producer

Gernot Meyer  
[meyer@oemus-media.de](mailto:meyer@oemus-media.de)

### Product Manager

Timo Krause  
[t.krause@oemus-media.de](mailto:t.krause@oemus-media.de)

### Art Director

Alexander Jahn  
[a.jahn@oemus-media.de](mailto:a.jahn@oemus-media.de)

### Designer

Sandra Ehner  
[s.ehner@oemus-media.de](mailto:s.ehner@oemus-media.de)

Theresa Weise

[t.weise@oemus-media.de](mailto:t.weise@oemus-media.de)

### Customer Service

Marius Mezger  
[m.mezger@oemus-media.de](mailto:m.mezger@oemus-media.de)

### Published by

OEMUS MEDIA AG  
Holbeinstraße 29  
04229 Leipzig, Germany  
Tel.: +49 341 48474-0  
Fax: +49 341 48474-290  
[kontakt@oemus-media.de](mailto:kontakt@oemus-media.de)

### Printed by

Silber Druck oHG  
Otto-Hahn-Straße 25  
34253 Lohfelden, Germany

### implants

international magazine of oral  
implantology is published in cooperation  
with the German Association of Dental  
Implantology (DGZI).

### DGZI

DGZI Central Office  
Paulusstraße 1  
40237 Düsseldorf, Germany  
Tel.: +49 211 16970-77  
Fax: +49 211 16970-66  
[office@dgzi-info.de](mailto:office@dgzi-info.de)

[www.dgzi.de](http://www.dgzi.de)

[www.oemus.com](http://www.oemus.com)

[www.implants.de](http://www.implants.de)



## Copyright Regulations

implants international magazine of oral implantology is published by OEMUS MEDIA AG and will appear with one issue every quarter in 2020. The magazine and all articles and illustrations therein are protected by copyright. Any utilisation without the prior consent of editor and publisher is inadmissible and liable to prosecution. This applies in particular to duplicate copies, translations, microfilms, and storage and processing in electronic systems.

Reproductions, including extracts, may only be made with the permission of the publisher. Given no statement to the contrary, any submissions to the editorial department are understood to be in agreement with a full or partial publishing of said submission. The editorial department reserves the right to check all submitted articles for formal errors and factual authority, and to make amendments if necessary. No responsibility shall be taken for unsolicited books and manuscripts. Articles bearing symbols other than that of the editorial department, or which are distinguished by the name of the author, represent the opinion of the aforementioned, and do not have to comply with the views of OEMUS MEDIA AG. Responsibility for such articles shall be borne by the author. Responsibility for advertisements and other specially labeled items shall not be borne by the editorial department. Likewise, no responsibility shall be assumed for information published about associations, companies and commercial markets. All cases of consequential liability arising from inaccurate or faulty representation are excluded. General terms and conditions apply, legal venue is Leipzig, Germany.

# PROSTHETIC EFFICIENCY

## Straumann® Ceramic Healing Abutments The first step to harmonious soft-tissue healing.

First Ceramic  
Healing Abutment  
in Straumann history!

straumann



### FAVORABLE SOFT-TISSUE ATTACHMENT

With blood  
circulation similar to  
that around natural  
tooth.<sup>1,2\*</sup>



### DESIGNED FOR HEALTHY PERI-IMPLANT ENVIRON- MENT

Less plaque  
attachment.<sup>2,3,8-9\*</sup>



### ESTHETICS FROM THE DAY OF SURGERY

Ceramic for healing  
phase and final  
restoration.



### EASE OF USE

Aspiration-security  
and color-coding

\*references on [www.straumann.com/ceramic-healing-abutments](http://www.straumann.com/ceramic-healing-abutments)



Contact your local Straumann representative  
now or visit

[www.straumann.com/ceramic-healing-abutments](http://www.straumann.com/ceramic-healing-abutments)

A0022/en/A/00 12/19



GLOBAL  
Symposium  
April 16-18, 2020  
LAS VEGAS by  
Envista

# See the future unveiled

**Experience the innovations set  
to reshape implantology.**

Join us for three science-focused days with key  
industry speakers and exciting hands-on sessions.

April 16-18, 2020, Mandalay Bay Resort, Las Vegas.

[nobelbiocare.com/symposia](https://nobelbiocare.com/symposia)

Sharpen your skills

Be one of the first to know

Expand your network

Scan  
to learn more  
and register

