

Complex management of drug-induced gingival hyperplasia

Dr Mihail Tanev¹, Dr Georgi T. Tomov¹, Bulgaria & Jyuhn H. Ke², Taiwan

¹ Department of Periodontology and Oral Disease, Faculty of Dental Medicine, Medical University of Plovdiv, Bulgaria

² Institute of Mechanical and Electrical Integration, National Taipei University of Technology, Taiwan

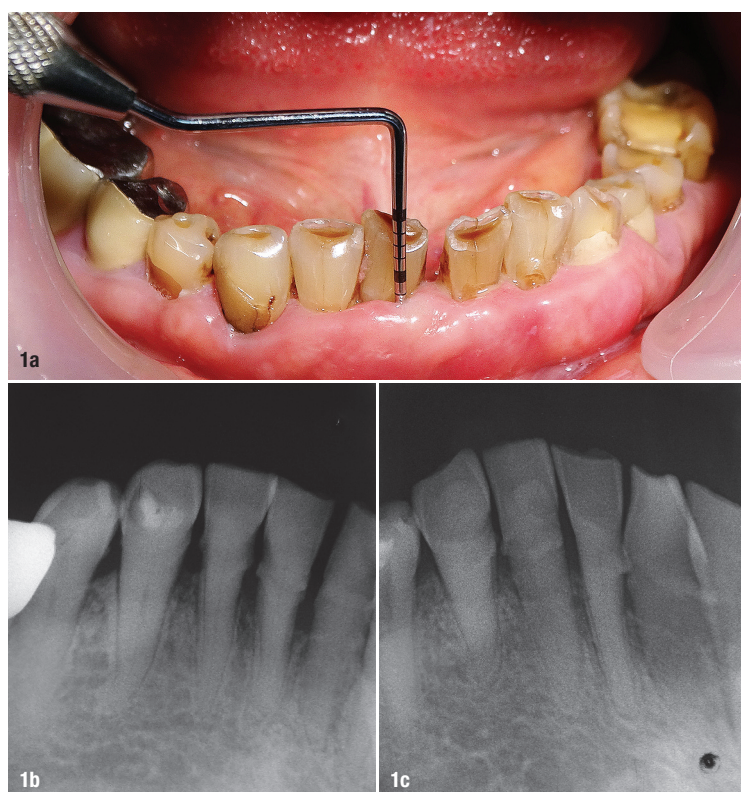


Fig. 1a: Preoperative view of soft tissues and estimation of periodontal probing depth with a CP-15 probe. **Figs. 1b & c:** Radiographic evaluation of the mandibular anterior region, showing approximately 2 mm of attachment loss, subgingival calculus and carious lesions.

Introduction

Drug-induced gingival overgrowth or enlargement occurs as a part of the systemic therapy of some non-dental conditions.¹ It occurs as an adverse effect following administration of drugs such as calcium channel blockers, anticonvulsants, specific immunosuppressants, among others.¹ The existence of specific oral and extra-oral factors (age, genetic predisposition, presence of pre-existing plaque and gingival inflammation) determine the interaction between the drugs and gingival tissue. However, the gingival response in patients can vary in severity and scope. Drug-induced gingival overgrowth impairs

proper hygiene habits, lowers the aesthetic profile of the dentition and creates a suitable environment for further plaque formation and aggravation of pre-existing periodontal conditions. As of yet, there has been not enough data and research findings which could consolidate the challenging management of affected patients. There is a clear need for developing new and reproducible clinical treatment protocols, committed to recent advancements made in dental technology. The aim of this case report is to demonstrate a comprehensive treatment protocol of drug-induced gingival overgrowth, employing different treatment modalities.

Case presentation

A 57-year-old female patient was referred to the Laser Center in the Faculty of Dental Medicine of the Medical University of Plovdiv in Bulgaria, with the complaint of the unaesthetic appearance of gums in the mandibular anterior region, along with occasional bleeding when brushing and overall difficult oral hygiene in the region (Fig. 1a). After obtaining written consent for diagnostics and treatment, a thorough dental history was taken. The patient revealed she suffers from hypertension (high blood pressure) which has been treated by means of a calcium channel blocker (Amlodipine) for more than five years. The rest of the medical history was non-contributory.

Periodontal assessment of the patient revealed firm and nodular attached gingiva in the anterior mandibular region covering over one-half of the clinical crowns with clinical signs of inflammation: redness as well as bleeding upon gentle probing was noted and loss of stippling and rolling of the free gingival margin was visible. Its position was estimated coronally from the CEJ (cemento-enamel junction). Consecutively, periodontal charting was performed, presenting pocket probing depths around 6 mm in the anterior mandibular region and 4–5 mm in the rest of the dentition. The radiographic examination of the dentition revealed initial periodontal involvement with clinical attachment loss of around 2 mm throughout (Figs. 1b & c). Based on the collected diagnostic data, the observed pocketing in the anterior mandibular

region was deemed pseudo-pocketing, classified as grade 2 in the modified index system of Angelopoulos & Goaz (1972); see Table 1.

The active treatment protocol continued with devising a treatment plan consisting of two distinct phases: initial periodontal therapy and corrective periodontal therapy. Initial treatment consisted of thorough scaling and root planing by means of ultrasonic devices and manual instrumentation. The patient's oral hygiene habits were discussed and a 0.12% chlorhexidine solution was prescribed. After two weeks, the patient was recalled for corrective treatment. The corrective protocol involved three procedures, each scheduled one week apart.

Procedure 1

Er:YAG laser-assisted gingivectomy and gingivoplasty (2,940 nm)

The gingivectomy was performed according to a standard surgical protocol. Local anaesthesia was infiltrated, before the bleeding points were marked with Crane-Kaplan forceps. The gingivectomy was performed 1.5 mm apically from the bleeding points with a continuous excision bevelled at 45°. The excision was done with Er:YAG laser system (LiteTouch, Syneron Dental) at a wavelength of 2,940 nm (Figs. 2a & b). A chisel-type tip was used with high water cooling at an energy level of 300 mJ/18 Hz in contact mode. The consequent gingivoplasty consisted of

Grade	Hyperplasia	Size	Tooth coverage
0	No	Normal	No
1	Minimal	<2 mm	Cervical third or less
2	Moderate	2–4 mm	Middle third
3	Severe	>4 mm	More than 2/3rd

Table 1: Degree of gingival hyperplasia according to modified index by Angelopoulos & Goaz (1972).

beveling and smoothing of the excised margin, until a festooned knife-edge gingival contour is achieved (Fig. 2c). The gingivoplasty was performed using a 1.3 x 19 mm laser tip and the laser set at 200 mJ/15 Hz in non-contact mode with high water cooling. Upon finishing the procedure, a periodontal dressing (Peripac, Dentsply DeTrey) was placed inside the patient's mouth and she was given thorough instructions for post-op care (Fig. 2d).

Procedure 2

Antibacterial photodynamic therapy with an 810 nm diode laser

After two weeks, the epithelisation process finalised uneventfully (Fig. 3). However, signs of inflammation were

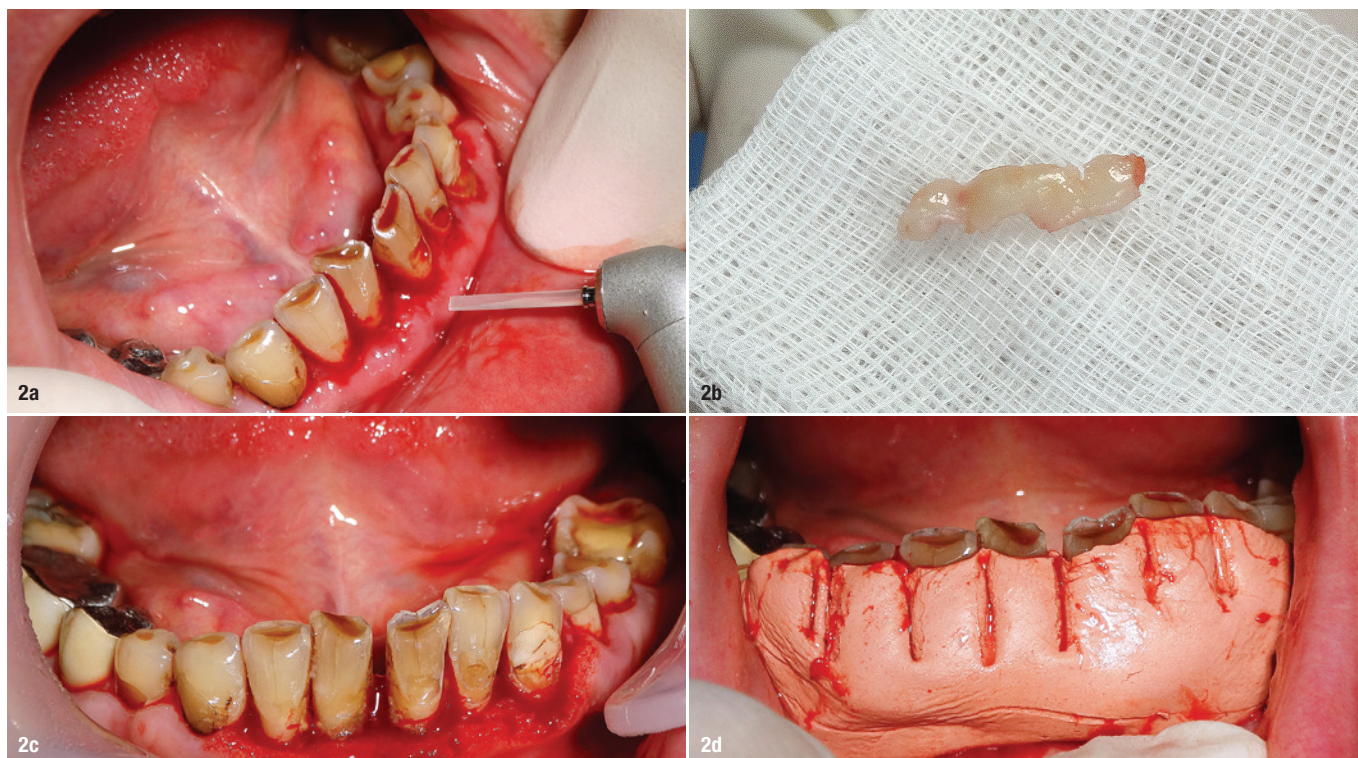


Fig. 2: Performance of gingivectomy with Er:YAG laser (a); view of the excised soft tissue (b); immediate postoperative view of the treated area (c); placement of periodontal dressing (d).

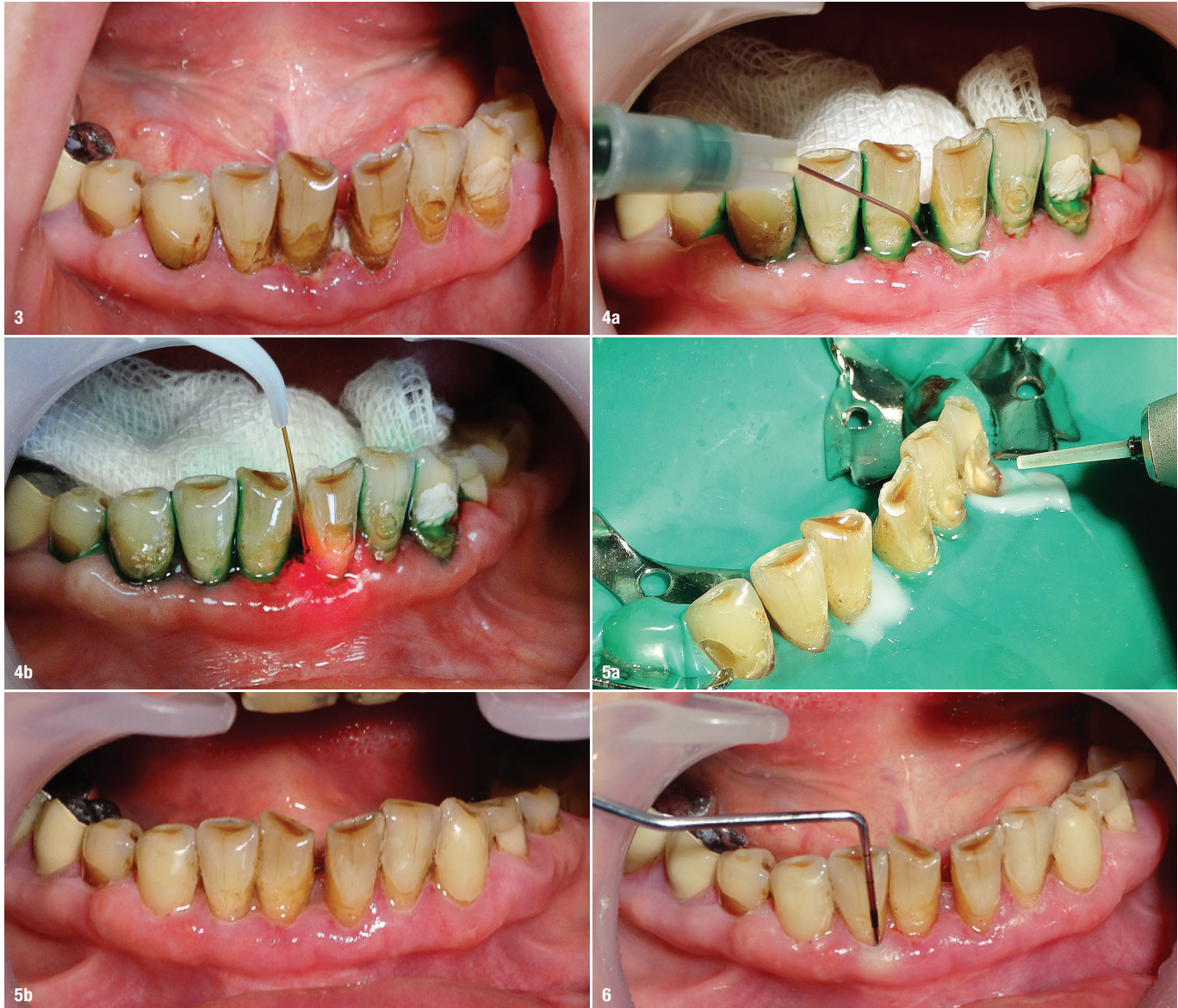

Fig. 3: Postoperative view of the soft tissues after 14 days. **Fig. 4a:** Application of indocyanine green dye. **Fig. 4b:** Light activation of the dye with 810 nm diode laser. **Fig. 5a:** Er:YAG laser-assisted tooth structure preparation for adhesive obturation. **Fig. 5b:** Postoperative result after three weeks. **Fig. 6:** Periodontal status after six months.

still visible, thus indicating the need for antibacterial photodynamic therapy (aPDT). This is a novel approach in supplementary periodontal treatment. It involves the application of a specific dye into the periodontal pockets, which—when activated with a specific light wavelength—dissipates into reactive oxygen species (ROS). In the periodontal pockets, ROS have high cytotoxic properties against most of the periodontal flora. aPDT is a non-thermal and non-invasive local therapy, bearing numerous beneficial effects. For this case, aPDT was performed using indocyanine green dye (EmunDo; Fig. 4a), mixed ex tempore and activated with an 810nm diode laser (Syneron Dental; Fig. 4b). Indocyanine green is a fluorescent dye with an absorption spectrum of between 750 and 850nm wavelength. Hence, a diode laser system operating at a wavelength of 810nm is deemed its op-

timal light activation. When activated, indocyanine green is highly toxic to most anaerobic periodontal flora. Photodynamic activation was performed three times for a duration of 20 seconds per tooth.

Procedure 3

Er:YAG laser-assisted cavity preparation and composite obturation

However, after soft-tissue contouring, many carious and non-carious lesions were evident, acting as plaque-retentive factors. The teeth were prepared for obturation with the Er:YAG laser (LiteTouch) with a 1.0 x 17 mm tip, set to non-contact mode, 200mJ/20Hz, and water cooling. Laser preparation of tooth structures is vastly more conservative and effective due to the water absorption

peak of the Er:YAG wavelength. After preparation, the cavities were obturated according to a standard adhesive protocol with a nano-filled composite (G-ænial Anterior, GC Europe; Figs. 5 & 6).

Discussion

Drug-induced gingival hyperplasia is a soft-tissue condition that often requires a complex treatment approach.² In most cases, the enlarged gingival tissue presents a suitable environment for the growth of a pathogenic periodontal flora and impairs oral hygiene efficacy, thus aggravating a pre-existing periodontal condition. In some cases, the drug-tissue interaction cannot be avoided or substituted with another medicament, which ultimately creates a therapeutic challenge. Surgical excision of the hyperplastic tissue in the form of a gingivectomy is the procedure of choice in this context.² Implementation of laser-assisted protocols in both surgical and supplementary treatment provides a vast number of advantages over standard procedures.³

In the soft-tissue surgical phase Er:YAG lasers provide high cutting efficacy with minimal to no thermal damage to the tissue, improved healing and better post-op comfort for the patient.³ Erbium-doped lasers can be used in non-contact mode along with water cooling, thus improving the field of view of the operator. Er:YAG laser systems have the highest absorption peak in water molecules, thus rendering them as one of the most sophisticated surgical systems for soft-tissue interventions. This is well presented in a secondary surgical procedure—the gingivoplasty. Gingivoplasty is the surgical recreation of the thin, scalloped, knife-edge contour of the gingival tissue. Traditionally, this is performed with a diamond bur, which causes thermal (frictional) and mechanical trauma to the soft tissue.⁴ With Er:YAG laser systems, a gingivoplasty is performed in a non-contact minimally invasive fashion without thermal or mechanical trauma to the soft tissue.⁴ The achieved contour is much more delicate and provides faster healing. Er:YAG laser systems are the only ones suitable for hard-tissue preparation, owing to their water molecule absorption peak. Er:YAG laser-assisted tooth preparation is a minimally invasive, non-contact process which does not create a smear layer on the hard tooth structure, improving the adhesive protocol of obturation as a result.


Antibacterial photodynamic therapy is a novel approach in supplementary periodontal treatment.⁵ It relies on the photoactive properties of some dyes, which when activated (through a specific light wavelength) release an array of ROS. ROS, in turn, have highly specific cytotoxic effects on the bacterial cells. The photochemical reaction in its essence is purely oxidative, thus creating oxidative stress on bacterial membranes. Antibacterial photodynamic therapy is a local, non-thermal and non-in-

vasive supplement to the standard protocols of non-surgical periodontal treatment.⁵ The high selectivity of this method depends on two main factors: photoactive dye and light source. Lasers are especially suitable for photodynamic therapy, since they provide a monochromatic, coherent light beam with a fixed wavelength. In this case, indocyanine green was selected for its proven efficacy against Gram-negative anaerobic flora (predominantly found in periodontal pockets). As the dye's highest absorption peak ranges between 750 and 850nm, a diode laser with a wavelength of 810nm was selected as a light source for the photodynamic reaction.

Conclusion

A treatment plan that includes complex laser-assisted modalities for treating drug-induced gingival hyperplasia offers a plethora of benefits outcome-wise. However, insufficient knowledge of light-tissue interaction and the optical properties of some structures and substances in the oral cavity can limit the clinician's scope of treatment with laser light.

Acknowledgement: This work is a part of an intramural project funded by the Medical University of Plovdiv under Grant No DPDP-04/2019.



about the author



In 2004 **Dr Georgi T. Tomov** graduated from the Medical University of Plovdiv, Bulgaria, with Summa cum laude for his Master's degree in Dental Medicine. In 2009, after the defense of a doctoral thesis, he obtained a PhD degree. He has two specialties – endodontics (2008) and periodontology (2019). Currently, Georgi Tomov is Head of the Oral

Pathology Division and the Director of the Laser Center at the Faculty of Dental Medicine, Plovdiv. The scientific interests and clinical practice of Dr Tomov are focused on endodontics, periodontology, oral pathology and laser applications in dentistry.

contact

Dr Georgi T. Tomov

Head of the Department of Oral Pathology
Faculty of Dental Medicine
Medical University of Plovdiv, Bulgaria
dr.g.tomov@gmail.com

