

The key to optimal implant aesthetics

Dr Kunal Shah, UK

Initial clinical situation

A 58-year-old male patient presented with a dental gap where tooth #15 had been missing for many years. He had been recommended to the practice by another patient. He was fit and healthy with an unremarkable medical history. Having undergone extensive restorative treatment in the past, the patient was very aware of the different procedures that are currently available to restore teeth. As such, the challenge of this case was to effectively manage the patient—the restorative aspect of treatment was crucial to success, especially as the patient had high expectations of the overall result. All treatment options were discussed with the patient, including the advantages and disadvantages of each. The patient chose a dental implant, as he preferred a fixed solution. The different types of implants available were then discussed with him, including bone and tissue level systems. It is important for clinicians to explain treatment options to this level of detail, as patients need to know what each dentist can offer them and/or what else they could access through professional referral. Many patients are also very conscious of what will be put in their mouths.

As improved aesthetics could be achieved with its zirconia collar design, the patient decided on the Z1 implant system from TBR Dental. This was the most superior, yet cost-effective, option compared with the alternatives

offered. As the Z1 is a tissue level system, the surgical site does not have to be reopened for the implant to be accessed in order for the clinician to remove the cover screw and replace it with a healing abutment. This saves the patient from having to attend an additional appointment for this, thereby maximising on valuable chair time. Furthermore, the Z1 enables the clinician to place the implant in one surgical step, which helps optimise operating room planning and sterilisation protocols, making the Z1 much more convenient for patient and practitioner. The versatility of the Z1 also optimises stock management for practices and helps to minimise maintenance treatments for patients. In addition, the Z1 itself was more affordable than the other implant systems that were offered to the patient in this case, providing further cost-saving benefits. Modern patients are increasingly more price-conscious, so they need solutions that can achieve the best clinical outcomes while meeting their budget.

Treatment planning

Standard treatment planning protocols were followed. This involved taking a cone beam computed tomography scan to assess the sinus and bone level, as well as to provide a 3D view of the proposed surgical site for improved visualisation. A comprehensive assessment confirmed that there was adequate width and height of bone to place an implant. Digital software ensured that the treatment planning process was very precise. A 4.0 x 10.5mm tissue level Z1 implant was planned for, as this solution provides excellent aesthetics and, in this case, did not require a bone grafting procedure prior to surgical placement. Every aspect of treatment was discussed with the patient before informed consent was obtained for treatment to begin.

Implant placement

Surgery proved to be unremarkable. A delayed implant placement protocol was followed, which involved making a small incision in the gingiva and raising a flap. The surgical site was cleaned and prepared for the implant to be placed successfully and achieve primary anchorage. The zirconia collar was sunk 1 mm into the bone to pro-

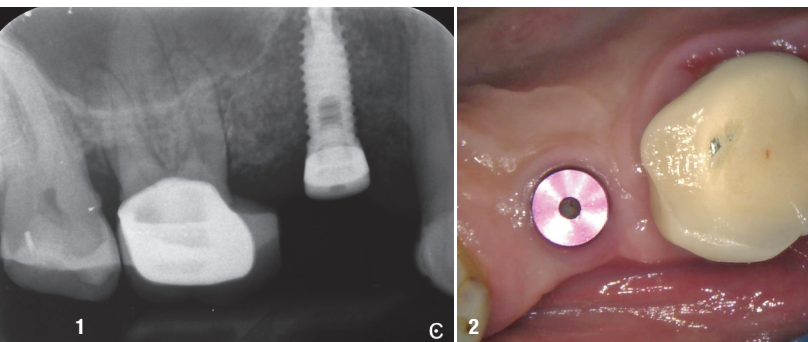
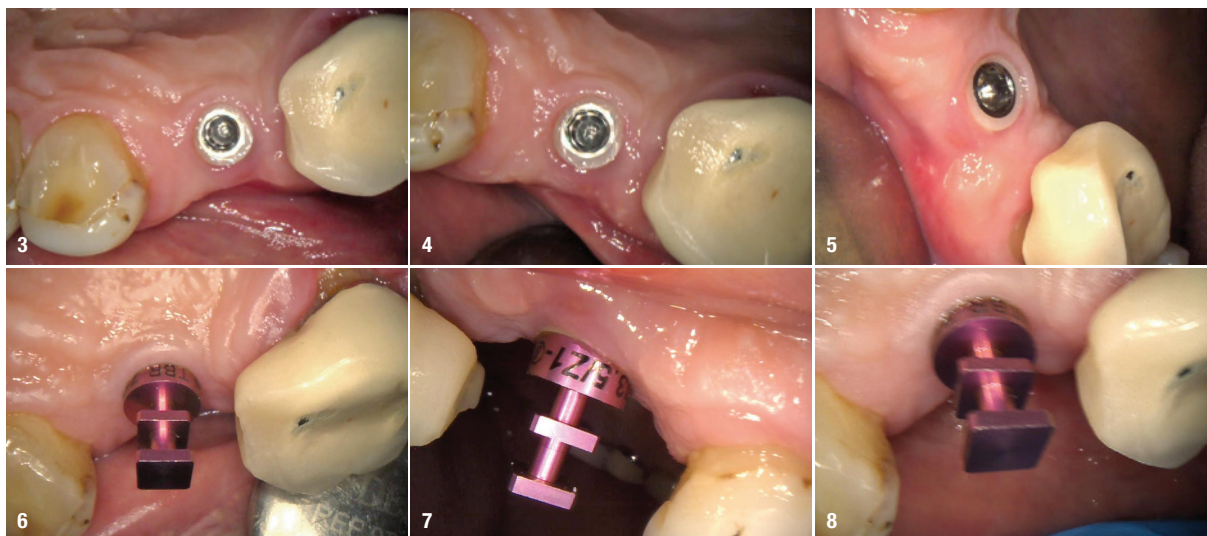


Fig. 1: Periapical radiograph showing the Z1-infinity implant in position #15 at the three-month review. **Fig. 2:** Intra-oral photograph showing the Z1-infinity implant with a cover screw in position #15.



Figs. 3–5: Intra-oral photograph showing the Z1-infinity implant with the cover screw removed. **Figs. 6–8:** Intra-oral photograph showing the Z1-infinity implant with a SwissClip impression coping for the closed-tray approach.

vide additional stability and boost aesthetics by promoting a good emergence profile. This was accomplished by using the countersink drill in the implant kit. A healing cap was not required owing to the transgingival nature of the implant and the design of the zirconia collar, so a cover screw was placed post-surgery. The surgical site was then assessed before the patient was sent away with appropriate post-surgery care instructions to take anti-inflammatories and antibiotics to aid the healing process and prevent infection.

Restoration

After a healing period of three months, the implant was evaluated and found to have achieved excellent stability (Fig. 1). The soft tissue around the implant was also pink with no inflammation, indicating that it had healed well and was healthy (Fig. 2). The cover screw was removed (Figs. 3–5) in order to fit a TBR SwissClip impression coping (Figs. 6–8). This is a very efficient and convenient solution that is quicker than traditional methods of taking an impression, as it simply clips on to the implant. A closed-tray impression was taken, alongside a digital scan, which were both sent to the laboratory to produce a screw-retained IPS e.max crown (Ivoclar Vivadent). The patient chose an implant-retained crown that was a whiter shade than his existing restorations, as he was keen to replace these in the future.

The patient later returned to the practice for the placement of the definitive restoration. The porcelain-fused-to-metal crown was seated (Figs. 9–11) and the access hole was sealed with PTFE tape, before being filled with a temporary dressing (Fig. 12). After a week, this was removed and the crown tightened to 25–30Ncm. The screw access hole was then sealed with PTFE tape and

composite. Clinical and radiographic assessments after implant restoration showed optimal aesthetics and osseointegration (Fig. 13). The patient was very happy with the final outcome.

AD



Latest 3D ultrasound technology for dentists

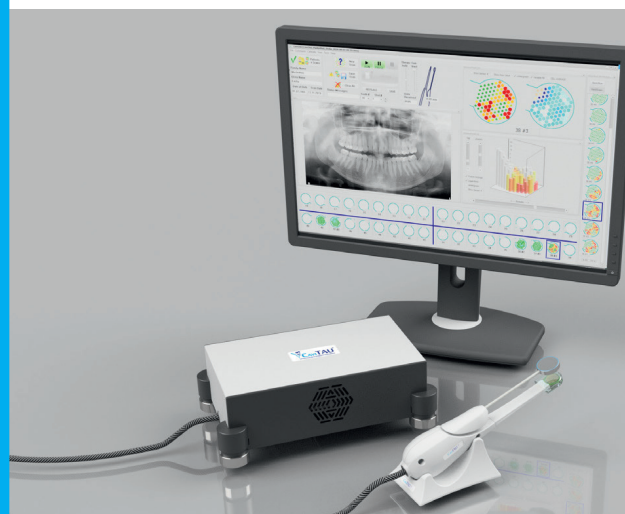

Illustration of bone density
Checking the bone bed before implantation
Identification of jawbone cavities

Register & Order:
shop.cavitaude.de

CaviTAU® GmbH | Grünwalder Str. 1 | 81547 Munich | Germany
 Ph. +49 89 244 15 44 60 | F. +49 89 244 15 44 69
www.cavitaude.de | office@cavitaude.de

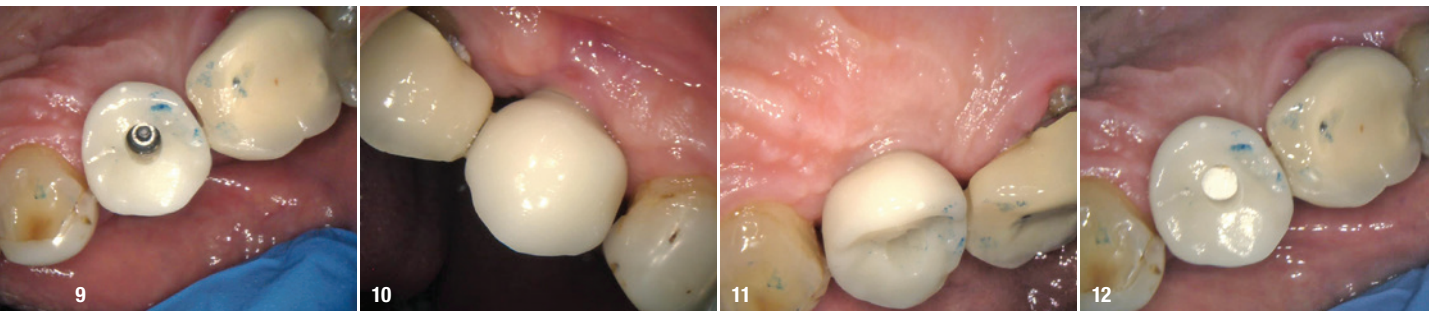


Fig. 9: Intra-oral photograph showing the screw-retained implant crown seated. **Fig. 10:** Intra-oral photograph showing the screw-retained implant crown seated, buccal view. **Fig. 11:** Intra-oral photograph showing the screw-retained implant crown seated, palatal view. **Fig. 12:** Intra-oral photograph showing the screw-retained implant crown seated with PTFE tape to protect the access hole.


Discussion

In this case, the zirconia collar of the Z1 acted as a healing abutment for the implant to encourage gingival flaring and soft-tissue healing for a good gingival profile to develop. This meant that a cover screw could be fitted to the implant and left for three months to achieve excellent osseointegration. Simultaneous healing of the hard and soft tissue further emphasised the time-saving benefits that the Z1 provided throughout this case. The zirconia collar also promoted gingival attachment and served as an antibacterial shield to the crestal bone to prevent iatrogenic inflammation and infection.^{1,2} This is the only implant system that encourages natural gingival growth, whereas other solutions tend to result in gingival recession over time. Moreover, there are fewer surgical steps involved with placing the Z1, as the clinician does not need to reopen the surgical site to access the implant for the restorative phase of treatment.

Conclusion

The success of a dental implant is always based on planning treatment correctly. It is also important to offer an

implant solution that caters to the needs of the patient. Together, these elements can ensure outstanding results, as was demonstrated in this case. The unique design of the Z1 enabled placement of the implant at tissue level, thus minimising the number of surgical steps required, which ultimately ensured treatment was less invasive and more convenient for the patient.



about the author



Dr Kunal Shah is the principal of LeoDental in London. He graduated from the University of Birmingham in the UK, was selected as a finalist for Young Dentist of the Year—South in the Dental Awards 2018 and has the accolade for the best implant and imaging clinic in London in 2018. He has a keen interest in the topics of digital dentistry, implantology and restorative dentistry specific to direct resin composites and impression materials, and has published several articles in the professional press and lectured internationally. Dr Shah is also a clinical mentor for students on the year-long postgraduate implant course at LeoDental in conjunction with SmileTube.tv.

implantology and restorative dentistry specific to direct resin composites and impression materials, and has published several articles in the professional press and lectured internationally. Dr Shah is also a clinical mentor for students on the year-long postgraduate implant course at LeoDental in conjunction with SmileTube.tv.

contact

Dr Kunal Shah
LeoDental
 Bell Lane Dental Practice
 19 Bell Lane, Hendon, London
 NW4 2BP, United Kingdom
 Phone: +44 20 82033155
 referral@leodental.co.uk
 www.leodental.co.uk

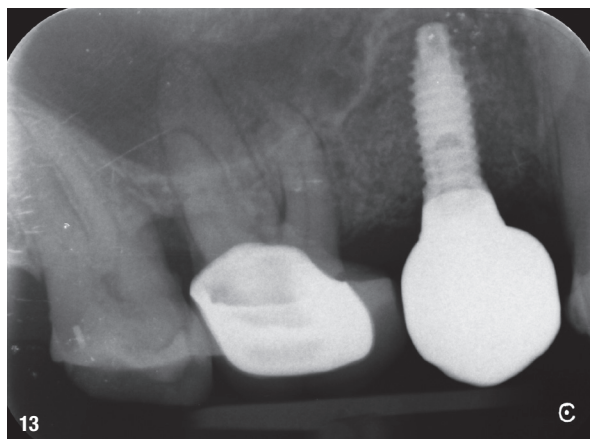


Fig. 13: Post-op periapical radiograph showing the screw-retained implant crown seated.

50 Years – From single Implant to digital Workflow

VISIONS IN IMPLANTOLOGY

3RD FUTURE CONGRESS FOR
DENTAL IMPLANTOLOGY

6–7 November 2020

Maritim Hotel & Congress Centrum Bremen/Germany

DOWNLOAD
REGISTRATION FORM



event@oemus-media.de

Premium partner:

camlog

group

Geistlich
Biomaterials

Dentsply
Sirona

VISIONS IN
IMPLANTOLOGY

BREMEN

6–7 November 2020

50th DGZI INTERNATIONAL ANNUAL CONGRESS
3rd FUTURE CONGRESS FOR DENTAL IMPLANTOLOGY

 **DGZI**
Deutsche Gesellschaft für
Zahnärztliche Implantologie e.V.

Simultaneous translation German/English.
Register now and get your early bird special:
event@oemus-media.de



 **DGZI**
Deutsche Gesellschaft für
Zahnärztliche Implantologie e.V.