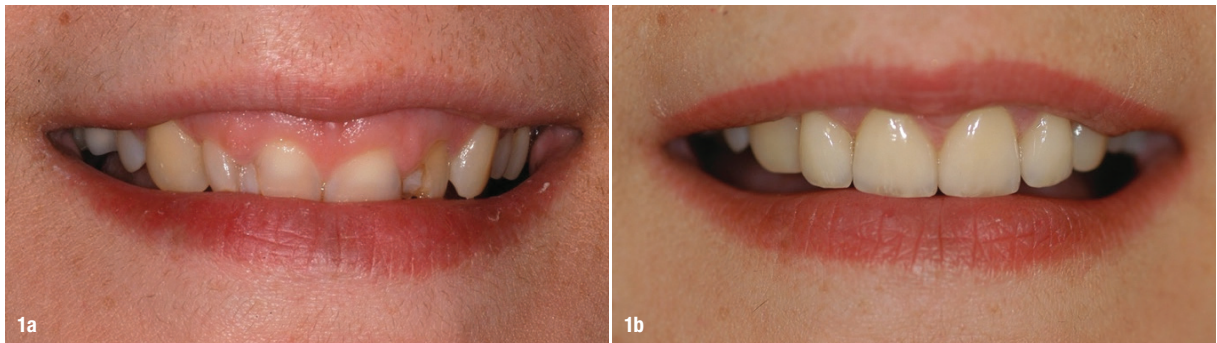


Pre-prosthetic periodontal plasty with the Er:YAG laser

Dr Fabrice Baudot, France



Figs. 1a & b: Pre-op situation: unattractive gingival smile and alteration of dental structures (a), post-op situation (b).

A **minimally invasive** approach is a global philosophy that has extended to all medical disciplines (there have been nearly 100,000 publications on this subject since 1992), and periodontics is not at the margin of this general trend. The objectives of this approach are to improve the operative and postoperative comfort of patients and to optimise the results of interventions. The Er:YAG laser is a microsurgical tool in the service of this concept. Thanks to its novel operating mode, it allows the clinician to perform operations in accordance with all the criteria of a minimally invasive approach. Tissue is treated on the basis of respecting vascular and anatomical structures in a microsurgical manner, thus reducing postoperative effects and improving the reliability of the results.¹ To illustrate the microsurgical operative capacities of the Er:YAG laser, we present in the following

a clinical case of pre-prosthetic periodontal preparation which was performed by tissue sculpting and without a flap.

Case presentation

The female patient came to the consultation for an aesthetic and functional evaluation of the maxillary anterior sector. She complained about the condition of her teeth and the unattractive appearance of her gummy smile. She had received several professional opinions before, and all of them included crown lengthening surgery by osteotomy via a full-thickness access flap. This prospect frightened the patient, which was why she was looking for an alternative approach. We suggested Er:YAG laser-assisted pre-prosthetic periodontal plasty under an operating microscope.

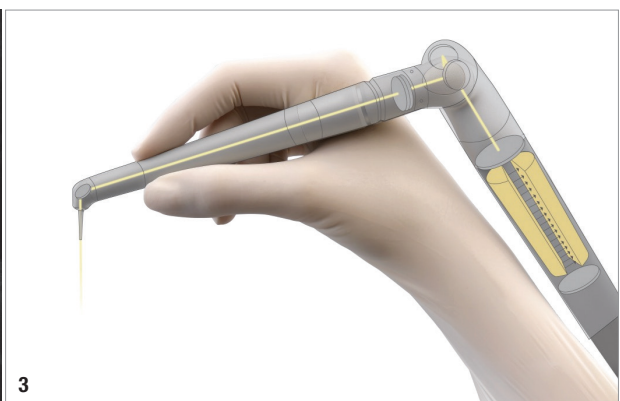
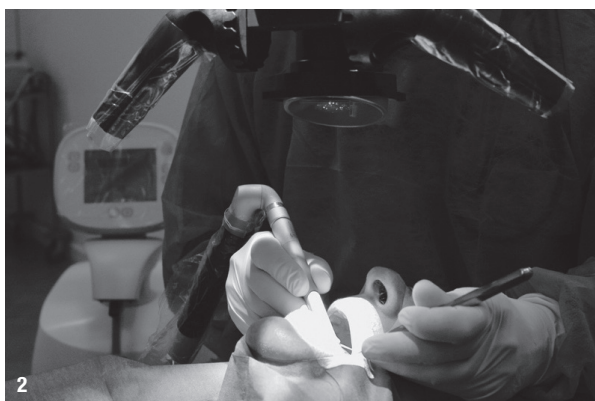
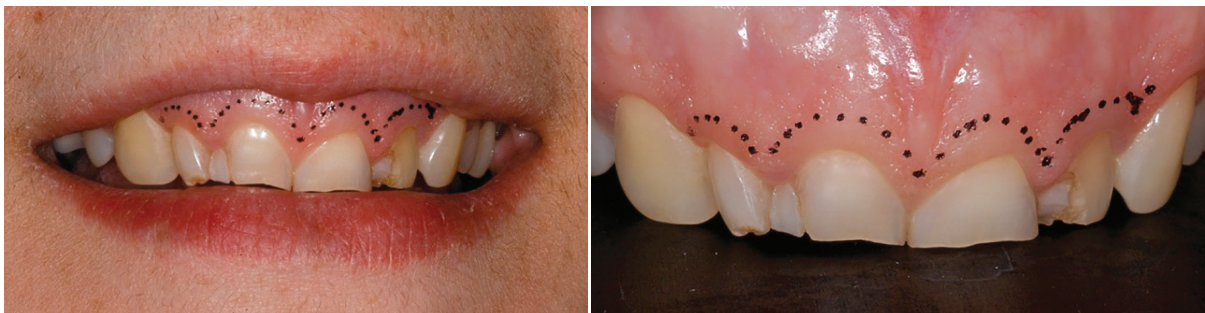
Fig. 2: Intervention with Er:YAG laser under an operating microscope. **Fig. 3:** The applicator of the Er:YAG laser (2,940nm) is very ergonomic. The laser is in the handpiece.



Figs. 4 & 5: Surgical planning.

The clinical examination and analysis of the smile revealed alteration of the dental structure of the four incisors, excess superficial periodontal tissue, short crown heights and a gummy smile (Figs. 1a & b). The pre-prosthetic analysis of the smile discussed in accordance with the patient's wishes led to the indication of a homothetic plasty of the periodontal tissue around the four incisors of about 3 mm.

Surgical protocol

Thanks to its ultra-precise photo-ablative effects, the Er:YAG laser allows truly flapless crown lengthening (Figs. 2 & 3). In this case, tissue plasty was performed by subtractive sculpting of all periodontal tissue. We then proceeded to the controlled layer-by-layer ablation of the various tissues composing the periodontium: keratinised epithelium, connective tissue, bone tissue and periodontal ligament. Tissue sculpting was done in accordance with pre-prosthetic aesthetic planning and performed entirely under high magnification under visual control in order to remain within the ablative dimension of the Er:YAG laser, which is approximately 30 μ/s (Figs. 4 & 5). It is considered a rather quick procedure, since the surgeon does not need to elevate and suture a flap and therefore saves time. The different tissue layers are directly sculpted with only one surgical tool. This type of intervention on four teeth does not take more than 45 minutes.

At the end of the procedure, the cementum layer was removed by gentle polishing with a fine multiblade milling cutter according to the protocol proposed by Becker et al. in 1998 (Fig. 6).² Although it cannot be performed with the Er:YAG laser, this step is crucial in order to avoid postoperative tissue rebound. In combination with good osteoplasty, which allows the biological space to be restored, it guarantees the stability of the tissue architecture obtained after the operation.³ The patient reported having experienced a relatively pleasant postoperative phase. There was no oedema or delay in healing often induced by the elevation of a flap. The patient was advised to apply a hyaluronic acid gel for two to three days for wound protection. In this context, the use of autologous blood concentrate platelet-rich fibrin can also be recommended. A wound like this, which has been treated with a dental

laser and is stimulated by its irradiation, heals very quickly, and the healing potential of the periodontal ligament is enormous. After the healing phase at six weeks post-operatively, temporary restorations could be placed after the preparation of the four incisors (Figs. 7 & 8). At eight weeks postoperatively, the definitive restorations were tried in and placed for finishing and adjustment (Figs. 9 & 10).

Benefits of the Er:YAG laser in this type of intervention

Among all medical lasers, the Er:YAG laser has a wavelength with the property of being the most absorbed by water. This gives it ultra-precise ablative effects at low energy levels. The thermal alteration layer is at 30 μ, which allows microsurgical tissue sculpting while preserving adjacent tissue.⁴ It acts selectively on tissue that is characterised by its water load gradient. The most hydrated tissue is irradiated first by the laser beam while preserving the less hydrated tissue from ablation. In the clinical case presented here, the tissue sculpting was thus perfectly safe. The first layers of soft tissue (epithelial and connective tissue) were removed without any risk of touching the bone. The considerable difference in water load be-

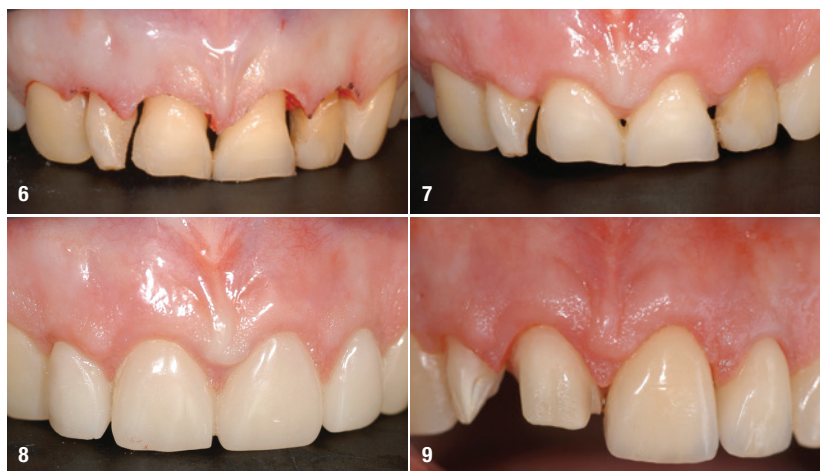

Fig. 6: Immediate post-op result. **Fig. 7:** Post-op result at six weeks. **Fig. 8:** Post-op clinical view with temporary restorations, also at six weeks. **Fig. 9:** Clinical view of the try-in of the definitive restorations. Periodontal stability at eight weeks was acquired.

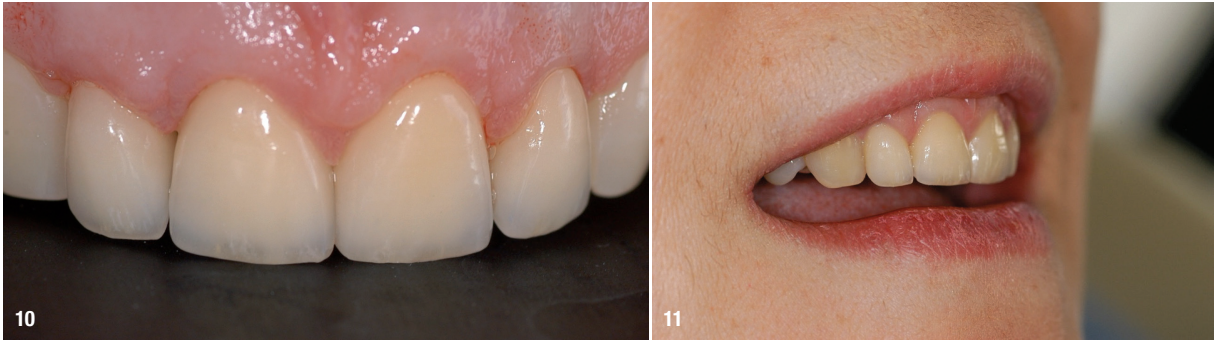


Fig. 10 Definitive restorations in place on the day of placement at eight weeks postoperatively. **Fig. 11:** The final outcome brought complete satisfaction to the patient.

tween soft tissue and bone allows very precise selective ablation. Under high-magnification optical guidance, the surgeon can operate layer by layer by subtraction in a microsurgical manner. Once the bone has been removed from the soft tissue, it is possible to sculpt the bone in order to restore the biological space around the root homothetically and safely for the dentine and cementum by relying on the difference in water load between bone and dentine. The decreasing water load gradient at this level is conducive to safe ablation with the Er:YAG laser. Under visual control, the periodontal ligament is irradiated simultaneously to the bone while preserving the tooth root.

To perform this microsurgical operation, the surgeon has six setting parameters at his or her disposal: three adjustment parameters to determine the power of the laser beam on the machine (i.e. the amount of energy transmitted to the targeted tissue; frequency of impacts; and water flow rate, which allows modulation of the effect of the delivered power) and three parameters in the surgeon's hand (i.e. the distance between the beam and the target, beam angulation, and exposure time). By modulating these different parameters, the surgeon sculpts the tissue being operated on according to his or her surgical planning.

Compared with conventional instrumentation, the Er:YAG laser offers the following advantages:

- It improves operating ergonomics (the surgeon operates with only one instrument on both soft and hard tissue; ultra-precise selective action on different tissue layers; clearance of the operating field rinsed by the laser spray, which allows operation without bleeding).
- The layer-by-layer approach allows a flapless procedure.
- The excellent water absorption of the Er:YAG laser allows surgery in the very restricted space of the sulcus without altering the adjacent tissue.
- Tissue sculpting is a novel procedure compared with conventional incision and milling. It allows simple and intuitive intervention in complete safety.
- The postoperative results are excellent because the vascularisation of the operated tissue is preserved and

the adjacent tissue is not traumatised by the elevation of a flap. Also, healing is quicker.⁵

- The Er:YAG laser decontaminates tissue by its bactericidal effects.^{6,7} Thus, the perfectly clean surgical field heals all the better. Bacteraemia is reduced compared with conventional instrumentation.⁸

Conclusion

In the clinical case described in this article, the Er:YAG laser allowed us to perfectly meet the patient's expectations (Fig. 11). Her smile was restored corresponding to her desires by preparing the periodontal tissue without creating a flap. The treatment result was considered stable at the follow-up after five years. As we have seen, this type of intervention is simple, reliable and secure. It is perfectly accessible within the framework of a general dental practice. There needs to be more research on the Er:YAG laser in the future, and it deserves to be integrated into our workflows owing to its great versatility.

about the author



Dr Fabrice Baudot is a French dentist specialised in periodontics and implantology. He currently leads a practice that focuses on laser-assisted microsurgery. His therapeutic approach is always based on minimally invasive surgery. Dr Baudot is frequently invited to speak at international dental conferences, and he is the author of numerous scientific publications. In addition, he is one of the founding members of the European Academy of Ceramic Implantology.

contact

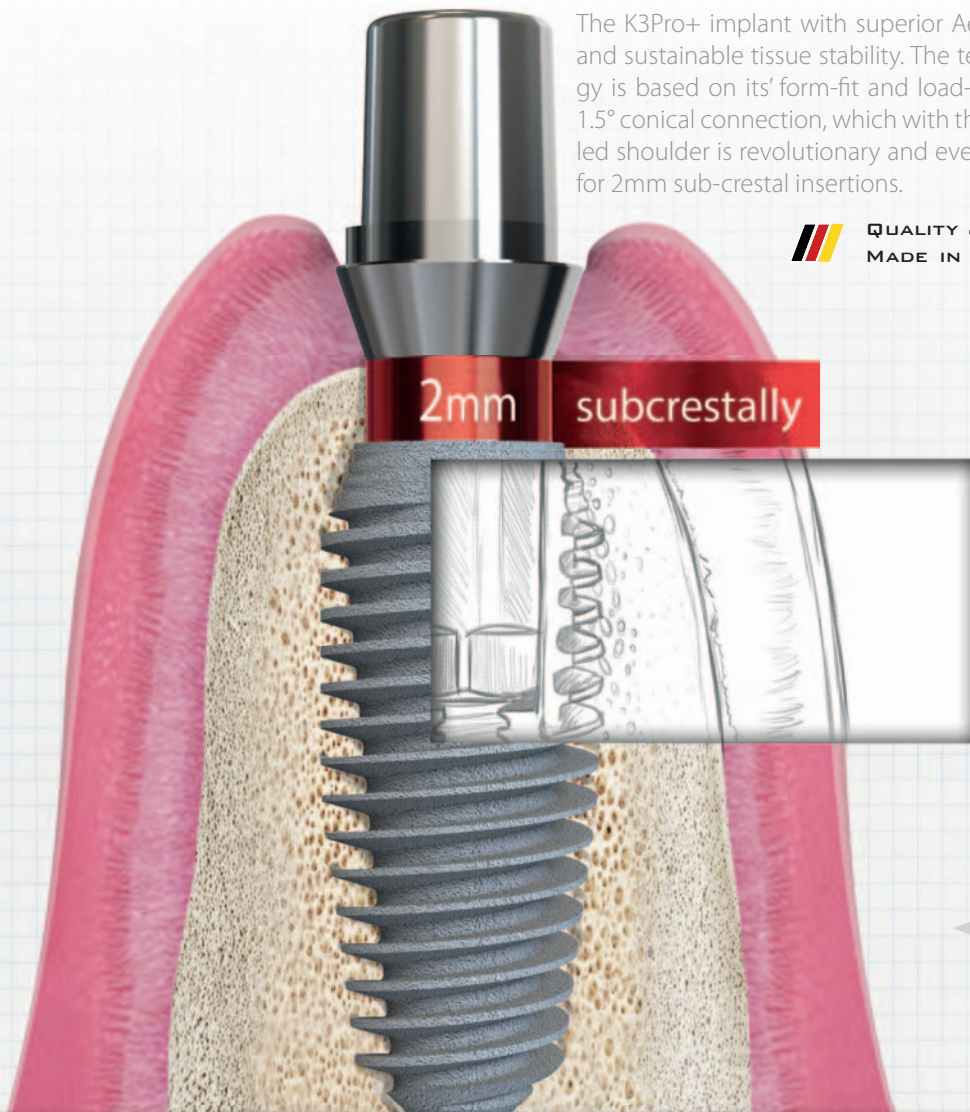
Dr Fabrice Baudot
 Impasse des Trois Pointes 65
 34980 Saint-Gély-du-Fesc
 France
 Phone: +33 4 99060060
 dr.baudot34@orange.fr



BIOMEDICAL ENGINEERING & SUPERIOR AESTHETICS

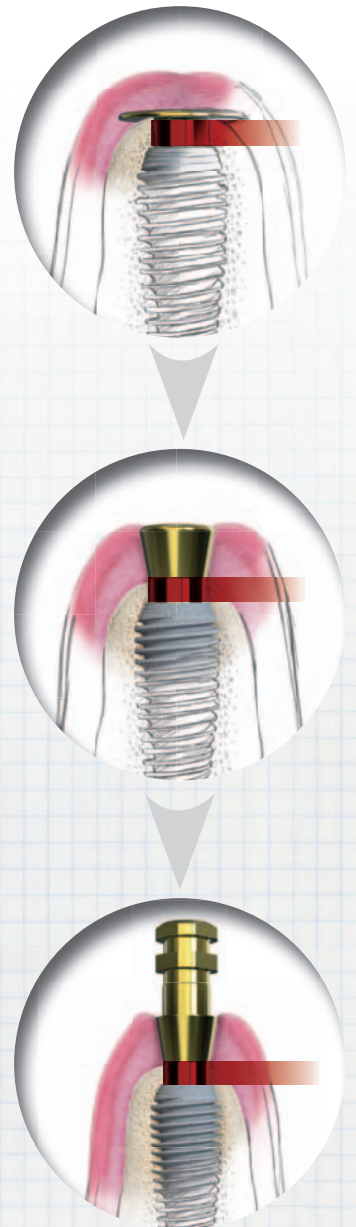


creating
STABLE TISSUE.



The K3Pro+ implant with superior Aesthetics and sustainable tissue stability. The technology is based on its' form-fit and load-disperse 1.5° conical connection, which with the beveled shoulder is revolutionary and even allows for 2mm sub-crestal insertions.

 **QUALITY & DESIGN**
MADE IN GERMANY



ARGON Medical
Tel.: 06721/ 3096-0
info@argon-medical.com
www.argon-medical.com

