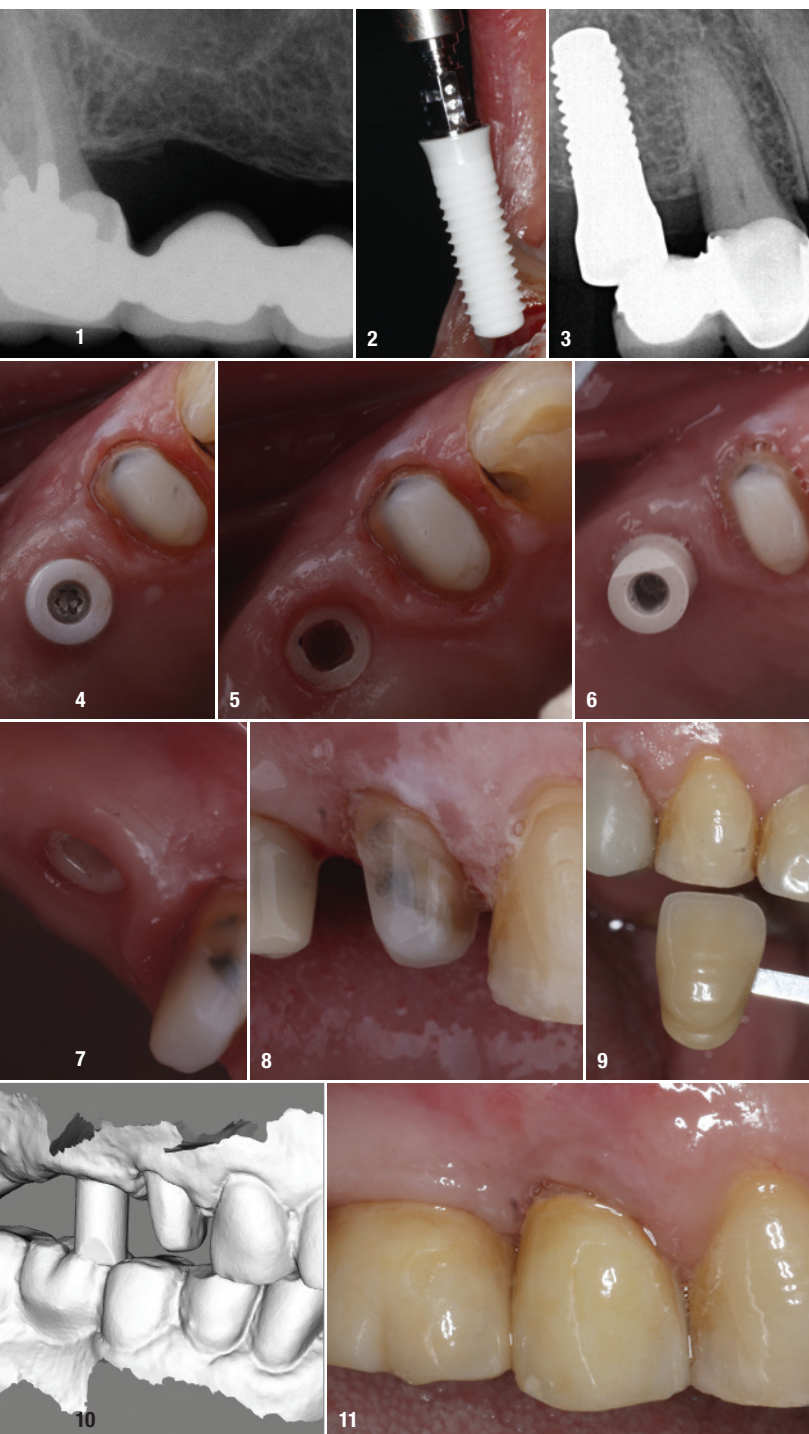


# Posterior single-tooth replacement using a two-piece tissue-level implant

Dr Dan Hagi, Canada



## Diagnosis

The patient, a 72-year-old male with well controlled hypertension, arthritis and an otherwise unremarkable medical history, presented with decay under the distal abutment of a long standing 4-unit fixed partial denture replacing teeth #15 and #16 (Fig. 1). Radiographic and clinical exams revealed an endodontically compromised #17, that was suspected to be vertically fractured. Also, tooth #18 was periodontally involved and unrestorable. The right maxillary sinus was pneumatized and the patient did not wish to have any sinus augmentation. The abutment tooth #14 exhibited coronal leakage and fractured porcelain, but was vital.

## Treatment plan

As the patient wanted a fixed restoration, the only option was an implant-supported restoration. He desired to be completely metal-free as teeth were replaced on the contralateral side with one-piece ceramic implants four years prior. A decision was made to place an implant at tooth #15 and make it a molar size, thus avoiding sinus involvement and giving the patient a first molar occlusion. The possibility of the use of a zirconia two-piece dental implant (PURE, Institut Straumann) was discussed and the alternative titanium implant option was also reviewed. The replacement of the restoration on tooth #14 was also planned. Temporisation initially was to be with a cantilevered restoration from the sectioned bridge. After healing, a fixed provisional was to be made on the implant. The final treatment would involve the sectioning of the fixed bridge, extraction of tooth #17 and placement of the two-piece ceramic implant and healing abutment. After a period of three months and the rigid fixation of the

**Fig. 1:** Preoperative radiograph. **Fig. 2:** Insertion of the two-piece implant. **Fig. 3:** Postoperative radiograph: implant is in final position. No violation of the maxillary sinus and placement of the implant at the correct vertical position. **Fig. 4:** Healed implant with healing abutment. **Fig. 5:** Soft tissue immediately surrounding the implant. **Fig. 6:** Scanbody in place. **Fig. 7:** Soft-tissue health after three months of healing. **Fig. 8:** Preparation of temporary abutment. **Fig. 9:** Provisional restoration. **Fig. 10:** Intra-oral scan STL files, lateral view. **Fig. 11:** Final restoration day of insertion.

implant, full contour milled Prettau crowns would be used as final restoration.

## Surgical treatment

The patient was pre-medicated with an antibiotic (Amoxicillin 500 mg). Infiltration with 4% Articaine 1:200,000 epinephrine (Septocaine, Septodont Inc.) was performed to anaesthetise the operative area. The prosthesis was sectioned and removed, and tooth #17 atraumatically removed. A full-thickness flap was raised to expose the underlying bone. The osteotomy was performed utilising drills at a maximum speed of 350 rpm. The slow drilling helps to maintain the vitality of the bone. No irrigation was used during the drilling and bone debris was collected from the drills. The implant was threaded into position (Fig. 2) and achieved excellent stability at 30 Ncm, threads in bone and the mucosal portion terminating 0.5 mm below the expected tissue level. The facial portion was grafted with the autogenous bone chips mixed with allograft (Oragraft, LifeNet), which was done to thicken up the crestal bone profile. The fixed partial denture that was removed and sectioned was cleaned and cemented with a resin cement to act as a one tooth cantilevered provisional. The post-surgical intra-oral radiograph shows the final position of the implant (Fig. 3).

## Prosthetic treatment

After twelve weeks, the soft tissue had healed and the implant had integrated. At that point, the implant was ready for final restoration (Figs. 4 & 5). The provisional was cut off and tooth #14 prepared for full coverage restoration. A scanbody was secured on the implant and both arches were scanned with an intra-oral scanner (CS3700, Carestream) before tissue retraction with retraction paste (3M Retraction Paste, 3M ESPE) on tooth #14 was performed (Fig. 6). After the scanning was completed, a PEEK abutment was secured on the implant and prepped to accommodate a new provisional (Fig. 8). An immediate provisional (VISCO III Auto-cure, anaxdent) was made with a direct method from a digital wax-up that was prepared previous to surgery and transferred intra-orally via matrix (Fig. 9). The STL files from the scan were transferred to the laboratory (Fig. 10). Utilising the digital files, the Prettau crowns were designed and milled. The screw-retained implant crown was inserted with 25 Ncm torque on the abutment screw. The access was sealed with a layer of PTFE tape and flowable composite. The crown on the tooth was inserted with a glass ionomer cement (GC FujiCEM 2, GC America). Excess cement was carefully cleaned. Occlusion was adjusted again as to avoid any prematurities (Fig. 11).

## Discussion

Two-piece ceramic implants are entering the marketplace. The key advantage over the one-piece option is

the ability to accommodate angulation as well as to simplify the healing period by minimising the surface area exposed to the oral cavity and thus reducing the occurrence of premature loading of the implant abutment. Proper angulation is achievable with the one-piece implant but needs to be managed by meticulous surgical planning and execution. If the angulation or spacing of implants is not correct, the outcome is very difficult to manage as we do not have a myriad of prosthetic options that can ameliorate poor placement. One-piece ceramic implants are a double-edged sword. If placed correctly, the soft-tissue profile and tissue health is remarkable, but if placed incorrectly, there are very few options to fix problems. The availability of two-piece ceramic implants certainly expands the application of the metal-free approach. As with the one-piece implants, soft-tissue health seems to be enhanced and thus so are aesthetic outcomes. The absence of a micro gap at bone level assures better bone preservation and thus better soft-tissue outcomes (Fig. 7).

## Conclusion

This case presented an example of where old concepts can be used with new cutting edge materials and a tooth can be replaced in an efficient, aesthetic and predictable manner. As with any aspect of this emerging field, we need more evidence and more work to validate the application of these techniques in the long term.

## about the author



**Dr Dan Hagi** received his dental training at the University of Toronto and now maintains a multidisciplinary implant and rehabilitative practice in Thornhill, Ontario. He is an associate Fellow of the American Academy of Implant Dentistry (AAID), a Fellow of the International Congress of Oral Implantology (ICOI), the Academy of General Dentistry (AGD), the Academy for Dental Facial Esthetics (ADFE) and the Misch International Implant Institute (MIII). His private practice focuses on metal-free, minimally invasive implant rehabilitation and aesthetic smile design. He is a lecturer and mentor at the Dental Implantology Center of Excellence (DICE), as well as a consultant on emerging metal-free materials and techniques.

## contact

**Dr Dan Hagi**  
**DDS, FAGD, FICOI, (A)FAAID**  
 DH Smile Center Dentistry  
 Thornhill, ON, Canada  
 +1 905 7093177  
[www.drdanhagi.com](http://www.drdanhagi.com)

