A new approach for patients on direct oral anti-coagulant medication

Dr Stefan Grümer & Melissa Yüce, Germany

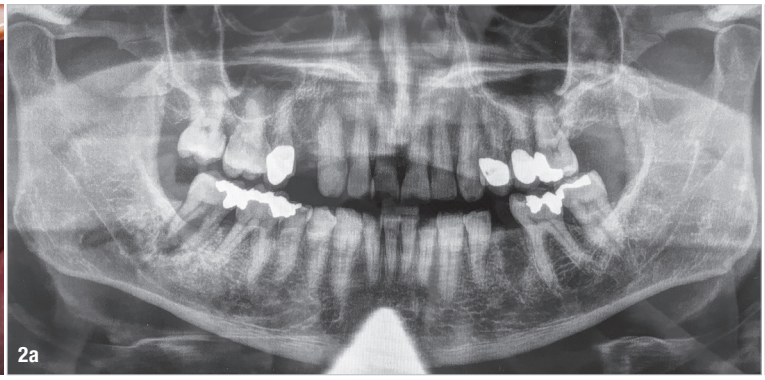

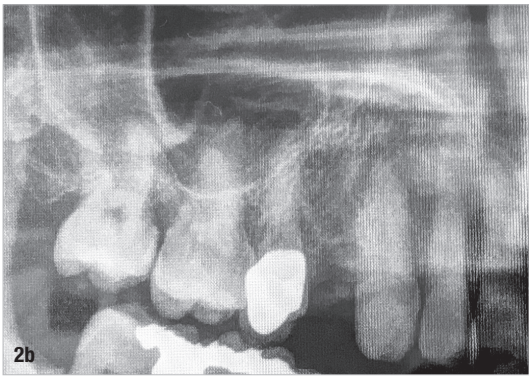

Fig. 1: The reduced size of position #14. **Figs. 2a & b:** Dental panoramic tomogram **(a)** and periapical radiograph **(b)** prior to implant placement.

Implant placement is a surgical procedure employed in accordance with the individual wishes of patients. It can often be avoided by choosing conventional, non-surgical alternatives. In particular, in cases of patients with haemorrhagic diathesis or patients undergoing anti-coagulant therapy with direct oral anti-coagulants (DOACs), the risk of undesired side effects, with even life-endangering consequences, necessarily led to a strict selection of patients who are suitable for dental implants. A new laser-supported approach in implantology for patients undergoing anti-coagulant therapy has been developed by the Aachen Institute for Continuous Medical and Dental Education in cooperation with the Clinic for Cardiology, Pneumology, Angiology and Internal Intensive Medicine of the RWTH Aachen University hospital in Germany.

Fig. 3: The initial osteotomy for the implant being performed with the pilot drill.

Case presentation

Nowadays, the number of implants placed in patients with a higher average age and in medically compromised cases is rising. Particularly cases of patients undergoing DOAC therapy, with the advantage of no need to permanently control the coagulation parameters, are rising significantly. Despite the advice of cardiologists not to stop or interrupt the medication, these patients often request implants. In addition, for only two DOACs does an antagonist drug exist. For three other DOACs, there is no antagonist drug yet, leading to an increase in possible postoperative complications. Nevertheless, among this group of patients, the demand for implants is rising as well. To fulfil these wishes while following the advice of the cardiologist, a new transgingival, nearly blood-free surgical protocol has been developed. The following case describes this procedure in general and points out differences in relation to conventional treatment.

Clinical and radiographic situation

A 62-year-old male patient with moderate general health attended the prosthetic consultation. His medical history revealed that he had had three bypasses between 2014 and 2016 and signs of anginal attacks. Also, there

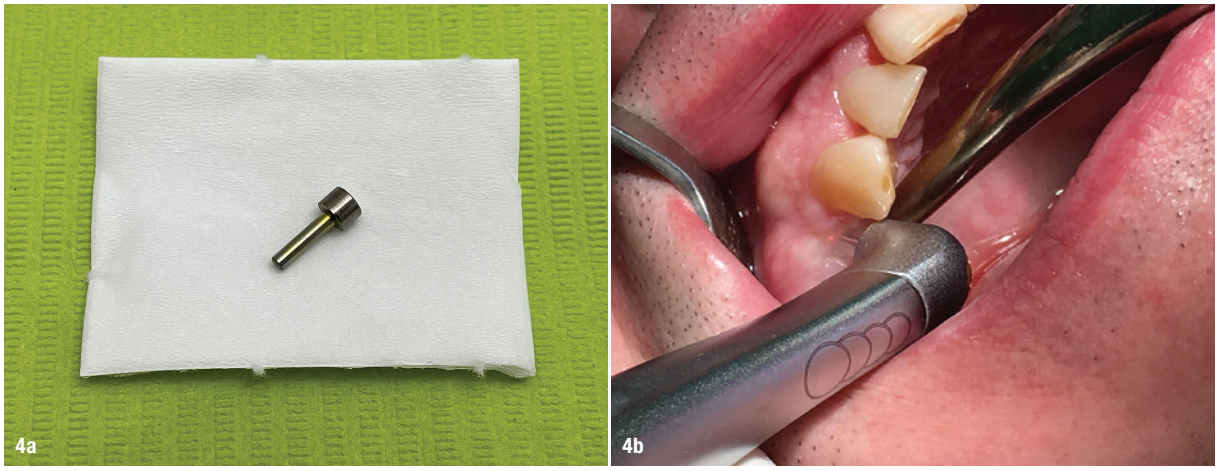

Figs. 4a & b: The guide for a conventional rotating soft-tissue punch with a central guide pin matching the pilot drill hole **(a)**. The laser handpiece used **(b)**.

were periodically recurring events of sinus arrhythmias. For a duration of three years, he had been on dabigatran etexilate (Pradaxa), which is a direct thrombin inhibitor. He was slightly overweight and a non-smoker. Upon intra-oral examination, restoratively and prosthetically rehabilitated dentition and missing teeth #14, 27 and 35 were noted, and it was observed that position #14 had reduced in size (Fig. 1). The patient maintained good oral hygiene. The panoramic radiograph revealed an apically compromised tooth #47 with furcation involvement and good bone structure in positions #14 and 35 (Figs. 2 & b). The patient was thoroughly informed regarding the treatment options. He asked for an implant replacement for tooth #14 and possibly, at a later stage, for tooth #35. After an explanation about the medical compromises regarding a surgical intervention and after consulting the cardiologist regarding the DOAC therapy, it was mutually decided not to interrupt medication with Pradaxa and to opt for transgingival, laser-supported implant surgery in position #14. The initial bone contours showed a sufficient amount of bone in all three dimensions. If the bone width appears critical, a 3D radiograph is highly recommended to evaluate the amount of bone in the third dimension.

Laser treatment and implant insertion

After local anaesthesia, the initial osteotomy for the implant was performed with a pilot drill (locator drill; Fig. 3). A guide for a conventional rotating soft-tissue punch with a central guide pin that matched the pilot drill hole was placed *in situ* as an outline guide for the blood-free laser punch procedure (Figs. 4a & b). The laser unit used was an Er,Cr:YSGG laser operating at a wavelength of 2,780 nm (Waterlase iPlus, BIOLASE). The laser was set to the parameters shown in Figure 5. After the laser incision, the punched tissue was removed with a curette (Figs. 6a & b). Thereafter, following the drill protocol of the implant system placed, a ProActive Tapered implant of 4 mm in diameter and 13 mm in length (Neoss) was inserted to a 32 Ncm torque (Figs. 7 & 8). The healing abutment was inserted to 15 Ncm. Slight pressure on the surrounding tissue is important, for which the diameter of the healing abutment should be at least 1 mm larger than the punch diameter. In this case, the tissue punch diameter was 4.3 mm and the healing abutment was 5.5 mm in diameter (Fig. 9). The definitive restoration is shown in Figure 10.

Discussion

After three months of healing, the implant can be loaded and the superstructure can be installed. Following the protocol described, 143 implants have been inserted during the last three years. The retrospective analysis of this method showed postoperative haemorrhage with the need for additional intervention for ten of these. Seven

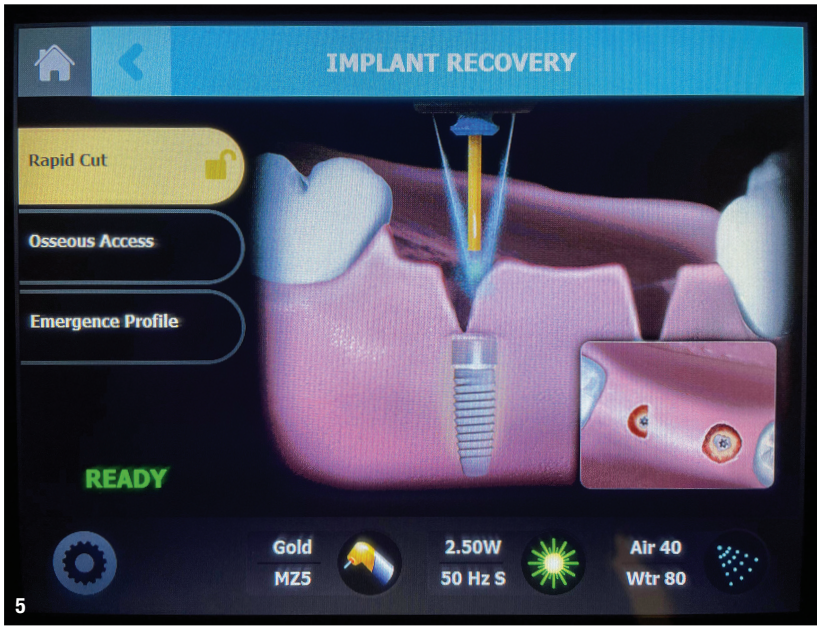

Fig. 5: The laser settings.

Figs. 6a & b: Removal of the punched tissue with a curette **(a)**. The tissue removed with the punch **(b)**. **Fig. 7:** The implant placed. **Fig. 8:** Periapical radiograph immediately after implant insertion. **Fig. 9:** Slight anaemia was visible around the healing abutment, demonstrating the pressure on the surrounding tissue required to prevent post-op haemorrhage. **Fig. 10:** The definitive restoration.

of the ten appeared during the first 30 implantations. After finding the right relation between size of the tissue punch and size of the healing abutment (diameter and height), only three cases of postoperative haemorrhage were encountered. The main precondition for this kind of treatment is a sufficient amount of bone in the implant site. Any augmentative procedures more demanding than a punch technique to gain 1–2 mm in the neck area of the implant are not compatible with the protocol described. In cases of reduced horizontal bone volume, case suitability for the laser-supported protocol should be evaluated by 3D radiography. The postoperative evaluation by the Clinic for Cardiology, Pneumology, Angiology and Internal Intensive Medicine showed no negative effects on the general health of the patients treated. This protocol is officially recommended by the clinic.

Conclusion

The use of laser in this delicate zone of soft tissue and bone of the implant site is very beneficial and does not harm the bone (or soft tissue) through high temperatures or carbonisation. In addition, the positive effect of biostimulation leads to quicker and better healing by accelerating the fibroblast activity around the implant. Of course, the primary benefit for patients is the reduction of the general risk of blood clotting and thrombosis, which can possibly cause seizures or strokes during the interruption of anticoagulant therapy, and such interruption is no longer essential with this laser-supported protocol.

about the author

Dr Stefan Grümer, MSc, is a specialist in implantology and laser dentistry. In 2013, he was appointed clinical director of the first academic teaching clinic in dentistry in Germany accredited by RWTH Aachen University. He is the head of clinical education in the MSc in lasers in dentistry programme at RWTH Aachen University. In addition, he is a member of the board of directors of the German Society for Laser Dentistry and the International Society for Laser Dentistry.

contact

Dr Stefan Grümer
Zahnärzte an der Theaterstraße
Aachen, Germany
+49 241 36461
doc@gruemer.de
zahnaerzte-theaterstrasse.de

Author details

Our dental implants have an outstanding survival rate

98%

With maintained marginal bone after 5 years

0.3 mm

Stronger than ever. Thanks to science.

After 30 years of research and more than 1,000 scientific publications, we can confidently say that Astra Tech Implant System® EV delivers life-long function and natural esthetics.

Thanks to science, our implants have an outstanding survival rate and a marginal bone maintenance far better than the industry standard.

If you are looking for endless possibilities and superior outcomes, this is the only system you need. Today and tomorrow.

Follow Dentsply Sirona Implants for the latest in implant dentistry

dentsplysirona.com/implants

Dentsply Sirona