

Laser phototherapy in Bell's palsy

A case report

Authors_Profa Aparecida Maria Cordeiro Marques*, Luiz Guilherme Pinheiro Soares*, Dr Cristina Maria do Nascimento*, Alberto de Aguiar Pires Valença Neto*, Roberta Cordeiro Marques*, Dr Antonio Luiz Barbosa Pinheiro*, Brazil

_Introduction

Bell's palsy is a sudden idiopathic peripheral palsy of the facial nerve. This condition is caused by some kind of damage to the VII cranial nerve that causes either complete or partial of the facial mimics.³ It may be associated or not to gustative disturbance, hyper salivation, and of eye and ear disturbances.⁸ Its diagnosis is by the exclusion of any other causes that may cause the palsy of the facial nerve as its etiology remains unclear.^{2,11} It has been demonstrated that herpes virus may cause this type of palsy due to reactivation of the virus or by immunomediated post-viral nerve demyelination.^{12,13} Most cases of Bells' palsy recover without treatment. Besides the unbalance of the facial esthetic and some sensorial symptoms, the acute phase of this disease is not associated to severe disturbances.¹⁶ The condition has a annual incidence estimated of 20–30:100.000 people^{2,12} and has a good prognosis, with spontaneous resolution in 95 % of the cases within 6–8 weeks.

One common symptom reported by suffers is pain around the ear prior to the clinical appearance of the facial palsy. This pain is caused by sensorial distur-

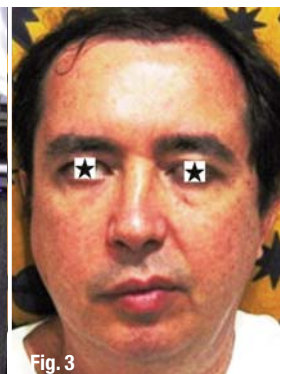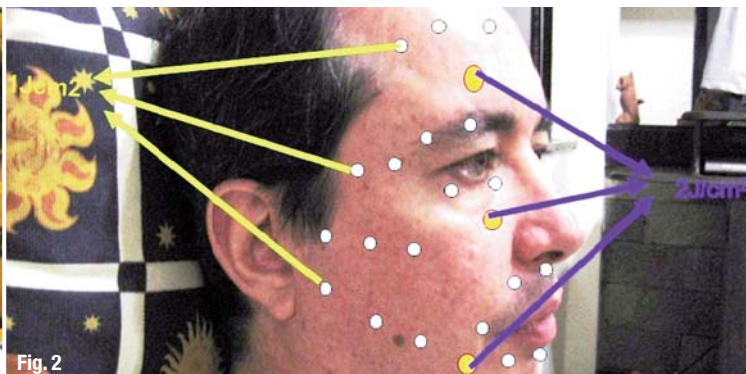
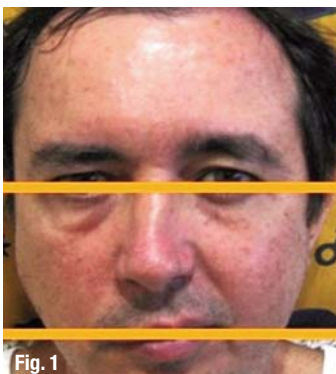bance of the facial nerve.¹⁸ The muscular spasm and sensitivity around the ear is an alert, an early sign, and it is due to hyper excitability of the facial nerve that causes the spasm of the facial muscles of the mimic and that may be provoked by centripetal impulses generated by the contact of the axons of the nerve with the Nervi nervorum.⁶

Clinical examination evidences the lost of facial expression on the affected side. The patient is not able, for example, of closing the eye as the eyelid does not respond to the order to close due to the palsy of the facial nerve. The eyeball rotates itself up. This is known as Bell's sign.¹³ Ru Lan et al. (2009) suggested that ageing increases the severity of the condition due to a reduced capacity of neural regeneration. This may be attributed to a hyperactivity of glial cells and increased activity of cerebral cytokines that impair the repair of nerve cells.⁸ There is also some evidence that Bell's palsy may be associated to bacterial infection Liu et al. (2009) suggested on their study that the use of penicillin on suffers showing normal counts of leukocytes and increased number of neutrophils resulted in Best results than when anti-viral agents were used. These aspects are indicative of a multi-fac-

Fig. 1 _Initial aspect of the patient showing limitation of the facial expression.

Fig. 2 _Diagram showing the sites of application of the Laser and amount of energy delivered to each point.

Fig. 3 _Aspect of the patient lips of the affected site during the treatment (30 days).



torial etiology and that it may require different treatments according to the etiological agent.

The success of the treatment of Bell's palsy by using laser phototherapy isolated or in association with other therapeutic approach has been reported on the literature.^{1,16,20} The ability to increase the amplitude of the action potential and increased regeneration of nerves are probably related to the efficacy of the protocol used on cases of Bell's palsy.⁷ A previous report by Shamir et al. (2001) on a rodent model used applications of $\lambda = 780\text{nm}$ laser light applied daily and transcutaneously (30 min, 21 consecutive days), to corresponding segments of the spinal cord and to the injured sciatic nerve. Their results showed positive somato-sensorial response on 69.2% of the animals that were irradiated with the laser. Controls showed only 18.2% of positive responses. Immunohistochemical analysis evidenced both increased number of total axons and improved quality of nerve repair on irradiated animals.

The treatment of Bell's palsy aims mainly to prevent corneal damage usually by physiotherapy and steroids.¹³ Physiotherapy, steroids and retroviral agents are now widely accepted for treating Bell's palsy. Laser phototherapy is able to stimulate the metabolism of the damaged nerve stimulating the production of proteins associated to its growth and improved recovery capacity of the facial nerve.²⁰ Ailioaie, Chiran, (2004) studied nerve regeneration on 31 children using Laser light ($\lambda = 670/830\text{nm}$) and found complete regeneration on 87.5% of the cases. Controls showed only 60% of recovery. This work reports the treatment of a case of Bell's palsy with laser phototherapy, electrotherapy and physiotherapy.

_Case report

A 52-years-old white male complaining of hemi facial palsy was seen at the Laser Center of the Center of Biophotonics of the School of Dentistry of the Federal University of Bahia (Fig. 1). Laser phototherapy was carried out during two months. A diode laser ($\lambda = 790\text{nm}/40\text{mW}/26\text{--}29\text{J}/\text{cm}^2$ - Kondortech®, São Carlos, São Paulo, Brazil) was used and treatment started 48h after the onset of the palsy. During the first week the treatment was carried out on daily basis ($26\text{J}/\text{cm}^2$) on the following weeks treatment was carried out three times a week ($29\text{J}/\text{cm}^2$). The number of total sessions was 21. Laser light was delivered on extra-oral contact points on the affected hemi face and was carried out along the five branches of the facial nerve and at the infraorbital and mental foramina (Fig. 2). Besides Laser phototherapy the patient was also submitted to TENS and physiotherapy three times a week. The palsy weakened along the time of treatment as seen on Figures 3 and 4.

_Discussion

Bell's palsy may be uni or bilateral disturbance of the conduction of the Facial nerve with non-specific etiology.² Treatment of this pathology is carried out using antiviral drugs^{2,12,17}, steroids^{4,6,14,15}, physiotherapy³, and acupuncture.¹¹ The use of steroids has been shown effective on the treatment of Bell's palsy due to its strong anti-inflammatory effect that reduces the damage to the nerve resulting in a better prognosis.^{2,15}

Over the last 10 years the use of Laser phototherapy has been suggested as an associated treatment to other types of therapeutic approaches.^{5,9,16,20} This positive effect has been attributed to the effect of the light on nerve regeneration and consequent recovery of normal nerve physiology. Khullar et al. (1996) suggested that Laser light might stimulate reinnervation of the tissues by either the penetration of the axons or on adjacent Schwann's cells inducing the compromised tissue to secrete proteins related to nerve growth or the releasing of mediator of nerve growth that will affect non-damaged adjacent nerves. These aspects were reflected on the treatment of the patient. Despite the positive result of the treatment, further studies are needed to elucidate the effect of the laser light on nerve as well as on the etiology of Bell's palsy.

_Conclusion

Laser phototherapy seems to positively affect the outcome of the treatment of Bell's palsy carried out with other therapeutic approaches causing mainly quicker sensorial recovery and improved quality of life of the patients.

_Abstracts

Bell's palsy is defined as a peripheral facial nerve palsy, idiopathic, and sudden onset and is considered the most common cause of this pathology. It is caused by damage to cranial nerves VII, resulting in complete or partial paralysis of the facial mimic. May be associated with taste disturbances, salivation, tearing and hyperacusis. It is diagnosed after ruling out all possible etiologies, because its cause is not fully understood. Physical therapy, corticosteroids and antiviral therapy have become the most widely accepted treatments for Bell's palsy. Therapy with low-level laser (LLLT) may induce the metabolism of injured nerve tissue for the production of proteins associated with its growth and to improve nerve regeneration. In most cases, the recovery occurs without uneventfully (complications), the acute illness is not associated with serious disorder. This paper reports a successful treatment of Bell's palsy treated with Laser phototherapy, electrotherapy and physiotherapy.



Fig. 4 Aspect of the patient at the end of the treatment showing the recovery of the facial mimics (60 days).

_contact laser

Profa Aparecida Maria Cordeiro Marques
Center of Biophotonics
School of Dentistry
Federal University of Bahia
Av. Araújo Pinho,
62, Canela
Salvador, BA,
CEP 40140-110, Brazil
Tel./Fax:
+55 71 32839010
E-mail:
amarques@ufba.br,
cidamarques77@hotmail.com

*Center of Biophotonics,
School of Dentistry,
Federal University of Bahia,
Av. Araújo Pinho, 62,
Canela, Salvador, BA, CEP
40140-110, Brazil