

Frenectomy review

Comparison of conventional techniques with diode laser

Authors_Dr M.L.V. Prabhuji, Prof Dr S.S. Madhu Preetha, Dr Ameya G. Moghe, India

_Introduction

The word frenum is derived from the Latin word "fraenum". Frena, are triangle-shaped folds found in the maxillary and mandibular alveolar mucosa, and are located between the central incisors and canine premolar area.

Frenum may be classified depending upon its morphology as:

- _Long and thin
- _Short and broad.

Depending upon the attachment level, frenum has been classified as: (Placek et al. 1974)

- _Mucosal
- _Gingival
- _Papillary
- _Papillary penetrating.

When the insertion point of the frena is at the gingival margin it may pose a problem (Corn 1964). This kind of abnormal insertion of the frenum may cause marginal recession of the gingiva. Abnormal frenal insertion can distend and retract the marginal gingiva or papilla away from the tooth when the lip is stretched. A frenum that encroaches on the margin of the gingiva may interfere with plaque removal, and tension on this frenum may tend to open the sulcus.

This condition may be more conducive to plaque accumulation and inhibit proper oral hygiene.

Aberrant frenum can be treated by frenectomy or frenotomy procedures. The terms frenectomy and frenotomy signify operations that differ in degree of surgical approach. Frenectomy is a complete removal of the frenum, including its attachment to the underlying bone, and may be required for correction of abnormal diastema between maxillary central incisors (Friedman 1957). Frenotomy is the incision and relocation of the frenal attachment.

Indications

- _The indications for frenectomy procedure include
- _Tension on the gingival margin (frenal-pull concomitant with or without gingival recession)
- _Facilitate orthodontic treatment
- _Facilitate home care.

Techniques for frenectomy

- _Conventional technique
- _Using soft tissue lasers.

Conventional technique

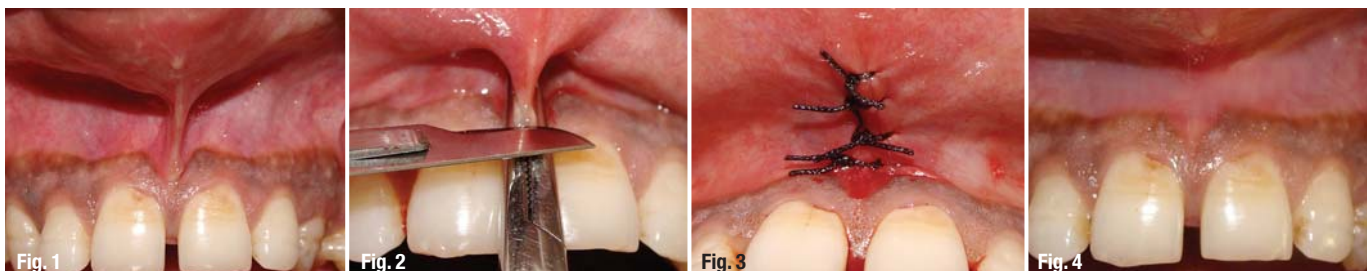
Conventional technique utilises traditional instruments like the scalpels and periodontal knives. Different procedures have been mentioned under the conventional frenectomy technique. These include

Fig. 1 _Abnormal frenal attachment.

Fig. 2 _Haemostat in place & incision made.

Fig. 3 _Sutures placed.

Fig. 4 _Post-op two months.



Dieffenbach, Schuchardt, & Mathis. The most common being Dieffenbach V-plasty & Schuchardt Z-plasty.

Armamentarium

Bard-Parker handles no. 3, No. 15 blade, mosquito haemostat, suture material.

Procedure

Dieffenbach V-plasty

Surgical steps: The area is anesthetized by giving local anesthetic injection (2% lignocaine with 1:200,000 adrenaline). After anesthesia is achieved, the frenum is held with the mosquito haemostat to its full depth. With the No. 15 blade mounted on a Bard-Parker handle, an incision is made along the upper surface of the haemostat till the entire depth of the frenum extending into the vestibule. A similar incision is repeated on the under-surface of the haemostat so that the haemostat is detached along with the frenal tissue within its beaks. Once this is achieved, a rhomboid area exposing the deeper connective tissue fibers becomes visible. With the help of fine scissors, the deeper fibers are detached from the underlying periosteum. Periosteal scoring is done with the help of surgical blade so as to prevent the reattachment of fibers. The labial mucosa is un-

dermined so as to permit the approximation of the edges. The bleeding is controlled by applying pressure packs.

Suturing: The diamond shaped wound is sutured using either a 4-0 or 5-0 silk sutures in simple interrupted fashion. Proper approximation of the margins is ensured. A periodontal dressing is placed to cover the surgical area.

Frenectomy by V-plasty may result in scar formation that could prevent the mesial movement of the central incisors (West 1968). However, it is typically a safe surgical procedure with no notable complications.

Schuchardt Z-plasty

The main advantage of this method over the V-plasty method was minimal scar tissue formation. The method requires a skilled operator as it is tedious to perform.

Frenectomy using soft tissue lasers

LASER (Light Amplification by Stimulated Emission of Radiation) is based on Albert Einstein's theory of spontaneous and stimulated emission of radiation. It was Maiman in 1960 who gave the first laser prototype using ruby crystal. Shortly there-

Laser Type		Wavelength	Colour
Excimer laser	Argon fluoride (ArF) Xenon chloride (XeCl)	193 nm 308 nm	Ultraviolet Ultraviolet
Gas laser	Argon Helium-Neon (HeNe) Carbon dioxide (CO ₂)	488 nm 514 nm 637 nm 10,600 nm	Blue Blue green Red Infrared
Diode laser	Indium Gallium Arsenide Phosphorus (InGaAsP) Gallium Aluminium Arsenide (GaAlAs) Galium Arsenide (GaAs) Indium Galium Arsenide (InGaAs)	655 nm 677–830 nm 840 nm 980 nm	Red Red-Infrared Infrared Infrared
Solid state	Frequency doubled Alexandrite Potassium Titanyl Phosphate (KTP)	337 nm 532 nm	Ultraviolet Green
Lasers	Neodymium:YAG (Nd:YAG) Holmium:YAG (Ho:YAG) Erbium,Chromium (Er,Cr: YSGG) Erbium:YSGG (Er:YSGG) Erbium:YAG (Er:YAG)	1,064 nm 2,100 nm 2,780 nm 2,790 nm 2,940 nm	Infrared Infrared Infrared Infrared Infrared

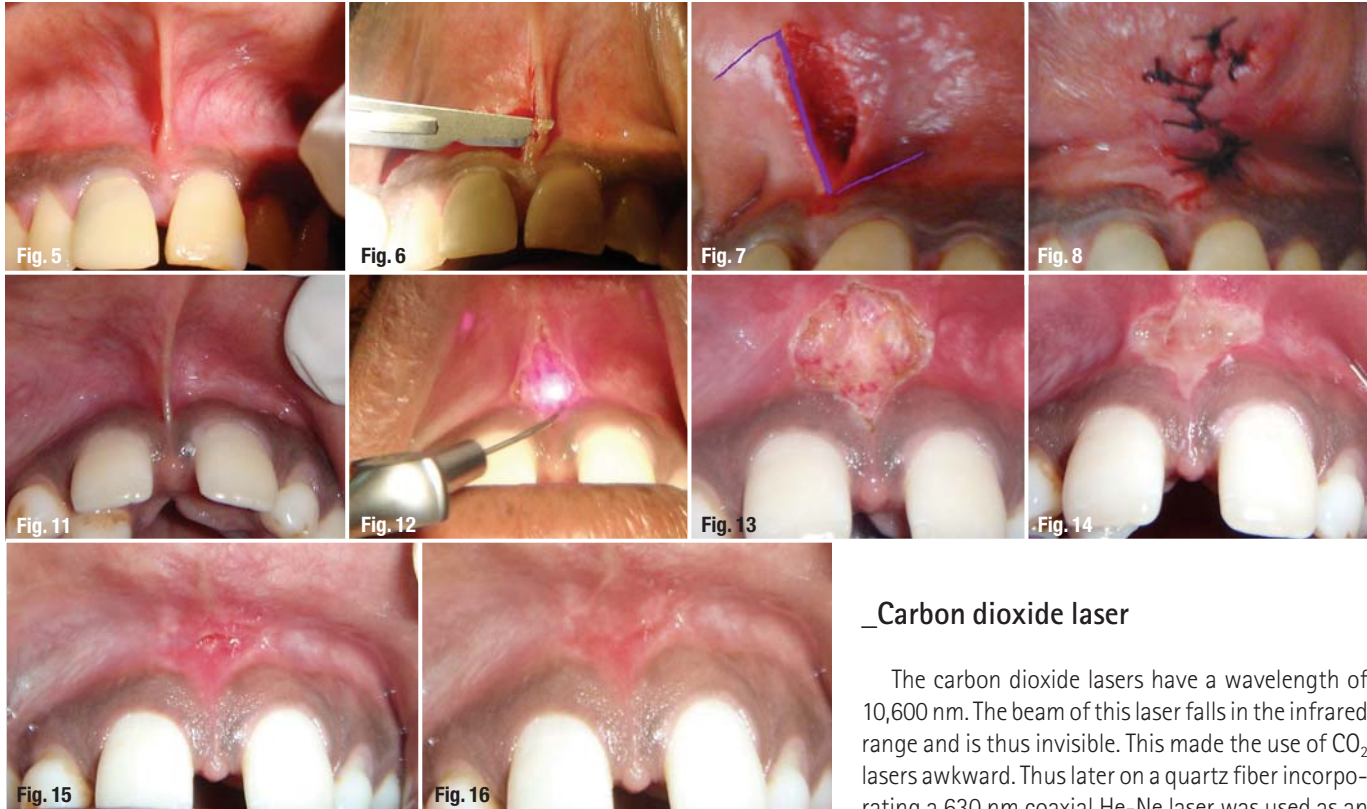

Fig. 5_Papillary frenal attachment.

Fig. 6_Horizontal incision made.

Fig. 7_Outline for Z-plasty.

Fig. 8_Sutures placed.

Fig. 11_Papillary penetrating frenum.

Fig. 12_Diode laser applied.

Fig. 13_Immediate Post-operative view.

Fig. 14_Post-op 2 days.

Fig. 15_Post-op 1 week.

Fig. 16_Post-op 2 months.

after, in 1961, Snitzer published the prototype for the Nd:YAG laser. The first application of a laser to dental tissue was reported by Goldman et al. and Stern and Sognnaes, each article describing the effects of the ruby laser on enamel and dentin. Lasers designed for surgery deliver concentrated and controllable energy to the tissue. For the laser to have effect the energy must be absorbed. The degree of absorption in the tissue varies as a function of wavelength and characteristics of target tissue. As the temperature increases at surgical site, the soft tissues are subjected to:

- _Warming (37 °C to 60 °C)
- _Welding (60 °C to 65 °C)
- _Coagulation (65 °C to 90 °C)
- _Protein denaturation (90 °C to 100 °C)
- _Drying (100 °C)
- _Carbonization (above 100 °C)

_Carbon dioxide laser

The carbon dioxide lasers have a wavelength of 10,600 nm. The beam of this laser falls in the infrared range and is thus invisible. This made the use of CO₂ lasers awkward. Thus later on a quartz fiber incorporating a 630 nm coaxial He-Ne laser was used as an aiming beam in the handpiece. The CO₂ laser received safety clearance from FDA in 1976 for use in soft tissue surgery. With the CO₂ laser there is rapid intracellular rise of temperature and pressure leading to cellular rupture and release of 'laser plume' (vapour and cellular debris).

The CO₂ laser is readily absorbed by water. Soft tissue consists of 75 % to 90 % water, 98 % of the incident energy is converted into heat and absorbed at the tissue surface with very little scatter or penetration. Thus moist surface is essential for maximal effect. With CO₂ laser no contact is made with the tissue, and no tactile feedback occurs.

_Neodymium:YAG laser

The Nd:YAG laser has a wavelength of 1,064 nm and lies in the infrared zone like the CO₂ laser. The Nd:YAG laser penetrates water upto 60 mm after which it is attenuated 10 % of its original strength. Thus energy is scattered in soft tissue rather than being absorbed onto the surface. The wavelength of Nd:YAG laser is attracted to colours and as a result its scattering in heavily pigmented soft tissues like skin is almost double its absorption. This heating effect of the Nd:YAG laser is ideal for the ablation of potentially haemorrhagic abnormal tissue and for haemostasis of small capillaries and venules. In 1990, the FDA approved soft tissue removal by means of a pulsed Nd:YAG laser. In 1997, the FDA approved sulcular debridement by means of a pulsed Nd:YAG laser.

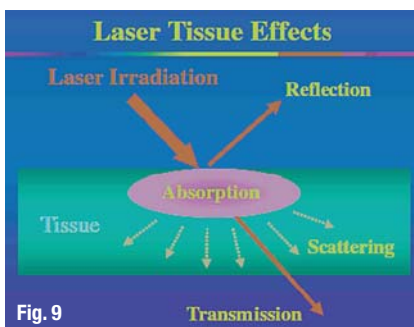


Fig. 9

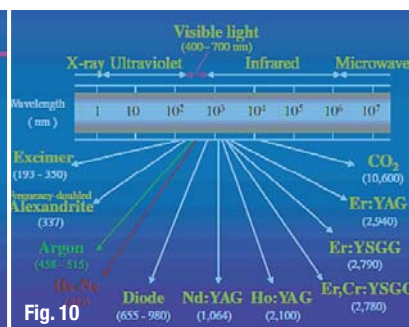


Fig. 10

Er:YAG laser

The Er:YAG laser was introduced in 1974 by Zharikov et al. as a solid-state laser that generates a light with a wavelength of 2,940 nm. Of all lasers emitting in the near- and mid-infrared spectral range, the absorption of the Er:YAG laser in water is the greatest because its 2,940 nm wavelength coincides with the large absorption band for water. The absorption coefficient of water of the Er:YAG laser is theoretically 10,000 and 15,000–20,000 times higher than that of the CO₂ and the Nd:YAG lasers, respectively. Since the Er:YAG laser is well absorbed by all biological tissues that contain water molecules, this laser is indicated not only for the treatment of soft tissues but also for ablation of hard tissues. The FDA approved the pulsed Er:YAG laser for hard tissue treatment such as caries removal and cavity preparation in 1997, unchanged for soft tissue surgery and sulcular debridement in 1999 and for osseous surgery in 2004.

Diode lasers

The diode laser is a solid-state semiconductor laser that typically uses a combination of Gallium (Ga), Arsenide (Ar), and other elements such as Aluminum (Al) and Indium (In) to change electrical energy into light energy. The wavelength range is about 800–980 nm. The laser is emitted in continuous-wave and gated-pulsed modes, and is usually operated in a contact method using a flexible fiber optic delivery system. Laser light at 800–980 nm is poorly absorbed in water, but highly absorbed in hemoglobin and other pigments (ALD 2000). Since the diode basically does not interact with dental hard tissues, the laser is an excellent soft tissue surgical laser (Romanos G, 1999), indicated for cutting and coagulating gingiva and oral mucosa, and for soft tissue curettage or sulcular debridement.

The FDA approved oral soft tissue surgery in 1995 and sulcular debridement in 1998 by means of a diode laser (GaAlAs 810 nm). The diode laser exhibits thermal effects using the 'hot-tip' effect caused by heat accumulation at the end of the fiber, and produces a relatively thick coagulation layer on the treated surface (ALD 2000). The usage is quite similar to electrocauterization. Tissue penetration of a diode laser is less than that of the Nd:YAG laser, while the rate of heat generation is higher (Rastegar S 1992), resulting in deeper coagulation and more charring on the surface compared to the Nd:YAG laser. The width of the coagulation layer was reported to be in excess of 1.0 mm in an incision of bovine oral soft tissue in vitro (White JM 2002). The advantages of diode lasers are the smaller size of the units as well as the lower financial costs.

cosmetic dentistry

— beauty & science



One issue free of charge!



Subscribe now!

You can also subscribe via
www.oemus.com/abo

☐ I hereby agree to receive a free trial subscription of **cosmetic dentistry** (4 issues per year). I would like to subscribe to **cosmetic dentistry** for € 44 including shipping and VAT for German customers, € 46 including shipping and VAT for customers outside Germany, unless a written cancellation is sent within 14 days of the receipt of the trial subscription. The subscription will be renewed automatically every year until a written cancellation is sent to OEMUS MEDIA AG, Holbeinstr. 29, 04229 Leipzig, Germany, six weeks prior to the renewal date.

☐ **Reply** per Fax +49 341 48474-290 to OEMUS MEDIA AG or per E-mail to grasse@oemus-media.de

Last Name, First Name

Company

Street

ZIP/City/Country

E-mail

Signature

Notice of revocation: I am able to revoke the subscription within 14 days after my order by sending a written cancellation to OEMUS MEDIA AG, Holbeinstr. 29, 04229 Leipzig, Germany.

Signature

Laser type	Current/Potential dental application	
Excimer lasers	Argon Fluoride (ArF) Xenon Chloride (XeCl)	Hard tissue ablation, Dental calculus removal
Gas lasers	Argon (Ar)	Curing of composite materials, Tooth whitening, Intraoral soft tissue surgery, Sulcular debridement (subgingival curettage in periodontitis and peri-implantitis)
	Helium Neon (HeNe) Carbon Dioxide (CO ₂)	Analgesia, Treatment of dentin hypersensitivity, Aphthous ulcer treatment, Intraoral and implant soft tissue surgery, Aphthous ulcer treatment, Removal of gingival melanin pigmentation, Treatment of dentin hypersensitivity, Analgesia
Diode lasers	Indium Gallium Arsenide Phosphorus (InGaAsP) Galium Aluminum Arsenide (GaAlAs) and Galium Arsenide (GaAs)	Caries and calculus detection Intraoral general and implant soft tissue surgery, Sulcular debridement (subgingival curettage in periodontitis and peri-implantitis), Analgesia, Treatment of dentin hypersensitivity, Pulpotomy, Root canal disinfection, Aphthous ulcer treatment, Removal of gingival melanin pigmentation
	Frequency-doubled Alexandrite Neodymium:YAG (Nd:YAG)	Selective ablation of dental plaque and calculus Intraoral soft tissue surgery, Sulcular debridement (subgingival curettage in periodontitis), Analgesia, Treatment of dentin hypersensitivity, Pulpotomy, Root canal disinfection, Removal of enamel caries, Aphthous ulcer treatment, Removal of gingival melanin pigmentation
Solid state lasers	Erbium group Erbium:YAG (Er:YAG), Erbium:YSGG (Er:YSGG), Erbium,chromium:YSGG (Er,Cr:YSGG)	Caries removal and cavity preparation, Modification of enamel and dentin surfaces, Intraoral general and implant soft tissue surgery, Sulcular debridement (subgingival curettage in periodontitis and peri-implantitis), Scaling of root surfaces, Osseous surgery, Treatment of dentin hypersensitivity, Analgesia, Pulpotomy, Root canal treatment and disinfection, Aphthous ulcer treatment, Removal of gingival melanin/metal-tattoo pigmentation

Argon laser

The argon laser uses argon ion gas as an active medium and is fiber optically delivered in continuous wave and gated pulsed modes. This laser has two wavelengths, 488 nm (blue) and 514 nm (blue-green), in the spectrum of visible light. The argon laser is poorly absorbed in water and therefore does not interact with dental hard tissues. However, it is well absorbed in pigmented tissues, including haemoglobin and melanin, and in pigmented bacteria.

The argon laser was approved by the FDA for oral soft tissue surgery and curing of composite materials in 1991 and for tooth whitening in 1995. Considering the advantages of eradication of pigmented bacteria, this laser may be useful for the treatment of periodontal pockets.

Alexandrite laser

The Alexandrite laser is a solid-state laser employing a gemstone called Alexandrite, which is chromium doped: Beryllium-Aluminum-Oxide chrysoberyl (Cr+3; BeAl₂O₄) and is one of the few trichroic minerals. Rechmann & Henning first reported that the frequency-doubled Alexandrite laser (wavelength 337 nm, pulse duration 100 ns, double spikes, q-switched) could remove dental calculus in a completely selective mode without ablating the underlying enamel or cementum.

The development of this laser for clinical use is widely expected due to its excellent ability for selective calculus removal from the tooth or root surface without ablating the tooth structure.

Excimer laser

Excimer lasers are lasers that use a noble-gas halide, which is unstable, to generate radiation, usually in the ultraviolet region of the spectrum. Frentzen et al. demonstrated that the ArF excimer laser, wavelength 193 nm, could effectively remove dental calculus without causing any damage to the underlying surface. The cementum surface was clean, and only a slight roughness could be observed after irradiation, supporting the use of excimer lasers for laser scaling. Folwaczny et al. have reported that the 308 nm wavelength XeCl excimer laser could effectively ablate dental calculus without thermal damages or smear layer production.

Frenectomy procedure using diode lasers

Diode laser (A.R.C. Fox™) with wavelength of 810 nm was selected for the procedure. No local anaesthesia was given to the patient. The frenum was stretched to visualize its extent. The diode laser was applied in a contact mode with focused beam for excision of the tissue. The ablated tissue was continuously mopped using wet gauze piece. This takes care of the charred tissue and prevents excessive thermal damage to underlying soft tissue. The tissue was lased until all the underlying muscle fibers were dissected. No sutures were placed at the end of this procedure. Patients were asked to take analgesics only if needed.

Advantages of Laser over Conventional technique:

- _ No need of local anaesthesia. Hence it's a painless procedure. As a result there is less patient apprehension.
- _ Bloodless operative field, thus better visibility.
- _ No need of periodontal dressing, therefore no patient discomfort as a result of irritation from the dressing.
- _ Better healing and less scarring.
- _ Less time consuming.

_contact	laser
Dr M.L.V. Prabhuji MDS Department of Periodontics Krishnadevaraya College of Dental Sciences Hunasamaranahalli, Via Yelahanka Bangalore, 562157, India E-mail: prabhujimlv@gmail.com	

19th ANNUAL CONGRESS OF THE DGL



LASER START UP 2010

OCTOBER 29–30, 2010, BERLIN, GERMANY

027713

» Please fax this form
+49 341 48474-390

More information:

☐ **LASER START UP 2010**

☐ **19th ANNUAL CONGRESS OF THE DGL**

October 29–30, 2010, Berlin, Germany

office stamp