Successful rehabilitation of an anterior tooth

Dr Dr Branislav Fatori & Dr Inge Schmitz, Germany

Fig. 1: Radiograph of the initial clinical situation. **Fig. 2:** View of the old crown. **Fig. 3:** Situation after crown removal.

Replacing a tooth in the anterior region with a dental implant is a demanding task. When it comes to aesthetics, it virtually always poses a challenge for the clinician, since his or her primary objective is to preserve the smile line as effectively as possible. Ideally, the transition from implant to crown should not be visible. If there is too little gingiva or if it is thin, there is a risk that the implant and abutment connection will show through the gingiva. To ensure that the colour of the crown does not differ from the colour of the adjacent teeth, close cooperation with a skilled dental technician is always required. If the transition between the implant (or tooth) and the gingiva is not visible when smiling, the problem of aesthetics can usually be solved well. However, if the smile line is relatively high, the gingiva and bone volume play a crucial role in the aesthetic treatment. In the following, a clinical case is presented in which the successful restoration of an anterior tooth in a patient with a high smile line is described. The patient had an old restoration which needed replacement after 15 years of wear.

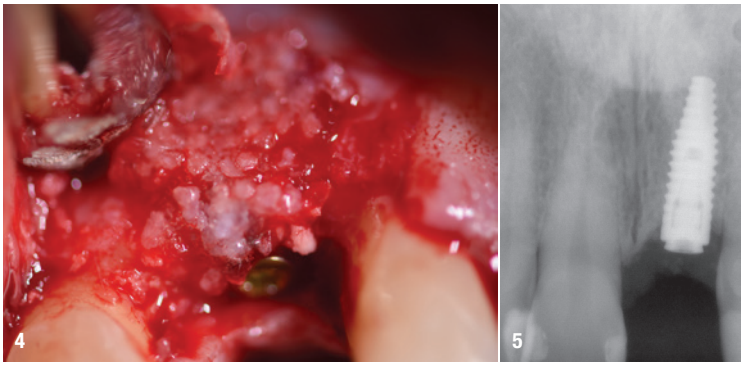

Fig. 4: Bone augmentation. **Fig. 5:** Radiographic view of the freshly inserted implant.

Materials and method

The 51-year-old female patient was a non-smoker. Her medical history did not reveal any peculiarities. The periodontal examination did not reveal any pathologies. Her dentition was largely free from caries. However, tooth #21 was deemed unsalvageable, owing to apical osteitis (Fig. 1). It was decided to replace the tooth (Fig. 2) with a 3.75 mm × 12.0 mm DENTAL RATIO implant (Meisinger).

Premedication and implant insertion

As for premedication, microbiological examination before surgery and optional therapy with antibiotics have been proved to be successful. To this end, the authors usually prescribe amoxicillin–clavulanic acid (Augmentin 875 mg/125 mg, GlaxoSmithKline), to be administered three times a day. Before surgery, plaque was removed by means of professional dental cleaning. In addition, HELBO therapy was carried out. The principle of this approach is based on the binding of photoactivated substances to the bacterial cell wall and their activation by light of a defined wavelength. Local anaesthesia was administered with Ultracain D-S forte (Sanofi-Aventis Deutschland). For the incision, a 14C scalpel (Aesculap) was employed while optimally preserving the gingival mucosa (Fig. 3). The preparation of the osteotomy commenced with a pilot drill (1.80 mm), which was then continued with a drill (2.28 mm) and a final drill (3.20 mm). The machined implant was inserted to a torque of 40 Ncm. The thorough evaluation of the peri-implant soft tissue and the bony tissue at bottom of the osteotomy was carried out by means of standardised methods. The gingiva was evaluated according to the papillary bleeding index by Saxer and Mühlemann.[1] Also, an evaluation by means of the sulcus bleeding index was done.

Augmentation

If there is insufficient bone volume for successful rehabilitation with dental implants, bone augmentation with autologous bone or bone grafts of other origin is required. In this context, the use of autologous bone is still considered the gold standard. In addition to their osteoregenerative effect, bone grafts must have the following properties: they have to be sterile; they have to be biocompatible; they should provide suitable biomechanics in that they need to withstand mechanical forces; they should be resorbable (in order to maintain the contour of the alveolar ridge or support the soft tissue, a slowly resorbed or non-resorbable bone graft may be a suitable choice); ideally, they should be osteoconductive; and they should be bioactive, since a solid connection between healthy vital bone and bone grafts is required for successful bony integration of the material. In the present case, NanoBone (Artoss) was used for augmentation (Figs. 4 & 5). Its structure leads to quick bone formation. Once the granulated substance is mixed with blood, it can be easily applied with a spatula or augmentation spoon.

Fig. 6: Final radiograph. **Fig. 7:** View of the definitive restoration shows a satisfactory aesthetic result.

Postoperative care

Acute peri-implant complaints are characterised by the following symptoms: pain, swelling, pus extrusion, bleeding on probing and implant mobility, loss of peri-implant hard tissue and increased probing depth. Postoperative follow-up appointments are conducted according to the criteria of Albrektsson et al. and Buser et al.[2,3] In the present care, treatment success was evaluated with a view to the following parameters: implant stability, a good macroscopic character of the implant surface, satisfactory results of the periodontal testing, little plaque occurrence and the absence of osteolysis indicators on the control radiograph (Fig. 6 & 7).

Discussion and conclusion

The loss of a tooth in the maxillary anterior area leads to impairments in terms of social interactions, in addition to functional ones. For the treating dentist, the paramount objective should therefore be to reconstruct the red–white aesthetics as perfectly as possible. In the case described, a satisfactory treatment outcome and high patient satisfaction could be achieved. In smokers, the baseline situation can be problematic, as implant loss rates are significantly higher in heavy smokers than in non-smokers. Studies have shown a higher implant loss rate of 5–9%. In smokers, the occurrence of marginal bone loss is also significantly higher than in non-smokers. Moreover, when employing the maxillary sinus for implants, implant loss occurs twice as often in smokers than in non-smokers.

Conflicts of interest: Dr Inge Schmitz declares that she has no conflicts of interest.

Acknowledgements: Dr Dr Branislav Fatori would like to thank Ulf-Christian Henschen from DENTAL RATIO in Langenfeld in Germany and Dr Walter Gericke from Artoss in Rostock in Germany for their support.

Dr Dr Branislav Fatori

Dr Inge Schmitz

Literature

about the authors

Dr Dr Branislav Fatori has more than four decades of experience in implantology. In addition to his German doctoral degree, he holds a second doctoral degree from the University of Belgrade in Serbia. He was trained at prominent clinics around the globe and has worked as a consultant for expert societies and implant manufacturers.

Dr Inge Schmitz has worked at the Institute of Pathology of the Ruhr University Bochum in Germany since 1990. Her main interests are implantology, stents, electron microscopy and osteology. She studied biology at the Ruhr University Bochum and completed her PhD at the then University of Essen in Germany in 1989.

contact

Dr Dr Branislav Fatori
Essen, Germany
+49 201 8218-8890
info@fatori.de
www.fatori.de

Dr Inge Schmitz
Georgius Agricola Stiftung Ruhr
Institut für Pathologie
Ruhr University Bochum
Bochum, Germany