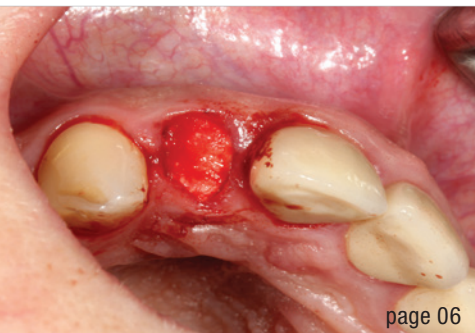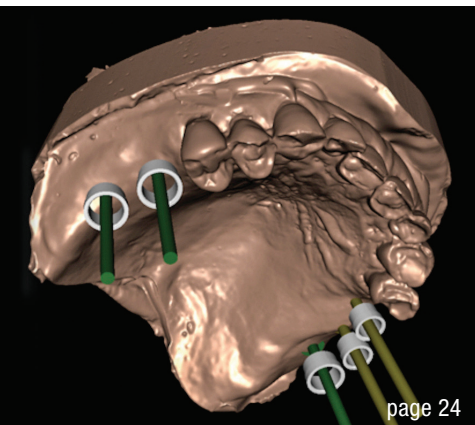

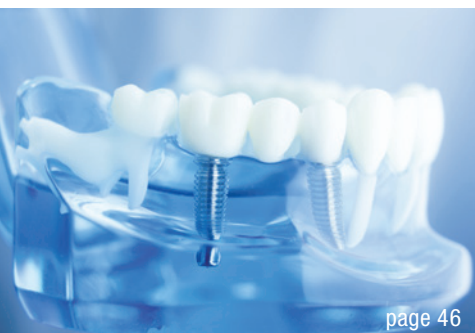
page 06



page 24



page 46

Cover image courtesy of
TBR Dental / www.tbr.dental



editorial

Dental **implantology** in times of crisis 03
Dr Georg Bach

case report

Delayed **immediate** implant placement and direct **soft-tissue** management 06
Dr Haki Tekyatan

Restorative simplicity for a challenging case with limited space 14
Dr Fernando Rojas-Vizcaya & Jose de San Jose Gonzalez

Immediate fixed **full-arch** rehabilitation of periodontitis patients 16
Prof. João Caramês

Graft volumetric changes of **collagenated** xenograft 24
Dr Livio Lo Faro, Dr Francesco Giachi Carù & Prof. Tiziano Testori

Dental lasers against **peri-implantitis** 34
Dr Bradley Labrecque

Successful **rehabilitation** of an anterior tooth 36
Dr Dr Branislav Fatori & Dr Inge Schmitz

interview

On remaining **vigilant** 38
An interview wiith Julien Benhamou

obituary

The inventor of the Bicon system has passed away 40

news

manufacturer news 42

news 48

events

Dental implant quality **under scrutiny** 46
Dr Dirk U. Duddeck

about the publisher

imprint 50

FLEX YOUR MUSCLES

OUR SHORTCUT TO IMMEDIACY:
CONELOG® PROGRESSIVE-LINE FLEX



PROSTHETIC SIMPLICITY AND CLEVER TRAY

- Consequently prosthetically oriented implant system
- Small tray with all instruments you need for implant placement
- Washtray function: validated for reprocessing
- Implant design for high stability in soft bone [1,2]

EXPERIENCE THE PROGRESSIVE EFFECT.



video animation

CURIOUS? PHONE +49 7044 9445 239

sales@camlog.com

www.camlog.com

References

- [1] Conserva E. Initial stability after placement of a new buttress threaded implant. A case series study. *implants*. 2019(3):24-28.
- [2] Ruppin J. One-year clinical experience with Progressive-Line implants. *EDI journal*. 2020(4):54-63.

camlog

 **biohorizons
camlog**