

implants

international magazine of oral implantology



case report

Type 4 implant placement

interview

Periodontitis and peri-implantitis
in implant dentistry

events

Education across borders



KS system

BA SURFACE

*Strong!
Simple!
Easy!*

OSSTEM[®]
IMPLANT

AFI Avenir Park, Radlická 740/113c, 158 00, Prague 5, Czechia
T: +420 296 238 802 www.osstem.eu

Dr Georg Bach

President of the DGZI



Same procedure as **every** year?

Dear colleagues, when writing the editorial for this first issue of our **implants—international magazine of oral implantology**, the British cabaret sketch *Dinner for One* came to mind. Each time the legendary butler James asks the question “The same procedure as last year?”, he is answered with the catchphrase “The same procedure as every year, James!” by the lady of the house. Indeed, the situation in which we now find ourselves at the beginning of 2022 is reminiscent of exactly one year ago. In view of the agonising uncertainty, I too have the fear that it could be the same again at the beginning of 2023—the same procedure as...—because the fact is that the pandemic will not let us out of its clutches.

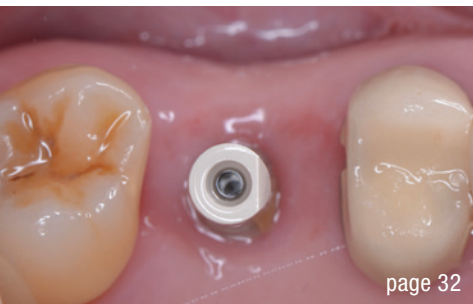
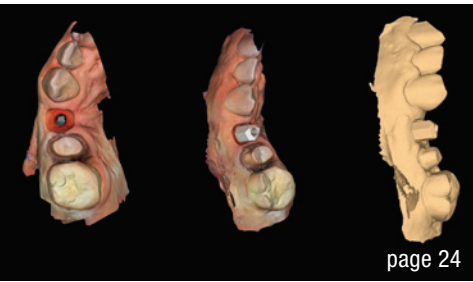
But what has happened in this past year, from editorial to editorial? The pandemic has changed our everyday lives and that of our practices for yet another year; it has thoroughly shaken things up again. But fortunately, there have also been beautiful moments, like the German Association of Dental Implantology's (DGZI's) grandiose birthday congress in Cologne last autumn, when the DGZI family celebrated the 50 plus one anniversary with many friends.

Do we have cause for resignation? There might be plenty of reasons, but resignation does not befit the spirit of our profession. Dentists are creators, and this should and will remain so. Let us—despite the adverse conditions—approach the new year positively and with vigour. The realisation that we are allowed to practise one of the most beautiful professions of all and the joy of our special discipline, dental implantology, allow us to generously overlook a thing or two.

Let us look forward to an exciting year and to many personal interactions with the members of our large and international DGZI family! I wish you well in your private and professional lives, success, much joy and, above all, the best of health.

Warm and collegial greetings,

Dr Georg Bach



Cover image courtesy of
bredent medical GmbH & Co. KG /
www.bredent-implants.com



editorial

Same procedure as **every** year? 03
Dr Georg Bach

case report

Radicular transplantation 06
Dr Renaud Girieud

Partial **extraction therapy** and implant treatment in the maxilla 12
Dr Snježana Pohl, Dr Mijo Golemac, Dr Daniela Grgić Miljanić,
Dr Pantelis Petrakakis & Prof. Jelena Tomac

Resolving severe bone **atrophy** 18
Dr Roberto Rossi, Dr Giovanni Franzone & Stefano Giuliani

Type 4 implant placement with custom healing abutment 24
Dr Pál Nagy

Maxillary **molar replacement** with an implant and **immediate** restoration 32
Dr Leandro Soeiro Nunes

interview

Periodontitis and **peri-implantitis** in implant dentistry 36
An interview with Dr Inga Boehncke

Laser protocol for **peri-implantitis** treatment 38
An interview with Dr Michał Nawrocki

news

manufacturer news 40

news 48

industry

Osstem Europe: **New European headquarters** in Prague 43
Henrik Eichler

events

Education across **borders** 44
Janine Conzato

about the publisher

imprint 50

NovoMatrix™ Reconstructive Tissue Matrix – the next generation material

NovoMatrix™ Reconstructive Tissue Matrix is an acellular dermal matrix derived from porcine tissue intended for soft tissue applications. The proprietary LifeCell™ tissue processing is designed to maintain the biomechanical integrity of the tissue, which is critical to support tissue regeneration.

Indications

- Localized gingival augmentation to increase keratinized tissue (KT) around teeth and implants
- Alveolar ridge reconstruction for prosthetic treatment
- Guided tissue regeneration procedures in recession defects for root coverage

Product features

- Consistent thickness (1 mm)
- Pre-hydrated
- Controlled source

www.biohorizonscamlog.com

Before use, physicians should review all risk information, which can be found in the Instructions for Use attached to the packaging of each NovoMatrix™ Reconstructive Tissue Matrix graft. NovoMatrix™ is a trademark of LifeCell™ Corporation, an Allergan affiliate. ©BioHorizons. All rights reserved. Not all products are available in all countries.



MinerOss™ A The allograft for outstandingly fast bone remodeling [1]

The scientific evidence shows that allografts are the second best option to patient's own bone compared to other bone substitutes. [2]

Benefits of MinerOss™ A human bone substitute [1, 3–5]

- Optimal osteoconductivity
- Fast graft incorporation
- Complete remodeling potential

www.biohorizonscamlog.com



[1] Wen et al. J. Periodont. 2019, 1, 734.
 [2] Schmitt et al. Clin Oral Implants Res. 2013, 24, 576.
 [3] Kloss et al. Clin Oral Implants Res. 2018, 29, 1163.
 [4] Solakoglu et al. Clin Implant Dent Relat Res. 2019, 21, 1002-1016.
 [5] Kloss et al. Clin Case Rep. 2020, 8, 5.
 References available at: www.biohorizonscamlog.com/references_mineross



MinerOss™ A is a trademark of BioHorizons®. BioHorizons® is a registered trademark of BioHorizons. ©BioHorizons. All rights reserved. Not all products are available in all countries.



Radicular transplantation

The use of dental roots in the treatment of bone insufficiency

Dr Renaud Girieud, France

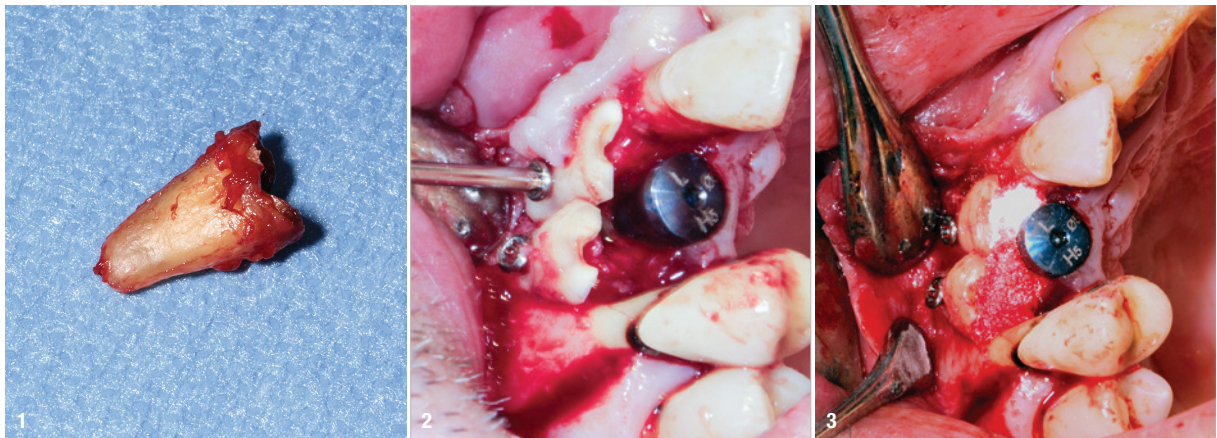


Fig. 1: Extracted root for radicular graft. **Fig. 2:** Radicular grafts are polarised. **Fig. 3:** Space between the graft and ridge filled with a filling material.

Treating bone insufficiency is a familiar challenge for all implant practitioners. Such insufficiency can compromise the placement of an implant, its long-term viability and even the anticipated aesthetic outcome. In summary, where there is a bone defect, there are two broad treatment types available to us. Firstly, there is guided bone regeneration. This combines a membrane and a biomaterial, of which there are several variants, depending on the type of membrane and the materials used.¹ Secondly, we can use autogenous bone in block or chip form as an onlay or supporting structure, according to the technique developed by Prof. Fouad Khoury.²

Depending on the skill and experience of the surgeon, these various techniques can necessitate several operations, and it can be months before an implant can be placed into the arch.

However, there is a third way to treat bone insufficiency, based on the principle of ankylosis and root resorption, by block grafting the roots of the patient's own teeth. We will use the term "radicular graft" to refer to the root fragments used. This technique was originally described by the team working with Prof. Frank Schwartz, who proposed the grafting of dental roots in pre-implant

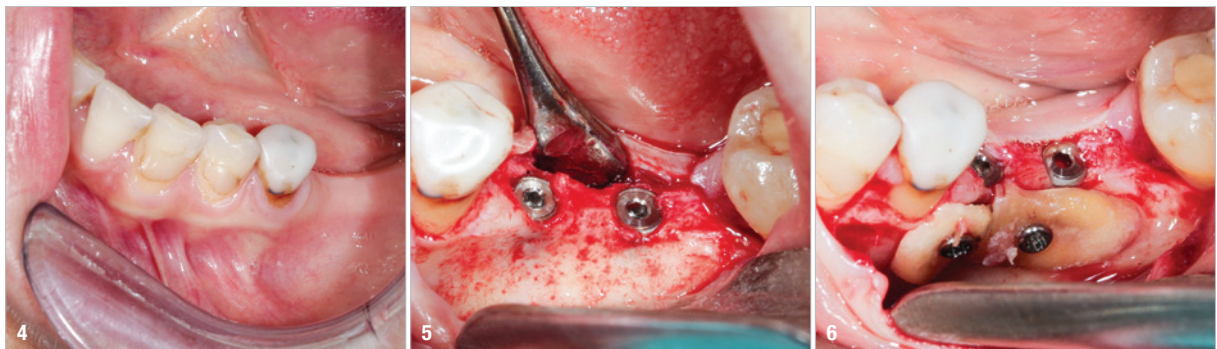

Fig. 4: Serious risk of dehiscence. **Fig. 5:** Low residual bone thickness in the vestibular area of the implants. **Fig. 6:** The roots were shaped to fit the defect and fixated at the insertion site using osteosynthesis screws.

Long?
Short?
Ultrashort?

The new copaSKY!

Innovative hybrid connection –
adequate space for soft tissue,
can be positioned subcrestally.



Open for next

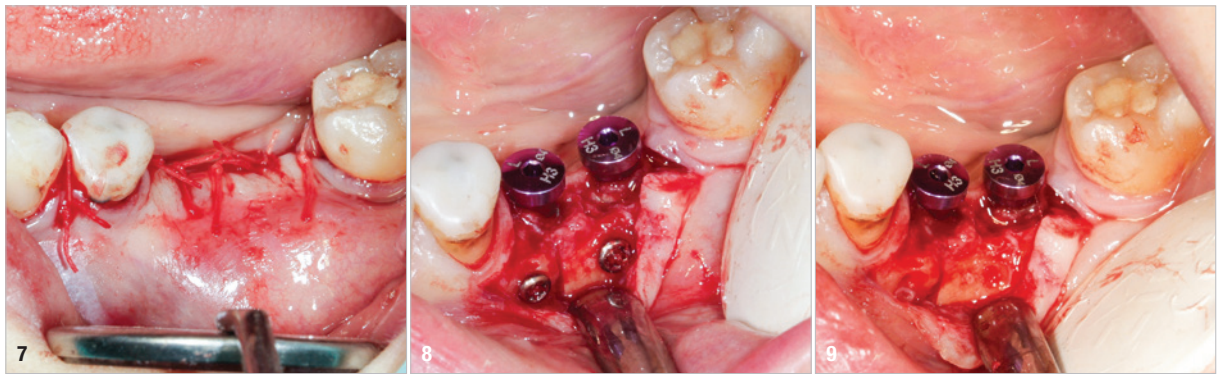

Fig. 7: A #4/0 rapidly resorbed braided thread was used for the sutures. **Fig. 8:** Healing abutments were connected to the implants. **Fig. 9:** The osteosynthesis screws were removed.

surgery in 2016.³ Through three clinical cases, we will discuss the scope of application for radicular grafts as we use them in our daily work in the dental surgery and how this has changed in comparison with the technique described by the team working with Prof. Schwartz.³ Our aim is to improve our patient's surgical experience and, whenever possible, to achieve bone augmentation and implant placement concomitantly. We have deliberately restricted our application to transverse bone insufficiency.

Materials and method

First, the root must be extracted; this will be the future radicular graft (Fig. 1). This is then prepared by polishing it gently to clean it and remove calculus deposits. The coronal section and any soft or decayed parts are removed.³ The root is cut into two using a disc. A diamond drill is used to clean the canals, and any debris from fillings is removed.³ If necessary, the root is cut again to shape it to match the defect, and holes are drilled into it for the osteosynthesis screws.³ The graft is fixated at the insertion site using osteosynthesis screws with the dentine in contact with the bone ridge and the cementum in contact with the soft tissue.³ Radicular grafts are actually polarised: the dentine must be in contact with the bone ridge to allow ankylosis, while the cementum, in contact with the soft tissue, acts as a barrier to prevent graft resorption by the soft tissue (Fig. 2). If the graft is being

used as a biological membrane and is intended to form a supporting structure, the space between the graft and the ridge is filled with a filling material (Fig. 3).

Case 1

A 36-year-old patient with teeth #36 and 37 missing and transverse bone insufficiency in the existing gap was treated. It would have been possible to place implants, but this would have left only a thin layer of vestibular bone at the neck of the implants. There was a serious risk of dehiscence, which can compromise the survival of the implant in the arch (Fig. 4).

We had three alternative courses of action: a bone block graft from the mandibular ramus,² a segmental osteotomy⁴ or a radicular graft, knowing that tooth #46 could not be saved. We chose the third option because it allowed for simultaneous implant placement and bone reconstruction. A large flap was elevated to assess the gap in the bone and in anticipation of closing the flap on an augmented ridge. Two implants were placed as normal despite the low residual bone thickness in the vestibular area of the planned positions for the implants (Fig. 5). The roots of tooth #46 were extracted atraumatically (root separation, use of piezo-surgery, etc.) and were then prepared as described. The roots were shaped to fit the defect and fixated at the insertion site using osteosynthesis screws (Fig. 6).³ The flap was mobilised and stretched

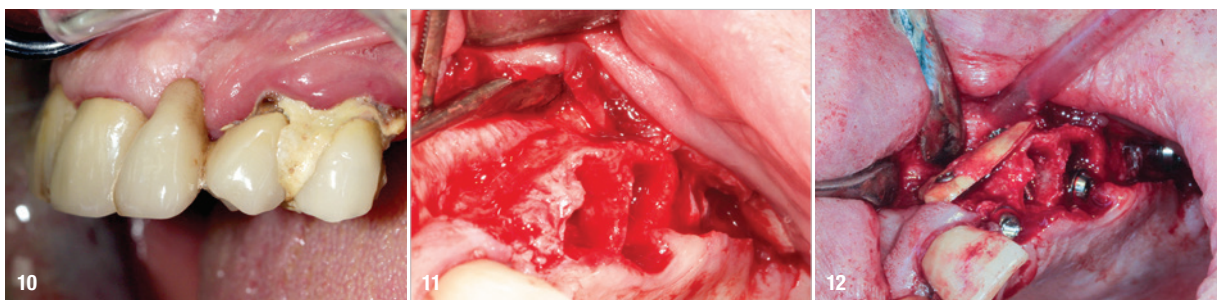
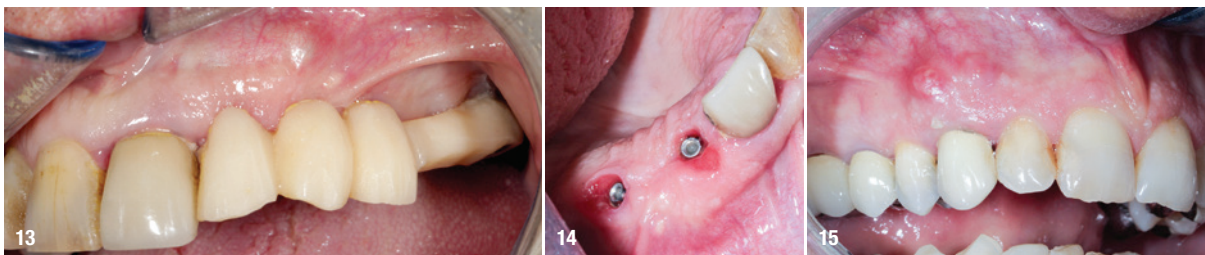


Fig. 10: Transverse bone insufficiency on the ridge of tooth #22. **Fig. 11:** Full-thickness flap elevation and extraction of teeth #23 and 24. **Fig. 12:** Edges of the radicular graft in contact with the alveolar bone.



Figs. 13 & 14: The osteosynthesis screws were not removed because they were not visible under the gingiva. **Fig. 15:** Radicular fracture at tooth #13 under a crown and with a fistula opposite.

to achieve edge-to-edge closure without tension, and a #4/0 rapidly resorbed braided thread was used for the sutures (Fig. 7). Four months after the bone augmentation and implant placement, healing abutments were connected to the implants and the osteosynthesis screws removed (Figs. 8 & 9). During the operation, time was taken to perform a visual check that ankylosis of the radicular grafts had been successful and that these were sound. Finally, a CBCT assessment was performed. The prosthesis was fitted by our colleague a few weeks later, once the soft tissue had healed.

Case 2

A 62-year-old patient with a bridge from tooth #21 to tooth #27 requiring replacement, teeth #21, 23, 24 and 27 with abutments and the crown of #22, 25 and 26 missing, was treated. The ridge of tooth #22 exhibited a transverse bone insufficiency which would have allowed the placement of an implant, but the aesthetic outcome would have been unsatisfactory (Fig. 10). First, the bridge of tooth #24 was sectioned distally and the root of tooth #27 extracted. After a two-month healing period, the patient was treated with simultaneous extraction, implantation and aesthetic restoration. The bridge was sectioned distally at tooth #21, a full-thickness flap was elevated and the teeth #23 and 24 were extracted, allowing the bone defect at tooth #22 to be assessed (Fig. 11). Implants were placed into sites #22, 24 and 27. The root of tooth #23 allowed us to compensate for the bone defect and achieve a satisfactory aesthetic result. The root was prepared as described. The radicular graft was fixated away

from the ridge, the edges of the graft in contact with the alveolar bone (Fig. 12). The spaces between the ridge, the graft and the alveoli were filled with a synthetic, hydroxyapatite-based biomaterial, the flap was stretched and sutured around the healing abutments, an impression was taken, and a temporary prosthesis from implant #22 to 27 was made during the day by the laboratory and fitted the same evening. The stitches were removed on the tenth day and the bridge after two months to check for the successful osseointegration of the implants. The osteosynthesis screws were not removed in this case because they were not visible under the gingiva (Figs. 13 & 14). A CBCT assessment was performed after six months to check that the graft had taken successfully. Finally, our colleague fitted the definitive prosthesis.

Case 3

A 55-year-old patient with a radicular fracture at tooth #13 under a crown and a fistula opposite was treated (Fig. 15). The plan was to treat this patient with simultaneous extraction, implantation and aesthetic restoration. Unfortunately, as sometimes happens and despite the precautions taken, a large part of the vestibular wall of the alveolus was extracted with the root, creating a significant bone defect. A full-thickness flap was elevated and the implant placed. The root was prepared and fixated with an osteosynthesis screw to replace the lost wall (Fig. 16). The space between the root and the implant was filled with a hydroxyapatite-based biomaterial (Fig. 17). This bone reconstruction was combined with a connective graft. The flap was stretched and sutured with a

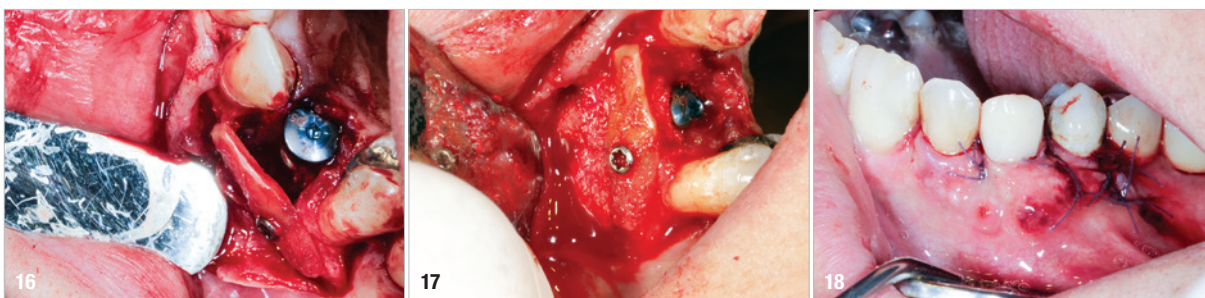
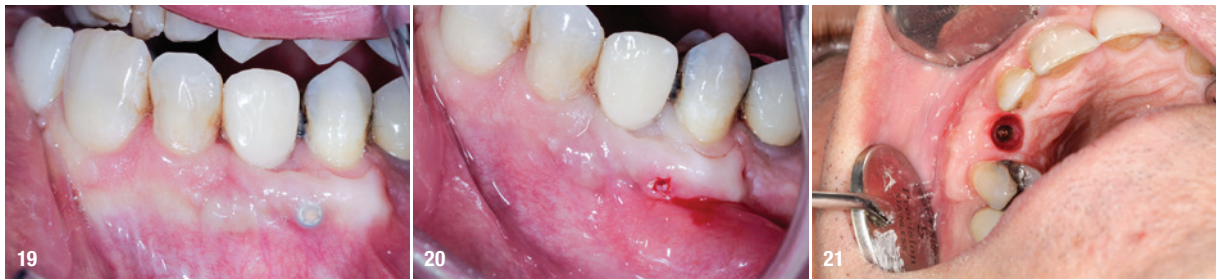

Fig. 16: Preparation of the root and fixation with an osteosynthesis screw to replace the lost wall. **Fig. 17:** The space between the root and the implant was filled with a hydroxyapatite-based biomaterial. **Fig. 18:** A #5/0 resorbable braided thread was used for the sutures.



Figs. 19 & 20: The osteosynthesis screw was visible under the gingiva and was thus removed after six months. **Fig. 21:** Fitting of the definitive prosthesis.

#5/0 resorbable braided thread (Fig. 18). An impression was taken and a temporary screw-retained prosthesis was made during the day by the laboratory and fitted the same evening. The sutures were removed on the tenth day. The temporary prosthesis was removed after two months to check that the implant had been successfully integrated into the bone. The osteosynthesis screw was visible under the gingiva and was removed after six months (Figs. 19 & 20). A CBCT assessment was performed at the same time. The radicular graft had ankylosed perfectly and the ridge regenerated *ad integrum*. The definitive prosthesis was fitted by our colleague (Fig. 21).

Discussion

Radicular grafts as graft materials have many of the same characteristics as autogenous bone, plus some of the advantages of biomaterials. Moreover, they are autogenous materials consisting of a mineral fraction, an organic fraction (the patient's own proteins) and water, in proportions comparable to those found in alveolar bone.³ They are thus identified as part of the patient's body and do not cause an inflammatory response as occurs with foreign bodies. They are highly compatible with the soft tissue that covers them if no sharp or cutting edges are left when the wound is closed. They allow for remarkably high-quality, fast healing. They can be used in two different ways, either as a stand-alone block or as a biological membrane in combination with a biomaterial.^{3,5,6} Initially, there is ankylosis of the root on the ridge, then centrifugal resorption replaces this.³ The root is resorbed and replaced by bone, as expected under the principle of root resorption. What differs is that when the graft is fixated at a distance from the ridge we also observe the formation of new bone between the dentine and the graft. The material exhibits osteoconductive and osteoinductive properties.^{3,5,6} The grafts are easy to extract. There is no specific protocol or storage period: during the operation, before they are used, they can be left quite safely open to the air in the operating theatre with no consequences. These solid blocks are unaffected by muscle tension and are easy to shape with a bur or a disc. They make it possible to restore the horizontal shape of the ridge. They have a certain plasticity, which means that they can be flexed slightly to create curvature without breaking them.^{3,5} Their slow

resorption gives them great volumetric stability over time, so the volume of the graft extracted always regrows.^{5,7} The major downside is their availability. Whether from roots extracted during a dental extraction or implantation, third molars or condemned teeth, this substance is only available in limited quantities.

In conclusion, as demonstrated in these three cases, this technique has enabled us to combine implant placement consistently and successfully with bone reconstruction and even to fit temporary prostheses on the same day. We have been able to achieve our surgical, mechanical and aesthetic objectives while minimising the trauma of surgery for our patients, since they only undergo one operation. Given the characteristics and the many advantages associated with these radicular grafts, this technique is now our treatment of choice when condemned roots are available. In this first article, we have chosen to present only simple cases to explain the technique. However, having now used it to treat several dozen patients, we have been able to broaden the scope of what we can accomplish with this technique. It has allowed us to treat complex aesthetic cases which would previously have been impossible to treat with surgery in a straightforward, predictable way. We intend expanding on this subject in a second article.

about the author



Dr Renaud Girieud has a European master's degree in dental implantology, clinical surgery, prosthetics and bone grafts from Goethe University in Frankfurt am Main in Germany. He received university diplomas in maxillofacial surgical rehabilitation from Paris Diderot University and in clinical periodontics from Aix-Marseille University, both in France.

contact

Dr Renaud Girieud
Eyguières, France
girieud.renaud@wanadoo.fr



The universe at your fingertips.

TwinLight[®] Peri-implantitis Treatment

A simple and effective procedure that offers the power to treat peri-implantitis – an increasing threat to oral health.

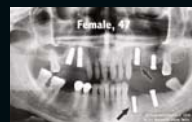- Minimally-invasive technique
- Fast regeneration/healing
- Reduced inflammatory response
- Highly effective treatment
- No antibiotics needed



LightWalker[®]

The ultimate all-in-one hard and soft tissue laser

Peri-implantitis treatment video



Partial extraction therapy and implant treatment in the maxilla

Two years of follow-up

Dr Snježana Pohl, Dr Mijo Golemac, Dr Daniela Grgić Miljanić, Dr Pantelis Petrakakis & Prof. Jelena Tomac, Croatia & Germany

Introduction

Various techniques and methods based either on grafting of the fresh extraction socket (ridge preservation) with different materials and delayed implant placement or on immediate implantation with grafting of the gap between implant and socket wall have been applied in order to prevent ridge alterations after tooth extraction. However, insights concerning superiority of the type of grafting technique or material are scarce.^{1,2} Partial extraction therapy, leaving either the whole root (root submergence therapy) or the buccal part of the root (socket shield technique) of hopeless teeth inside the extraction socket, may have clinical significance as an alternative to conventional preservation procedures. These techniques are based on the observation, made already 80 years ago, that resorption of the bundle bone within the extraction socket may be reduced by leaving the root or a root fragment inside the socket, attached by a healthy periodontal ligament to the buccal socket wall, providing good blood supply to the hard and soft tissue.³⁻⁵ This procedure was forgotten until 2007, when Salama et al. published a case report showing an implant-supported bridge with perfectly maintained hard and soft tissue by leaving a root submerged in the pontic area.⁶ Likewise, the socket shield technique has been shown to be an efficient technique for reducing the amount of post-extraction ridge resorption as well.⁵ The present case report introduces ridge preservation with root submergence therapy and the socket shield technique, as well as augmentation with particulate autologous dentine, in the course of an implant and prosthetic rehabilitation in a partially edentulous maxilla.

Patient situation

The 58-year-old, non-smoking and systemically healthy female patient was referred by her dentist to our dental clinic for implant treatment. The patient's main complaints were poor aesthetics in the upper jaw, including a high smile line and distinct tooth pattern anomalies in the anterior maxilla (Figs. 1 & 2), as well as masticatory discomfort. Teeth #17, 15 and 27 were missing and had not undergone any prosthetic treatment, whereas the five missing teeth in the premolar and molar areas on both sides of the mandible had been replaced with a removable partial denture. All remaining teeth were affected by Stage IV periodontitis according to the 2017 Classification of Periodontal and Peri-implant Diseases and Conditions, displaying a mean periodontal pocket depth of 5.6mm.⁷ Mean bleeding on probing and mean plaque index were 70% and 80%, respectively. With respect to periodontal parameters, as well as to oral hygiene measures (visible calculus and dental plaque), the patient's oral hygiene was graded as poor. The patient had been treated elsewhere with two implants in the posterior maxilla in order to replace the right first premolar and first molar (Fig. 3). She had a thick flat biotype, according to a definition introduced in 1977.^{8,9}

Diagnostics and treatment planning

After obtaining informed consent from the patient, we would start dental rehabilitation in the maxilla, and we opted for a two-stage surgical approach after initial therapy. Initial therapy would consist of systematic periodontal

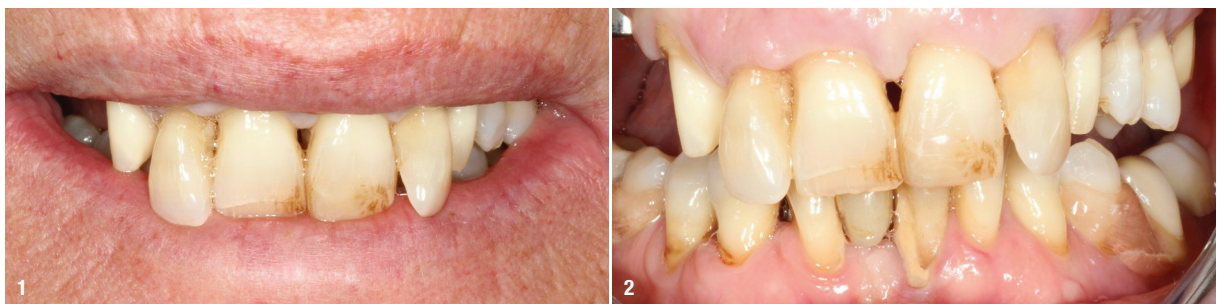


Fig. 1: Patient's initial situation, extra-oral aspect. **Fig. 2:** Patient's initial situation, intra-oral aspect.

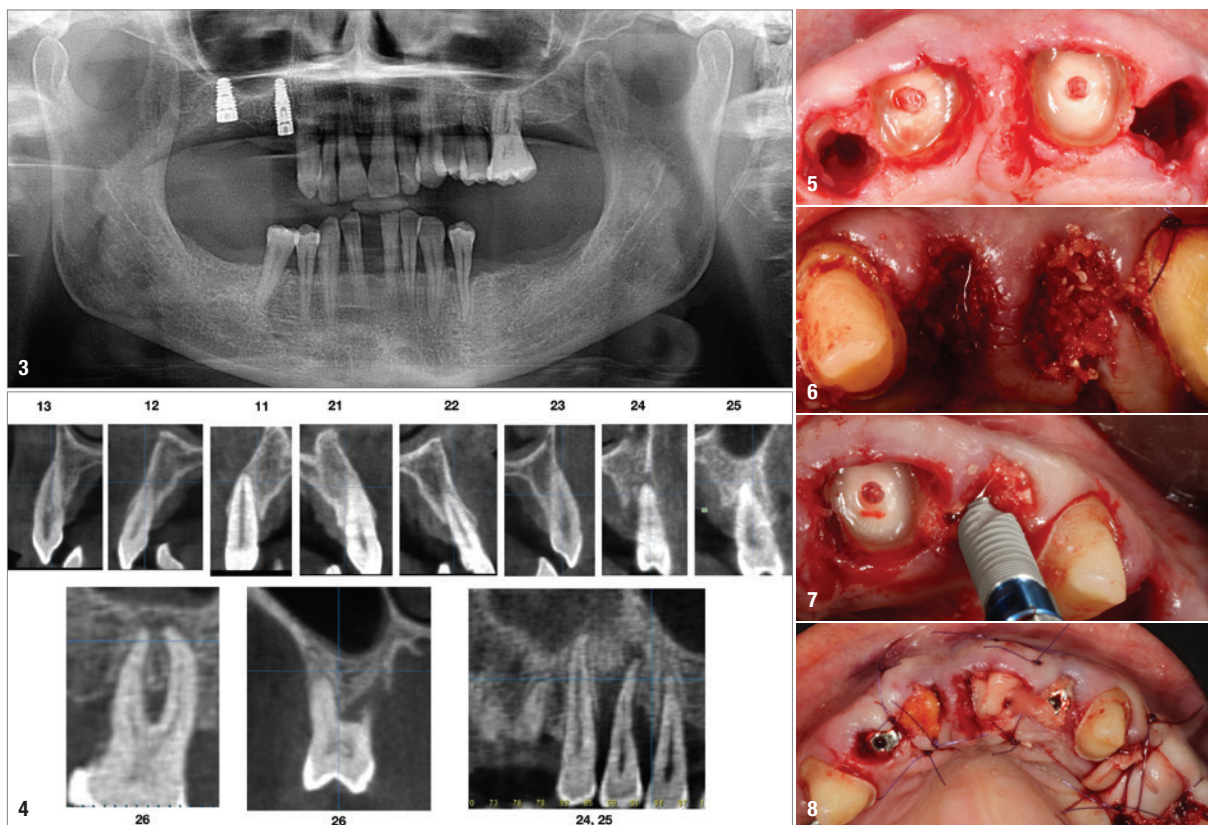


Fig. 3: Initial radiograph before treatment. **Fig. 4:** CBCT scan showing the bone condition of the maxillary teeth. Vertical resorption and reduced thickness of the buccal bone plate of the right and left central incisors were evident. **Fig. 5:** Clinical situation after partial extraction of tooth #12, extraction of tooth #22, and root submersion of teeth #11 and 21. **Fig. 6:** Clinical situation after extraction of teeth #24 and 25 and augmentation with autologous dentine. **Fig. 7:** Immediate implant placement into the fresh extraction socket of tooth #22 after ridge grafting with autologous dentine. **Fig. 8:** Clinical situation after completion of first-stage surgery.

treatment and regular recalls with instructions and checks for dental hygiene over a period of three months. The first stage of rehabilitation of the maxilla would consist of partial extraction therapy in conjunction with Type 1 implant placement in the regions of the teeth #12 and 22 according to the Proceedings of the Fourth ITI Consensus Conference and ridge preservation in the region of teeth #24 and 25 with particulate dentine, obtained and processed from the two extracted left maxillary premolar teeth.¹⁰ Owing to increased tooth mobility and the obvious poor buccal bone volume, as displayed on the CBCT scan (CRANEX 3D Ceph, Soredex, KaVo Kerr), regions #11 and 21 were not suitable for the socket shield technique in conjunction with implant placement (Fig. 4). Both central incisors were to be treated with the submerged root technique instead, in order to prevent damage of the buccal socket wall and volume loss of the alveolar ridge after tooth extraction. With both roots in place, a physiological pontic site development for the definitive restoration would be enabled. Based on periodontal re-evaluation after the initial therapy, only the two maxillary canines were considered worth preserving. The left first molar was to be temporarily retained in order to serve, in conjunction with the two canines, as an additional abutment tooth for fixation of the temporary bridge during the healing period. Crown preparation of the three remaining teeth would be

done before surgical treatment, in order to prefabricate a temporary bridge for immediate fixed provisionalisation after the first surgery. The second surgical stage would consist of implant placement in region #24, performing of the socket shield technique on the mesiobuccal root, submersion of the distobuccal root and extraction of the palatal root of tooth #26 before immediate implant placement. Definitive prosthetic treatment would be performed after a transgingival implant healing period of at least three months, applying a conventional implant loading protocol with fixed bridges.¹¹

Surgical intervention

Both surgical interventions were performed under local anaesthesia, and antibiotic medication (a single dose of 2g of amoxicillin) was administered 60 minutes before surgery. The first stage of rehabilitation of the maxilla involved immediate implant placement in the post-extraction sockets of both lateral incisors in combination with the socket shield technique for the right lateral incisor. Owing to an increased tooth mobility of more than Grade II, the socket shield technique was contra-indicated for the left lateral incisor and both premolars. The clinical crowns of both central incisors were decapitated, and the roots were carefully prepared with a round diamond bur under rinsing with

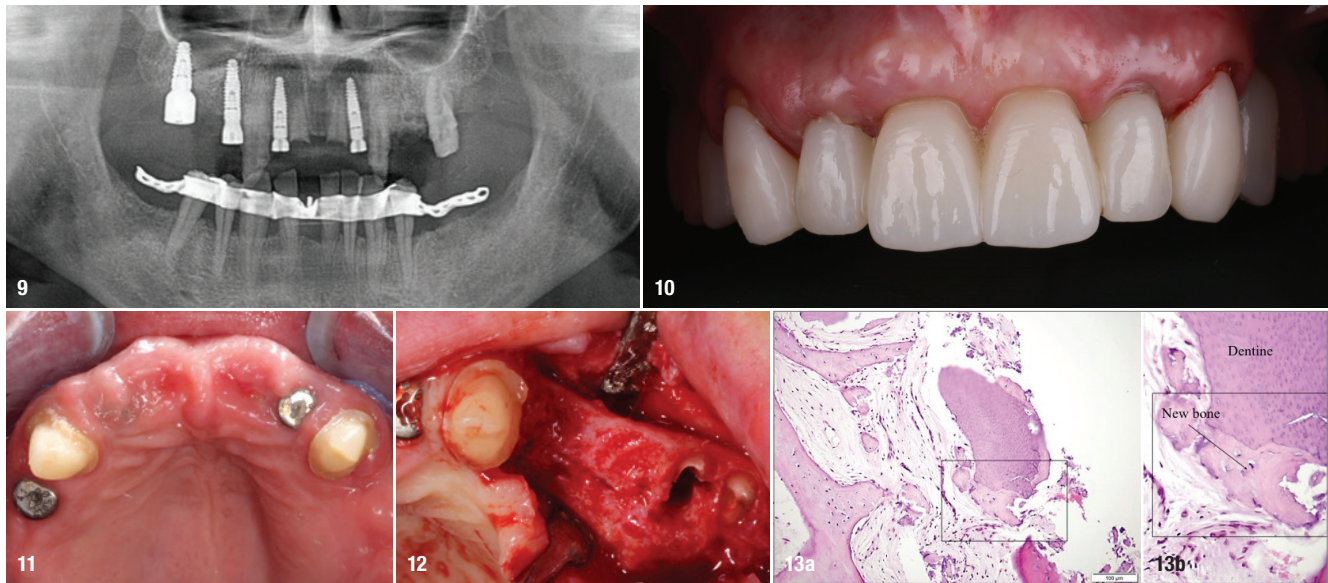


Fig. 9: Radiograph after first-stage surgery. **Fig. 10:** Temporary bridge. **Fig. 11:** Clinical situation after a three-month healing period, displaying proper volume of the alveolar ridge in the maxilla. **Fig. 12:** Clinical situation during second-stage surgery after flap elevation, displaying proper bone regeneration in the premolar area after ridge preservation with autologous dentine. **Figs. 13a & b:** Histological images showing new bone formation in close contact with dentine particles.

sterile saline solution, until both cranial root edges reached a distance of 3 mm from the gingival margin (Fig. 5). In the right lateral incisor site, a socket shield was prepared as described by Gluckman et al.¹² The extracted premolars were mechanically cleaned and then dried and processed with the Smart Dentin Grinder (KometaBio) according to the manufacturer's recommendations.¹³ After implant site preparation, particulate dentine was applied into the prepared left lateral incisor implant site, and both extraction sockets of the left premolars (Fig. 6). Implant placement was performed in the extraction sites of both lateral incisors with two BEGO Semados RSX implants (BEGO Implant Systems) with a length of 13.00 mm and a diameter of 3.75 mm (Fig. 7). Peri-implant gaps were grafted with particulate dentine autograft and sealed with platelet-rich fibrin (PRF) membranes using the Poncho technique.¹⁴ After buccal and palatal tunnel preparation, the premolar extraction sockets and submerged left central incisor root were covered with PRF membranes, prepared according to the Choukroun method (A-PRF, mectron) after centrifugation at 1,300rpm for 13 minutes.¹⁵ The right central incisor was covered with a connective tissue graft harvested from the palatal mucosa of the first quadrant. Covering membranes and the connective tissue graft were introduced into the buccal and palatal tunnel preparations and fixed with absorbable monofilament #5/0 suture thread (Serafast, Serag Wiessner; Fig. 8). The postoperative radiograph showed adequate root submersion of the central incisors, correct implant positioning in the lateral incisor sites and proper filling of both premolar extraction sockets (Fig. 9). The patient was provided with the fixed provisional bridge (Fig. 10) and prescribed amoxicillin (1 g three times a day for five days after surgical intervention). Postoperative healing was uneventful.

At the time of the second surgical intervention, three months after the first surgery, no obvious volume loss of the maxillary alveolar crest was noticed (Fig. 11). Second-stage surgery was performed in the left posterior maxilla with an open flap approach. After elevation of the mucoperiosteal flap, very good preservation of bone volume was observed, indicating successful ridge preservation by means of particulate dentine as the augmentation material (Fig. 12). Partial extraction therapy was performed for the right first molar. After decapitation, socket shield therapy of the mesiobuccal root and submersion of the distobuccal root was performed. After extraction of the palatal root, the implant site was prepared in the septum and the sinus membrane was concomitantly lifted by the use of an osseodensification protocol with Densah burs (Versah).¹⁵ After sinus grafting with Gen-Os (OsteoBio), a particulate collagenated corticocancellous bone mix of porcine origin, a BEGO Semados RSX implant with a length of 13.0mm and a diameter of 4.5mm was placed. Another BEGO Semados RSX implant with a length of 13.0mm and a diameter of 4.1 mm was placed into the first premolar region. In order to evaluate the remodelling process after ridge preservation with the dentine autograft histologically, a histological sample was harvested with a trephine bur from the first premolar region during implant preparation. Histological analysis revealed new bone formation in close contact with dentine particles and no signs of inflammation or fibrous encapsulation of the autologous augmentation material (Fig. 13). Immunohistochemistry was done in order to evaluate osteoblast differentiation and bone formation. New bone formation was confirmed by osteoblasts, being marked by antibodies against Osterix (Anti-Sp7/Osterix antibody,

ChIP grade, ab22552; Abcam). All implants healed uneventfully during a period of four months.

Prosthetic treatment

Definitive prosthetic treatment was performed after completion of implant healing with three CAD/CAM-fabricated monolithic zirconia bridges (DD cubeX², Dental Direkt). The bridges were screwed on to BEGO titanium base abutments (Figs. 14–16). Good fit of the prosthetic superstructures was displayed in the radiograph after placement (Fig. 17). The two-year follow-up examination in July 2019 revealed excellent aesthetic and clinical soft-tissue conditions (Figs. 18–20). No radiographic bone loss had occurred at the implant sites (Fig. 21). Neither the submerged central incisors nor the distobuccal molar root displayed any signs of periapical inflammation, and the patient reported no complications. The patient's oral hygiene had improved significantly during the follow-up period.

Discussion

The key objective of the present treatment approach was maintenance of maximal ridge volume for both aesthetic and functional reasons as described in a recently published technical report.¹⁶ A staged approach using a few teeth to support a provisional fixed restoration during the healing process was applied for a number of reasons: (1) immediate implant placement after the extraction of hopeless teeth was contra-indicated in the premolar area owing to the poor periodontal state; (2) a fixed provisional prosthesis would enable soft-tissue conditioning during healing;¹⁷ and (3) surgical burden, postoperative morbidity and additional costs could be reduced for the patient through the application of partial extraction therapy, an osseodensification protocol for bone expansion, compaction and crestal sinus elevation, and autologous dentine as augmentation material. Root submergence therapy of both central incisors was chosen in our patient case as the procedure of choice in order to avoid unfavourable buccal bone remodelling. Submerged root therapy is based on reports from the early 1940s that showed that fractured roots may be retained in the extraction socket without any pathological clinical symptoms if they are protected by epithelial gingival overgrowth.^{3,4} Since the alveolar bundle bone and periodontal ligament are preserved, submerged root therapy appears to be a promising technique for ridge preservation in conjunction with conventional prosthetic treatment. The presence of the periodontal ligament seems to preserve a higher amount of surrounding hard and soft tissue, compared with conventional socket preservation techniques.^{6,18} Reduction of root heights in order to maintain a sufficient soft-tissue thickness of 3 mm between submerged roots and the gingival margin and future pontic base, respectively, as well as dense primary

closure of submerged roots with connective tissue grafts or fibrin membranes, seems to be a prerequisite for a rapid healing process and for successful submersion of root segments.^{19,20}

Hinze et al. demonstrated in a cohort study successful preservation of alveolar width and height by applying the socket shield technique in conjunction with immediate implant placement, producing no midfacial recession or increased probing depths.²¹ The main concerns with the socket shield technique still lie in the limited evidence, specifically the need for randomised controlled studies, in order to enable more evidence-based insights.

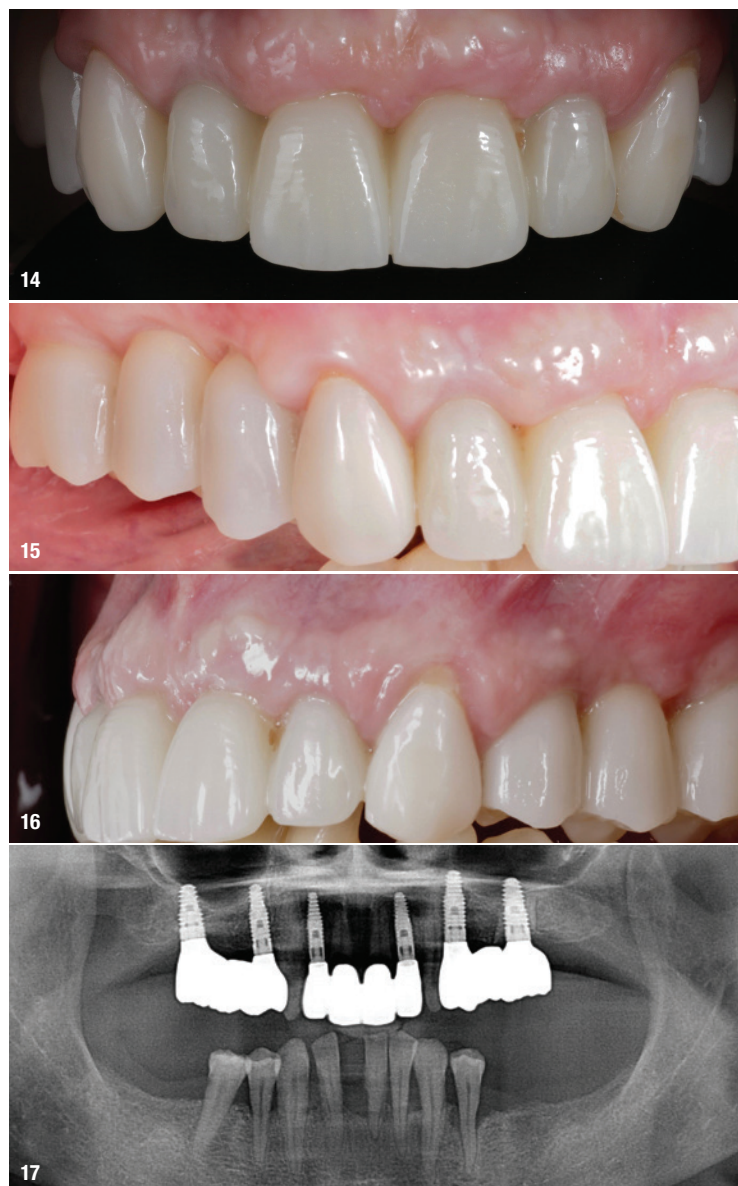

Fig. 14: Frontal aspect of the definitive prosthetic restorations, showing good aesthetic conditions with no signs of soft-tissue complications after insertion. **Fig. 15:** Right lateral aspect of the restorations. **Fig. 16:** Left lateral aspect of the restorations. **Fig. 17:** Final radiograph with definitive prosthetic superstructures in place.

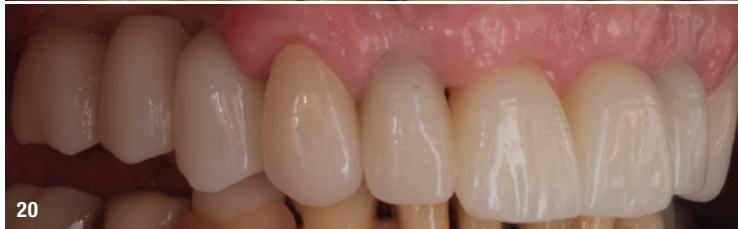
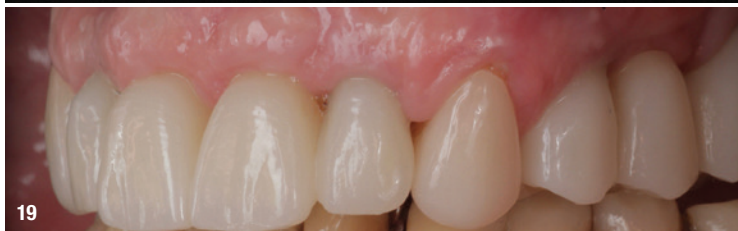
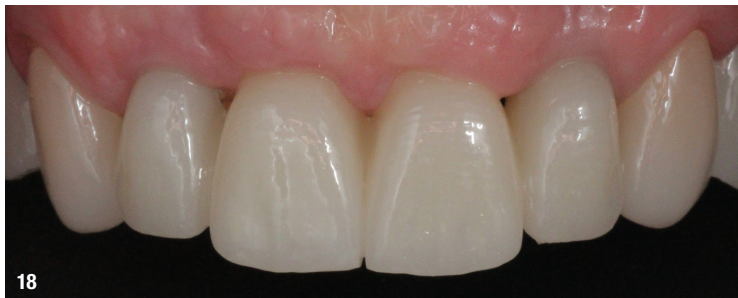Fig. 18: Frontal aspect of the restorations after the two-year follow-up period. **Fig. 19:** Right lateral aspect of the restorations after the two-year follow-up period. **Fig. 20:** Left lateral aspect of the restorations after the two-year follow-up period.

Autogenous particulate dentine has gained attention as an alternative grafting material to autologous bone and bone substitutes. Despite the fact that dentine is an acellular matrix, bone and dentine are very similar in their biochemical structure, comprising mainly Type I collagen

with growth factors like bone morphogenetic protein (BMP-2) and fibroblast growth factors.^{22,23} The present histological and clinical findings after ridge preservation with autologous dentine are in line with the insights of clinical studies, including new bone formation, favourable wound healing and good dimensional stability.^{24,25} Clinical aspects in connection with re-entry in the left posterior maxilla showed very good ridge dimensions after three months. The present clinical and histological results confirm suitability of particulate dentine autograft as augmentation material for ridge preservation, retaining adequate dimensional stability and holding osteoinductive and osteoconductive capacity.

In our present case, implant site preparation of the molar septum after partial extraction of the right maxillary first molar, as well as the simultaneous trans-crestal sinus elevation, could be performed by using the osseodensification protocol with Densah burs.²⁶ Osseodensification has been shown to increase bone mineral density and bone to implant contact and to enhance primary implant stability, compared with standard drilling.^{27,28} Nonetheless, this technique should be used with caution, because of a limited number of long-term studies.^{29,12} The main concerns with the socket shield technique still lie in the technique sensitivity of this method and the need for randomised controlled studies in order to enable evidence-based insights and transfer of this technique into routine dental practice.³⁰ However, the present case report encourages the application of different preservation procedures as alternative clinical methods for successful ridge preservation. Corresponding patient cases are intended for presentation in future publications.

about the author



Dr Snježana Pohl is a doctor of both general medicine and dental medicine and holds a specialisation in oral surgery, periodontics and implantology. She is currently based in Rijeka in Croatia, where she practises, teaches and mentors. Since 2010, she has been head of the department of oral surgery at Rident dental clinics in Croatia.

She also teaches as an assistant professor at the Department of Oral Medicine and Periodontology of the Faculty of Dental Medicine at the University of Rijeka.

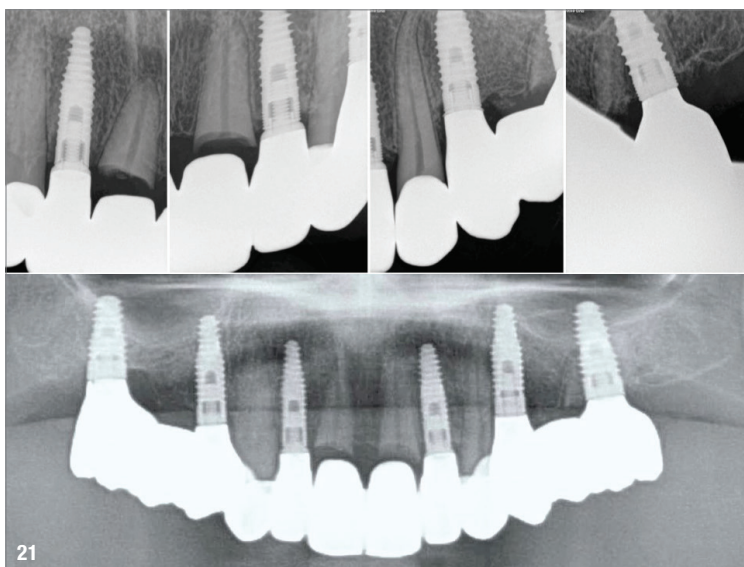


Fig. 21: Radiographic control after the two-year follow-up period, showing no visible bone loss at the implant sites and no signs of periapical inflammation at submerged roots.

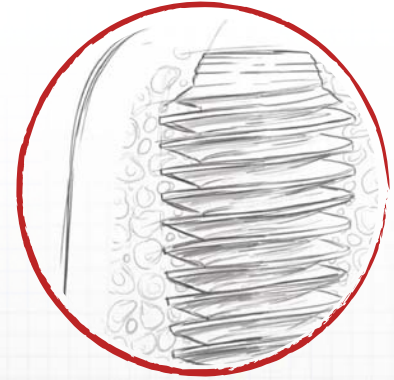
contact

Dr Snježana Pohl
 +385 51 648900
 snjezana.pohl@rident.hr
 www.snjezanapohl.com



Compress®

Implant



Softbone stability!

Available in 8, 9, 11 and 13 mm length with 4.0, 4.5, 5.0, 5.5 and 6.0 mm diameter

Beveled shoulder for preservation of bone and Soft tissue

Plateau designed thread for maximum primary stability in soft bone

Microbacterial Seal + micromoment free Implant-Prosthetics-Connection

Slightly conical, slender implant body for maximum clearance between the thread and body for formation of blood coagulum

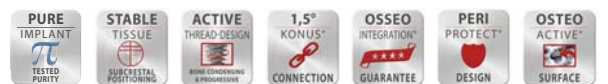Spiral progressive + compressive thread for easy insertion in soft bone

Implant design allows the use of reduced diameter Flnal drills, according to the bone quality



ARGON Medical
Fon.: +49 6721/ 3096-0
info@argon-medical.com
www.argon-medical.com

QUALITY & DESIGN
MADE IN GERMANY



Resolving severe bone atrophy

with the cortical lamina technique and innovative materials

Dr Roberto Rossi, Dr Giovanni Franzone & Stefano Giulini, Italy

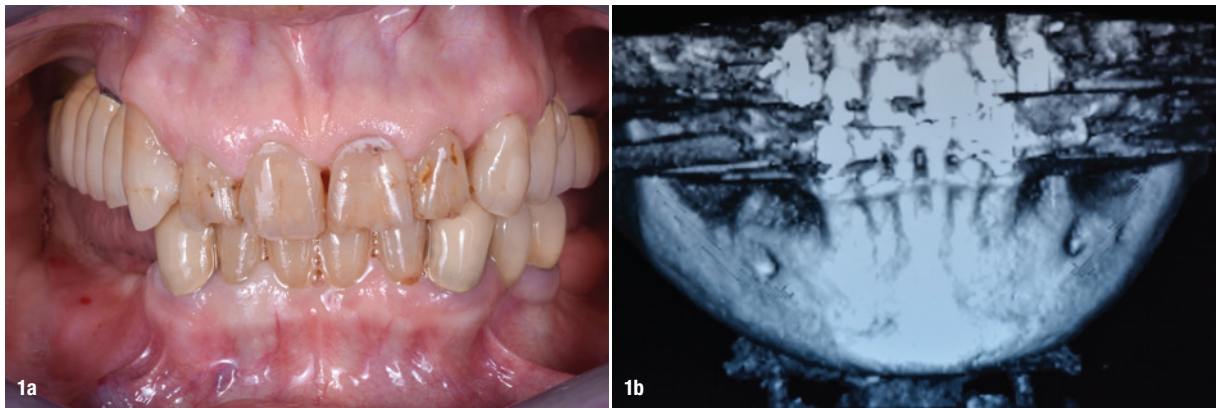


Fig. 1a: Initial situation. Figs. 1b & c: Initial CBCT scan.

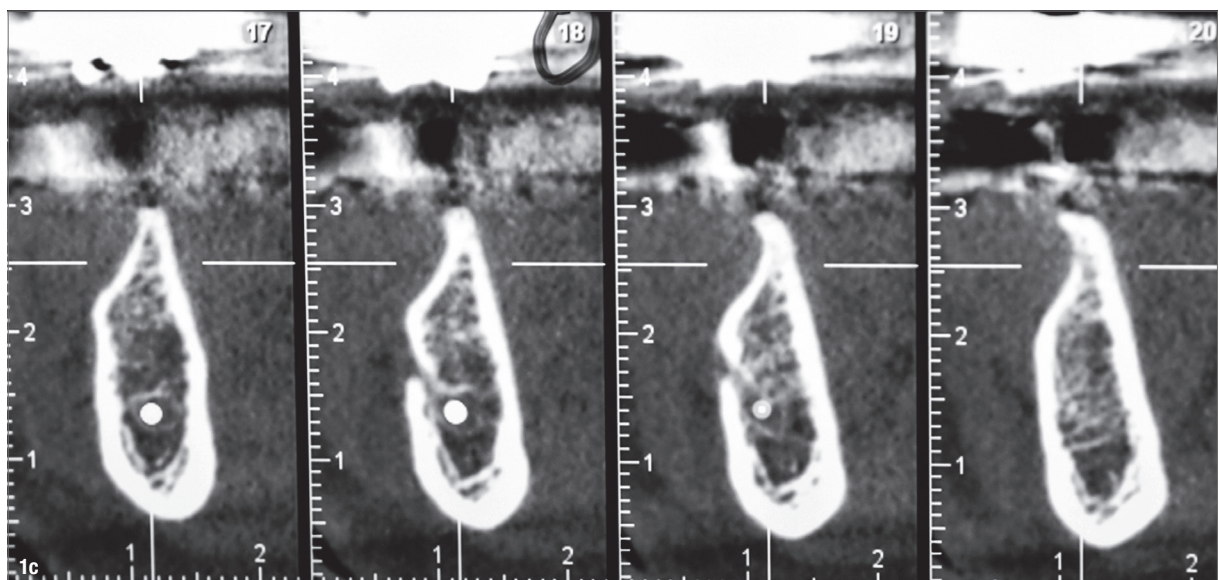
Introduction

The 65-year-old female patient presented for treatment of her bilateral posterior edentulism. She presented with a negative medical history and the loss of her diathoric teeth as a result of fractures after an old prosthesis (Fig. 1a). The CBCT scan of the mandibular dental arch showed a horizontally resorbed edentulous bone ridge with an average thickness not exceeding 3mm (Figs. 1b & c). After a preventive oral hygiene session, bone regeneration using the cortical plate technique was planned (Fig. 2).

The objectives of the treatment plan designed for this patient included in the first phase the insertion of implants (Neodent, Straumann), two implants in the left of and four in the right of the mandible, with subsequent augmentation of the bone volume and at the uncovering of the implants the increase of the soft tissue, given the small amount of attached gingiva.

Materials and methods





Local anaesthesia with articaine with 1:200,000 adrenaline was administered. An incision with a #12 blade was



INTRODUCING DS PRIMETAPER™

THE PERFECT UNION OF FORM AND FUNCTION

DS PrimeTaper is a demonstration of science and art in harmony. With immediate function and intuitive digital workflows, these unique implants will complement and enhance your expertise.

-  EFFICIENT HANDLING
-  LASTING BONE CARE
-  ENVIABLE ESTHETICS
-  SEAMLESS WORKFLOW INTEGRATION



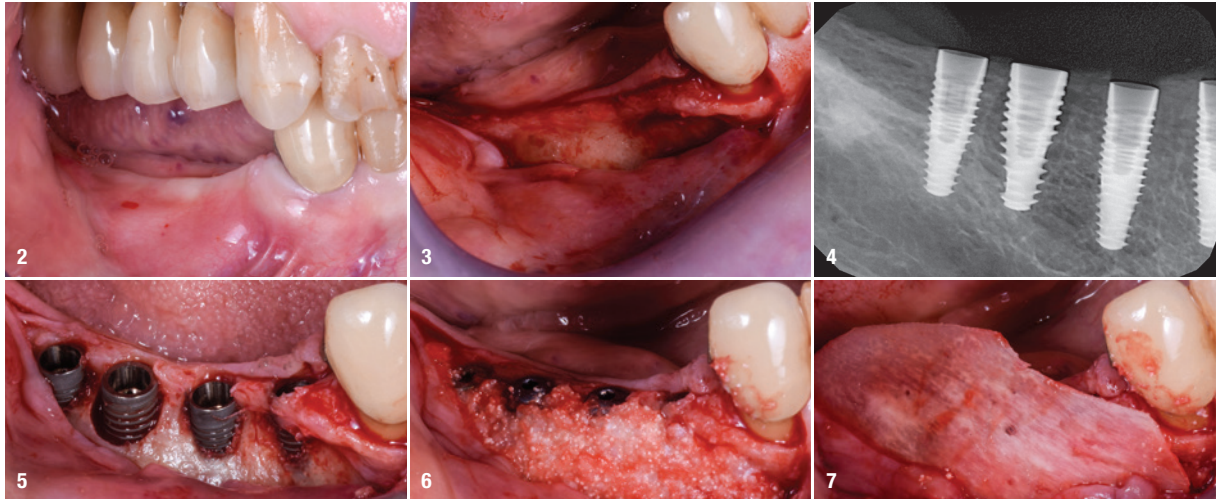


Fig. 2: Close-up of the edentulous area. **Fig. 3:** Exposure of the residual bone ridge. **Fig. 4:** Post-op radiograph. **Fig. 5:** Implants in position. **Fig. 6:** Bone grafting material placed. **Fig. 7:** Lamina inserted.

made on the edentulous ridge, taking care to divide the small amount of keratinised gingiva equally between the vestibular and lingual flaps. The exposed ridge confirmed what had been observed on the CBCT scan: the thickness in the ridge was 3mm in the area distal to the canine and thinned to 1mm in the molar area (Fig. 3). Near site #46, there was a residual root, which was removed, and an implant of standard diameter (4mm) was inserted in the same position, whereas the implants placed in the premolar and second molar sites were of reduced diameter (3.5mm; Fig. 4).

The postoperative radiograph showed that the implant in site #46 was anchored to the bone only by its apical portion. The clinical image showed an evident vestibular dehiscence affecting all four implants, at least

five to six implant threads being exposed outside the crest, and evident volume insufficiency horizontally (Fig. 5).

For this specific clinical situation, a grafting material (GTO, OsteoBio) with special characteristics was selected. This sticky biomaterial is composed of collagenous porcine bone combined with a thermosensitive gel (TSV Gel, OsteoBio), allowing it to jellify and become solid on contact with the moisture of the mouth. GTO can be used to create and maintain volume even in an anatomically unfavourable situation. Its properties make it both easy to mould to the defect and stable. Figure 6 shows how this stability makes it possible to apply an adequate amount of material to correct the defect in the ridge and cover the exposed implant threads.

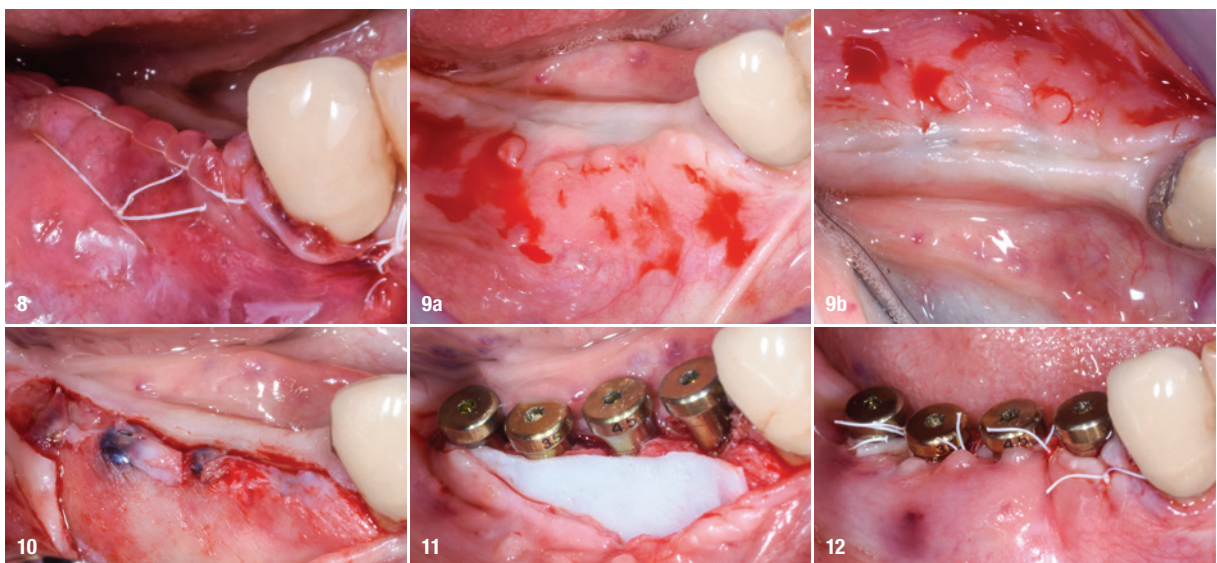


Fig. 8: Sutures. **Figs. 9a & b:** The ridge six months post-op. **Fig. 10:** Reintegration. **Fig. 11:** NovoMatrix (BioHorizons) in position. **Fig. 12:** The sutured flap.

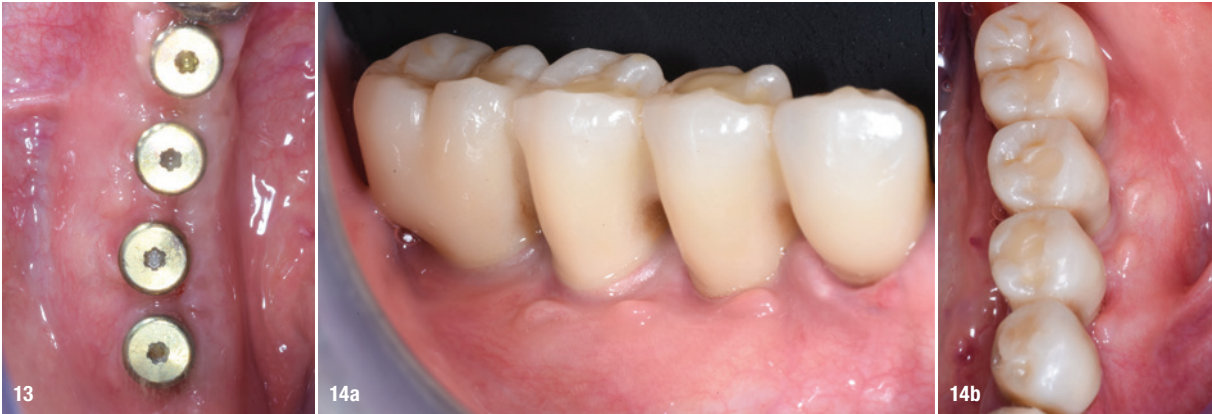

Fig. 13: Occlusal view of the ridge. Figs. 14a & b: Fixed crowns in position.

The procedure was completed with the use of a fine cortical lamina (Lamina, OsteoBioI) as a membrane. The lamina was adequately modelled, cut out, hydrated with a clot of blood from the patient and stabilised by the stickiness of the graft, which it covered, helping it adhere to the underlying bone (Fig. 7).

Sutures play a crucial role in this phase. One or two horizontal mattress sutures with a PTFE thread aim to compress the lamina horizontally and to produce

coronal tissue positioning. The flaps are then approximated using a continuous blocking suture to guarantee airtight closure of the area (Fig. 8). This type of graft, that is using a membrane made of bone, takes slightly longer to heal. This being a large graft, it was decided to re-explore the area after a six-month period of healing (Figs. 9a & b).

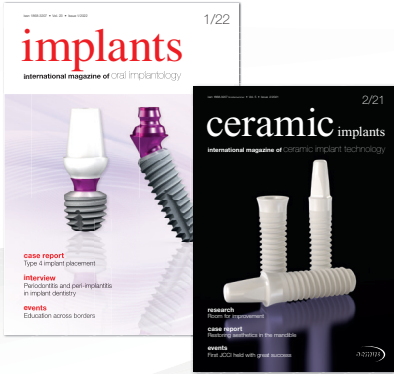Under local anaesthesia, an incision that left a modest part of the attached gingiva on the lingual side

AD

SUBSCRIBE NOW!

implants—international magazine of oral implantology

Interdisciplinary, transparent & market orientated



ONLINE SUBSCRIPTION HERE



www.oemus-shop.de

Fax: +49 341 48474-290

I would like to subscribe for the following journals:

- ceramic implants—international magazine of ceramic implant technology 2 issues p.a. € 30*
- implants—international magazine of oral implantology 4 issues p.a. € 44*

Terms & Conditions: The subscription may be cancelled in written form without due justification within 14 days of order by contacting OEMUS MEDIA AG, Holbeinstraße 29, 04229 Leipzig, Germany. Dispatching notification in good time will suffice. The subscription is automatically extended by another twelve months if it is not cancelled in written form 6 weeks prior to the end of the reference period.

* All prices include VAT, shipping and handling.

Last Name, First Name

Company

Street, ZIP, City, Country

E-mail

Credit Card Number Expiration Date Security Code

Signature

Stamp

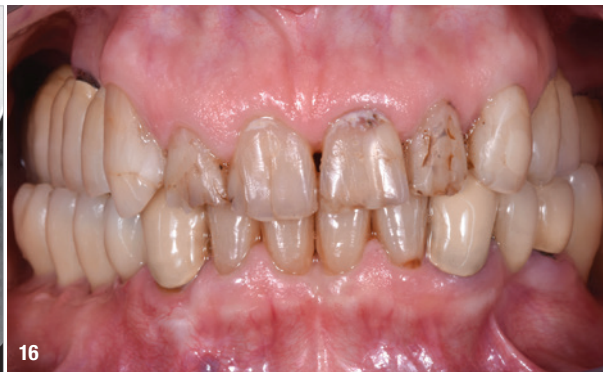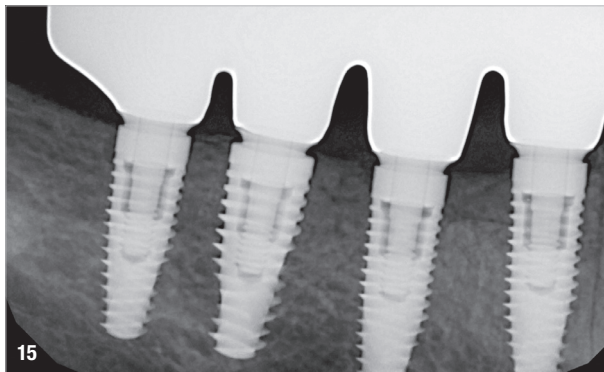


Fig. 15: Radiograph taken at six months after implant insertion. **Fig. 16:** Follow-up at 12 months post-op.

was made and a full-thickness vestibular flap was raised, revealing excellent mineralisation of the lamina and maintenance of the horizontal volume (Fig. 10). It could also be seen how the bone had formed and mineralised even above the screws covering the implants.

To remove the bone layer, it was necessary to use a diamond drill in order to unscrew the covering screws and connect the healing screws. At the same time as the implants were being uncovered, the planned vestibular soft-tissue augmentation of the reconstructed area was performed. Given the size of the area to be augmented and the scarcity and quality of palatal tissue (as well as the difficulty of access in a relatively small mouth), it was decided to use a connective tissue substitute of the same origin as the grafts (NovoMatrix, BioHorizons). This biomaterial has a peculiarity that differentiates it from similar products: it is pre-hydrated and reminiscent of native connective tissue, has a thickness of 0.8mm and is available in different sizes. In this case, it can be seen that with a 2.5 × 1.5cm strip the entire previously grafted area was substantially increased (Fig. 11). Given the easy manageability and stability of this new type of graft, it was not necessary to suture it to the underlying tissue or implants, so it was simply inserted under the vestibular flap and repositioned at the neck of the healing screws (Fig. 12).

About eight weeks later, the integration of the grafts (bone and soft tissue) and the significant difference in the vestibular ridge volume could be observed (Fig. 13). Three months after the implants had been uncovered and the tissue had completely healed, impressions were taken and definitive zirconia crowns placed (Figs. 14a & b). The radiograph taken six months after prosthetic completion (Fig. 15) showed the stability of the prosthesis-implant complex and the complete reconstruction of the bone defect surrounding the implants. Compared with Figure 1a, Figure 16 shows how the initially concave edentulous area was restored to a convex shape to protect the prosthetic restoration.

Conclusion

The correct diagnosis and planning of complicated cases are key factors for achieving a sustainable result. A fundamental component is knowledge of new biomaterials and their correct application in complex situations. In the present case, the use of this particular sticky grafting biomaterial in an unfavourable anatomical situation helped to achieve rapid healing without any complications. The decision in favour of a fine lamina rather than a thick, rigid one facilitated the integration and the excellent mineralisation of the lamina itself.

The choice of a conical implant with an aggressive tip facilitated primary stability (especially in the post-extraction site) even where the anatomy was unfavourable. Grafting a biomaterial instead of autologous connective material simplified the procedure and reduced morbidity to zero. For this reason, it is believed that knowledge of the best, new and innovative biomaterials is the way forward to make even complex procedures simple in the future.

about the author



Dr Roberto Rossi graduated in dentistry and dental prosthetics (with honours) from the University of Genoa in Italy and obtained a specialist qualification in periodontics in 1991 and an MSc in dentistry in periodontics from the Boston University Henry M. Goldman School of Dental Medicine in the US in 1992. Since 1993, he has been practising in his practices in Casale Monferrato and Genoa in Italy.

He has been a contract professor in several Italian universities and since 2004 has been a contract professor in the master's degree in periodontics programme at the Sapienza University of Rome in Italy.

contact

Dr Roberto Rossi
+39 010 5958853
drrossi@mac.com



Premium Partner:

straumanngroup

Geistlich
Biomaterials

51ST INTERNATIONAL ANNUAL CONGRESS OF

DGZI

30 September/1 October 2022
Hotel Berlin Central District

**SAVE
THE DATE!**

DOWNLOAD
REGISTRATION FORM



www.dgzi-jahreskongress.de



Type 4 implant placement with custom healing abutment

A completely digital prosthetic workflow

Dr Pál Nagy, Hungary

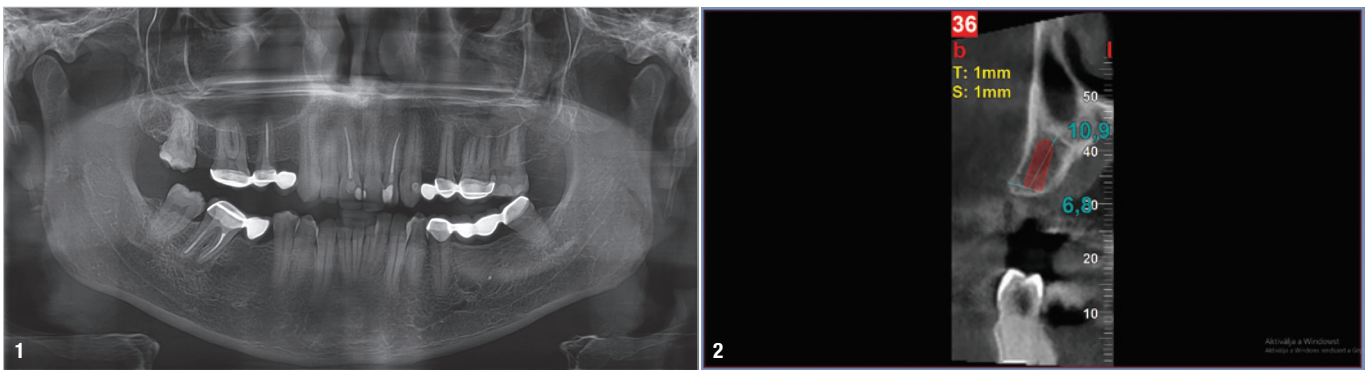


Fig. 1: Pre-op dental panoramic tomogram showing missing maxillary right first premolar and cantilever bridge. **Fig. 2:** Digital planning with CBCT for implant size.

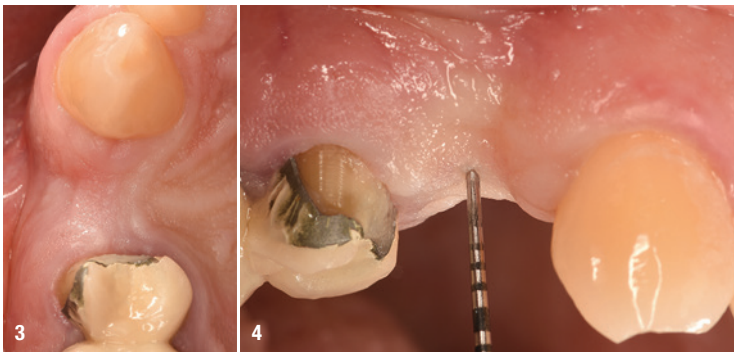


Fig. 3: Buccal soft-tissue defect. **Fig. 4:** Evaluation of biologic width based on vertical soft-tissue thickness.

Introduction

Implant therapy is a safe and reliable method for the replacement of missing teeth. In the past few years, implant dentistry has witnessed several advancements in biomaterial science, treatment technique and even equipment. Digitisation in implant dentistry is one such aspect. The dentist can plan and predict the outcome before performing the surgery. This enables better communication and improves treatment acceptance. Another aspect of improving predictability is giving utmost importance to the soft tissue during treatment planning. Long-term success of an implant restoration is correlated with

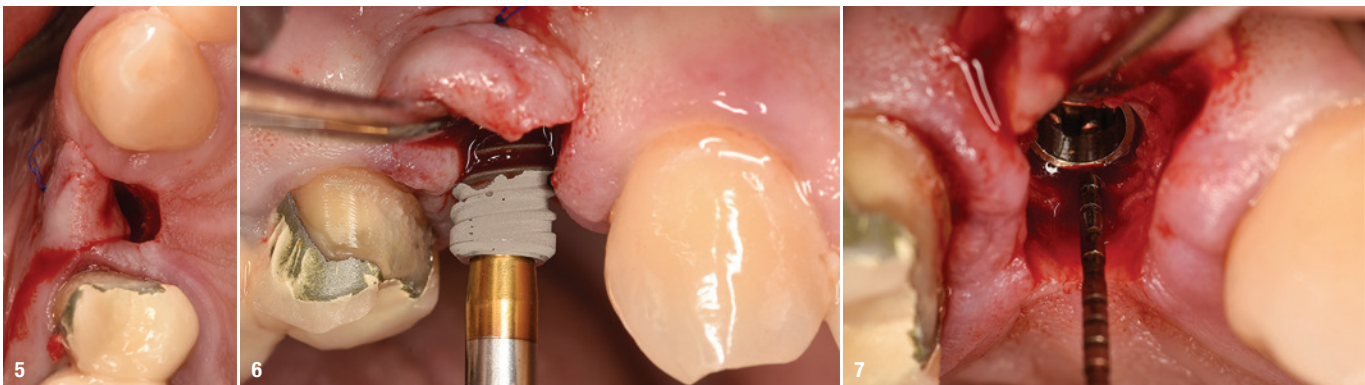


Fig. 5: Palatal roll flap. **Fig. 6:** brented medical copaSKY 4x10 implant placement. **Fig. 7:** Subcrestal implant placement according to expected biologic width.



PERFECT
MATCH



mis[®]

MIS CONICAL CONNECTION. MAKE IT SIMPLE

MIS conical connection feature a 12-degree friction fit which ensures a secure seal and minimal micro-movements. Visit MIS Blog to get tips from experienced, world-renowned implant specialists on optimizing working with conical connection implants and restorative components: www.mis-implants.com/blog

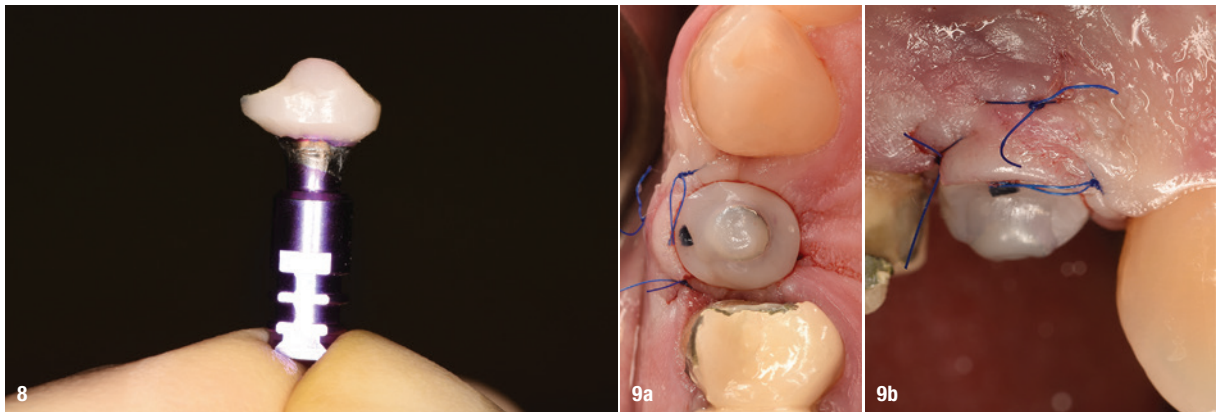


Fig. 8: Customised healing abutment on a titanium base showing a tulip-shaped emergence profile. **Fig. 9a:** Occlusal view of closure. **Fig. 9b:** Buccal view of tension-free closure.

many factors, among others especially peri-implant health. All efforts should be made to achieve a good peri-implant seal. The following case report highlights the combination of soft-tissue management and a completely digital prosthetic workflow for a Type 4 implant placement.

Preoperative phase

A young patient presented with a fractured cantilever prosthesis (Fig. 1). The missing first premolar was indicated for implant-supported restoration. A CBCT assessment with NNT Viewer (NewTom) was used for bone evaluation, and a copaSKY 4 × 10 mm implant (bredent medical) was planned (Fig. 2). Soft-tissue evaluation revealed a Seibert Class I ridge defect (Fig. 3).¹ Hence, a palatal roll flap technique was proposed with simultaneous implant placement to compensate for the buccal soft-tissue collapse. The vertical soft-tissue thickness was measured and subcrestal implant placement was planned to correlate with biological width establishment during the transgingival healing period (Fig. 4).

Surgical phase

The procedure was done under local anaesthesia (articaine hydrochloride 4% with 1:100,000 adrenaline).

A papilla-sparing U-shaped palatal incision was made, and a full-thickness mucoperiosteal flap was raised and rolled buccally (Fig. 5). De-epithelisation was done on the buccally rolled part of the flap. This would compensate for the buccal soft-tissue defect. Sequential osteotomy was done and the bredent copaSKY 4x10 implant was placed to a torque of 30Ncm (Fig. 6). The implant was placed 1 mm subcrestally to compensate for future supracrestal soft-tissue widening (Fig. 7).

A customised healing abutment was fabricated by luting composite on to a titanium base for soft-tissue conditioning during the transgingival healing phase (Fig. 8). The individualised healing abutment imitated a tulip shape to create the preferred emergence profile. The soft tissue was sutured with a tension-free closure using a #6/0 non-resorbable monofilament thread (Optilene, B. Braun Deutschland; Figs. 9a & b). A postoperative radiograph was taken, and it showed parallel placement with adjacent teeth (Fig. 10). Postoperative instructions were given to the patient for hygiene maintenance around the implant site.

At the first follow-up visit one week later, the sutures were removed and the site showed satisfactory healing (Fig. 11). Delayed loading after four months was planned according to the patient's wish.

Prosthetic phase

A completely digital prosthetic workflow was executed on exocad software (exocad) for the fabrication of a hybrid screw-retained zirconia monolithic crown over a copaSKY uni.fit titanium base (bredent medical). The implant site showed adequate buccal soft tissue thickness and a favourable gingival contour (Figs. 12a & b). After the removal of the customised healing abutment, a healthy peri-implant soft-tissue collar was observed (Figs. 13 & 14). Furthermore, a preoperative intra-oral scan was immediately taken for soft-tissue profile recording. This was followed by placement of the scan body, and a digital impression was

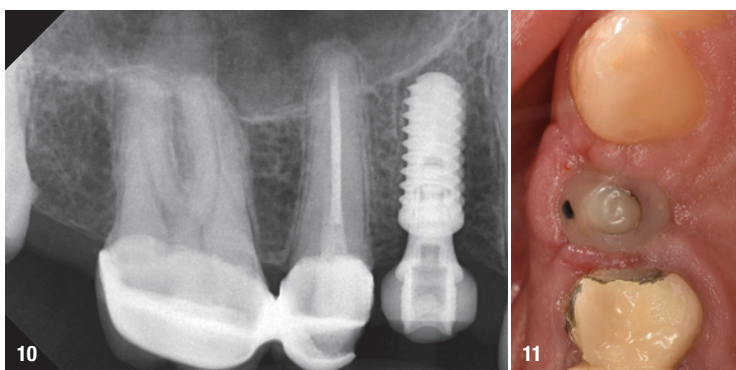


Fig. 10: Immediate post-op radiograph. **Fig. 11:** Suture removal after one week, showing satisfactory healing.

CURAPROX

PROTECT YOUR PATIENTS



THE 'PERIO PLUS
REGENERATE' REVOLUTION:

- + Inspiring fresh taste sensation
- + Proven more effective than pure CHX*
- + Regeneration and protection of oral mucosa
- + Additional protection against infections* and the causes of bad breath

*Studies on www.perioplus.com/studies

FIND OUT MORE NOW AT
PERIOPLUS.COM

SWISS PREMIUM 
ORAL CARE

Developed by

curaden
better health for you

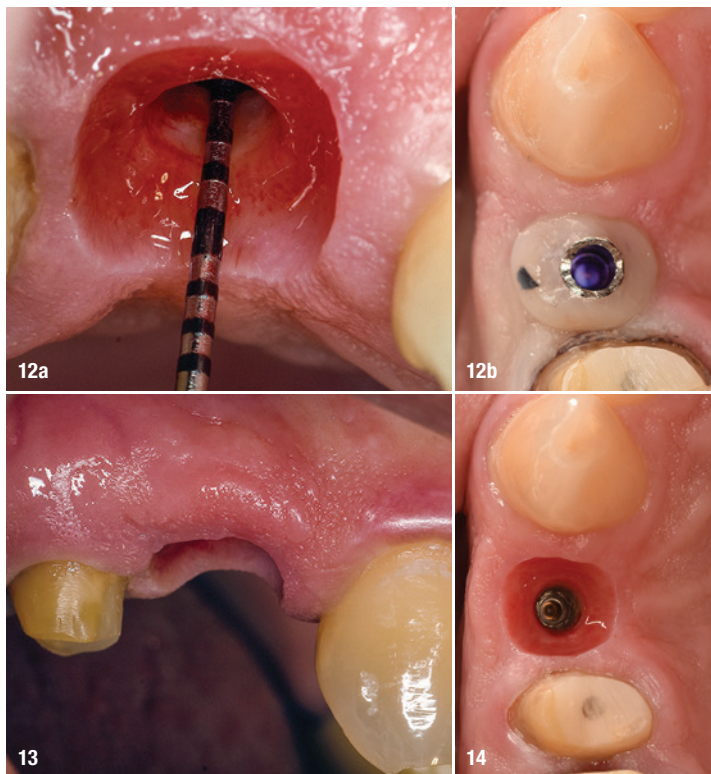


Fig. 12a: Biologic width of 5 mm. **Fig. 12b:** Post-op occlusal view after four months showing adequate buccal soft-tissue thickness. **Fig. 13:** Buccal view after four months showing marginal zenith maintained. **Fig. 14:** Healthy peri-implant soft tissue collar.

performed to record the implant position (Fig. 15). The opposing arch and the bite were also recorded with the same technique. The acquired STL files were digitally

transmitted to the dental laboratory. A PMMA try-in crown was fabricated on the titanium base to check for proximal and marginal fit as well as to harmonise the occlusion (Figs. 16 & 17). A re-scan was carried out once all the adjustments had been completed. The definitive hybrid screw-retained full-contour zirconia crown over a titanium base was fabricated with a highly polished gingival surface and torqued to 25Ncm (Fig. 18). An excellent shade match and clinical outcome was achieved (Fig. 19). The occlusal opening was plugged with PTFE and sealed with composite (Fig. 20). A postoperative control radiograph was taken which showed proper seating of the prosthesis (Fig. 21). At the six-month follow-up, an enhanced soft-tissue profile and maintained crestal bone levels were clearly visible (Figs. 22–24).

Discussion

One of the challenges of delayed implant placement is compensation for post-extraction ridge atrophy. The amount of horizontal and vertical ridge loss may reach up to 60% within two years of tooth extraction, most of it occurring within the first six months of tooth extraction.²

The current case report demonstrates a predictable soft-tissue management technique performed simultaneously with implant placement. A modified palatal roll flap technique was used to compensate for the buccal defect and to achieve a better soft-tissue contour. Unlike a free subepithelial connective tissue graft, this pedunculated approach not only augments the ridge deficiency with better vascularity but also thickens the marginal

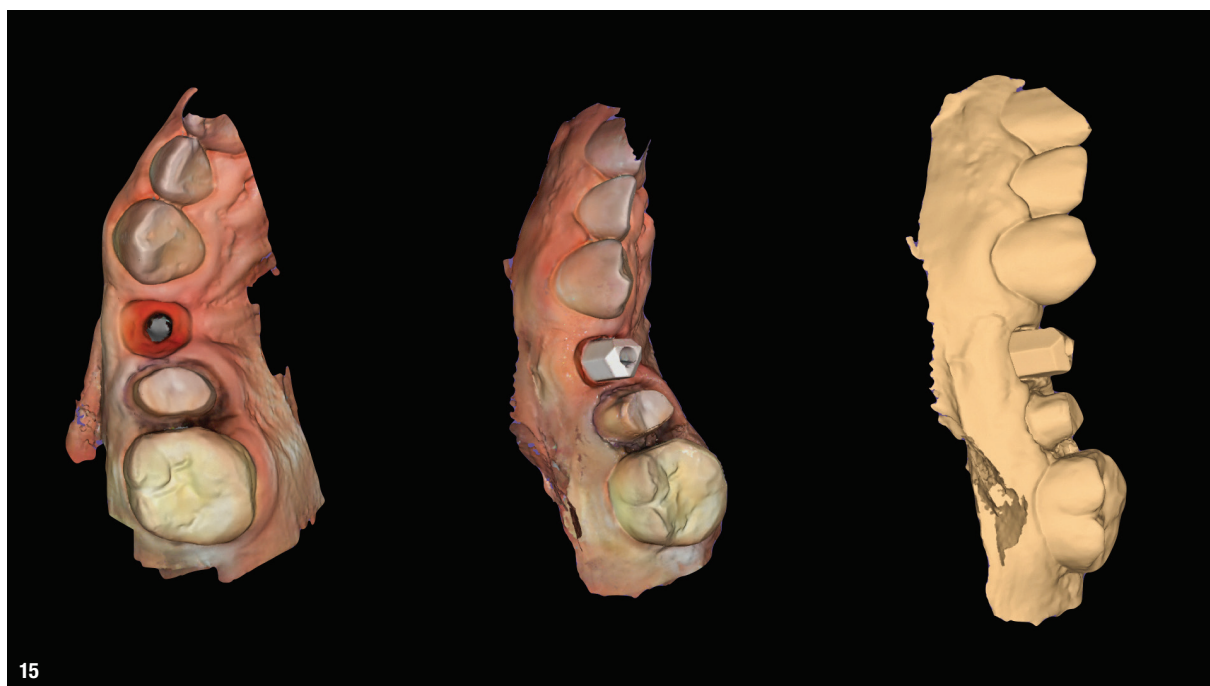


Fig. 15: Intra-oral scanning done sequentially to record the soft tissue, implant position with the scan body and to obtain a digital master cast.

gingiva around the uncovered implant. Biotransformation to a thicker peri-implant mucosa may promote peri-implant tissue stability.³ This approach is also preferable, as there is no secondary donor site or raw area which could cause additional pain and discomfort to the patient during the healing phase. Since it is performed at the same time as implant placement, a second surgery for soft-tissue enhancement is avoided. This improves patient comfort and creates a positive dental experience. Subcrestal implant placement was utilised to compensate for biological width enlargement during transgingival healing. Supracrestal soft-tissue thickness around implant restoration is very important, as it has a direct influence on the peri-implant seal and ultimately the long-term success of the therapy. Violation in this relation between the bone and soft tissue around the implant may be one of the causes of early crestal bone loss.⁴ Marginal bone loss around implants can either affect the long-term aesthetic outcome owing to gingival recession after bone loss or be the initial causative factor of a later peri-implant infection. A one-stage non-submerged protocol is more predictable compared with the submerged technique owing to advantages such as reduced chairside time and a more matured soft-tissue healing, since no additional surgical procedure is required.⁵ When it comes to transgingival healing, a customised healing abutment is preferable in order to achieve a favourable soft-tissue profile for the definitive restoration. Hence, creating a surface with similar dimensions to those of the lost tooth at the level of the gingival margin, together with a narrowing transmucosal part towards the implant platform, help reach this goal. The main advantage of the customised healing abutment is the preformed gingival contours to determine the correct emergence profile of the future prosthetic components when immediate provisionalisation is not an option.⁶ To summarise, the soft-tissue considerations employed in this case report include the following: pouch roll flap, subcrestal placement to avoid biological width violation and customised healing abutment. The implant system used was selected for its unique osseo connect surface (OCS) and because the neck of the implant supports

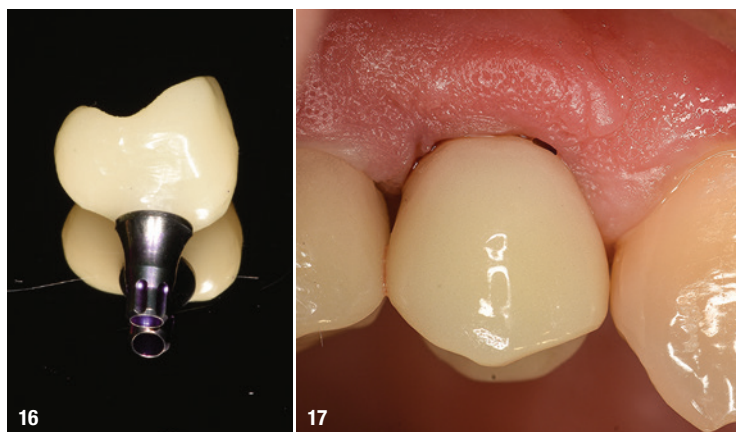


Fig. 16: Fabrication of provisional PMMA crown. **Fig. 17:** Adjustments on PMMA crown. Note the minimal gap between the marginal gingiva and PMMA pseudo-cemento-enamel junction. This is because the soft tissue had already shrunk between the time the healing abutment was removed and the time the first scan was performed. This was easily corrected by the technician through a minimal surface enlargement on the gingival surface of the crown–abutment interface.

soft-tissue attachment for the prevention of bacterial infiltration and protection of the implant. The sandblasted and etched surface enhances rapid osseointegration. It has a back taper design and double self-cutting compression threads, which are important for the attainment of high primary stability. In addition, the copaSKY implant system employs platform switching to minimise crestal bone loss because the minimisation of crestal bone loss is crucial for the long-term success and stability of the implant. The self-tapping double thread achieves faster insertion of the implant with lower heat generation and bone condensation.⁷ Sandblasted and etched implants with a self-cutting thread in a cylindrical and conical hybrid design show statistically higher insertion and removal torque values compared with machined implants, along with enhanced primary stability.⁸ A fully digital prosthetic protocol was followed for fabrication of the definitive prosthesis. Intra-oral scanners are devices used to capture direct optical impressions in dentistry.⁹ A review of the current literature of intra-oral

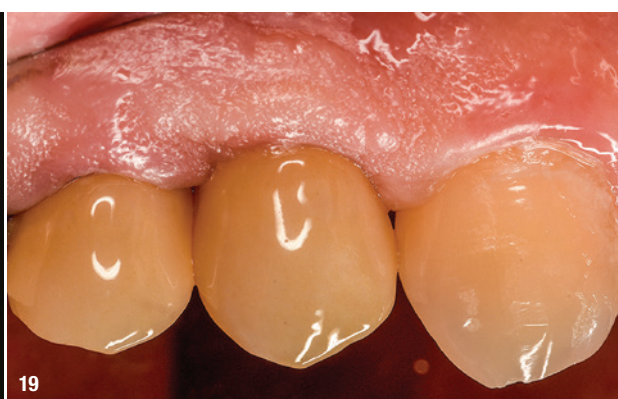
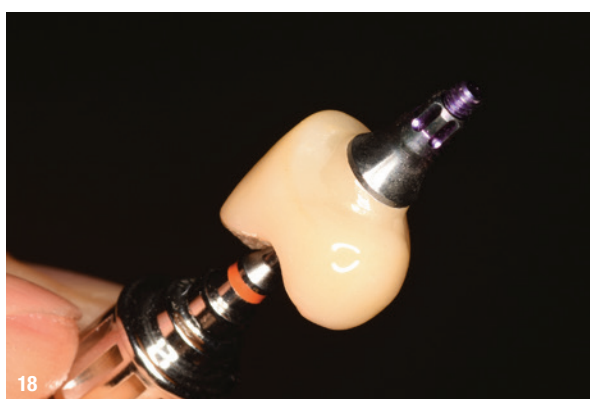
Fig. 18: Definitive hybrid screw-retained monolithic zirconia crown over titanium base with polished gingival collar without glaze. **Fig. 19:** Buccal view of definitive crown showing excellent shade match and contours.

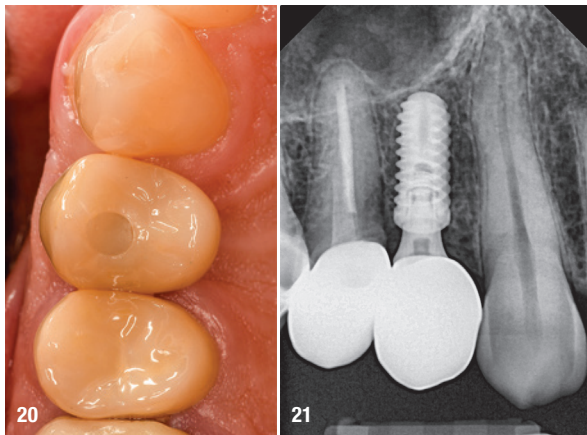


Fig. 20: Occlusal opening sealed with composite. **Fig. 21:** Post-op radiograph after definitive crown placement.

scanners concluded that they are time-efficient, reduce patient discomfort, eliminate the use of plaster models and allow better communication with the dental laboratory technician.¹⁰ A hybrid screw-retained prosthesis

Monolithic crowns are fabricated with CAD/CAM technology and have high flexural strength and fracture toughness, higher than those of alumina-based ceramic crowns.¹⁴

Conclusion

The pursuit of precision and perfection has led to an evolution in the field of implant dentistry. New-age techniques and materials, coupled with rapid digitalisation in dentistry, have improved the patient experience through improved comfort, shorter treatment time and more predictable results. Digital workflows minimise manual and technical errors not only by the dentist but also by the dental laboratory technician. Hence, there being a plethora of implant companies available, it is crucial to choose a provider which enables completely digital workflow options in implant dentistry for both the surgical and prosthetic aspects. Holistic treatment planning with regard to well-laid down biologic principles for the peri-implant soft and hard tissue yields superior aesthetic results and leads to long-term success.

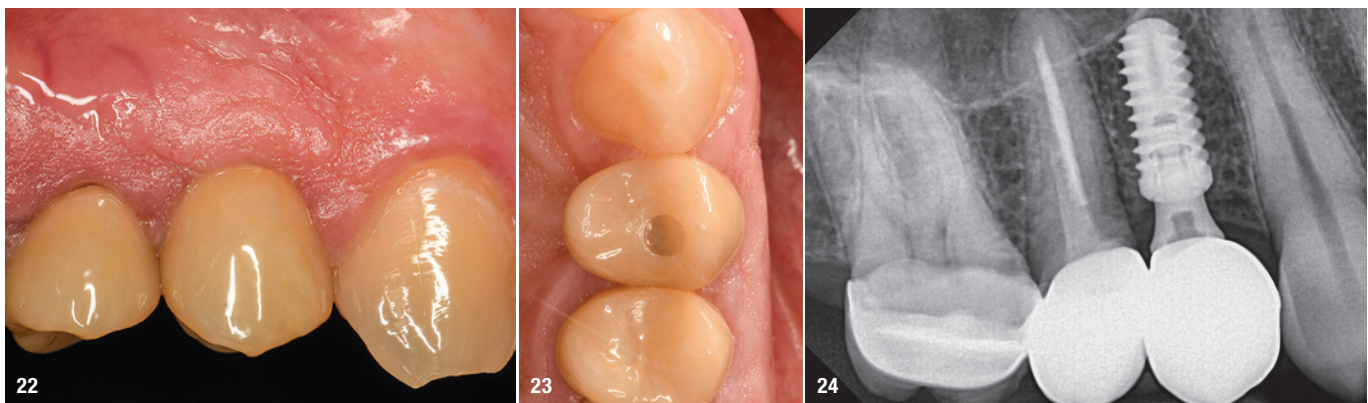



Fig. 22: Six-month follow-up showing excellent emergence profile. **Fig. 23:** Six-month follow-up showing enhanced soft-tissue thickness. **Fig. 24:** Six-month follow-up radiograph showing maintained crestal bone levels.

was planned and executed in this case. A comprehensive review focused on clinical significance of screw-retained versus cement-retained crowns for decision-making found that a screw-retained restoration demonstrates fewer biological complications and has the advantage of easy retrievability without damage to the abutment and the crown.¹¹ The removal of a cement-retained crown is still more challenging and less predictable compared with a screw-retained restoration.¹¹ Thus, a screw-retained prosthesis simplifies case management if any complication arises in the future. Cement extrusion and retention in the peri-implant tissue can result in microbial colonisation and peri-implant tissue damage. With screw-retained restorations, it is easier to evaluate oral hygiene and maintenance procedures are easier to carry out.¹² A polished full-contour zirconia crown was used for the definitive prosthesis. In layered zirconia crowns, the veneering porcelain shows chipping or even delamination after long-term wear, resulting in restoration failure.¹³

about the author



Dr Pál Nagy, DMD, PhD, is a certified clinical specialist in periodontics and dental implantology. He started the DifferENTAL dental clinic together with his brother in Budapest, Hungary. Dr Nagy would like to acknowledge the dental technician and the dental technician's lab: Kapos Dentart Dental Lab – Tamas Cser.

contact

Dr Pál Nagy
Csalogány utca 26
1015 Budapest, Hungary

kardpali@gmail.com
+36 30 9605255

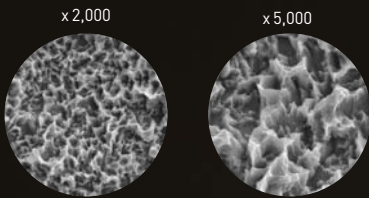


SQ

Submerged Qualified

Dual & Open Thread

Prevent bone loss



S.L.A. Surface

Excellent Osseo-Integration with SLA surface

Double Thread

Smooth implant placement and shorten surgery time

Wide Cutting Edge

Improved Self-tapping

Sharp shape of Apex

Superior initial placement

Tapered Body

Improving Initial fixation force

Vacuum cleaning machine



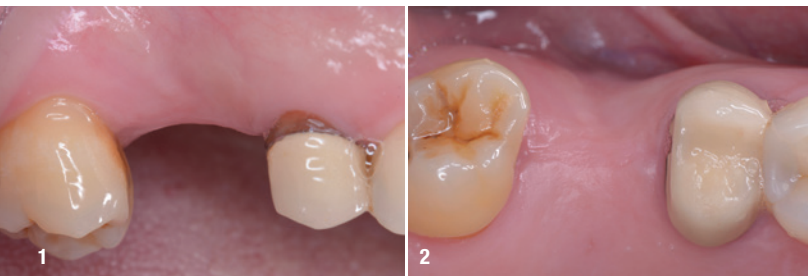Quality Control

Clean implant with automatic cleaning system



Maxillary molar replacement with an implant and immediate restoration

Dr Leandro Soeiro Nunes, Brazil



Figs. 1 & 2: The periodontal condition of the patient, showing the missing maxillary right first molar. **Fig. 3:** Pre-op CBCT scan revealing sufficient vertical and horizontal bone availability.

The introduction of dental implants for the replacement of missing teeth disrupted the era of dental prosthetic dentistry by providing the possibility of replacing a missing tooth with a fixed restoration without affecting the adjacent teeth to perform a tooth-supported restoration. During the

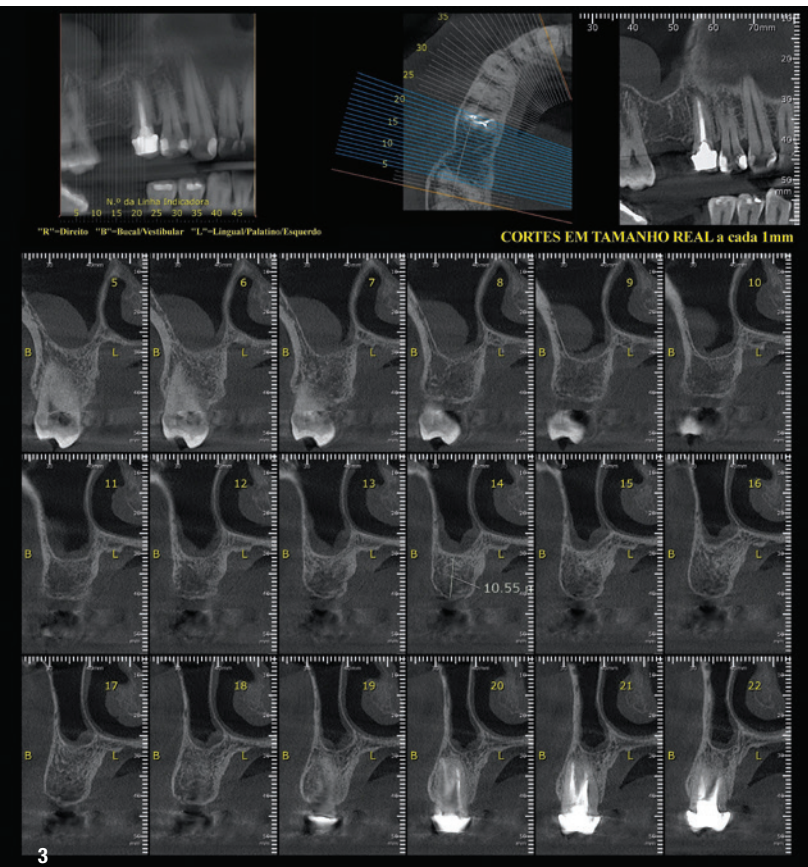
beginning of the era of implant dentistry, two-stage procedures were followed by a waiting period of three to six months from the day of the surgery to the loading.¹ The attempts to provide a better patient experience have led to the development of improved manufacturing technology, innovative techniques and a better understanding of biology through clinical and preclinical studies. The immediate loading of implants is today a reality, and these protocols are frequently used in the anterior maxillary area. However, the placement of dental implants simultaneously with provisional restorations can also provide benefits in the posterior area, including a reduction in time to recovery of the masticatory function.¹ For this, the estimation of the risk of treatment and effective treatment planning are crucial. It is essential to perform an analysis of the medical condition of the patient, the bone availability, the soft tissue and the desired tooth shape and to take into consideration the patient's needs and expectations. The following case report describes the replacement of a single maxillary molar with the new Straumann TLX implant into a fully healed site (International Team for Implantology Type 4 implant placement) and immediate provisional restoration.

Initial situation

A healthy, non-smoker, 40-year-old female patient presented to our clinic with a missing maxillary molar. Her chief complaint was that her condition did not allow her to eat properly and was affecting her quality of life, and she desired to recover masticatory function as soon as possible. Her dental history revealed that the tooth was lost owing to a vertical fracture several months before. This incident happened during the COVID-19 lockdown; therefore, she had not been able to receive complete treatment of the site. The intra-oral examination confirmed that the maxillary right first molar was missing. The periodontal condition of the patient was healthy, and her oral hygiene was classified as good (Figs. 1 & 2). The preoperative CBCT scan revealed sufficient vertical and horizontal bone availability for implant placement in site #16 and no risk of damage to surrounding anatomical structures (Fig. 3).

Treatment planning

For a prosthetically driven planning a close communication between the patient, the prosthodontist and the dental technician is essential. After discussing, she opted for im-



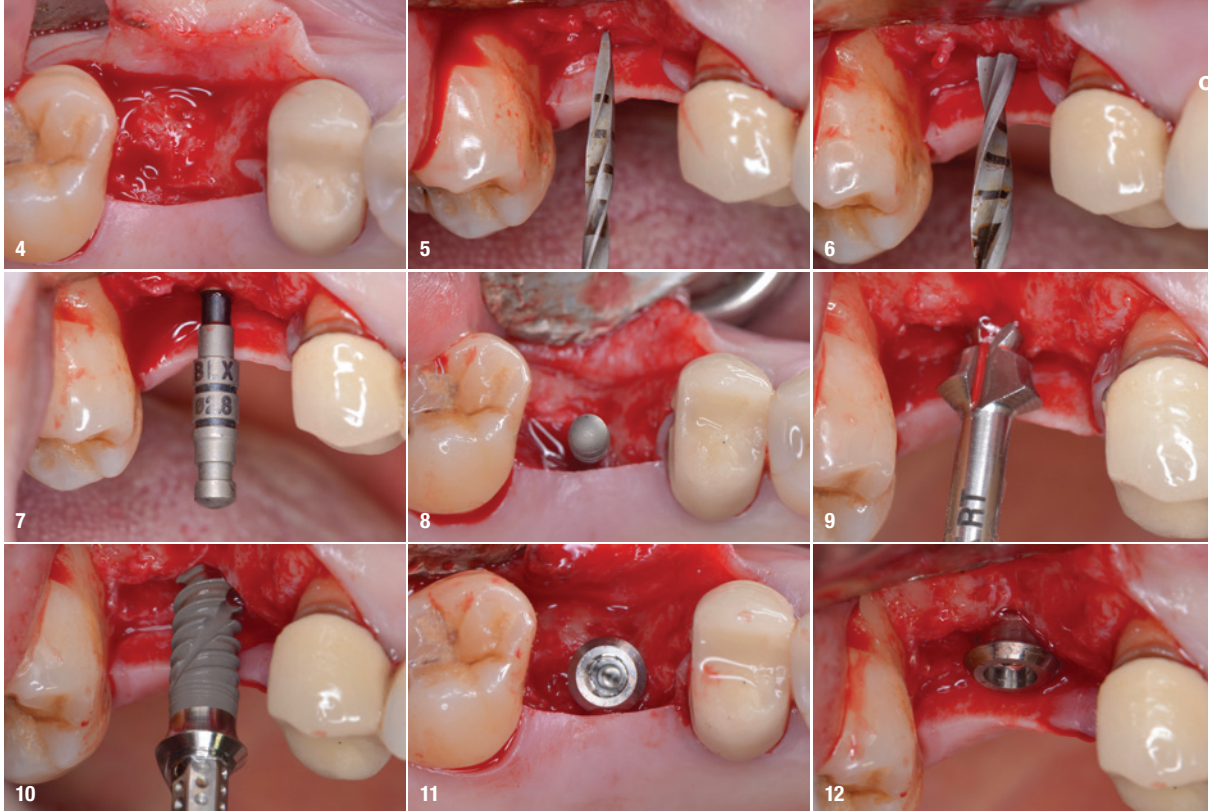


Fig. 4: Raising of the flap for exposure of the bone in the area of site #16. **Fig. 5:** Pilot drill (diameter: 2.2mm) used to full implant length (10.0mm). **Fig. 6:** Use of the second drill (2.8mm). **Figs. 7 & 8:** Placement of the alignment pin. **Fig. 9:** Use of the corresponding profile drill. **Figs. 10–12:** Placement of the Straumann TLX implant to achieve optimal primary stability. **Figs. 13–18:** Straight provisional titanium abutment and preselected tooth based on the stone cast.

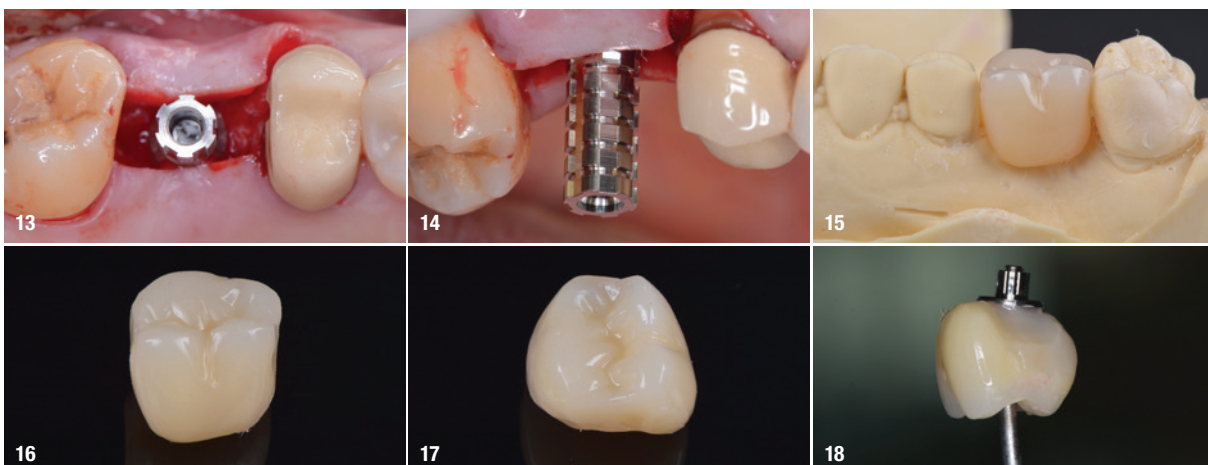
plant placement and provisional restoration in site #16. The clinical and radiographic evaluation showed adequate conditions for implant placement in the healed site. Furthermore, the CBCT scan for diagnosis revealed no need for bone augmentation procedures. Therefore, a Straumann TLX Regular TorcFit (RT) Standard Plus Roxolid implant (3.75×10.00mm) with immediate provisionalisation, provided the desired primary stability was achieved, was planned. The implant system used offers fully tapered tissue-level implants that are designed for high primary stability and immediate treatment procedures.

Materials and method

Local anaesthetic was infiltrated using articaine (4%) with adrenaline. Mid-crestal and intrasulcular incisions were performed without vertical release. The flap was raised to expose the bone around site #16 (Fig. 4). Following the manufacturer’s surgical

protocol, the implant was placed in a prosthetically driven position. A minimum distance of 1.5mm from the implant shoulder to the adjacent tooth was taken into consideration.

Owing to the self-cutting properties of the implant used, the implant bed was lightly underprepared. The drills were used in a clockwise drill rotation direction and with an intermittent drilling technique and precooled (5 °C) sterile saline solution. For this, first, the needle drill (diameter: 1.6mm) was used to mark the implant site, and this was then followed by the pilot drill (diameter: 2.2mm) used to full implant length (10.0mm; Fig. 5). Then the bone density was determined through a pilot hole, and the second drill (diameter: 2.8mm) was used (Fig. 6). Afterwards, an alignment pin was placed to check the 3D position of the osteotomy and preparation depth (Figs. 7 & 8). Additionally, since the placement of the implant was planned to be deeper than the shoulder mark on the mesial site, the corresponding



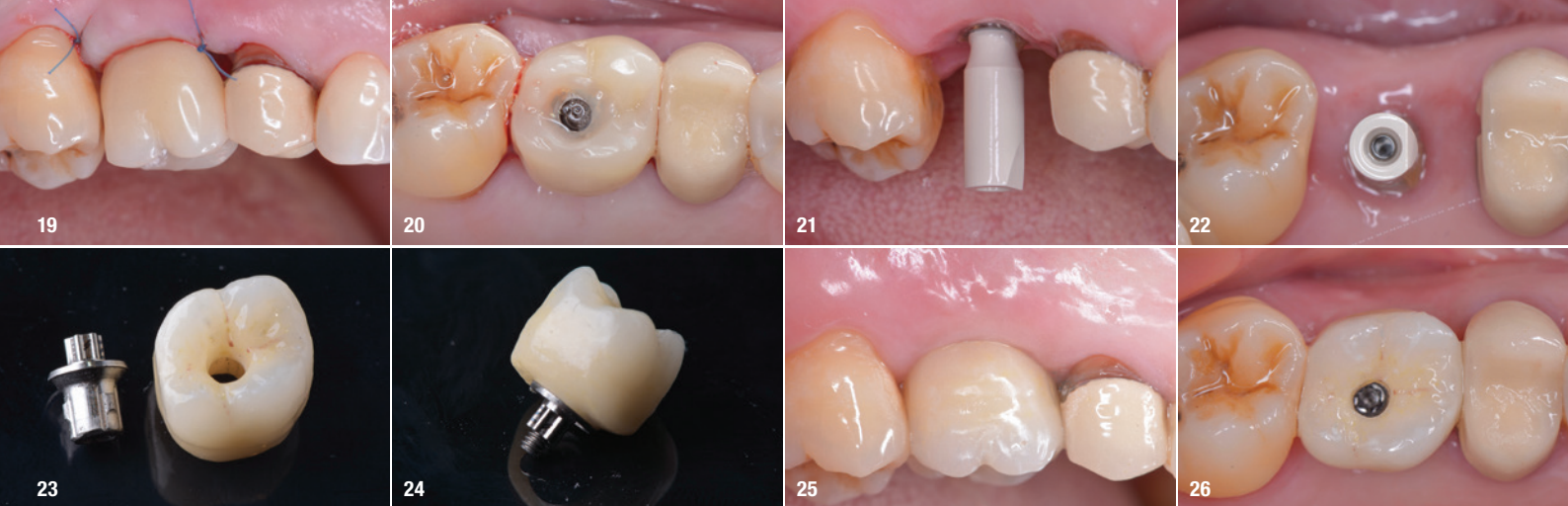
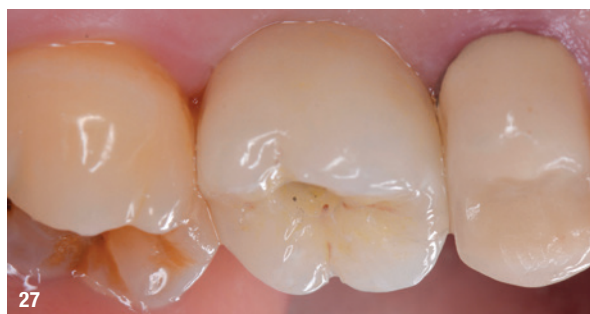

Fig. 19: Single sutures placed around the implant. **Fig. 20:** Occlusal view of the restoration. **Figs. 21 & 22:** Monotype scan body screwed into the implant. **Fig. 23:** The metal-free restoration was to be cemented on top of the RT Variobase abutment (Straumann). **Fig. 24:** Restoration cemented on to the abutment. **Figs. 25 & 26:** The restoration *in situ*. **Fig. 27:** Sealing of the screw access hole with composite material.

profile drill was used (Fig. 9). The implant was placed with a surgical ratchet to a torque value of >35 Ncm, and optimal primary stability was achieved (Figs. 10–12).

manufacturer's recommendations, the restoration was screwed in to a torque of 35 Ncm (Figs. 25 & 26). Finally, the screw access hole was sealed with composite material (Fig. 27).



Treatment outcomes

Replacing one tooth in the posterior zone and loading it immediately can represent many challenges. The key is to know in whom we can perform this type of treatment, and for this, the selection of the patient is crucial. In this case, we obtained good and predictable results in a short period as requested by the patient. The Straumann TLX implant system allows immediate loading, which in our case brought high satisfaction in terms of health, aesthetics and function.

Prosthetic procedure

Since optimal primary stability had been achieved, we could proceed with the preparation of the provisional restoration as requested initially by the patient. For the provisionalisation, a straight provisional titanium abutment and a preselected tooth based on the stone cast were used (Figs. 13–18). The provisional titanium abutment was reduced with a carborundum disc to avoid occlusal contact with the antagonist. The preselected tooth was prepared for adaptation to the abutment and bonded with flowable composite. The final contour and polishing were done chairside by Dr Cristiane Juchem. Single sutures with a #5/0 nylon thread were placed around the implant (Figs. 19 & 20). Analgesics were prescribed postoperatively, and a control appointment and the suture removal were planned for one week later.

The follow-up appointments were scheduled for 30 and 60 days postoperatively. After two months of healing, a monotype scan body was screwed into the implant, and a digital impression with the Virtuo Vivo intra-oral scanner (Straumann) was taken (Figs. 21 & 22). The coDiagnostiX software (Dental Wings) was used for CAD processing, and a metal-free restoration (zirconia) was cemented (RelyX U200, 3M) on the top of an RT Variobase abutment (diameter: 5 mm, height: 6 mm; Straumann) for screw-retained restoration. The height of the abutment was adjusted accordingly (Figs. 23 & 24). According to the implant

Reference:

1. Davarpanah M, Szmukler-Moncler S. Immediate loading of dental implants: theory and clinical practice. Paris: Quintessence International; 2008. 356 p.

about the author

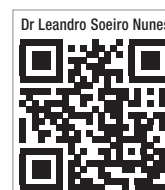

Dr Leandro Soeiro Nunes, MD, DMD, graduated from the Federal University of Rio Grande do Sul in Porto Alegre in Brazil and specialised in oral and maxillofacial surgery in 2006 at the Universidade Luterana do Brasil in Canoas in Brazil. During his advanced studies, he evaluated the behaviour of biomaterials in sinus lift procedures and compared

the biological behaviour of several implant surfaces. He is an International Team for Implantology fellow and study club director in Porto Alegre and teaches implantology at the Associação Brasileira de Odontologia, seção Rio Grande do Sul (Rio Grande do Sul section of the Brazilian association of dentistry). He also runs his own private practice focused on oral surgery, implant therapy and bone regeneration.

contact

Dr Leandro Soeiro Nunes
contato@nunesodontologia.com



ISMI

INT. SOCIETY OF METAL FREE IMPLANTOLOGY



The innovative specialist society for modern metal-free implantology

Become a member now!

Benefits

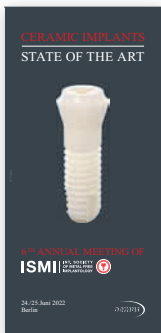

Effective public relations

Benefit from a strong community that elevates the marketing of your practice through effective public relations strategies.

Personal online member profile

ISMI provides a personal profile of all active members on their website—free of charge. In addition, the ISMI patient platform provides important information for patients and features a search tool with which patients can find their perfect dentist.

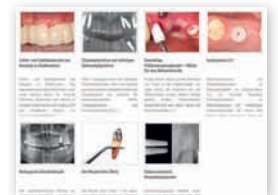

Discount on congress fees

Come and join us! Attend the Annual Meeting of ISMI in Berlin on 24 and 25 June 2022 and benefit from first-rate continuing education. ISMI members receive a special discount on the participation fee.

Online archive for specialists

Get exclusive access to ISMI's extensive online archive. Discuss all relevant questions regarding metal-free implantology with experts and colleagues from around the world and enjoy free access to the online archive where you will find informative training videos and clinical case reports.



Newsletter

The ISMI newsletter keeps you up to date with the latest scientific trends, products, and events on a regular basis. It also features user reports as well as a wide range of information and tips on the subject of metal-free implantology.

Specialist magazine

As a member of ISMI, your membership fee includes a subscription of the independently published English language magazine *ceramic implants—international magazine of ceramic implant technology*. Published twice a year, the magazine offers specialist articles and event reports as well as industry- and science-related news from the international world of metal-free implantology. In addition, *ceramic implants* provides information about manufacturers and their latest products.



ISMI e.V. Office Leipzig
Holbeinstraße 29 | 04229 Leipzig | Germany
Phone: +49 800 4764-000 | Fax: +49 800 4764-100
office@ismi.me | www.ismi.me

Become a
member of ISMI now!



Periodontitis and peri-implantitis in implant dentistry

An interview with Dr Inga Boehncke, Germany



Dr Inga Boehncke is a member of the German Association of Oral Implantology.

Peri-implantitis continues to be one of the greatest challenges for dental professionals. According to studies, the prevalence of the condition will continue to rise in the coming years. **implants—international magazine of oral implantology** spoke with implant specialist Dr Inga Boehncke, who has been running her own practice in Bremen in Germany since 2009, about specific features of implant therapy in the case of previous periodontal disease, surgical and non-surgical treatment protocols for peri-implantitis and how the treatment of the condition will develop in the future.

Dr Boehncke, what is especially challenging about implant treatment for patients with previous periodontal disease?

First, a stable periodontal situation must be established by determining and discussing the individual risk profile of the patient. The type and extent of previous periodontal disease play an important role and several questions need to be addressed. Have there been recurrences?

Is the periodontal situation stable? Does the patient smoke? Does the patient have diabetes? In addition, it is important to establish and monitor the haemoglobin A1c level, which should normally be determined every three months and should not exceed a value of 6.5–7.0%.

Interleukin polymorphisms also need to be considered, especially in combination with several of the aforementioned factors, as about 10% of patients are high responders, meaning that an inflammatory change can be associated with a stronger to excessive reaction. Ultimately, the compliance of patients plays a decisive role regarding the removal of plaque at home and the willingness to undergo oral hygiene at short intervals in order to determine individual biofilm management depending on their risk profile.

If periodontal conditions are stable—free of bleeding and with probing depths of no more than 5 mm after previous periodontal disease—we apply a 0.2% chlorhexidine rinse three times for 30 seconds before implantation. If a film is visible on the tongue, it is removed with a tongue scraper and a chlorhexidine spray is used if necessary. Additionally, periodontally compromised patients are advised to undergo systematic plaque removal in the practice two to three days before the procedure. We also administer vitamin C and vitamin K2 and determine the vitamin D3 level, supplementing depending on the value. During follow-up, we closely monitor, in particular, the adequate removal of plaque. Postoperatively, patients are advised to rinse twice daily with a 0.2% chlorhexidine rinse for one minute. Alternatively, a chlorhexidine gel can be applied to the wound area. During subsequent follow-ups, depending on the severity, risk profile and cooperation of the patients, an individual schedule of short intervals of monitoring involving biofilm removal and determination of the bleeding on probing is indicated.

In addition, we work with the active matrix metalloproteinase-8 (aMMP-8) biomarker from Bioscientia, which determines collagenase activity and thus represents a kind of destruction marker. Inflammatory tissue destruction can thus be detected at an early stage before it becomes clinically visible. A value of 0 for the patient is determined two to four weeks after prosthetic restoration of the implant. One year later, another aMMP-8 test is carried out.

Nowadays, dental implants have a high survival rate, but peri-implant infections are among the most common complications. In the 2019 Delphi study of the European Association for Osseointegration, experts agree that the prevalence of peri-implantitis will increase in the coming years. How can dentistry meet this challenge?

The prevalence of peri-implant mucositis, which is roughly comparable to gingivitis and is initially limited to the inflammatory change in the soft tissue, is currently approximately 43%. Peri-implantitis, which is associated with inflammatory bone resorption that has already occurred, meaning it is comparable to periodontitis, affects approximately 22% of patients. In my opinion, early detection of inflammatory signs and timely intervention are the pillars of postoperative care. Regular bleeding on probing assessment is a key diagnostic tool to detect inflammatory changes at an early stage. As already mentioned, destruction markers can also be used. These are helpful in explaining the therapy to the patient.

In addition, patients with implants should be enrolled in special oral health programmes that include regular systematic removal of the microbial biofilm and early inflammatory diagnostics.

Recent studies have found that mesially and distally splinted implants, as well as implants with an over-contoured restoration, pose an increased risk of peri-implantitis. The more difficult plaque removal for patients and the resulting accumulation of plaque plays a central role in this.

The design of the implant superstructure in terms of facilitation of cleaning and adequate attachment of the soft tissue should be given high priority from the outset to guarantee patients easy and pain-free plaque removal at home. An unattached and thin mucosa often leads to discomfort during cleaning as well as to faster pocket formation and thus plaque accumulation. We often use CAMLOG's NovoMatrix to thicken and secure the peri-implant tissue.

Peri-implantitis can be treated both surgically and non-surgically or with a combination of both methods. However, there is no standardised surgical protocol yet. How can dentists guarantee good care for their patients?

The decision of whether to treat peri-implantitis surgically or non-surgically depends mainly on the severity and the implant surface. It must be clarified whether a rough surface or even already exposed contaminated threads are present. The first step is to eliminate mechanical risk factors such as overhangs that have contributed to plaque formation. The superstructures should be removed. For both surgical and non-surgical cases, the main focus lies on decontamination. Removal of the microbial biofilm and thus reduction of bacterial colonisation is achieved with hand instruments, ultrasonic tips and powder-blasting devices that use glycine powder. In

addition, we use multiple 3% hydrogen peroxide rinses and chlorhexidine rinses applied directly and alternately. Local antibiotics can also be administered as a supportive measure. We use Ligosan Slow Release from Kulzer with the aim of keeping the tissue free of bleeding and reducing pocket depths.

In the case of defect morphologies that limit access or already advanced bone resorption, we apply a surgical therapy that involves flap elevation, analogous to open periodontal therapy, to achieve better visibility over the contaminated parts and thus better accessibility. For this purpose, we use fine nickel-titanium brushes for decontamination, as well as glycine powder and repeated 3% hydrogen peroxide and chlorhexidine rinses.

Furthermore, regenerative work can be carried out, and the success of this is directly related to the morphology of the defect. If a small bowl-shaped intraosseous defect is present, it is easier to regenerate with augmentation than are already developed supra-crestal defects which show screw threads that are above bone level. If this occurs, the threads are removed and the protruding implant surface is smoothed as far as possible to eliminate roughness, with the aim of preventing plaque colonisation anew. There are also combined defects for which both procedures can be used. We use autogenous bone chips and a bone substitute material covered with a collagen membrane for regeneration. The main aim is to support the soft tissue, and in many cases thickening owing to scarring is observed.

How do you think the prevention and treatment of peri-implantitis will develop in the future?

Particular attention should be paid to postoperative care at short intervals in order to be able to intervene as early as possible. Immunomodulatory therapies are currently under discussion. Through the anti-inflammatory effect of natural cranberry extract on the tissue-destroying macrophages, topical application should directly intervene in the intensity of the inflammatory reaction.

Furthermore, I could imagine that new carrier materials for local antibiotics or natural extracts—as already mentioned—will be developed. Modified implant surfaces, possibly with anti-infection or plaque-inhibiting properties, are also conceivable. However, I think it is most important to raise patients' awareness and motivate them to have regular and thorough follow-up care and to remove plaque at home, irrespective of the therapeutic approach. After all, prevention is better than cure.

contact

Dr Inga Boehncke, MSc

Bremen, Germany

+49 421 232722, info@zahnarzt-boehncke.de

www.instagram.com/doc.bremen



Dr Inga Boehncke

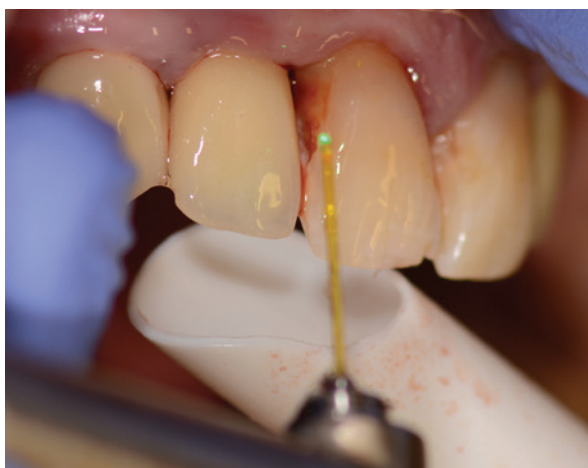Laser protocol for peri-implantitis treatment

An interview with Dr Michał Nawrocki, Poland

Laser is becoming essential for every modern dental practice. Moreover, from an educational standpoint, there are many benefits in terms of the personal and professional development of the practitioner. In this interview with **implants—international magazine of oral implantology**, Dr Michał Nawrocki explains how laser dentistry has helped to advance his practice and career and why dental laser, especially Fotona's LightWalker, has become an essential part of his daily practice.

Dr Nawrocki, you've been using laser since 2016. Looking back at your journey as a laser dentist, how has LightWalker impacted your everyday practice?

I started my great adventure with Fotona's LightWalker in 2016. Before that I had used a diode laser, but it was insufficient for me, and to be honest my knowledge of lasers, physics, indications and procedures was incomplete at the time. Then in January 2016, I invited Dr Ilay Maden to my clinic to conduct a course and teach my colleagues and me about various Er:YAG and Nd:YAG procedures with the LightWalker laser. A few months later, I decided to extend my knowledge about lasers by attending the Master of Science in Lasers in Dentistry presented by Prof. Norbert Gutknecht in Aachen. Now, I cannot imagine continuing my daily practice and treatments without having LightWalker. Sometimes, I use it as an additional tool during certain procedures, but very often it's a crucial and necessary tool for me to use to conduct a particular procedure.



Use of the Er:YAG laser Varian tip for granulation tissue removal, implant surface decontamination and surface ablation of infected bone.

What procedures do you perform with laser?

Laser can be used in all fields of dentistry; however, I am mainly focused on implantology and surgery, as well as prosthodontics. In prosthodontics, it can be used for sulcus conditioning, preparation for veneers and removal of complete ceramic crowns, as well as during more challenging procedures like crown lengthening before tooth preparation. We can use it in gingivectomy (Nd:YAG laser) and bone recontouring (Er:YAG laser).

All my surgery cases are finished with photo-biomodulation using the Nd:YAG Genova handpiece. I have observed that wound healing is much faster and better in such cases owing to pain reduction, disinfection, reduction of oedema and the laser's analgesic function. Sometimes, I have to conduct an endodontic treatment during the procedure (which is quite rare and normally done by my colleagues), in which case I really appreciate the deep disinfection with Nd:YAG, which offers the highest bacterial reduction in comparison with other wavelengths, and the Er:YAG SWEEPS [shock wave enhanced emission photoacoustic streaming] procedure, which provides the most effective cleaning and disinfection. With surgical treatments, I use both wavelengths in almost all cases. Even when performing an easy and fast tooth extraction, I can use Er:YAG for granulation tissue removal, followed by Nd:YAG for disinfection, clot stabilisation and finally photo-biomodulation. Of course, I use laser before implant insertion, as well as when complications appear.

In your opinion, what are the main benefits of choosing a laser system that includes two complementary wavelengths, such as Er:YAG and Nd:YAG, especially in the field of oral surgery?

Very often, we combine these two wavelengths to conduct treatment in a fast, safe and predictable way. For me, it's crucial to use these two complementary wavelengths—the interaction between the tissue and laser beam is quite different, and owing to these differences in absorption, transmission and scattering, we obtain different actions. For example, during root apicectomy, after flap elevation, I remove granulation soft tissue with the Er:YAG laser using the H14 handpiece with a cylindrical tip (or when I want to be more precise—a Varian tip) and the apicectomy is done with the H02 non-contact handpiece. As the next step, I conduct deep disinfection with the Nd:YAG laser (trans-

mission in hydroxyapatite and absorption in pigmented bacteria) before bone augmentation. Finally, I finish the treatment with photo-biomodulation using the Nd:YAG laser. As you can see from this example, I need both of these two complementary wavelengths to achieve final success with fast healing and proper bone regeneration.

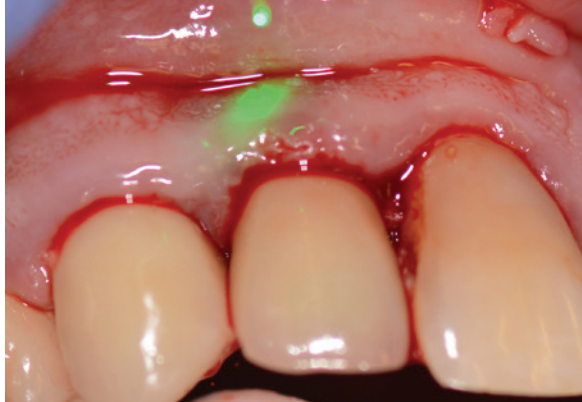


Photo-biomodulation with the Nd:YAG laser.

One of your main fields of specialisation is implantology. Where does the laser fit in this field?

We can use LightWalker for all implantology cases. Sometimes, it's only needed for better and faster wound healing (photo-biomodulation with the Nd:YAG laser), but very often it is necessary to conduct the treatment. For me, it's the most important device during immediate implantation with immediate loading, especially when the bone must be very precisely cleaned of granulation soft tissue and disinfected. In the meantime, we can also provoke bleeding of the bone using the Er:YAG laser for superficial bone ablation. I also really appreciate the use of laser during bone grafting with the Khoury method. Sometimes, I combine this technique with immediate implantation, especially in the aesthetic zone. Then, after bone shield fixation, I can use the laser for bone recontouring. With the Er:YAG laser, it's done very precisely—I remove sharp edges and create an emergence profile for the crown—and most importantly, everything is safe for the shield (almost no vibration, so we don't lose stability) and the implant (no thermal effect).

Of course, we can also use the Er:YAG laser for more common and "easy" procedures—like implant uncovering (Er:YAG). The healing is faster and we avoid suturing, but of course, even with the thin chisel tip, some amount of soft tissue is vapourised—so it cannot be conducted in all cases.

In 2018, you defended your master's thesis at RWTH Aachen University titled *Comparison of Two Methods of Peri-implantitis Treatment with the Use of Nd:YAG and Er:YAG Laser*. Can you tell us more about that research?

Owing to the increasing number of implants being placed, the development of peri-implantitis is a growing concern and one of the primary challenges in present-day dentistry. In cases of inflammation, it is necessary to implement treatment, or risk implant loss. However, until now, no uniform protocol or procedure has been defined which could be considered the best and the most effective solution. Different methods of treatment of tissue inflammation around the implant are used, depending on the extent of inflammation, method availability, type of defect, and skills and experience of the dental surgeon.

We know that laser can be used for the treatment of inflammation in soft and hard tissue around implants, such as mucositis and peri-implantitis. I wanted to investigate what kind of procedure would be the most effective and minimally invasive—so the question was whether we could use a minimally invasive, flapless procedure for proper treatment and solve the problem of inflammation.

The procedures were conducted with Er:YAG and Nd:YAG lasers. In the first group of patients, a mucoperiosteal flap was elevated in order to gain better access to the operative area, while the second group of patients was treated using a more minimally invasive procedure without the flap method. The assessment of treatment effectiveness involved clinical and radiographic examination before the surgical procedures and three months after the laser procedures. After conducting the intra-oral examination and defining plaque, probing depth and bleeding on probing indices, photographic documentation of a given area was performed, bitewing and occlusal surface radiographs were taken, and professional scaling and root planing were subsequently carried out.

Based on my research, we know that non-surgical treatment of peri-implantitis is effective and very often reduces inflammation. Of course, when we have severe defects, it's impossible to avoid a surgical procedure to elevate a flap to get proper access to the defect. In such cases too, we should use a non-surgical procedure as a first step to decrease the inflammation and, after two to three weeks, perform the flap procedure. („...“)

Unexpected ending?



Read the complete interview **online**



about the author



Dr Michał Nawrocki is an experienced implantologist. In 2009, he obtained a dental implantology certificate from Goethe University in Frankfurt am Main in Germany. In 2015 and 2016, he participated in the Implant Prosthodontics Program at the Mediterranean Prosthodontic Institute in Castellon in Spain. Dr Nawrocki also obtained an implantology certificate from the University of North Carolina at Chapel Hill in the US in 2016 and earned an MSc in lasers in dentistry from RWTH Aachen University in Germany in 2018. He is a member of the Polska Akademia Stomatologii Estetycznej (Polish academy of aesthetic dentistry), Polish Society for Laser Dentistry and International Society for Laser Dentistry. Dr Nawrocki runs a private practice in Gdańsk in Poland.

contact

Nawrocki Clinic

Ul. Czarny Dwór 10/34, 80–365 Gdańsk, Poland
+48 501 143042, rejestracja@nawrockiclinic.com



breident medical

The alternative to standard dental implants

German dental implants company breident medical has introduced the copaSKY ultrashort implant system which offers an alternative to standard dental implants which not only reduces costs—as a result of eradicating the need to build up the bone through augmentation

or sinus lift procedures—but also offers a less invasive route to restoration. With a length of only 5.2mm and a diameter of 4.0, 4.5, 5.0 or 6.0, the copaSKY ultrashort implant makes it possible to utilise the available native bone optimally. It creates a stable basis for implant-supported

restoration, even under the most challenging of conditions. Award winning Dr Marcus Gambroudes has placed over 4.000 implants and trains and mentors other dentists about complex implant cases. He comments “I am impressed by the clinical applications of the copaSKY implant range. I use it for the versatility of the implant for placement in areas of limited bone height, as well as immediate placement in extraction sockets and full arch immediate load.”

breident medical GmbH & Co. KG, Germany
+49 7309 872-600
www.breident-implants.com

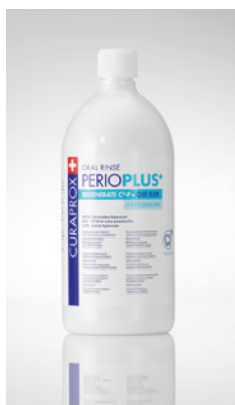Curaden

Rinsing against SARS-CoV-2—one mouthwash reduces infection risk

In a study that is the first of its kind, researchers from Claude Bernard Lyon 1 University in France have shown that Curaprox’s Perio plus regenerate mouthwash reduces the risk of transmitting SARS-CoV-2. A single rinse with the mouthwash lowers the viral load in the mouth by 71%, aiding the immune system in controlling the start of infection.

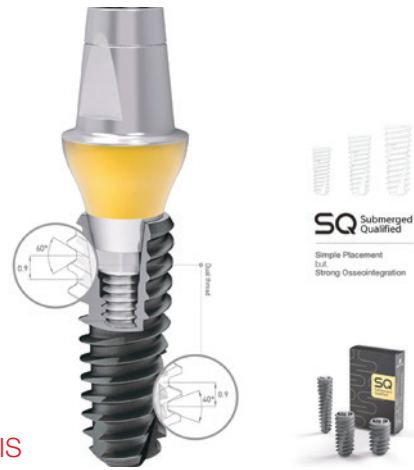An important breakthrough

The Curaprox Perio plus mouthwash protects against viral infections and has protective and regenerative properties, thanks to the hyaluronic acid it contains. The result is an oral mucosa that is in optimal health and minimally susceptible to viral infection. Rinsing and gargling with Perio plus regenerate is an excellent barrier measure against the spread of SARS-CoV-2. The discovery has interesting implications for fighting the COVID-19 pandemic, as well as for future antiviral preventive measures. Be it for personal or clinical use, antiviral mouthwashes could play an important role in reducing the general risk of contamination.



The study, titled “Use of an antiviral mouthwash as a barrier measure in the SARS-CoV-2 transmission in adults with asymptomatic to mild COVID-19: A multicentre, randomized, double-blind controlled trial”, was published in the October 2021 issue of *Clinical Microbiology and Infection*.

Curaden, Switzerland
www.perioplus.com



DENTIS

Easy placement and optimal osseointegration

The SQ implant is an integrated outcome of implant technology and clinical knowledge. It has been verified by clinical studies for over 16 years. It is becoming an exemplary product for fast and convenient implantation and is currently in the spotlight as an essential item for dental clinics. We will thoroughly explore the SQ that is further expanding the base of clinical studies with a perfect SQ implant solution that covers smooth implantation, osseointegration, as well as aesthetics.

SQ, launched as the new implant brand of DENTIS in 2018 based on decades of implant technology and expertise, stands for Submerged and Qualified System and for “Submerged Type, Depth Control.” As the name implies, it is an easy-to-install, bone-level implant that maximises placement, depth control, and fixation power, solving many challenges of implant surgery.

DENTIS, South Korea
+82 53 5832804
www.dentisimplant.co.kr/eng

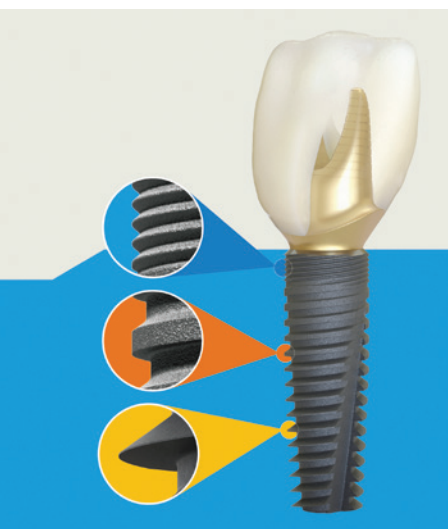


Dentsply Sirona

Discover the joy of efficient handling

The DS PrimeTaper Implant System delivers seamless workflow integration, enviable aesthetics, lasting bone care and efficient handling. The unique, progressive thread is designed to let clinicians install the implant quickly and shorten the procedure. The implant has three distinct thread shapes. On the top part of

the implant is the conserving MicroThread shape that provides long-term marginal bone maintenance. In the middle, there's the condensing crestal squared thread shape, and at the bottom of the implant the cutting apical pointed thread shape. Together, these variable thread shapes with the pronounced flute design contribute to initial stability and cutting efficiency, linear torque build-up throughout the implant installation for predictable implant placement, and immediate installation stability for all implant cases.



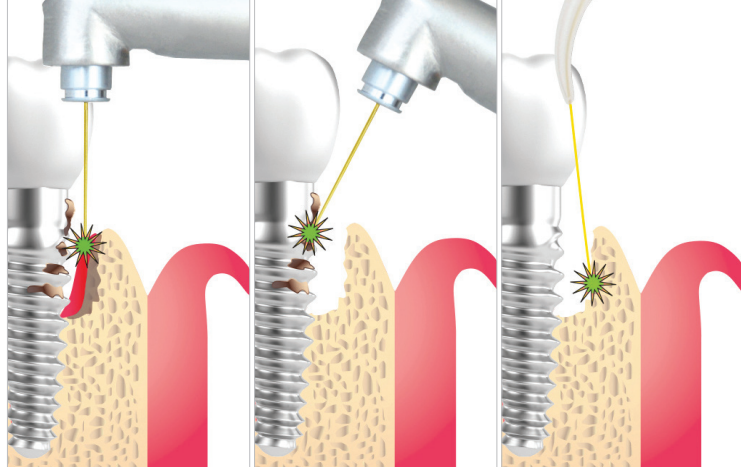
Dentsply Sirona
Sweden
+46 31 3763000
www.dentsplysirona.com/primetaper

Straumann

Iconic Tissue Level meets Immediacy

The science of tissue-level implants has been taken to the next level. Straumann® has built on and perfected its well established Straumann® TL system.

The Straumann® TLX system combines a neck design mimicking the natural anatomy and respecting the biological distance in all dimensions with latest innovative endosteal design, optimised for primary stability. The new system is designed to significantly reduce the risk of inflammation and bone resorption as the implant-abutment interface is moved away from the bone. The Straumann® TLX system has been developed for optimal primary stability and immediate protocols in all bone types and lets you increase efficiency with a one-stage, straightforward workflow. It forms the perfect complement to the Straumann® BLX system for bone-level implants. Both systems use one common drill set and TorcFit™ connection for maximum compatibility with minimum investment.



Fotona

Dual wavelength power for effective treatments

Peri-implantitis is a well-known inflammatory process affecting the soft and hard tissues surrounding dental implants. Fotona's award-winning SkyPulse and LightWalker dental lasers offer one of the most effective methods of peri-implantitis treatment, proven to successfully control infection and halt disease progression. The dual-wavelength procedure harnesses the bactericidal effect of the Er:YAG wavelength for decontaminating the implant surface and removing granulomatous tissue without chemicals, while the subsequent Nd:YAG or diode treatment step promotes disinfection and faster healing by biostimulating the tissue with photo-biomodulation (PBM) to help dilate blood vessels and improve blood circulation while also accelerating tissue regeneration. Fotona's unique MarcCo hand-piece line features a special ergonomic design that is engineered to enable fast and simple non-invasive PBM treatments for peri-implantitis, ensuring faster healing with reduced pain and inflammation.

Fotona d.o.o., Slovenia
+386 1 5009100
www.fotona.com

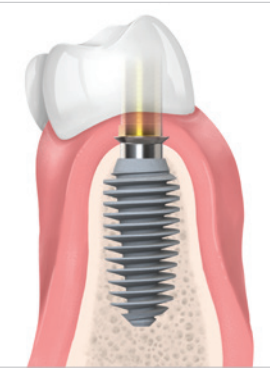


Institut Straumann AG, Switzerland
+41 61 9651111, www.straumann.com



Argon Medical

A combination of main healing aspects and desirable aesthetics



The successful K3Pro implant line from Argon Medical has been enlarged last year by an additional innovation, namely The Compress Implant. The dire need of discerning implantologists to provide their patients with stable provisionals immediately after implantological operations, requires an implant with exceptionally high primary stability—especially in the case of soft bone. For immediate implantations, however, it is often necessary that self-tapping thread flanks secure the implant with the alveolar wall. Also and of much importance is a generous free space for healing through blood coagulation. The new Compress Implants fulfil both aspects mentioned above without neglecting the classic virtues of optimisation for subcrestal insertion for outstanding aesthetics. Furthermore, the anti-bacterial seal, as well as the micromovement-free connection for sustained tissue preservation is also given in this well-rounded idea of the Stable Tissue Concept. The compressive and progressive self-tapping thread for easy and precise insertion in soft bone has a plateau design and offers added primary stability for immediate loading. The implant diameter is measured according to the width of the thread flank, whereas the implant body remains similarly slim. Therefore, the choice of diameter regulates the degree of primary stability.

Argon Medical, Germany
+49 6721 3096-0, www.argon-medical.com

BioHorizons Camlog

New regenerative materials for biomaterials portfolio

BioHorizons Camlog is expanding its portfolio of dental implant products to include innovative regenerative materials that cover almost all conceivable material and application preferences. These biomaterials include MinerOss[®] A, SynMax[®], PermaPro[®], Argonaut[®] and CeraOss[®]. The new products are manufactured by botiss biomaterials GmbH, whilst being distributed by BioHorizons Camlog under their own brand names. In the case of hard and soft tissue deficiencies, the choice of suitable bone graft substitute materials is of crucial importance to achieve the desired clinical result in functional, structural and aesthetic terms. MinerOss[®] A particles are allograft bone substitute from human donor bone, processed by the Cells+Tissuebank Austria, and available in cancellous and corticocancellous form. SynMax[®] is a fully synthetic, safe, and biocompatible material that, when brought into an osseous environment, serves as an osteoconductive scaffold

Neoss

Three-day conference to celebrate 20 years of Intelligent Simplicity

This summer, Neoss is celebrating 20 years of Intelligent Simplicity and is inviting the dental community from around the globe to attend an exceptional scientific programme. Happening in Gothenburg, Sweden, the home of modern implantology and Prof. Per-Ingvar Brånemark, from 9 to 11 June. This three-day conference chaired by Prof. Christer Dahlin, will invite renowned speakers to the stage to discuss topics and techniques such as prosthetic simplicity without compromise, simplicity in practice, managing risk factors, digital flexibility for you and your patient, and accurate simplicity in intra-oral scanning. Included, will be various break-out sessions for the whole dental team. The programme lectures and break-out sessions will showcase how you can bring efficient workflows into your daily practice. And that's not all! Each day, scheduled around the conference will be social activities and excursions which will delight all, from the more energetic morning running, boat trips and exciting dinners, to the more relaxed sunrise yoga and health and wellbeing sessions. All to celebrate the valued community Neoss has created over its 20 years of innovation.

Neoss Ltd., UK
www.neossintegrate.com

to support the ingrowth and fusion of adjacent, vital bone. PermaPro[®] is an exceptionally thin, non-resorbable and biocompatible membrane. Argonaut[®] membrane is a completely resorbable collagen membrane produced from porcine pericardium used to support guided tissue and bone regeneration. CeraOss[®] is a one hundred per cent pure bone mineral of bovine origin, which provides an appropriate scaffold for the adherence and migration of osteogenic and blood vessel-forming cells, which in turn promotes bone regeneration.

Argonaut[®], CeraOss[®], PermaPro[®] and SynMax[®] are registered trademarks of Camlog Biotechnologies GmbH. MinerOss[®] is a registered trademark of BioHorizons.

Camlog Biotechnologies GmbH, Switzerland
+41 61 5654100
www.biohorizonscamlog.com/biomaterial-news



Osstem Europe: New European headquarters in Prague

Henrik Eichler, Germany

As one of the fastest growing implant manufacturers in the world, the South Korean company Osstem Implant provides dental implants and related products to patients in more than 70 countries. Now the company opened the doors to its new headquarters in Prague. In an interview with **implants**, JM Lee, Executive Managing Director of Osstem Europe, talks about the company's motivation and their plans for the European market.

Osstem Implant was founded in South Korea in 1997. Why did you choose Prague as the location of your new European headquarters?

There were several reasons for choosing the Czech capital. It is geographically in the centre of Europe, and we wanted to be able to support our 41 partners across the continent even better and use the multi-cultural environment and thus this great pool of talents for our organisation. The expansion of our infrastructure and the ability to offer a wider portfolio of products and provide a total solution was another reason for Prague. Now we have a service centre, a training centre, and a logistics service. And of course, we wanted to be able to strengthen our presence in the German market and have the space for our direct sales in Germany.

What significance does the European market have for Osstem?

The European market has always been significant for us, but at the same time we have been recognising it as the most conservative and difficult market. Strategically, as an initial step of our globalisation, we targeted the Asian & Pacific Region, where we successfully grew into one of the market leaders. Thanks to our strong presence in those markets, we were able to achieve our market position as the fourth biggest dental implant manufacturer worldwide, accounting for 8% of the global market share.



Fig. 1: JM Lee, Executive Managing Director of Osstem Europe.

What makes Osstem Europe special compared to other major competitors?

I would say our various solutions and unbeatable value-for-money ratio. We have a range of special surgery kits that other companies do not offer. For example, the CAS Kit for sinus surgery, the ESSET Kit for narrow ridge and the ESR Kit maintenance kit. These special kits can serve as an entry product for our new customers. Furthermore, we offer high-quality products at a reasonable price.

Since the foundation of our company, we have been continuously investing 7% of our annual sales on R&D and recently we have even increased this share up to 11%. We pursue the philosophy of our founder: "Provide the best value to the dentist and patient." Once the practitioners experience our products, they will realise what I mean.

What are your plans for the future of Osstem Europe, and what developments can your customers perhaps look forward to this year?

We have plans of launching new products such as a new implant system, new implant surface treatments, GBR and of expanding our impression materials line-up. Additionally, continuous online and offline education courses will take place; for instance, Osstem OnDemand and Osstem OnSite. And finally, our annual event "The Osstem-Hiossen Meeting" in Rome will be held on 28 and 29 October 2022.

contact

Osstem Europe
Prague, Czech Republic
+420 296 238801
www.osstem.eu



Fig. 2: Dr Mukesh Soni, Course Director of Practical Implantology, UK (second from left), JM Lee, Executive Managing Director of Osstem Europe (third from left), Ben Nahab, CEO of Dental Direct UK (third from right) and Prof. Marco Tallarico, President of AIC Italy (second from right). Fig. 3: Prof. Marco Tallarico giving the first lecture in the new training centre.



Education across **borders**

Maximise your potential with DGZI's continuing education on an international level

Janine Conzato, Germany



Fig. 1: DGZI vice president Dr Vollmer (center) with the DGZI representatives from Sudan.

The medical market, particularly the dental market, is becoming increasingly global, and promoting medical progress in the field of implantology has always been a priority of the German Association of Dental Implantology (DGZI). DGZI, established and registered in 1970, is the oldest dental implantology association in Germany and represents in its more than 50-year history practice-oriented

and science-based implant dentistry and has set standards in oral implantology in Germany. Its activities are focused on the continuing education and training of implantologists in Germany and abroad. The goal of these activities is to improve quality and quality assurance, as well as the safety of therapies, in the interest of patients. Globalisation in dentistry has for years been setting new standards in the demand for internationally active implantologists and for German dental clinics that cater to international patients. A large number of German dentists work abroad, have partners all over the world and are very successfully engaged on an international level. Many implantologists have also adapted to this situation and are successfully treating patients from abroad. Especially patients from the Arab region, African countries and countries of the Commonwealth of Independent States appreciate the quality and knowledge of German dentistry and visit Germany for extensive dental treatment.

International exchange on implantological standard

In addition to the focus on established practices, international networking is a cornerstone of DGZI's philosophy. When it comes to global education, DGZI has also been a pioneer. Dr Rolf Vollmer, DGZI vice president and treasurer, is responsible for the society's successful foreign policy. In order to disseminate the implantological standard internationally, the German Board of Oral Implantology (GBOI)



"I have been in close cooperation with DGZI/GBOI since 2010 as a speaker in the GBOI programmes all over the Middle East and as a programme director of the Comprehensive Dental Implant Certificate Program, which is accredited by DGZI/GBOI. The feedback I have received from students and attendees has always been encouraging and appreciative. The certificates offered by DGZI/GBOI are also well recognised and distinguished, encouraging more practitioners to join the renowned body."—
Prof. Mohamed Moataz Khamis, University of Alexandria, Egypt



“After my completion of the DGZI/GBOI international education programme in Jordan in 2008, we have started cooperating with DGZI in Sudan. From that time until now, six groups have graduated from this one-year pure scientific programme with strong clinical requirements. Most of our candidates are satisfied with their work development and attribute their success to our GBOI novel programme and the great DGZI team. Although many international education programmes of implantology are running in Sudan, DGZI/GBOI is the most preferred and reliable.” —
Dr Ahmed Fadl, DGZI representative in Sudan

was launched and certified by DGZI. In 2002, a postgraduate programme offered through cooperation with universities, certified visiting professors and opinion leaders was created. Its mission is to elevate the standard of and to advance the science and art of dental implantology by encouraging its study and improving its practice. Besides providing training opportunities for dental experts from all over the world, the programme allows for professionals to acquire internationally recognised certificates such as the DGZI Expert in Oral Implantology certificate and DGZI Specialist in Oral Implantology certificate. These certificates are simultaneous proof of qualified subject-specific English knowledge. In fulfilling its purpose and objectives, the GBOI follows the guidelines and regulations set by the respective associations in Germany, such as the

Bundeszahnärztekammer (German dental association) and Deutsche Gesellschaft für Zahn-, Mund- und Kieferheilkunde (German association of oral and maxillofacial dentistry). It provides international examination procedures to evaluate the profound knowledge, expert skills and special talent required for practitioners to provide comprehensive, safe and effective oral implant therapy solutions for patients. The curriculum of the one-year programme covers surgical anatomy, imaging techniques and preoperative preparation, as well as provides detailed information on at-risk patients, anaesthesia and sedation, odontogenic infections and complications. Furthermore, the programme includes training on surgical basics and traumatology of the teeth and jaws. Also, practical training, patient surgery and e-learning modules are part of the curriculum.



Fig. 2: Congratulations to the examinees from Sudan from the DGZI board members Dr Rolf Vollmer (left) and Dr Rainer Valentin (second from right).

Why choose the GBOI curriculum?

The structural education and suitable training promote participants' success in implant treatment and promote the dental practice too by the dentist having earned the international board-certified qualification and having the certificate on display. The GBOI certificate is a professional qualification awarded by the GBOI and is accredited in all Arab and Gulf countries. Also, it is a step towards obtaining a master's degree in oral implantology from the University for Continuing Education Krems in Austria.

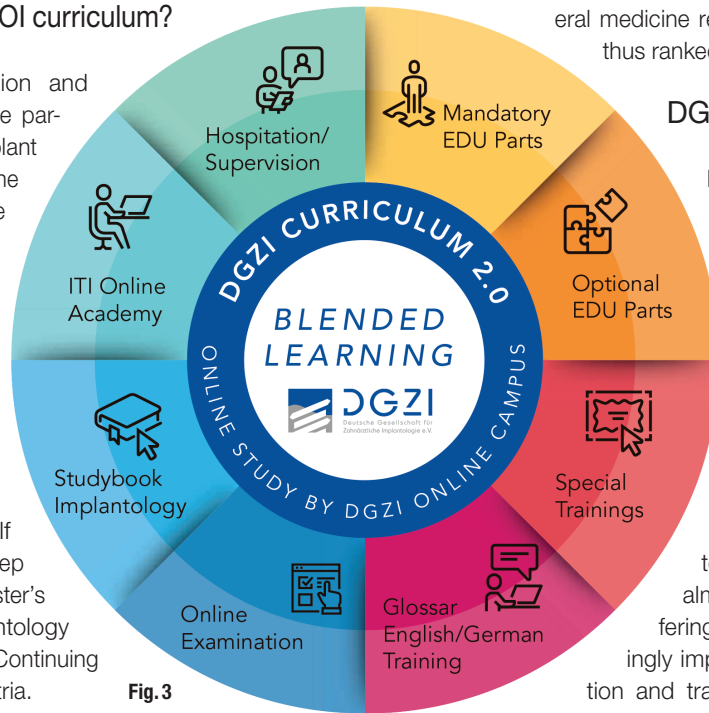


Fig. 3

Learning to perform exact planning avoids mistakes that lead to failures and subsequent medicolegal problems. In Germany, dentistry is ranked fourth regarding cases of suspected malpractice. Of the 14,042 cases of suspected medical errors reported in 2020, 1,198 concerned dentistry and 422 of these could be verified. With 4,337 cases, the disciplines of orthopaedics and trauma surgery had the greatest number of reported allegations. Internal and gen-

eral medicine recorded 1,634 cases and thus ranked second.

DGZI Curriculum 2.0

In 2019, DGZI introduced its online campus, a modern, innovative and, above all, convenient solution for participants. After the launch of the German campus, the English version for international DGZI members followed in 2020. Especially in times when face-to-face training has been almost impossible, online offerings are playing an increasingly important role in the education and training of dentists. Initially

developed only for curricular training at home and abroad, the online campus was opened to all interested dentists, offering this continuing education opportunity to a wider audience. The structure and content of DGZI's successful implantology curriculum was revised in 2019. In addition, all course participants receive access to the ITI Academy, through which young dentists and those with little experience in implantology can learn the fundamentals of dental implantology (Fig. 3)



Fig. 4: Group of participants in the GBOI programme in Sudan around Dr Ahmed Fadl.



Fig. 5: GBOI graduation ceremony in Cairo, Al Jazira Sofitel Hotel.

The new DGZI Online Campus has been completely re-designed and enables e-learning from all devices and from anywhere with Internet access. Well-prepared content, intermediate examinations and a final examination provide the participant with constant feedback on the level of knowledge he or she has achieved and thus

In conclusion, it can be stated that, with regard to the international implantological standard of the future, DGZI/GBOI will continue to work actively on this topic with the aim of mediating between science and clinical practice around the world and continue to validate the relevance of this professional society.



“The scientific and educational cooperation between the Faculty of Dentistry of the Cairo University and DGZI has started officially in the year 2006, when the first GBOI programme in Egypt was launched. I had the pleasure of being responsible for that programme ever since that time and until now. We proudly helped more than 300 graduated dentists, living in Egypt but from different countries to get decent basic and advanced theoretical and practical dental implantology education and international certification.” — Prof. Amr Abdel Azim, University of Cairo, Egypt

prepare him or her for the practical modules in the curriculum. Each block ends with a learning success check. The practical modules, however, can be practised as often as desired in advance of examinations. Since not only theoretical basics are necessary for curricular training, participants also start with practical modules in the face-to-face further training after completing the theoretical training online. Special implant prosthetics, hard- and soft-tissue management, and an anatomy course with work on human specimens form the foundation of the practical modules, which are then supplemented by two further elective modules with freely selectable topics of dental work.

On this behalf the DGZI invites its international guests again this year to the 51st International Annual Congress, which will take place on 30 September and 1 October 2022 at the Hotel Berlin Central District in Berlin.

contact

DGZI e.V.
 +49 211 1697077
 sekretariat@dgzi-info.de
 www.dgzi.de



Association details

Plant-derived composite developed by MIT researchers

New material could pave the way for sustainable plastics

Researchers at the Massachusetts Institute of Technology (MIT) have developed a potential 3D-printing material and conventional casting within dentistry. They have engineered a composite made mostly from cellulose nanocrystals, which are chains of organic polymers arranged in crystal patterns mixed with a bit of synthetic polymer. The researchers found the cellulose-based composite is stronger and tougher than some types of bone, and harder than typical aluminium alloys.

The team hit on a recipe for the CNC-based composite that they could fabricate using both 3D printing and conventional casting. They printed and cast the composite into penny-sized pieces of film that they used to test the material's strength and hardness. They also machined the composite into the shape of a tooth to show that the material might one day be used to make cellulose-based dental implants — and for that matter, any plastic products — that are stronger, tougher, and more sustainable. “By creating composites with CNCs at high loading, we can give polymer-based materials mechanical properties they never had before,” says A. John Hart, professor of mechanical engineering. “If we can replace some petroleum-based plastic with naturally-derived cellulose, that’s arguably better for the planet as well.”



Researchers at Massachusetts Institute of Technology have developed a new composite material that could one day be used to make implants.

The study, titled “Printable, castable, nanocrystalline cellulose-epoxy composites exhibiting hierarchical nacre-like toughening”, was published online on 10 February 2022 in *Cellulose*.

Source: MIT

OR Foundation meets in Rome

Inauguration of new board of trustees and new executive director

On 29 November 2021 the Oral Reconstruction (OR) Foundation has announced that Prof. Mariano Sanz from Spain, Dr Luca Cordaro

from Italy and Prof. Irena Sailer from Switzerland were elected to its board of trustees during the board meeting in Rome. Prof. Sanz was also officially inaugurated as president of the foundation.



From left: Dr Martin Schuler, who has held various management positions at Straumann in the past; Prof. Irena Sailer, head of the Division of Fixed Prosthodontics and Biomaterials at the University of Geneva in Switzerland; Prof. Mariano Sanz who has published more than 350 scientific articles and book chapters about periodontics, implant dentistry and dental education; and Dr Luca Cordaro who is head of the Department of Periodontology and Prosthodontics at the Eastman Dental Hospital in Rome in Italy. (Image: © Oral Reconstruction Foundation)

In addition, Dr Martin Schuler, who has a strong background in the field of medical devices and dental implants, was appointed executive director of the foundation, taking over responsibilities from Dr Alex Schär, who is retiring after 16 years as board member and five years as the foundation's CEO. Dr Schuler assumed full responsibility for the foundation on 1 January 2022. Dr Schär will support the transition of projects until the end of March 2022.

During his presidency, Prof. Sanz intends to focus on supporting young and upcoming scholars and on fostering clinical research and efficient treatment approaches for the benefit of the patient. Many educational events are scheduled for 2022, including symposia in France, Germany, Japan, Spain and the US, and the foundation will offer an excellent platform for the exchange of expertise between universities and dental practitioners worldwide throughout the year.

More information about the foundation can be found online at orfoundation.org.

Source: Dental Tribune International

EURO IMPLANTO

NICE | CÔTE D'AZUR | FRANCE

du 6 au 9
AVRIL 2022

PALAIS DE LA MÉDITERRANÉE

consultez le programme détaillé sur www.euroimplanto.fr

crédit photo : David Hirsch

MAKE IMPLANTOLOGY SIMPLE



WIR FÜR DICH
NEXT TO YOU
DEUTSCHE GESELLSCHAFT
FÜR ORALE IMPLANTOLOGIE



VILLE DE NICE

Congresses, courses and symposia



EuroPerio10

15–18 June 2022
Copenhagen, Denmark
www.efp.org/europerio




AAID Annual Conference

21–24 September 2022
Dallas, TX, USA
www.aaid.com/annual_conference



29th annual scientific meeting of EAO

29 September–1 October 2022
Geneva, Switzerland
www.eao.org



51st International Annual Congress of DGZI

30 September–1 October 2022
Berlin, Germany
www.dgzi-jahreskongress.de

implants

international magazine of oral implantology

Imprint

Publisher

Torsten R. Oemus
oemus@oemus-media.de

CEO

Ingolf Döbbbecke
doebbecke@oemus-media.de

Member of the Board

Lutz V. Hiller
hiller@oemus-media.de

Chairman Science & BD

Jürgen Isbaner
isbaner@oemus-media.de

Chief Editorial Manager

Dr Torsten Hartmann
(V. i. S. d. P.)
hartmann@dentalnet.de

Editorial Council

Dr Rolf Vollmer
info.vollmer@t-online.de

Dr Georg Bach

doc.bach@t-online.de

Dr Suheil Boutros

SMBoutros@aol.com

Editorial Management

Janine Konzato
j.konzato@oemus-media.de

Executive Producer

Gernot Meyer
meyer@oemus-media.de

Product Manager

Timo Krause
t.krause@oemus-media.de

Art Director

Alexander Jahn
a.jahn@oemus-media.de

Designer

Franziska Schmid
grafik@oemus-media.de

Customer Service

Marius Mezger
m.mezger@oemus-media.de

Published by

OEMUS MEDIA AG
Holbeinstraße 29
04229 Leipzig, Germany
Tel.: +49 341 48474-0
Fax: +49 341 48474-290
kontakt@oemus-media.de

Printed by

Silber Druck oHG
Otto-Hahn-Straße 25
34253 Lohfelden, Germany

implants

international magazine of oral implantology is published in cooperation with the German Association of Dental Implantology (DGZI).

DGZI

DGZI Central Office
Paulusstraße 1
40237 Düsseldorf, Germany
Tel.: +49 211 16970-77
Fax: +49 211 16970-66
office@dgzi-info.de

www.dgzi.de

www.oemus.com

www.implants.de



Copyright Regulations

implants international magazine of oral implantology is published by OEMUS MEDIA AG and will appear with one issue every quarter in 2022. The magazine and all articles and illustrations therein are protected by copyright. Any utilisation without the prior consent of editor and publisher is inadmissible and liable to prosecution. This applies in particular to duplicate copies, translations, microfilms, and storage and processing in electronic systems.

Reproductions, including extracts, may only be made with the permission of the publisher. Given no statement to the contrary, any submissions to the editorial department are understood to be in agreement with a full or partial publishing of said submission. The editorial department reserves the right to check all submitted articles for formal errors and factual authority, and to make amendments if necessary. No responsibility shall be taken for unsolicited books and manuscripts. Articles bearing symbols other than that of the editorial department, or which are distinguished by the name of the author, represent the opinion of the aforementioned, and do not have to comply with the views of OEMUS MEDIA AG. Responsibility for such articles shall be borne by the author. Responsibility for advertisements and other specially labeled items shall not be borne by the editorial department. Likewise, no responsibility shall be assumed for information published about associations, companies and commercial markets. All cases of consequential liability arising from inaccurate or faulty representation are excluded. General terms and conditions apply, legal venue is Leipzig, Germany.

EXCELLENCE IN IMMEDIACY

Straumann® BLX Confidence beyond Immediacy.



DYNAMIC BONE MANAGEMENT

Intelligent implant concept supporting immediate protocols in all bone types.



ESTHETIC EASE CONCEPT

One connection and under-contoured prosthetics to deliver esthetics with ease.



REAL CONFIDENCE

Backed by long-term scientific evidence for the technologies Roxolid® material and SLActive® surface.

BLX unifies progressive functional design with our high-performance Roxolid® material and the clinically proven SLActive® surface, designed to provide you with confidence for all clinical situations. Innovations like the VeloDrill™ System, Straumann® Dynamic Bone Management and our Esthetic Ease Concept are aimed to significantly improve surgical and restorative workflows.

Contact your local Straumann representative or scan QR-Code



A0016/en/B/01-IIM 02/22

Integrate 2022

JUNE 9-11
GOTHENBURG
SWEDEN



Register now!
neossintegrate.com

Integrate. Educate. Celebrate.

Neoss® celebrates 20 years of Intelligent Simplicity

Join us and our community from around the globe for an exceptional scientific program across three days. It will be an action-packed conference with endless opportunities for continuing education and to integrate with your peers.

Scientific Chair – Prof. Christer Dahlin

Meet our speakers

Dr. Emilie Abraham, United Kingdom
Dr. Michael Braian, Sweden
Dr. Pierluigi Coli, United Kingdom
Dr. Marcus Dagnelid, Sweden
Dr. Fabia Flensburg, Germany
Dr. Scott Froum, United States
Dr. David González, Spain
Dr. Nicolas Haßfurth, Germany
Dr. Norbert Haßfurth, Germany
Dr. John Hodges, United States
Prof. Torsten Jemt, Sweden
Dr. Nermin Kamal, Egypt

Dr. Sreenivas Koka, United States
Dr. Nico Laube, Germany
Dr. Giuseppe Luongo, Italy
Dr. Hazem Mourad, Egypt
Dr. Rishi Patel, United Kingdom
Mr. Steven Pigliacelli, United States
Prof. Raoul Polansky, Austria
Dr. Richard Rasmussen, United States
Dr. Rob Ritter, United States
Dr. Isabella Rocchietta, Italy
Dr. Chris Salierno, United States
Dr. Ronak Sandy, Sweden

Dr. Christian Schober, Austria
Dr. Silvio Schütz, Switzerland
Dr. Lloyd Seanson, United Kingdom
Prof. Lars Sennerby, Sweden
Dr. Nicola Sgaramella, Italy
Mr. Dhrumil Shah, United Kingdom
Dr. Kavita N. Shah, United Kingdom
Dr. Stephan Studer, Switzerland
Dr. Alberto Turri, Sweden
Dr. Nicole Winitsky, Sweden
Prof. Burak Yilmaz, Switzerland
Dr. Jakob Zwaan, Italy

