

A 12-month follow-up

Delayed immediate implant placement and direct soft-tissue management

Dr Haki Tekyatan, Germany

This follow-up after 12 months concerns the current clinical and radiological condition of a case previously documented in a published report,¹ more specifically an implantological treatment in region #12. In summary, endodontic treatment of tooth #12 had failed, the tooth was not worth preserving and it was thus extracted in a minimally invasive manner. Local bone and alveolar management were carried out using bio-functionalised (injectable platelet-rich fibrin or A-PRF) CERASORB Foam (curasan), a biomimetic, regenerative β -tricalcium phosphate collagen matrix. Six weeks after the alveolar management, delayed immediate implantation was carried out using a surgical guide and implant position was confirmed via an intraoperative scan. The scan was used to produce a new, special individualised PEEK healing abutment. Another six weeks later, implant exposure and direct soft-tissue management took place in the healing phase with the special PEEK healing abutment. Finally, the fitting of a ceramic crown was carried out. This allowed the creation of favourable conditions under appropriate circumstances and with targeted procedures in order to achieve an aesthetic, prognostically reliable and predictable result. A clinical examination and a radiographic follow-up were carried out after 12 months (Figs. 1 & 2).

Conclusion

The expectations of our implantology patients are very high, particularly in the aesthetically relevant area. It is of particular importance to use targeted procedures and methods to preserve soft tissue and bone for long-term functional and aesthetic success and to ensure the prerequisites for this. In our case, the 12-month follow-up showed stable clinical and radiological conditions to continue ensuring an aesthetic, safe and predictable result.

About CERASORB Foam

The precise filling of bone defects has an important influence on bone regeneration. In this context, the biomimetic, fully resorbable, hydrophilic and malleable β -tricalcium phosphate collagen matrix CERASORB Foam scores highly in every respect.

CERASORB Foam is a matrix of porcine collagen (Type I) and highly porous pure-phase β -tricalcium phosphate granules (CERASORB M, CERASORB Classic) of different sizes and densities. The granules are embedded in the collagen and are fixed by its fibres.

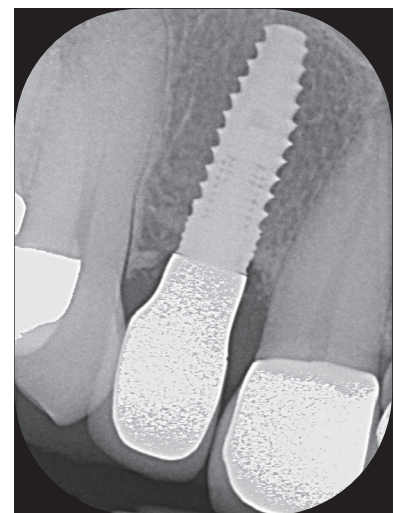
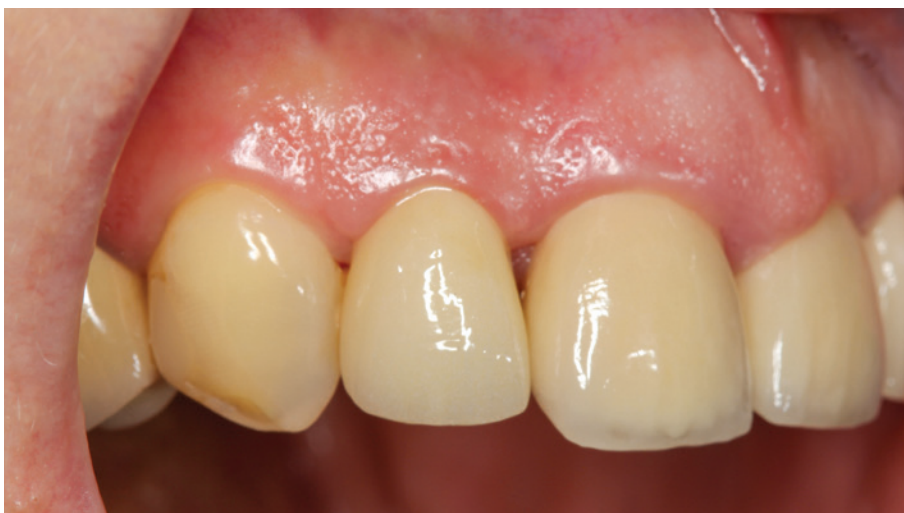

Fig. 1: Clinical situation 12 months after restoration. Stable, non-inflamed soft-tissue conditions. Distally almost complete and mesially partial formation of papillary structures. **Fig. 2:** Radiograph 12 months after restoration. Stable, well-developed osseous structures could be seen around the implant, along with complete integration of the implant. CERASORB Foam had been completely resorbed and replaced by endogenous bone.

Convenient to use

The collagen gives CERASORB Foam its particularly user-friendly properties. Moistened with blood from the defect or mixed with platelet rich fibrin (PRF), the initially dry material can be modelled and then positioned precisely and comfortably in the defect.

Synergy effects through the CERASORB collagen matrix

Collagen has a high binding capacity for physiological fluids. The resulting large area of contact with the surrounding vital bone allows bone-forming cells to integrate the material and facilitates the absorption of nutrients and proteins. This allows collagen to support bone regeneration early on.

The special CERASORB collagen matrix can hold a granulate content of 85% by weight and thus ensures high volume stability after degradation of the more quickly resorbable collagen. The high porosity of the granules in turn offers a stable scaffold for the newly forming bone.

Complete bone regeneration

CERASORB Foam is completely degraded and replaced by autologous bone. Degradation of the biomaterial with the simultaneous formation of new bone leads to the restoration of healthy bone. Resorption occurs in several phases and can easily be followed using radiography.

Literature

1 Tekyatan H. Delayed immediate implant placement and direct soft-tissue management. *implants*. 2021;3:6–12.

Author details



Case report



Contact address

curasan AG

+49 6027 409000

www.curasan.de

AD

Click & Meet

guaranteed COVID-free.



ZWP STUDY CLUB
zwpstudyclub.de

© master1305 -- stock.adobe.com