

Restoring an aesthetic smile

Case study on planning, surgical procedure and aesthetic prosthetic anterior reconstruction

authors Jan Bogena and Daniela Bogena, Germany

_Targeted advertising on television and in magazines has given rise to constantly growing patient demand for best possible aesthetics. Consequently, complete restoration of both implant-based and prosthetic reconstructions is expected, and in many cases patients are even looking for the implant-prosthetic treatment to actually be a substantial improvement on their original situation.

_Case history

A 60-year-old patient presented at our practice with acute pain in the upper anterior tooth region 11 (upper right central incisor). Moderate submucosal

swelling was detected by intraoral palpation. The patient's general history contained no peculiarities.

_Clinical findings

Clinical examination revealed insufficiently fixed restorations in all four quadrants, which according to the patient were at least 20 years old.

Teeth 11 and 21 (upper centrals) had previously been treated endodontically, restored with cast posts and cores and with porcelain-fused-to-metal crowns.

The periodontal findings were normal (PSI [periodontal screening index] 1–2); only in the posterior

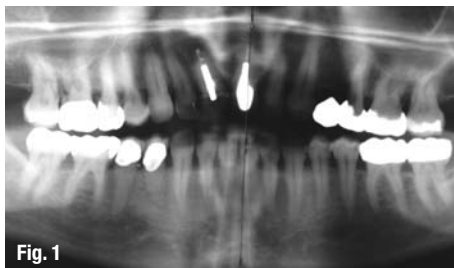


Fig. 1

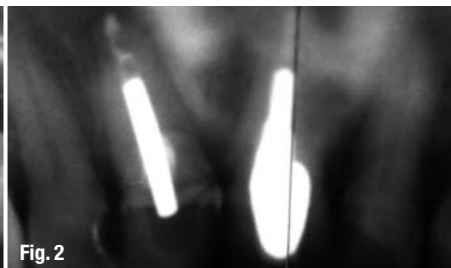


Fig. 2

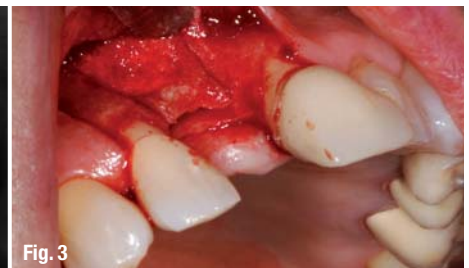

Fig. 3

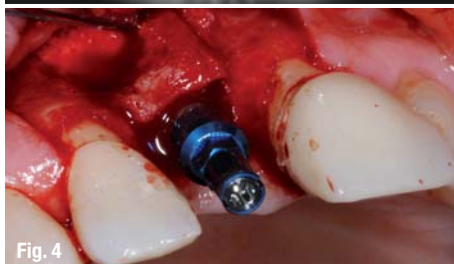

Fig. 4

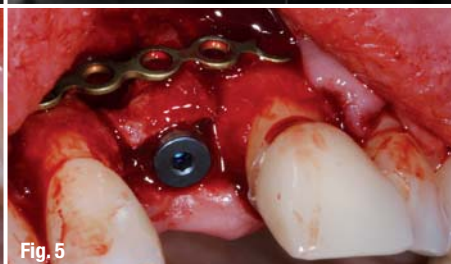

Fig. 5

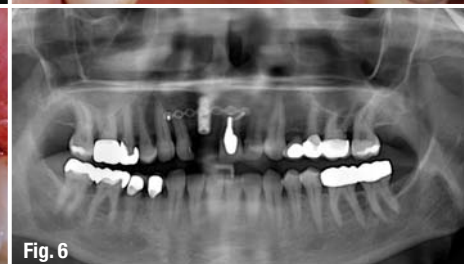

Fig. 6