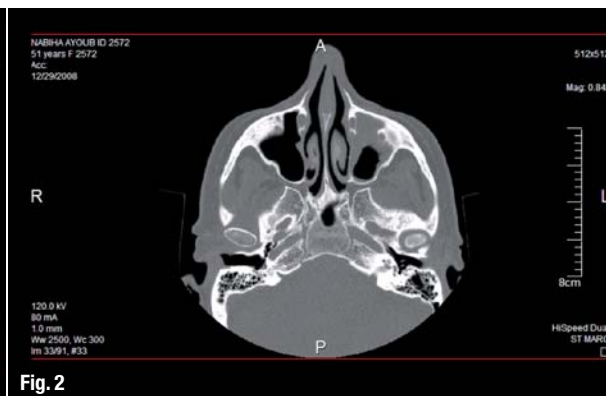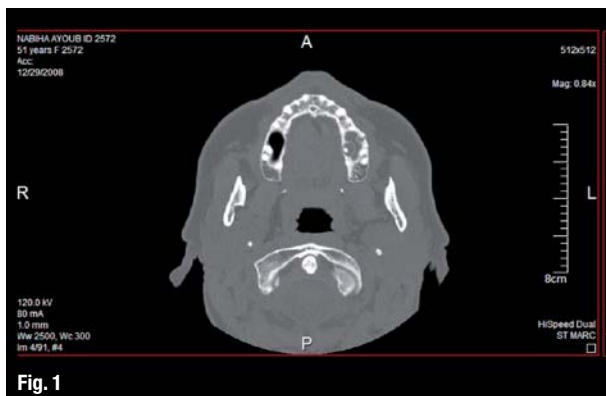


# A cavernous sinus infection: A root-canal case

Author\_Dr Philippe Sleiman, Lebanon



**Fig. 1** Palatal and mesial roots pierced the sinus membrane.

**Fig. 2** The opening in the middle of the sinus could lead to misdiagnosis.

Once upon a time, a patient walked into my office without an appointment. She introduced herself and said that her otorhinolaryngologist had referred her to my office. I asked my assistant to take the X-rays, conduct computed tomography (CT) scanning and schedule the patient as soon as possible. During coffee break, I was going through the scans and decided to look at not only the printouts but all of the slides burnt on the CD. As I was browsing through the slides, I realised that the palatal and mesial roots were piercing the sinus membrane and there was infection around them (Fig. 1). I went a few millimetres up and saw an opening in the middle of the sinus (Fig. 2). Today I know that it would have been a fatal error on my part had I stopped at this level. I do not know what made me continue my observation, but fortunately I did.

**Fig. 3** The infection occupied the greater part of the maxillary sinus and perforated the sinus.

**Fig. 4** The infection invaded the orbit.

**Fig. 5** Thickening of the cavernous sinus.

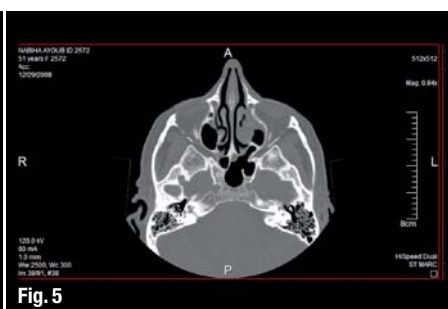
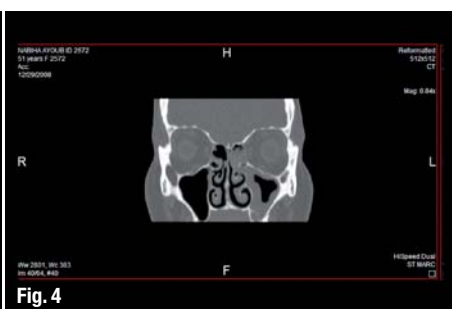
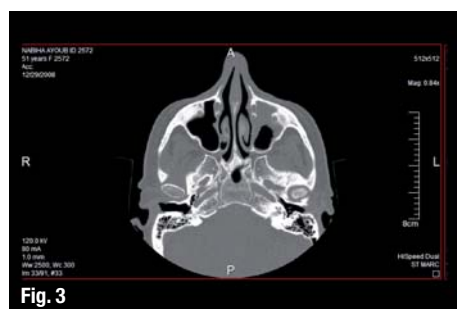A few millimetres higher, the infection was occupying the greater part of the maxillary sinus and perforating the sinus (Fig. 3). Even further up, the infection was invading the orbit (Fig. 4). The really un-

pleasant surprise was a thickening of the cavernous sinus observed in two slides (Fig. 5), and cold sweat covered my face. At this point, any flare-up, inflammation or infection could lead to such severe consequences as thrombosis in the cavernous sinus, bringing about a true life-or-death drama for the patient.

Before presenting the rest of the clinical case, here is a brief summary of the sinuses.

## Sinus definition—physiology

Sinuses are air-filled cavities with classical, pseudo-stratified, ciliated columnar epithelium interspersed with goblet cells. The cilia sweep mucus towards the ostial opening. Obstruction of sinus ostia might lead to mucous impaction and decreased oxygenation in the sinus cavities. During obstruction of the ostia, the pressure in the sinus cavity may decrease, which in turn causes the symptom of pain, particularly in the frontal region.



### Sphenoidal sinuses

The sphenoidal sinuses are located in the body of the sphenoid bone and may extend into its wings. They are unevenly divided and separated by a bony septum. Because of this extensive pneumatization (formation of air cells or sinuses), the body of the sphenoid is fragile. Only thin plates of bone separate the sinuses from several important structures: the optic nerves and optic chiasm, pituitary gland, internal carotid arteries and cavernous sinuses. The sphenoidal sinuses are derived from a posterior ethmoidal cell that begins to invade the sphenoid, giving rise to multiple sphenoidal sinuses that open separately into the sphenoidal recess. The posterior ethmoidal arteries and posterior ethmoidal nerve supply the sphenoidal sinuses.

### Complications of sphenoidal sinusitis (diplopia in childhood)

The most common complication of sphenoidal sinusitis is meningitis. Any surrounding tissue adjacent to sphenoid sinus may be infected. As a result of the close anatomical relationship with the sphenoidal sinuses, cranial nerves II to IV, the dura mater, pituitary gland, cavernous sinus, internal carotid artery, sphenopalatine artery and pterygopalatine nerve have been reported to be infected by dissemination. Complications such as orbital cellulitis, orbital abscess, orbital apex syndrome, blindness, meningitis, epidural and subdural abscesses, cerebral infarcts, pituitary abscess, cavernous sinus thrombosis and internal carotid artery thrombosis have been described in literature.

Clinical suspicion is very important for determining the diagnosis because the symptoms, history and physical examination do not specifically indicate sphenoidal sinusitis. High-resolution axial and coronal CT is recommended for the diagnosis of sphenoidal sinusitis and potential intracranial complications. However, cranial magnetic resonance imaging is superior to CT in terms of detecting the involvement of cranial nerves, cavernous sinus, surrounding neurovascular tissue and the presence of a tumour.

The most common pathogens in the aetiology of sphenoidal sinusitis are *Staphylococcus aureus*, *Streptococcus pneumoniae* and some aerobic and anaerobic *Streptococcus spp.* fungi, particularly *Aspergillus spp.*, should be kept in mind in immunosuppressed patients. Uren and Berkowitz reported eight children with Idiopathic subglottic stenosis, five out of which had been treated successfully with medical therapy. The remaining three children, either unresponsive to medical therapy or complicated cases, had undergone endoscopic sphenoidotomy. At the begin-

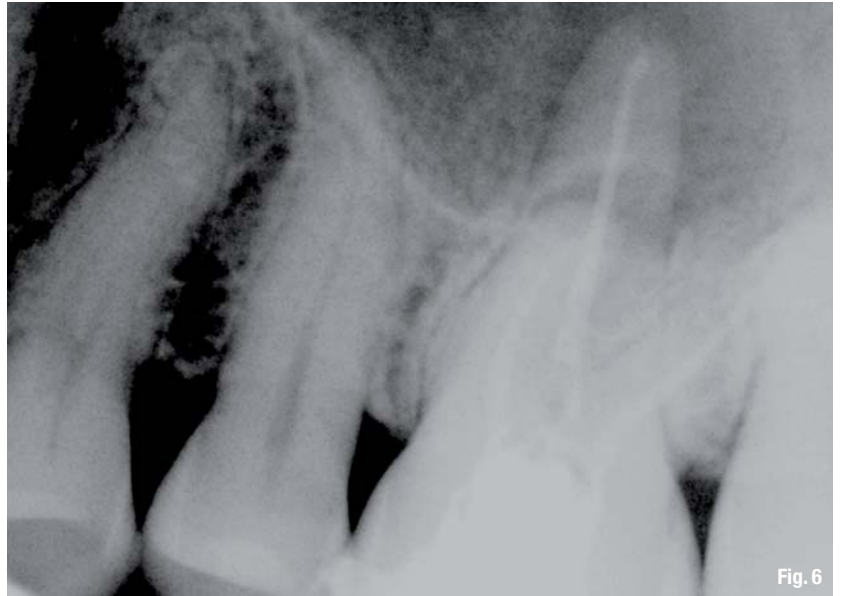


Fig. 6

ning, parenteral antibiotic therapy should be administered, since this infection may cause serious, even fatal, complications. A three- to four-week antibiotic therapy should be completed. Topical decongestants and irrigation with saline solution are recommended as adjunctive therapy.

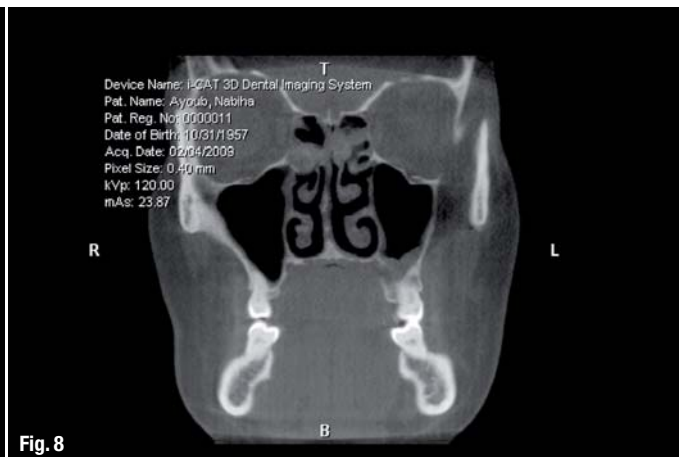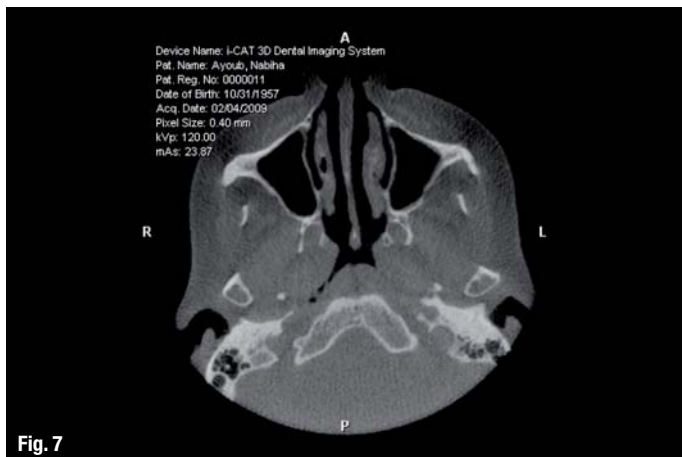Fig. 6\_Immediate post-op X-ray.

Since the sphenoid sinus has anatomical relationships with several vital structures, any delay in correct diagnosis and, therefore, in prompt and adequate treatment, can result in severe and life-threatening complications<sup>1</sup>, such as meningitis, pituitary abscess, peri-orbital cellulitis, orbital cellulitis, optic neuritis, carotid artery thrombosis and cavernous sinus thrombosis. Sphenoiditis is generally associated with inflammation of the maxillary and ethmoidal sinuses.

When complications occur, patients also complain of facial pain, paraesthesia at the level of the V1, V2, V3 areas, sixth nerve palsy, ocular signs and symptoms (blurred vision, diplopia, eye tearing, proptosis, visual loss, ptosis) and mental status changes. These complications are due to the anatomical relationship of the sphenoid sinuses with nearby vital structures such as the middle cranial fossa, hypophysis, superior orbital fissure, optical canal and cavernous sinus, which contain the internal carotid artery and cranial nerves III to VI. Thus, when a sinus infection spreads to these structures, it may mimic other neurological disorders, thus delaying correct diagnosis and appropriate treatment.

### Maxillary sinuses

Embryologically, the maxillary sinus is first to appear, initially, as a depression of the nasal wall below the middle turbinate. The growth of the sinus is related to the development and eruption of the maxillary molar teeth, and does not reach full size until the eruption



**Figs. 7 & 8** i-CAT scan showing healing of the sinuses.

of the permanent dentition. The maxillary sinus, also known as the *antrum of Highmore*, is the largest of the paranasal sinuses. The roof of the maxillary sinus is formed by the alveolar part of the maxilla. The roots of the maxillary teeth, particularly the first two molars, often produce conical elevations in the floor of the sinus.

#### *Infection of the maxillary sinuses*

Maxillary sinusitis (inflammation of maxillary sinus) may be of dental origin. The dental causes of maxillary sinusitis include peri-apical infection, periodontal disease or perforation of the antral floor and antral mucosa at the time of dental extraction. Roots and foreign objects forced into the maxillary sinus at the time of operation may also be the causative factors of sinusitis. The non-dental source of maxillary sinusitis includes allergic conditions, chemical irritation or facial trauma (fracture involving a wall or walls of the maxillary sinus).

The patient may complain of a sense of fullness over the cheek, especially on bending forward. Other complaints with regard to maxillary sinusitis may include headache, facial pain and tenderness to pressure. The pain may also be referred to the premolar and molar teeth, which may be sensitive or painful to percussion.

#### *Relationship of the teeth to the maxillary sinus*

The close proximity of the three maxillary molar teeth to the floor of the maxillary sinus poses potentially serious problems. During removal of a molar tooth or root-canal treatment, root fracture may occur. If proper retrieval methods are not used, a piece of the root may be driven superiorly into the maxillary sinus, while in the case of endodontic treatment overextension or over-obturation of the material may drive material into the sinus. A communication may be created between the oral cavity and the maxillary

sinus as a result and an infection may occur. Because the superior alveolar nerves (branches of the maxillary nerve) supply both the maxillary teeth and the mucous membrane of the maxillary sinuses, inflammation of the mucosa of the sinus is frequently accompanied by a sensation of toothache in the molar teeth.

### Cavernous sinus

The cavernous sinus is located on each side of the *sella turcica* on the upper surface of the body of the sphenoid, which contains the sphenoid (air) sinus. The cavernous sinus consists of a venous plexus of extremely thin-walled veins that extends from the superior orbital fissure anteriorly to the apex of the petrous part of the temporal bone posteriorly. The venous channels in these sinuses communicate with each other through venous channels anterior and posterior to the stalk of the pituitary glands, the intercavernous sinuses and sometimes through the superior and inferior petrosal sinuses and emissary veins to the pterygoid plexuses.

Inside each cavernous sinus is the internal carotid artery with its small branches, surrounded by the carotid plexus of sympathetic nerve(s), and the abducent nerve (cranial nerve VI). The oculomotor (cranial nerve III) and trochlear (cranial nerve IV) nerves, plus two of the three divisions of the trigeminal nerve (cranial nerve V) are embedded in the lateral wall of the sinus. The artery, carrying warm blood from the body's core, traverses the sinus filled with cooler blood returning from the capillaries of the body's periphery, allowing for heat exchange to conserve energy or cool the arterial blood. Pulsations of the artery within the cavernous sinus are said to promote propulsion of venous blood from the sinus, as does gravity.<sup>2</sup>

Cavernous sinus thrombosis usually results from infections in the orbit, nasal sinuses and superior part of the face (the danger triangle). In persons with thrombophlebitis of the facial vein, pieces of an in-

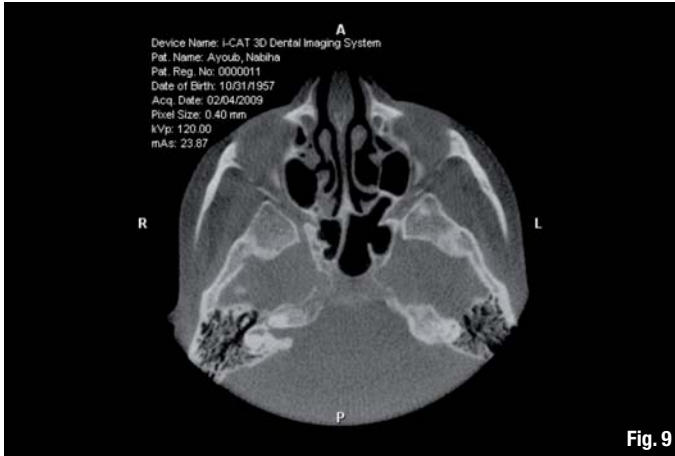

Fig. 9

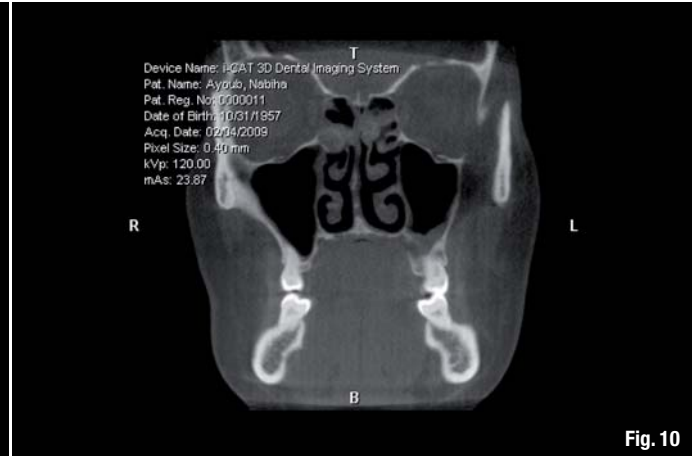


Fig. 10

ected thrombus may extend into the cavernous sinus producing thrombophlebitis of the cavernous sinus. The infection usually involves only one sinus initially but may spread to the opposite side through the intercavernous sinuses.

Thrombophlebitis of the cavernous sinus may affect the abducent nerve as it traverses the sinus and may also affect the nerves embedded within the lateral wall of the sinus. Septic thrombosis of the cavernous sinus often results in the development of acute meningitis and sometimes the life of the patient may be endangered.

### \_ Case report

After examining the patient, I called her otorhinolaryngologist and a neurologist to meet in the evening to discuss the case and we decided to put the patient on antibiotic therapy for three days prior to the beginning of the treatment. In the meantime, a conservative treatment was outlined, including root-canal treatment and tooth restoration.

Three days later, the patient returned to my office where I opened the tooth under strictest infection-control conditions. The canals were enlarged using Twisted Files (SybronEndo) to the size of 40, taper 0.04 in the apical part. No swelling was observed and obturation was done in the same session using RealSeal (SybronEndo), followed by composite coronal restoration placed immediately in order to stop any possible coronal leakage (Fig. 6).

The patient was checked regularly and an i-CAT was performed. I was very pleased to see the positive results and the healing of the greater part of the infection (Figs. 7 & 8). Most importantly, a complete healing of the cavernous sinus was observed (Fig. 9).

At the 18-month check-up, we saw the healing of the sinus above the molar.

### \_ Conclusion

A fatal error may have been made had I decided to extract the tooth. Under these circumstances, we would have potentially caused a flare-up, which could have resulted in severe consequences. It is important to underline that we should trust our root-canal treatment and use strict measures in bacteria and micro-organism control, starting from access cavity opening to the root-canal shaping, especially in the last 3 mm, where a size 40.04 Twisted File was used for apical enlargement. Obturation was done with RealSeal. This highly bio-compatible material is zinc and eugenol free, making aspergillosis and sinus inflammation due to paste extrusion beyond apex highly unlikely. The final results demonstrate a complete healing of the sinuses, of which the patient was very relieved to learn (Fig. 10).

The main message of this article is that we need to take our time in determining the correct diagnosis for each case that is presented to our office. We have to go beyond the oral sphere. The proper approach can ensure excellent results in a simple and straightforward treatment.

I would like to thank Phd Yulia Vorobyeva, interpreter and translator, for her help with this article.

*Editorial note: A list of references is available from the publisher.*

_contact	roots
<p><b>Dr Philippe Sleiman</b>                      Dubai Sky Clinic                      Burjuman Business Tower, Level 21                      Trade Center Street, Bur Dubai                      Dubai, UAE</p> <p>phil2sleiman@hotmail.com</p>	

Figs. 9 & 10\_ Healing of the sinuses.