

# Transparent teeth: A powerful educational tool

Author\_ Dr Sergio Rosler, Argentina

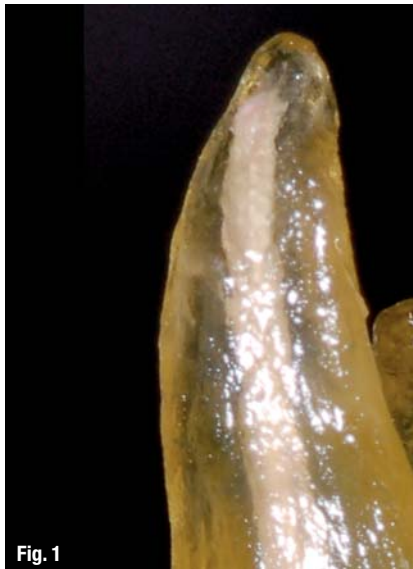

Fig. 1

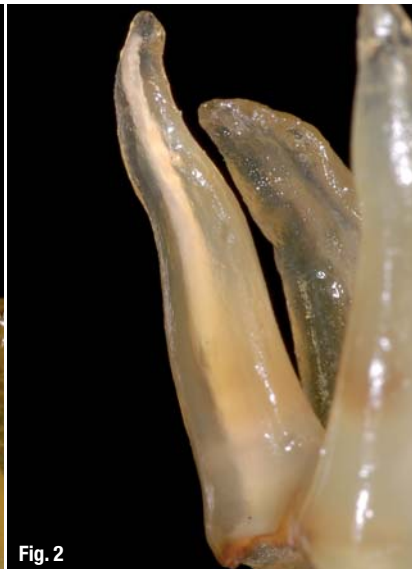

Fig. 2

Since the early days of dentistry, dentists have explored the morphology of the internal root anatomy. From the pre-X-ray period to the technology-driven present, the study and examination of the root-canal system has become an obsession for endodontists. Several methods such as radiographic<sup>1</sup> and histological examinations,<sup>2-3</sup> cross- and longitudinal sectioning,<sup>4</sup> and root-clearing techniques, to name a few, were widely used in the past. Today, different computerised tomography studies<sup>5</sup> and observations under dental operating microscopes<sup>6</sup> are performed to light up the dark confines of the dental pulp.

## The tooth-clearing technique

Over the last 100 years, the tooth-clearing technique was utilised in human dental pulp morphology studies, as it provides a 3-D view of the pulp cavity in relation to the exterior of the teeth and allows a

thorough examination of the pulp chambers and root canals.<sup>7-9</sup> It was also utilised in the study of apical leakage.<sup>10</sup> Today, the clearing technique remains useful only as a teaching and research tool, with little or no clinical applicability.<sup>11</sup>

In 1913, Hermann Prinz successfully cleared teeth using the protocol proposed by Spaltholz in 1906.<sup>12</sup> Okumura performed in-depth studies of the pulp anatomy and classified the canals according to their distribution and prevalence.<sup>13</sup> In order to simplify the canal system visually, he injected ink into the pulp cavity.<sup>13</sup> Samples can also be stained with Haematoxylin and Eosin, which are largely used to colour histological preparations. Compared with other procedures such as radiographic and histological examinations, the tooth-clearing technique has the following advantages:

- \_ retains the original form of the root;
- \_ enables the observation of minute details of the root-canal morphology;
- \_ is inexpensive;
- \_ samples can be conserved for a long time; and
- \_ is easy to perform.

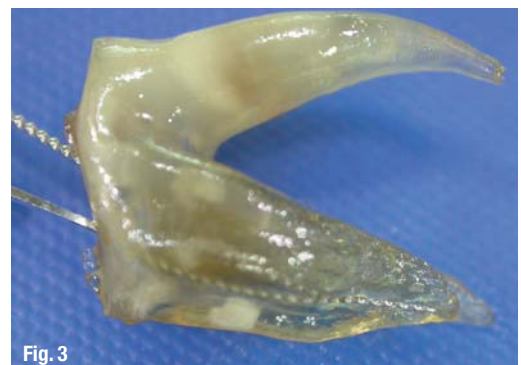


Fig. 3

The clearing process consists of three basic steps: demineralisation, dehydration and clearing of the root structure.<sup>14-15</sup>

#### Sample preparation

- \_ Store extracted teeth in 10% formal saline until use.<sup>11</sup>
- \_ Scale calculus and any remains of periodontal tissue.
- \_ Decoronate samples and negotiate canals with a #10 file (this will enhance acid penetration).
- \_ Store samples in 4.2% NaOCl solution (the organic tissue removal can be enhanced by placing the solution with the samples in the Ultrasonic Cleaner for 20 minutes).
- \_ Wash under running water and dry.
- \_ Indian ink can be drawn through the root-canal system by applying negative pressure to the apical end.

#### Demineralisation

- \_ Store samples in 5% nitric acid (HNO<sub>3</sub>) for three days.
- \_ Change solution every eight hours.
- \_ Manual or mechanical agitation promotes even demineralisation of the root.
- \_ Wash samples under running water for four hours<sup>16</sup> to clean.

#### Dehydration

- \_ Dehydrate samples by using ascending grades of alcohol: 60% ethanol for eight hours, 80% ethanol for four hours, and 96.6% ethanol for two hours.
- \_ Dry samples with paper towels.


#### Clearing

- \_ The sample should be placed in xylene for two hours to harden prior to placing the samples in methyl salicylate to render them transparent.<sup>16</sup> (This step is essential if samples are going to be used for practising instrumentation or obturation techniques.)
- \_ Store samples in methyl salicylate in order to preserve their transparency.

*Please note:* Always use proper protection when handling these dangerous solutions. Disposal of the used solutions should be done according to country regulations.

#### Educational tool

Successful root-canal treatment depends on adequate cleaning, shaping and filling of the root-canal system. However, in order to achieve this goal, it is imperative that the operator has a detailed knowledge of the root-canal morphology of each individual




tooth that is treated. Demineralised and cleared teeth may become a very valuable aid in the teaching of endodontic techniques. Hasselgren and Tronstad<sup>17</sup> used cleared teeth to teach and practise instrumentation and obturation procedures in a preclinical course at Lund University, Sweden. At the end of the course, the students were asked to give their opinions regarding the use of the transparent teeth in the learning process. The reaction was very favourable and encouraged the head of the department to extend the use of cleared teeth in following courses.<sup>17</sup>

Dipping the samples in xylene for two hours, as suggested by Robertson in 1980, prior to placing them in methyl salicylate will return dentine hardness to values slightly lower than those found in normal dentine.<sup>16</sup> This yields new possibilities for dentists eager to learn, who wish to practise new techniques, procedures and protocols, from rotary instrumentation with NiTi files to thermoplastic obturation with warm gutta-percha. Dentists are able to see what is actually happening with much greater detail, which is a significant improvement to working with a simulated canal in plastic blocks. Additionally, the tactile feeling experienced is very similar to the real clinical situation.

In summary, this simple and inexpensive technique will enable dentists to visualise the root-canal morphology in detail while allowing them to practise almost every endodontic procedure desired.

*Editorial note:* A list of references is available from the publisher.

_contact	roots
	
<p><b>Dr Sergio Rosler</b> graduated from the University of Buenos Aires, Argentina, in 1996, and had become a specialist in Endodontics by 2005. He has been a specialist in Oral Implantology since 2009 and works in private practice in Buenos Aires. He can be contacted at <a href="mailto:sarosler@hotmail.com.ar">sarosler@hotmail.com.ar</a>.</p>	