

Open-apex retreatment under the operating microscope

Author_ Dr Antonis Chaniotis, Greece

Owing to the lack of apical constriction, root-canal treatment of permanent teeth with open apices poses great challenges. When it comes to the endodontic treatment of such teeth, debridement and obturation of the canal space create a significant problem. The wide-open canal and thin dentinal walls are difficult to clean and shape, and it is even more difficult to obtain an acceptable conventional apical seal. For many years, apexification was the treatment of choice. The main goal of this procedure is to control the bacterial infection and establish a suitable environment for the induction of calcified tissue into the apical area. Calcium hydroxide—Ca(OH)₂—has remained the most acceptable intra-canal medication used for apexification.¹

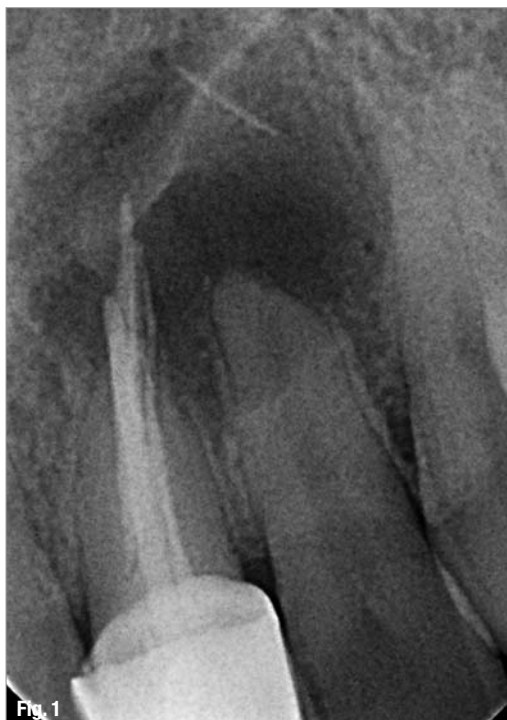However, this procedure is associated with a number of clinical problems, such as prolonged treatment time, unpredictability of apical closure, difficulty in patient follow-up and susceptibility to fracture. Moreover, long-term use of Ca(OH)₂ as an intra-canal medicament can weaken the thin dentinal walls of an immature root to a greater extent.²

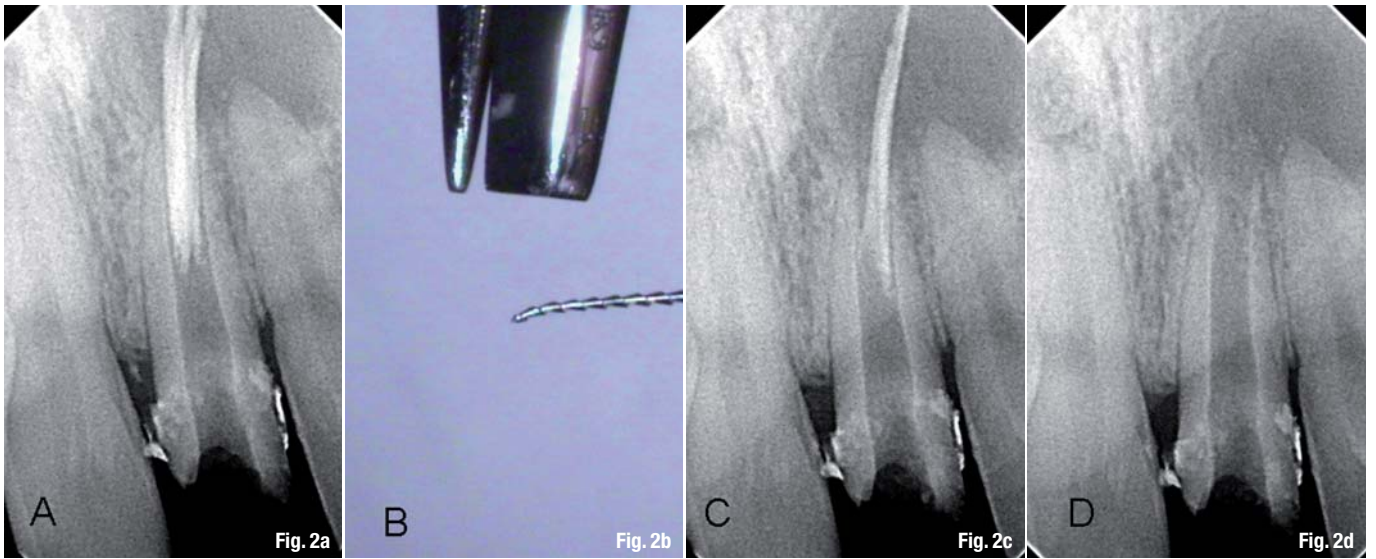
In order to override the disadvantages of the apexification technique, many alternatives have been suggested that aimed mainly at the development of a one-step procedure (one-visit apexification). Some of these potential alternatives were abandoned due to limitation in the availability and bio-compatibility of the materials.^{3,4}

Mineral trioxide aggregate (MTA) has been proposed as a material suitable for one-visit apexification. It combines bio-compatibility and bacteriostatic action with favourable sealing ability when used in contact with bone tissue.⁵⁻⁸ MTA offers an acceptable barrier at the end of root canals in teeth with necrotic pulps and open apices. This apical plug provides safe bio-compatible constriction that permits vertical condensation of warm gutta-percha in the remainder of the wide canal. For some, the intra-canal delivery technique is crucial for the adaptation and the quality of the apical MTA plug.⁹ Moreover, the use of an operating microscope may allow better control of the placement of the MTA apical plug.⁹

Following, the microscopic retreatment of an open-apex central incisor is described. Extruded through the open-apex, gutta-percha cones were retrieved successfully under magnification and completion of the treatment was achieved with the placement of an MTA apical barrier. Clinical tips for the procedure are provided and the predictability of the technique is considered.

Fig. 1 Pre-op radiograph of right maxillary central incisor.





_Case report

A 32-year-old male patient was referred to our practice for evaluation of the maxillary left central and lateral incisor. Medical history was non-contributory. There was a history of trauma at the age of 10. Clinical evaluation revealed no signs of infection in the area of the maxillary left incisor. Probing was within normal limits, and cold and electric vitality tests of the lateral incisor were positive. The central incisor was protected by a full coverage crown. Radiographic examination (Fig. 1) revealed a previously treated open-apex central incisor associated with a large radiolucent area at the end of the root-canal system of both the central and lateral incisors. Gutta-percha cones were extended far beyond the open apex inside the lumen of the peri-radicular lesion. It was evident that the previous dentist attempted to obturate the wide canal using the wrong technique and without previous apexification. The result was the extrusion of the obturation material far beyond the apex. The patient was informed of the possibility of performing surgery to resolve the problem following the orthograde attempt to retreat the wide-open canal.

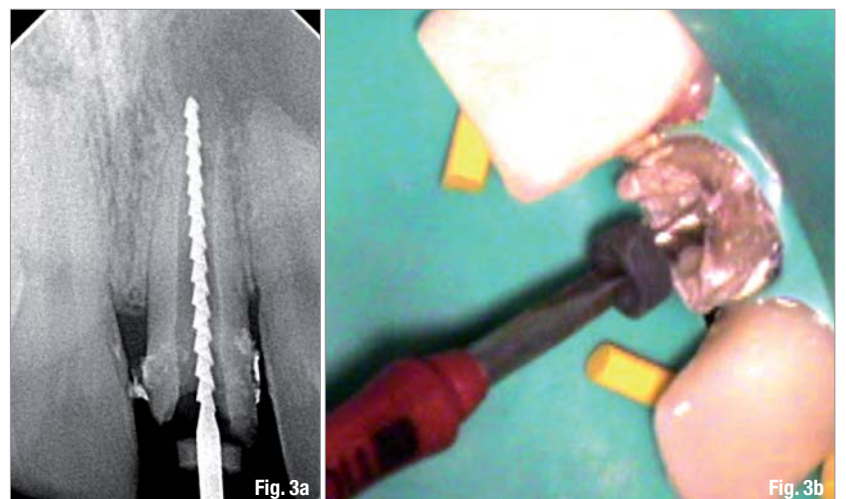
After crown removal, a prefabricated post was revealed. The post was easily removed by ultrasonic vibration, and access was achieved. Retrieval of the overextended gutta-percha cones was achieved with ISO size 45 Hedstrom Files (DENTSPLY Maillefer). No solvents or Gates-Glidden burs were used in order to avoid cutting or softening of the overextended material. With the help of a microscope (Global Surgical), an ISO size 45 file was inserted between the dentinal wall and the under-condensed material. Withdrawal of the Hedstrom File in one stroke retrieved the majority of the gutta-percha cones from the wide canal, leaving only the overextended ones (Fig. 2a). For the

retrieval of the extruded cones, the file was bent at the tip using the Endo-Bender (SybronEndo; Fig. 2b). Care was taken not to push the remaining cones out of the open apex, and the whole procedure was accomplished under x16 magnification. Figures 2c and d show the radiographs of the successful procedure.

Length was radiographically assessed using an ISO size 110 Hedstrom File (Fig. 3). After retrieval of the gutta-percha cones, the wide-open canal was cleaned using ultrasonic irrigation with 4.8% NaOCl (Irrisafe, Satelec). The canal was then dried and filled with Ca(OH)₂ (UltraCal, Ultradent). One week later, access was regained and Ca(OH)₂ was removed by ultrasonic irrigation with 4.8% NaOCl. A 17% solution of EDTA (SmearClear, SybronEndo) was left in the canal for one minute, and the final rinse was achieved using syringe irrigation with 4.8% NaOCl.

The canal was dried and an absorbable gelatine haemostatic sponge (SPONGOSTAN, Ethicon) was cut to fit the width of the canal (Fig. 4a). The sponge was

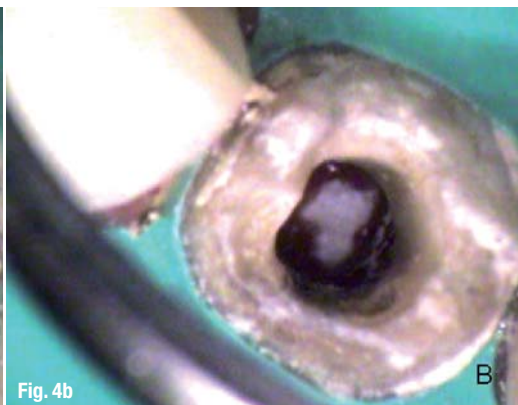
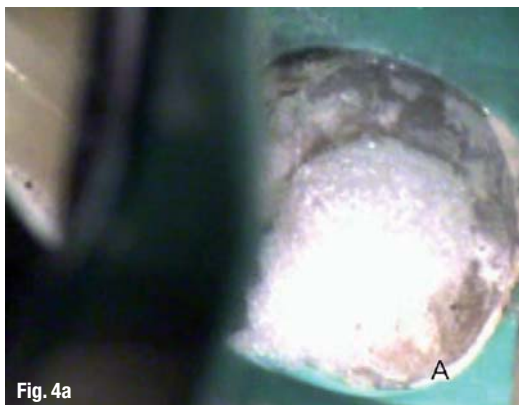Figs. 2a–d Radiographic assessment of gutta-percha cones retrieval (a, c & d), Hedstrom tip modification using Endo-Bender (b).



Figs. 3a & b Length determination radiograph.

Fig. 4a_Gelatine sponge cut to fit the canal.

Fig. 4b_Gelatine sponge in place.



guided through the wide canal to the open apex with pre-fitted pluggers, creating a platform for the safe adaptation of the MTA plug (Fig. 4b).

White MTA (DENTSPLY Maillefer) was mixed with sterile water until a thick consistency was achieved. MTA material was carried inside the root canal with an appropriate amalgam carrier used as MTA carrier (Fig. 5a). Pre-fitted pluggers were used with slight apical pressure to push the MTA material to the apex until the material was adapted to the apical anatomy of the open apex that was plugged with the absorbable sponge (Fig. 5b). Adaptation of the material was assessed visually under x16 magnification and radiographically until the plug filled the apical 5 mm of the wide canal (Figs. 6a & b). After the completion of the procedure, a wet cotton pellet was placed in contact with the MTA, and temporarisation was achieved with Cavit G (3M ESPE). The patient was referred back to his general practitioner for appropriate restoration and came back to our practice for a follow-up examination after six months (Figs. 6c & d).

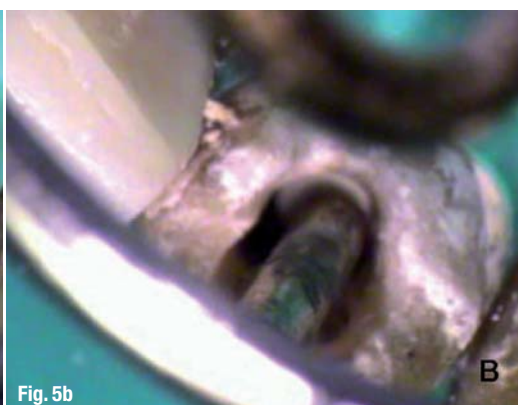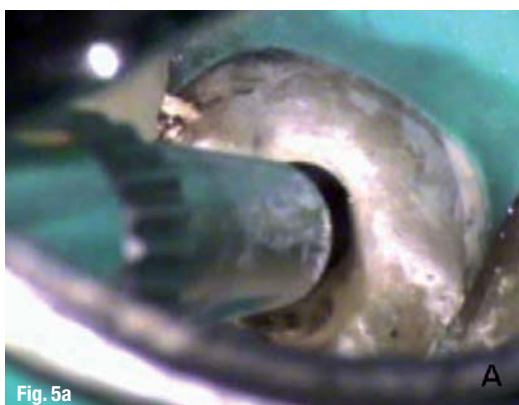Discussion

A major problem in performing endodontics in immature teeth with necrotic pulp and wide-open apices is obtaining an optimal seal of the root-canal system. For more than 40 years, such cases were approached clinically with apexification.¹ The initial aim

of the procedure was to limit the bacterial infection and create an environment conducive to the production of a mineralised tissue barrier or root-end formation at the immature root apex. Ca(OH)₂ was commonly used for this purpose. Despite the popularity of this technique, inherent disadvantages exist. Variability of treatment time, unpredictability of apical closure, difficulty in patient follow-up, susceptibility to fracture and reinfection are the main disadvantages of the procedure. All these disadvantages lead us to continue the search for procedures and materials that may allow for continued apical closure in teeth with immature apices. Although research on the revascularisation procedures of the necrotic open apex is promising,¹⁰ the MTA apical plug technique is considered a good alternative treatment procedure.

Its physical and chemical properties make MTA a good potential apical barrier, including its sealing and antimicrobial ability, marginal adaptation and biocompatibility.⁶ However, the material manipulation and delivery technique of the procedure pose great clinical challenges. The aim of the present article was to describe the MTA apical plug technique systematically, and to provide tips and hints for the successful management of challenging open-apex retreatment cases. Although extruded beyond the apex materials, which may indicate surgical treatment planning, an orthograde retreatment procedure was followed in the present case. Extruded materials were success-

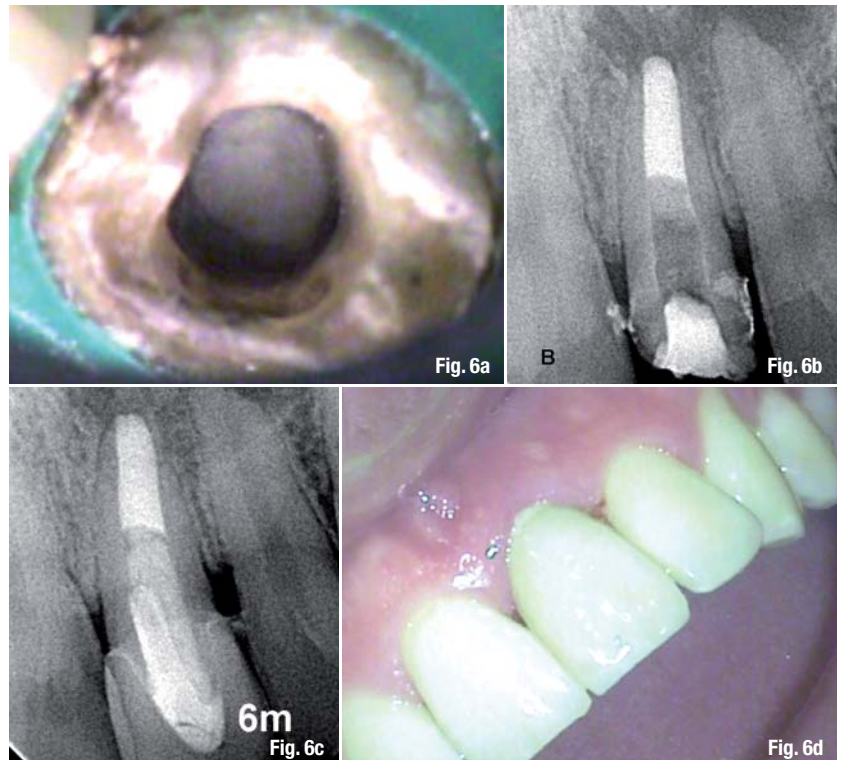
Figs. 5a & b_MTA carried inside the canal (a), and condensed to length (b).



fully retrieved through the wide-open apex with the indispensable aid of a surgical microscope. Modified Hedstrom Files proved very useful for the purpose. Cleaning of the wide-open canal was enhanced by ultrasonic irrigation, while $\text{Ca}(\text{OH})_2$ was placed as an intra-canal medicament. The effectiveness of $\text{Ca}(\text{OH})_2$ as an antimicrobial agent is well documented,¹¹ although its use is still controversial. Hachmeister *et al.*¹² demonstrated that the remains of $\text{Ca}(\text{OH})_2$ on canal walls has no significant effect on MTA leakage or displacement resistance. On the other hand, it was suggested by Porkaew *et al.*¹³ that remnants of $\text{Ca}(\text{OH})_2$ on the dentinal walls may interfere with the apical seal produced. However, in a recent paper by Ham *et al.*,¹⁴ it was suggested that the combination of MTA and $\text{Ca}(\text{OH})_2$ in apexification procedures may result in more favourable regeneration of the periapical tissues. In the present case, $\text{Ca}(\text{OH})_2$ was removed as effectively as possible from the dentinal walls using ultrasonic irrigation with 4.8% NaOCl and 17% EDTA for one minute.

For proper and safe adaptation of the MTA apical barrier, an absorbable gelatine sponge was condensed at the apex, creating a scaffold against which the MTA material could be seated. SPONGOSTAN is considered to be fully absorbed within four to six weeks (instruction for the material use), while in the orthopaedic literature it is referred to as a possible 3-D scaffold for a chondrocyte matrix.¹⁵ Concerns have been raised about delayed healing patterns and painful reaction to SPONGOSTAN when packed to sockets after surgical removal of third molars.¹⁶ In the case of an open apex and MTA plugs combined with the use of absorbable gelatine sponges, I have never encountered an experience of painful post-operative reaction or healing impairment attributed to the use of the gelatine sponge. Further research is needed on the subject. For the insertion of the material inside the wide canal, a small amalgam carrier was used in conjunction with appropriate Schilder pluggers under magnification. Concerns have been raised about the MTA placement technique. Lawley *et al.*¹⁷ found that ultrasonic condensation led to significantly less bacterial penetration compared to hand condensation, after 45 days but not in the 90-day interval. On the contrary, Aminoshariae *et al.*⁹ found better adaptation and less radiographic voids with hand condensation than with ultrasonics. More research is required to find the ideal placement technique.

Appropriate adaptation of the material was assessed visually under microscopic inspection and radiologically. Concerns have been raised about the appropriate MTA plug thickness. It has been postulated by some authors that the thickness of the apical plug may influence its leakage patterns. De Leimburg *et al.*¹⁸ reported in a recent paper that orthograde use



of MTA provided an adequate seal against bacterial infiltration, regardless of the thickness of the apical plug. Hachmeister *et al.*¹² underlined in their paper that the thickness of the apical plug may have a significant impact only on displacement resistance. In the present case, we obtained a sufficient apical plug of 5 mm, leaving 12 mm space for resin post and core restoration.

Figs. 6a & b_Post-op radiograph and microscopic appearance of the MTA plug (x16, Global Entrée Plus). **Figs. 6c & d**_Gutta-fishing at 6 months.

Orthograde delivery of MTA in open apices is considered a very sensitive technique and the clinician should practise his/her skills before going *in vivo*. This case presentation was designed to guide the clinician step-by-step to the successful management of challenging open-apex cases.

Editorial note: A list of references is available from the publisher.

_about the author

roots



Dr Antonis Chaniotis graduated from the University of Athens Dental School in 1998. He completed a three-year postgraduate programme in Endodontics at the University of Athens Dental School in 2003. He is a clinical instructor in the undergraduate and postgraduate programmes in the Department of Endodontics of the University of Athens Dental School. Since 2003, he has practised in a private practice in Athens that specialises in Endodontics. Dr Chaniotis can be contacted at antch@otenet.gr or via his website www.endotreatment.gr.