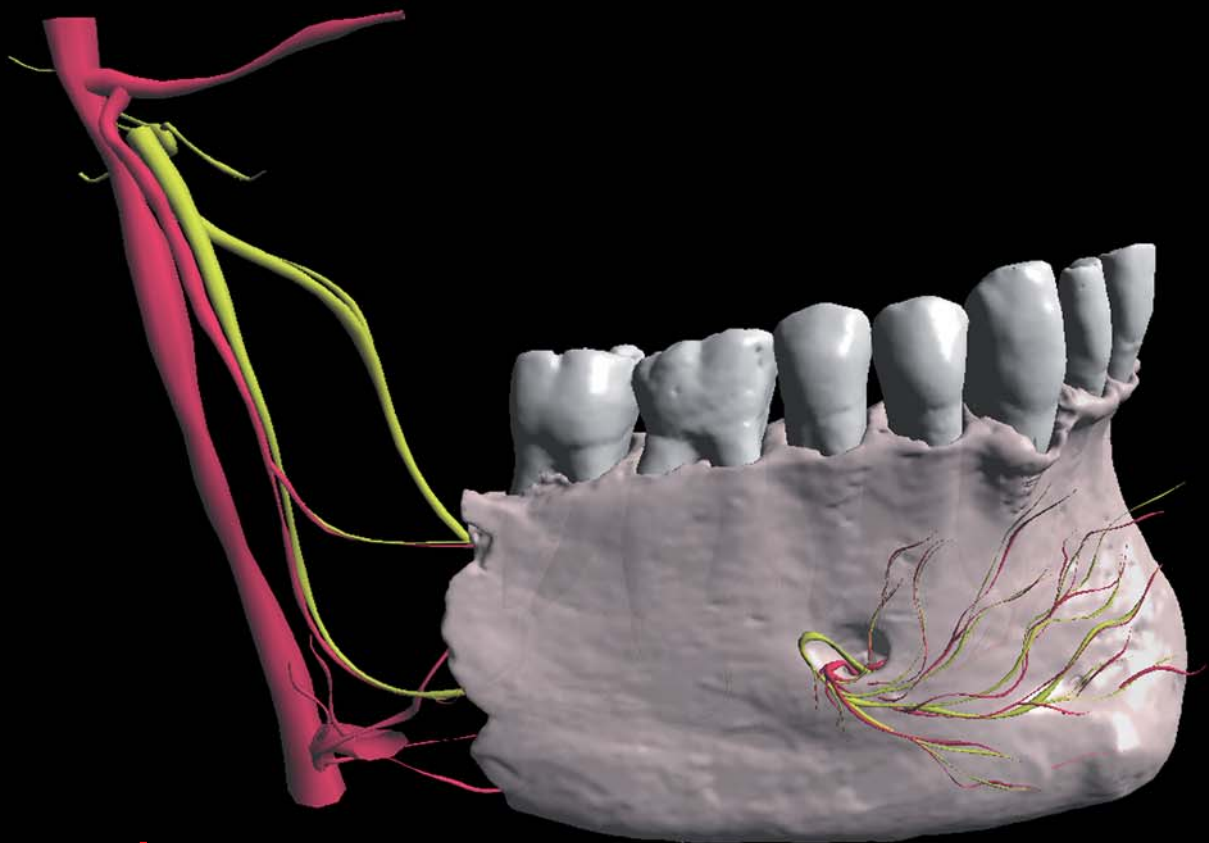


# roots

international magazine of endodontology

4<sup>2010</sup>



| **case report**

Open-apex retreatment  
under the operating microscope

| **special**

Endodontic success:  
The pursuit of our potential

| **feature**

An interview with MICRO-MEGA





MICRO-MEGA® presents  
the **MM-men**

# THEY ARE COMING

THEY HAVE THE SOLUTION  
FOR EACH SITUATION...



## MEGA+

Really dynamic, she accurately chooses the best solutions among her wide complementary powers, thus reinforcing the action of her team mates.



## REVOS

Very strong and resistant, nimble, gently efficient, he is always there when needed.



## CATH

She is clever and extremely precise. The catheterism MMC handfiles hold no secret for her!



## ENDOFLARE

Short and determined, he is always ready to go ahead in order to eliminate the obstacles and makes the job of the team easier.

### The MICRO-MEGA® + Your range of essentials!

- APEX Pointer™+: High precision electronic apex locator.
- MM-EDTA CREAM: EDTA in cream.
- MM-Paste: Calcium hydroxid paste.
- MM-Seal: sealer for root canal filling.
- MM-GP Points: Gutta percha.

### Revo-S™ Revolutionize your Endo with only 3 instruments!



- Its asymmetrical cross section initiates a snake-like movement of the instrument inside the canal!
- Less stress on the instrument: less risk of breakage.
- Better debris elimination: more efficient cleaning.

### MMC FILES Totally safe manual exploration!

- First indispensable step to any successful endodontic treatment.
- Extreme precision and simplicity.
- For use in combination with apex locators (Apex Pointer™+).

### ENDOFLARE® No more constraints!

- Coronal flaring.
- Elimination of the coronal strains.
- Easier insertion of preparation instruments.



[www.revo-s.com](http://www.revo-s.com)

**TO BE CONTINUED...**

MICRO-MEGA®

5-12, rue du Tunnel - F-25006 BESANÇON cedex  
Tél. : +33 (0)3 81 54 42 34 - Fax : +33 (0)3 81 54 42 39  
export@micro-mega.com - www.micro-mega.com



W e i n v e n t ,

y o u s u c c e e d !

# Dear Reader,

**Endodontics is fascinating.** I will put aside the romantic view that endodontics is an art and assume that it is an ever-growing science that requires a great deal of study and training to reach a high-level clinical performance. I dare say that no other clinical discipline in dentistry requires such a vast knowledge of and integration with so many other clinical and basic disciplines.

As a clinical health-care discipline, endodontics is concerned with the promotion of oral health and primarily deals with prevention and treatment of apical periodontitis. Every patient who enters our office is confident that we are well prepared to apply the most effective treatment protocol available to reach that goal. Unfortunately, this may not be true. Epidemiological studies reveal a very low success rate (40 to 60%) of endodontic treatment in the general population. The majority of failed (or diseased) teeth are poorly treated. The need for a complex background of knowledge and the technically demanding nature of endodontic procedures may help explain such an overall poor performance. However, the potential for success is very high (85 to 95%), as demonstrated by well-controlled, university-based studies. This rate is amongst the highest for any treatment in any health-care discipline. This keeps our hopes high. The challenge for the specialty now is to transfer this high success rate to the general population.

One of the possible solutions is to encourage the development of treatment procedures or protocols that are user-friendly and effective in order to allow more clinicians to be able to offer optimal outcomes. This would make endodontics more 'democratic' in terms of predictability. In a thought-provoking paper by Morgan and Alexander published in **roots** 2/10, the authors discuss the issue of applying scientific knowledge to improve clinical practice. Dr Irving Naidorf had discussed this 40 years ago and it is still significant today. Integrating scientific knowledge and clinical practice is certainly required to maximise the success rate, but this approach might well also be used to develop alternatives to improve the quality (and consequently the outcome) of treatment in the overall population.

In spite of the huge amount of scientific information about the aetiology and pathogenesis of apical periodontitis generated over the last three decades, this knowledge has not been translated into a significant improvement in endodontic treatment outcomes. This is because clinical technology and treatment protocols have not been devised or even slightly modified on the basis of this booming biological knowledge. Science has provided a great deal of information on the nature of the problem, so the time has come for this knowledge to be used by endodontic scientists and clinicians to find a better, affordable and less technically demanding approach that can still predictably treat our patients. In an ideal world, there should be no dichotomy or dispute between research and clinical practice. In a clinical discipline like endodontics, research should be mostly intended to find and test ways for the best treatment and to improve the quality of life, while clinicians should use this scientific knowledge to improve their practices. Denying the importance and advances of the other is arrogant, nonsense, selfish and counterproductive.

In contrast to the many Doomsday prophets, we can foresee a bright future for endodontics. It's up to us.

Yours faithfully,

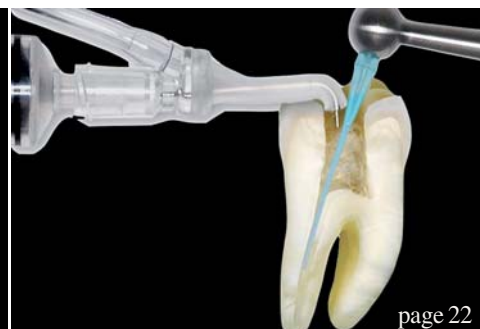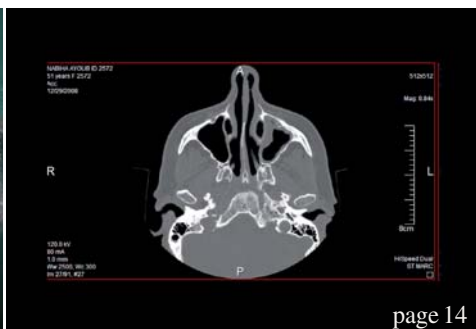
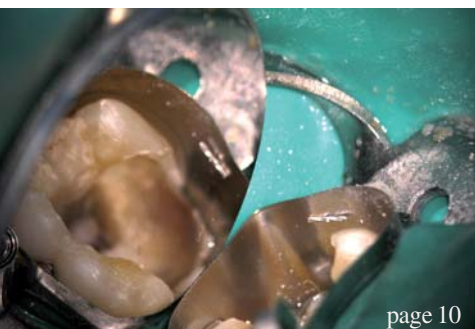


Prof José F. Siqueira Jr.  
Professor and Chairperson, Department of Endodontics, Estácio de Sá University  
Rio de Janeiro, RJ, Brazil



Prof José F. Siqueira Jr.





**| editorial**

- 03 **Dear Reader**  
| Prof José F. Siqueira Jr., Guest Editor

**| case report**

- 06 **Open-apex retreatment** under the operating microscope  
| Dr Antonis Chaniotis
- 10 **Treating a calcified mandibular molar: A modern-day protocol**  
| Dr Rafaël Michiels
- 14 **A cavernous sinus infection: A root-canal case**  
| Dr Philippe Sleiman

**| feature**

- 18 An interview with **Audrey Stefani, Dr Stephan Gruner & Dr Khaled A. Balto**

**| special**

- 22 **Endodontic success: The pursuit of our potential**  
| Dr Wyatt D. Simons
- 30 **Transparent teeth: A powerful educational tool**  
| Dr Sergio Rosler

**| research**

- 32 **CBCT applications in dental practice: A literature review**  
| Dr Mohammed A. Alshehri *et al.*

**| industry news**

- 40 **The RECIPROC system**  
| VDW

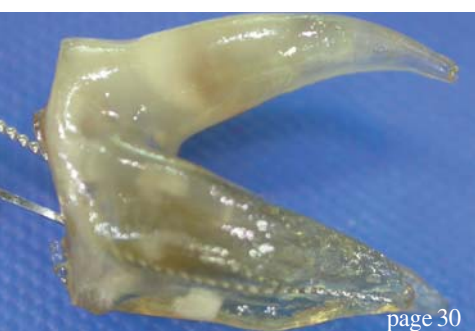**| meetings**

- 42 **Greece inspired us once again**  
| Dr Antonis Chaniotis
- 44 **A meeting of minds—Seeing is believing**  
| Dr David English
- 46 **Endodontics: A central theme of IDS 2011**
- 48 **International Events**

**| about the publisher**

- 49 | submission guidelines
- 50 | imprint

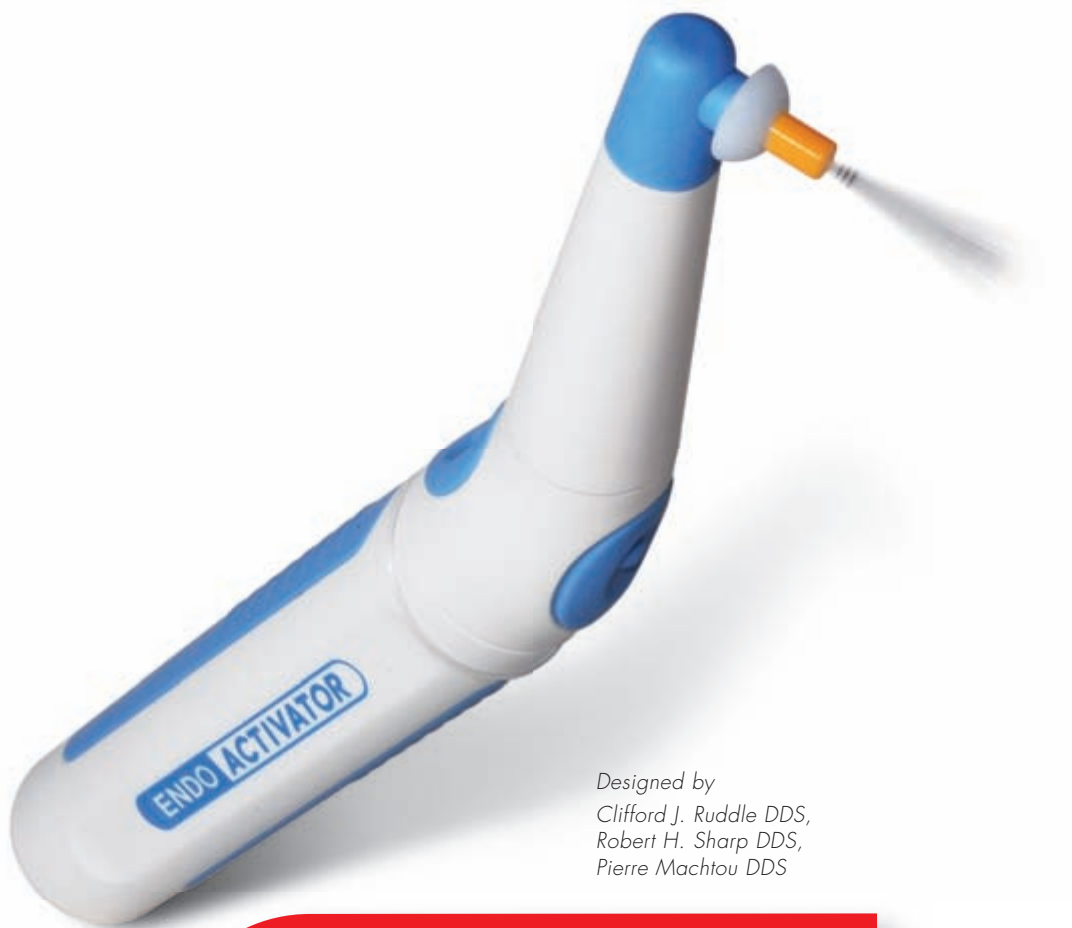Cover image courtesy of Brown & Herbranson Imaging, [www.eHuman.com](http://www.eHuman.com).





# ENDO ACTIVATOR<sup>®</sup>

AN EASY TO USE & SAFE SOLUTION  
TO ACTIVATE YOUR IRRIGATION



*Designed by  
Clifford J. Ruddle DDS,  
Robert H. Sharp DDS,  
Pierre Machtou DDS*

## MULTIPLE BENEFITS

### SAFE

- Strong, flexible medical grade polymer tips
- Single patient use
- Uncoated & Non Cutting tips

### EFFECTIVE

- Creates fluid hydrodynamics
- Improves debridement and the disruption of the smear layer and biofilm

### SIMPLE

- Very simple clinical technique
- Intuitive Device
- Ideal in practice when portability is required

**DENTSPLY**  
**MAILLEFER**

[www.dentsplymaillefer.com](http://www.dentsplymaillefer.com)

# Open-apex retreatment under the operating microscope

Author\_ Dr Antonis Chaniotis, Greece

Owing to the lack of apical constriction, root-canal treatment of permanent teeth with open apices poses great challenges. When it comes to the endodontic treatment of such teeth, debridement and obturation of the canal space create a significant problem. The wide-open canal and thin dentinal walls are difficult to clean and shape, and it is even more difficult to obtain an acceptable conventional apical seal. For many years, apexification was the treatment of choice. The main goal of this procedure is to control the bacterial infection and establish a suitable environment for the induction of calcified tissue into the apical area. Calcium hydroxide—Ca(OH)<sub>2</sub>—has remained the most acceptable intra-canal medicament used for apexification.<sup>1</sup>

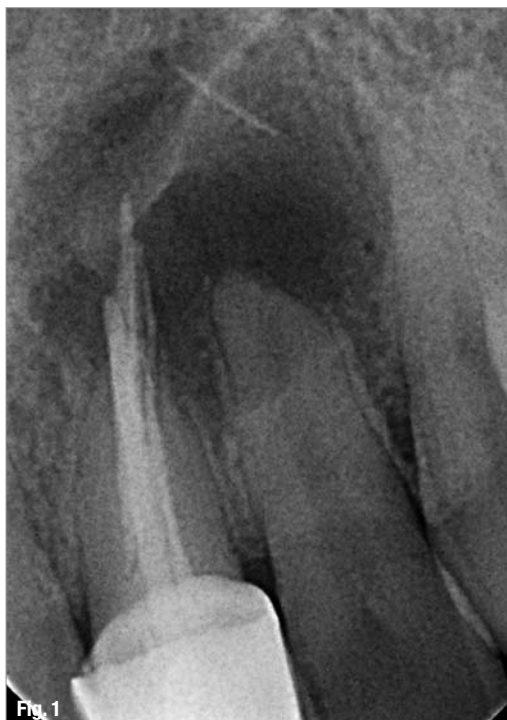However, this procedure is associated with a number of clinical problems, such as prolonged treatment time, unpredictability of apical closure, difficulty in patient follow-up and susceptibility to fracture. Moreover, long-term use of Ca(OH)<sub>2</sub> as an intra-canal medicament can weaken the thin dentinal walls of an immature root to a greater extent.<sup>2</sup>

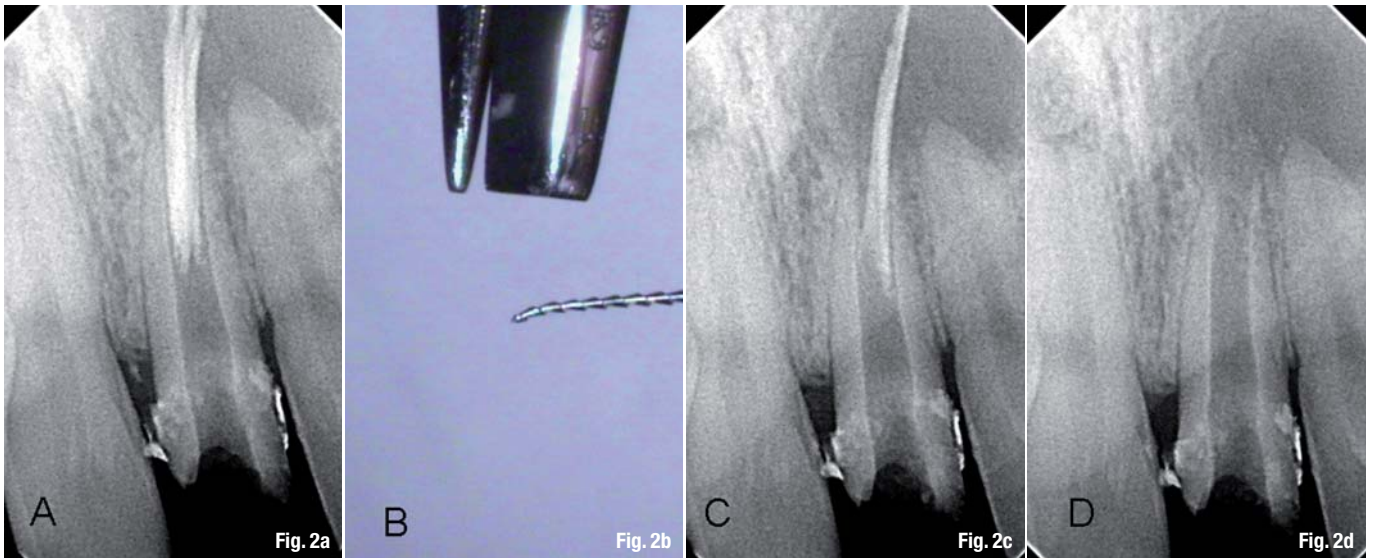
In order to override the disadvantages of the apexification technique, many alternatives have been suggested that aimed mainly at the development of a one-step procedure (one-visit apexification). Some of these potential alternatives were abandoned due to limitation in the availability and bio-compatibility of the materials.<sup>3,4</sup>

Mineral trioxide aggregate (MTA) has been proposed as a material suitable for one-visit apexification. It combines bio-compatibility and bacteriostatic action with favourable sealing ability when used in contact with bone tissue.<sup>5-8</sup> MTA offers an acceptable barrier at the end of root canals in teeth with necrotic pulps and open apices. This apical plug provides safe bio-compatible constriction that permits vertical condensation of warm gutta-percha in the remainder of the wide canal. For some, the intra-canal delivery technique is crucial for the adaptation and the quality of the apical MTA plug.<sup>9</sup> Moreover, the use of an operating microscope may allow better control of the placement of the MTA apical plug.<sup>9</sup>

Following, the microscopic retreatment of an open-apex central incisor is described. Extruded through the open-apex, gutta-percha cones were retrieved successfully under magnification and completion of the treatment was achieved with the placement of an MTA apical barrier. Clinical tips for the procedure are provided and the predictability of the technique is considered.

Fig. 1 Pre-op radiograph of right maxillary central incisor.





**\_Case report**

A 32-year-old male patient was referred to our practice for evaluation of the maxillary left central and lateral incisor. Medical history was non-contributory. There was a history of trauma at the age of 10. Clinical evaluation revealed no signs of infection in the area of the maxillary left incisor. Probing was within normal limits, and cold and electric vitality tests of the lateral incisor were positive. The central incisor was protected by a full coverage crown. Radiographic examination (Fig. 1) revealed a previously treated open-apex central incisor associated with a large radiolucent area at the end of the root-canal system of both the central and lateral incisors. Gutta-percha cones were extended far beyond the open apex inside the lumen of the peri-radicular lesion. It was evident that the previous dentist attempted to obturate the wide canal using the wrong technique and without previous apexification. The result was the extrusion of the obturation material far beyond the apex. The patient was informed of the possibility of performing surgery to resolve the problem following the orthograde attempt to retreat the wide-open canal.

After crown removal, a prefabricated post was revealed. The post was easily removed by ultrasonic vibration, and access was achieved. Retrieval of the overextended gutta-percha cones was achieved with ISO size 45 Hedstrom Files (DENTSPLY Maillefer). No solvents or Gates-Glidden burs were used in order to avoid cutting or softening of the overextended material. With the help of a microscope (Global Surgical), an ISO size 45 file was inserted between the dentinal wall and the under-condensed material. Withdrawal of the Hedstrom File in one stroke retrieved the majority of the gutta-percha cones from the wide canal, leaving only the overextended ones (Fig. 2a). For the

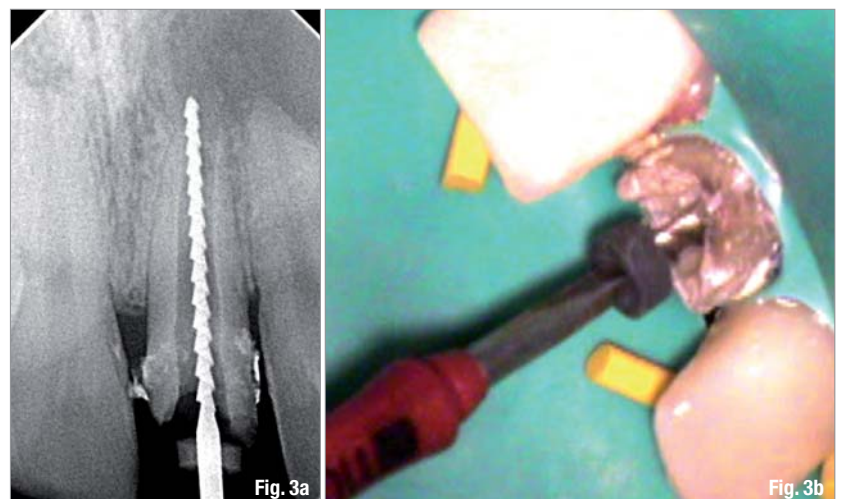
retrieval of the extruded cones, the file was bent at the tip using the Endo-Bender (SybronEndo; Fig. 2b). Care was taken not to push the remaining cones out of the open apex, and the whole procedure was accomplished under x16 magnification. Figures 2c and d show the radiographs of the successful procedure.

Length was radiographically assessed using an ISO size 110 Hedstrom File (Fig. 3). After retrieval of the gutta-percha cones, the wide-open canal was cleaned using ultrasonic irrigation with 4.8% NaOCl (Irrisafe, Satelec). The canal was then dried and filled with Ca(OH)<sub>2</sub> (UltraCal, Ultradent). One week later, access was regained and Ca(OH)<sub>2</sub> was removed by ultrasonic irrigation with 4.8% NaOCl. A 17% solution of EDTA (SmearClear, SybronEndo) was left in the canal for one minute, and the final rinse was achieved using syringe irrigation with 4.8% NaOCl.

The canal was dried and an absorbable gelatine haemostatic sponge (SPONGOSTAN, Ethicon) was cut to fit the width of the canal (Fig. 4a). The sponge was

**Figs. 2a–d**\_Radiographic assessment of gutta-percha cones retrieval (a, c & d), Hedstrom tip modification using Endo-Bender (b).

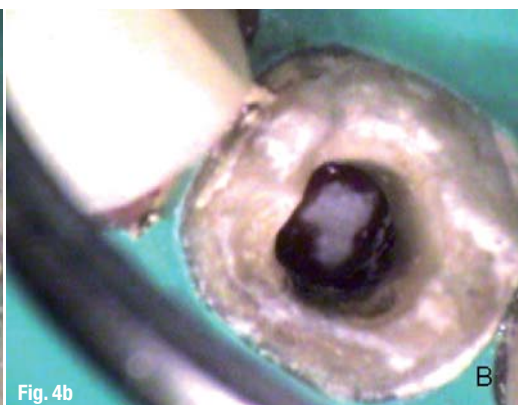
**Figs. 3a & b**\_Length determination radiograph.





**Fig. 4a**\_ Gelatine sponge cut to fit the canal.

**Fig. 4b**\_ Gelatine sponge in place.



guided through the wide canal to the open apex with pre-fitted pluggers, creating a platform for the safe adaptation of the MTA plug (Fig. 4b).

White MTA (DENTSPLY Maillefer) was mixed with sterile water until a thick consistency was achieved. MTA material was carried inside the root canal with an appropriate amalgam carrier used as MTA carrier (Fig. 5a). Pre-fitted pluggers were used with slight apical pressure to push the MTA material to the apex until the material was adapted to the apical anatomy of the open apex that was plugged with the absorbable sponge (Fig. 5b). Adaptation of the material was assessed visually under x16 magnification and radiographically until the plug filled the apical 5 mm of the wide canal (Figs. 6a & b). After the completion of the procedure, a wet cotton pellet was placed in contact with the MTA, and temporarisation was achieved with Cavit G (3M ESPE). The patient was referred back to his general practitioner for appropriate restoration and came back to our practice for a follow-up examination after six months (Figs. 6c & d).

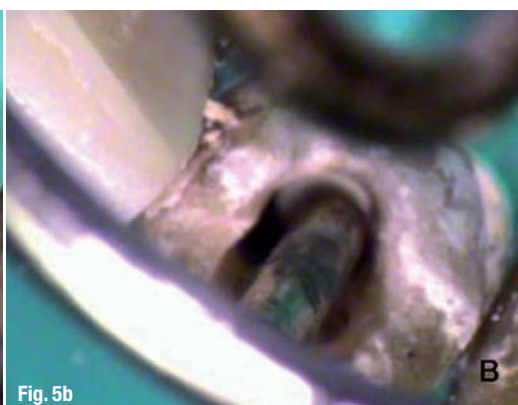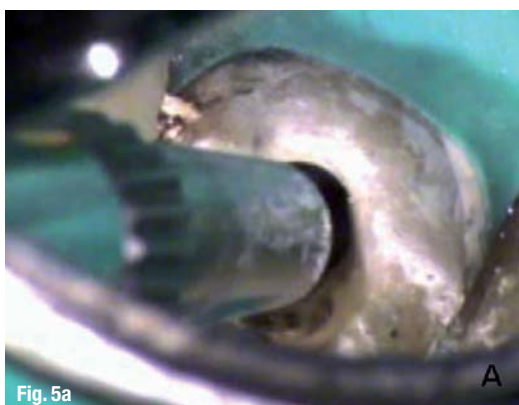### Discussion

A major problem in performing endodontics in immature teeth with necrotic pulp and wide-open apices is obtaining an optimal seal of the root-canal system. For more than 40 years, such cases were approached clinically with apexification.<sup>1</sup> The initial aim

of the procedure was to limit the bacterial infection and create an environment conducive to the production of a mineralised tissue barrier or root-end formation at the immature root apex. Ca(OH)<sub>2</sub> was commonly used for this purpose. Despite the popularity of this technique, inherent disadvantages exist. Variability of treatment time, unpredictability of apical closure, difficulty in patient follow-up, susceptibility to fracture and reinfection are the main disadvantages of the procedure. All these disadvantages lead us to continue the search for procedures and materials that may allow for continued apical closure in teeth with immature apices. Although research on the revascularisation procedures of the necrotic open apex is promising,<sup>10</sup> the MTA apical plug technique is considered a good alternative treatment procedure.

Its physical and chemical properties make MTA a good potential apical barrier, including its sealing and antimicrobial ability, marginal adaptation and biocompatibility.<sup>6</sup> However, the material manipulation and delivery technique of the procedure pose great clinical challenges. The aim of the present article was to describe the MTA apical plug technique systematically, and to provide tips and hints for the successful management of challenging open-apex retreatment cases. Although extruded beyond the apex materials, which may indicate surgical treatment planning, an orthograde retreatment procedure was followed in the present case. Extruded materials were success-

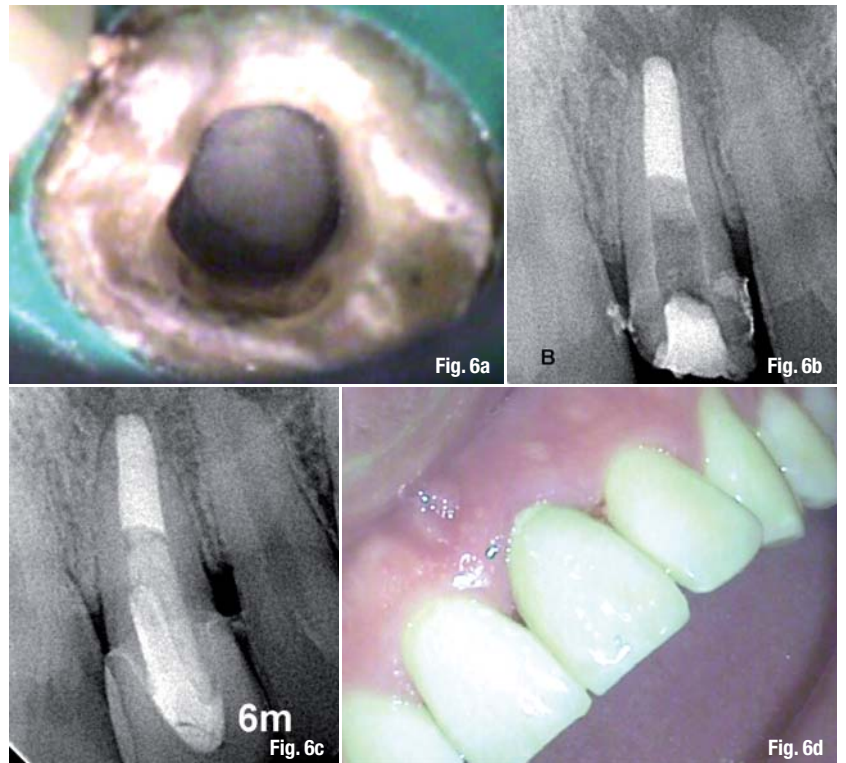
**Figs. 5a & b**\_ MTA carried inside the canal (a), and condensed to length (b).



fully retrieved through the wide-open apex with the indispensable aid of a surgical microscope. Modified Hedstrom Files proved very useful for the purpose. Cleaning of the wide-open canal was enhanced by ultrasonic irrigation, while  $\text{Ca}(\text{OH})_2$  was placed as an intra-canal medicament. The effectiveness of  $\text{Ca}(\text{OH})_2$  as an antimicrobial agent is well documented,<sup>11</sup> although its use is still controversial. Hachmeister *et al.*<sup>12</sup> demonstrated that the remains of  $\text{Ca}(\text{OH})_2$  on canal walls has no significant effect on MTA leakage or displacement resistance. On the other hand, it was suggested by Porkaew *et al.*<sup>13</sup> that remnants of  $\text{Ca}(\text{OH})_2$  on the dentinal walls may interfere with the apical seal produced. However, in a recent paper by Ham *et al.*,<sup>14</sup> it was suggested that the combination of MTA and  $\text{Ca}(\text{OH})_2$  in apexification procedures may result in more favourable regeneration of the peri-apical tissues. In the present case,  $\text{Ca}(\text{OH})_2$  was removed as effectively as possible from the dentinal walls using ultrasonic irrigation with 4.8% NaOCl and 17% EDTA for one minute.

For proper and safe adaptation of the MTA apical barrier, an absorbable gelatine sponge was condensed at the apex, creating a scaffold against which the MTA material could be seated. SPONGOSTAN is considered to be fully absorbed within four to six weeks (instruction for the material use), while in the orthopaedic literature it is referred to as a possible 3-D scaffold for a chondrocyte matrix.<sup>15</sup> Concerns have been raised about delayed healing patterns and painful reaction to SPONGOSTAN when packed to sockets after surgical removal of third molars.<sup>16</sup> In the case of an open apex and MTA plugs combined with the use of absorbable gelatine sponges, I have never encountered an experience of painful post-operative reaction or healing impairment attributed to the use of the gelatine sponge. Further research is needed on the subject. For the insertion of the material inside the wide canal, a small amalgam carrier was used in conjunction with appropriate Schilder pluggers under magnification. Concerns have been raised about the MTA placement technique. Lawley *et al.*<sup>17</sup> found that ultrasonic condensation led to significantly less bacterial penetration compared to hand condensation, after 45 days but not in the 90-day interval. On the contrary, Aminoshariae *et al.*<sup>9</sup> found better adaptation and less radiographic voids with hand condensation than with ultrasonics. More research is required to find the ideal placement technique.

Appropriate adaptation of the material was assessed visually under microscopic inspection and radiologically. Concerns have been raised about the appropriate MTA plug thickness. It has been postulated by some authors that the thickness of the apical plug may influence its leakage patterns. De Leimburg *et al.*<sup>18</sup> reported in a recent paper that orthograde use



of MTA provided an adequate seal against bacterial infiltration, regardless of the thickness of the apical plug. Hachmeister *et al.*<sup>12</sup> underlined in their paper that the thickness of the apical plug may have a significant impact only on displacement resistance. In the present case, we obtained a sufficient apical plug of 5 mm, leaving 12 mm space for resin post and core restoration.

**Figs. 6a & b**\_Post-op radiograph and microscopic appearance of the MTA plug (x16, Global Entrée Plus). **Figs. 6c & d**\_Gutta-fishing at 6 months.

Orthograde delivery of MTA in open apices is considered a very sensitive technique and the clinician should practise his/her skills before going *in vivo*. This case presentation was designed to guide the clinician step-by-step to the successful management of challenging open-apex cases.

*Editorial note: A list of references is available from the publisher.*

## \_about the author

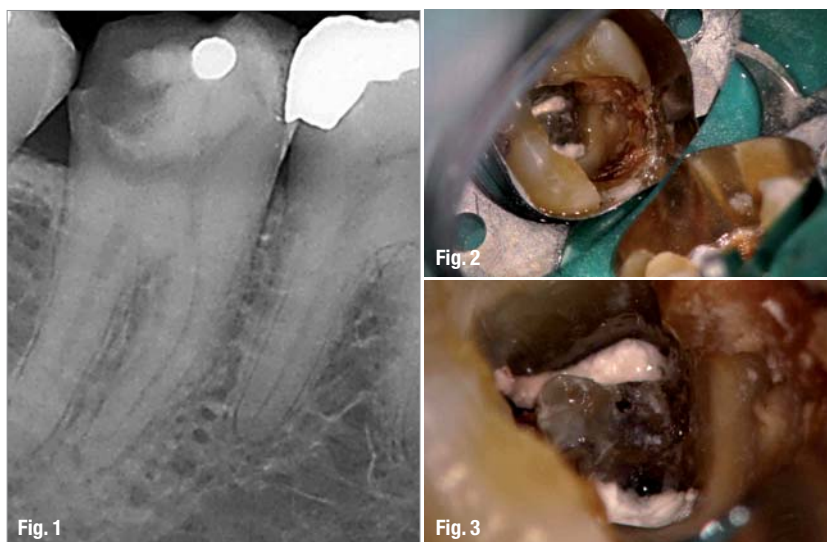
roots



**Dr Antonis Chaniotis** graduated from the University of Athens Dental School in 1998. He completed a three-year postgraduate programme in Endodontics at the University of Athens Dental School in 2003. He is a clinical instructor in the undergraduate and postgraduate programmes in the Department of Endodontics of the University of Athens Dental School. Since 2003, he has practised in a private practice in Athens that specialises in Endodontics. Dr Chaniotis can be contacted at [antch@otenet.gr](mailto:antch@otenet.gr) or via his website [www.endotreatment.gr](http://www.endotreatment.gr).

# Treating a calcified mandibular molar: A modern-day protocol

Author\_ Dr Rafaël Michiels, Belgium



## \_Treatment and discussion

A diagnostic radiograph (Fig. 1), which is essential in determining the treatment strategy, was taken to visualise the extent of the lesion and the anatomy of the roots. The patient was then anesthetised by a lower alveolar nerve block with 4% articaine, 0.01 mg/ml epinephrine (Septanest Special, Septodont).

The temporary filling and cotton pellet were removed, exposing a large carious lesion. In order to facilitate the temporary restoration after treatment, an AutoMatrix (DENTSPLY Caulk) was placed. This also enabled better isolation. The tooth was then isolated with a rubber dam (Coltène/Whaledent; Fig. 2).

Isolation, which is one of the fundamental principles in endodontics, is more than 100 years old. In 1864 already, Sanford C. Barnum developed the rubber dam, which was generally accepted as a necessity in achieving good isolation and better prognosis.<sup>1</sup>

*The first step in the treatment of a tooth [...] is the adjustment of rubber dam over the diseased tooth to preclude the possibility of the entrance of germs in the oral secretions into the pulp chamber. This should be the invariable rule.<sup>2</sup>*

However, a recent survey found that only 3.4% of general dental practitioners use the rubber dam in their endodontic routine.<sup>3</sup>

Visualisation and magnification can help clinicians greatly in cases like the one presented here. Without the use of a surgical operating microscope (OM), it is very difficult to locate canals in the presence of a great deal of calcification. "You cannot treat what you cannot see" is a quote that is regularly heard and that hits the nail right on the head.

**\_Endodontics has evolved** enormously over the last few decades. However, the basic principles from the past still apply today. The following case report gives an example of the manner in which the old principles are applied with newer techniques, devices and materials.

## \_History and diagnosis

A 37-year-old female patient was referred to our practice for a problem with her lower right second mandibular molar (tooth #31). She had no health issues, and was given an ASA score of 1. The referring dentist opened the tooth because of an acute pulpitis due to an extensive carious lesion disto-lingually. She had difficulty locating the mesial canals because the pulp chamber was heavily calcified. She had placed calcium hydroxide upon the orifices of the canals and sealed the tooth with a cotton pellet and a temporary restoration. The patient had no clinical symptoms when she presented to our office for treatment.

**Fig. 1\_** Diagnostic radiograph.  
**Fig. 2\_** Placement of rubber dam and AutoMatrix.  
**Fig. 3\_** Calcified tissue in the pulp chamber.



In this case, visualisation and magnification were obtained through the OM (OPMI pico, Carl Zeiss). Photographs were taken with a Canon PowerShot A650 IS (Canon) mounted on the FlexioStill adapter (Carl Zeiss).

I removed the carious dentine with LN burs (DENTSPLY Maillefer). There was a great deal of calcified tissue in the pulp chamber (Fig. 3), which I also removed with LN burs. The calcium hydroxide was easily removed with 10% citric acid.

After a clean opening cavity had been created, the actual root-canal treatment was begun. Two mesial canals were located and coronally pre-flared with ProTaper SX (DENTSPLY Maillefer; Fig. 4). Working length was determined with an ISO size 10 K-file (DENTSPLY Maillefer; Table I) and the Root ZX mini apex locator (J. Morita Europe). A glide path was then established with K-Flexofiles sizes 15 and 20.

Cleaning was performed with 3% NaOCl, which was ultrasonically activated with an Irrisafe tip (Satelec) several times throughout the procedure. The ultrasonic activation of the irrigating solution results in more effective removal of organic tissue, debris and planktonic bacteria.<sup>4</sup> It is a very easy and inexpensive procedure and should be incorporated in every endodontic routine.

Shaping was done with ProTaper files S1, S2 and F1 in the mesial canals and ProTaper file F2 in the distal

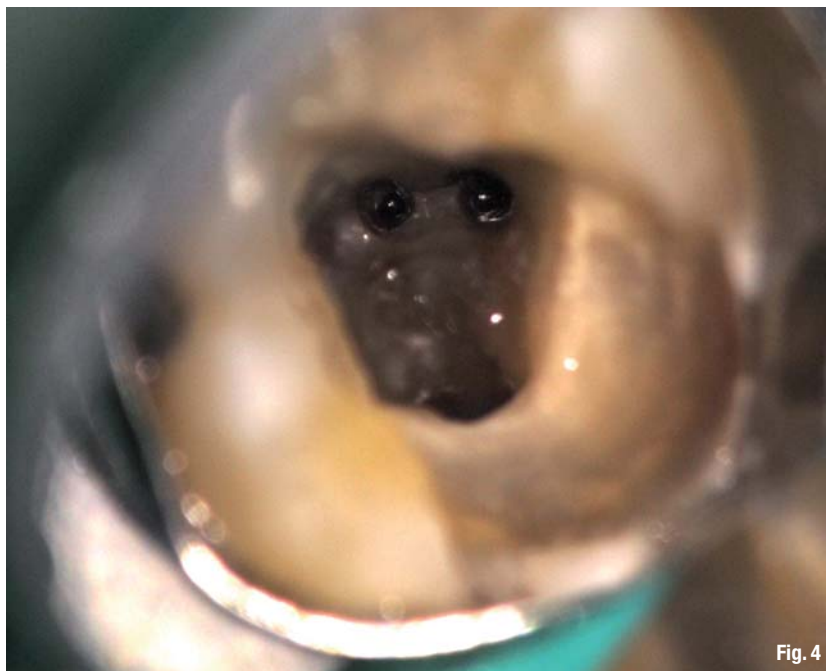


Fig. 4

Size in mm	Working length	MAF	Reference point
Oral D	21.5 mm	35	DB cusp
MB	21.5 mm	30	MB cusp
ML	22.5 mm	30	ML cusp

Table I

canal, giving the canal sufficient taper but a small apical diameter. Many controversies exist about shaping the apical diameter. I prefer an apical diameter of at

Fig. 4 \_ Locating the mesial canals.  
Table I \_ Working lengths and apical diameters of the canals.

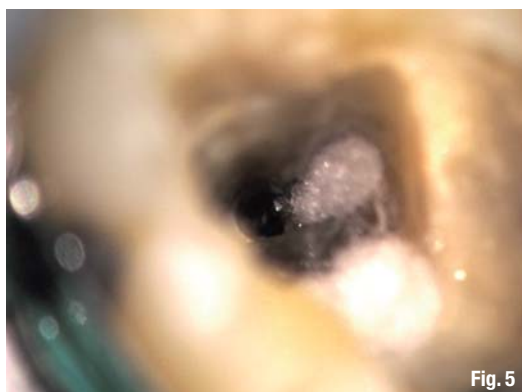

Fig. 5

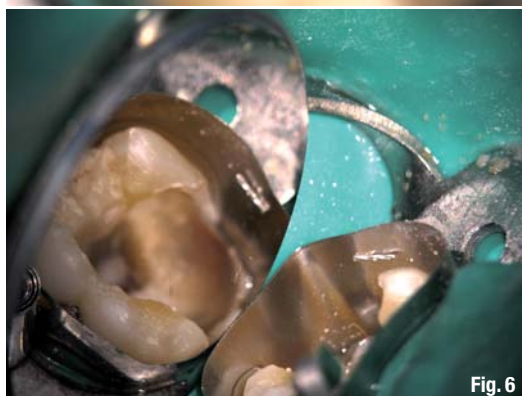

Fig. 6

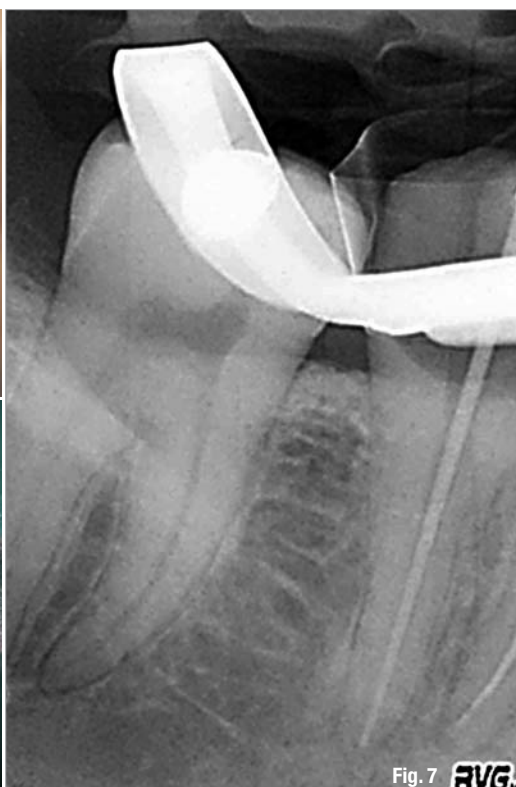
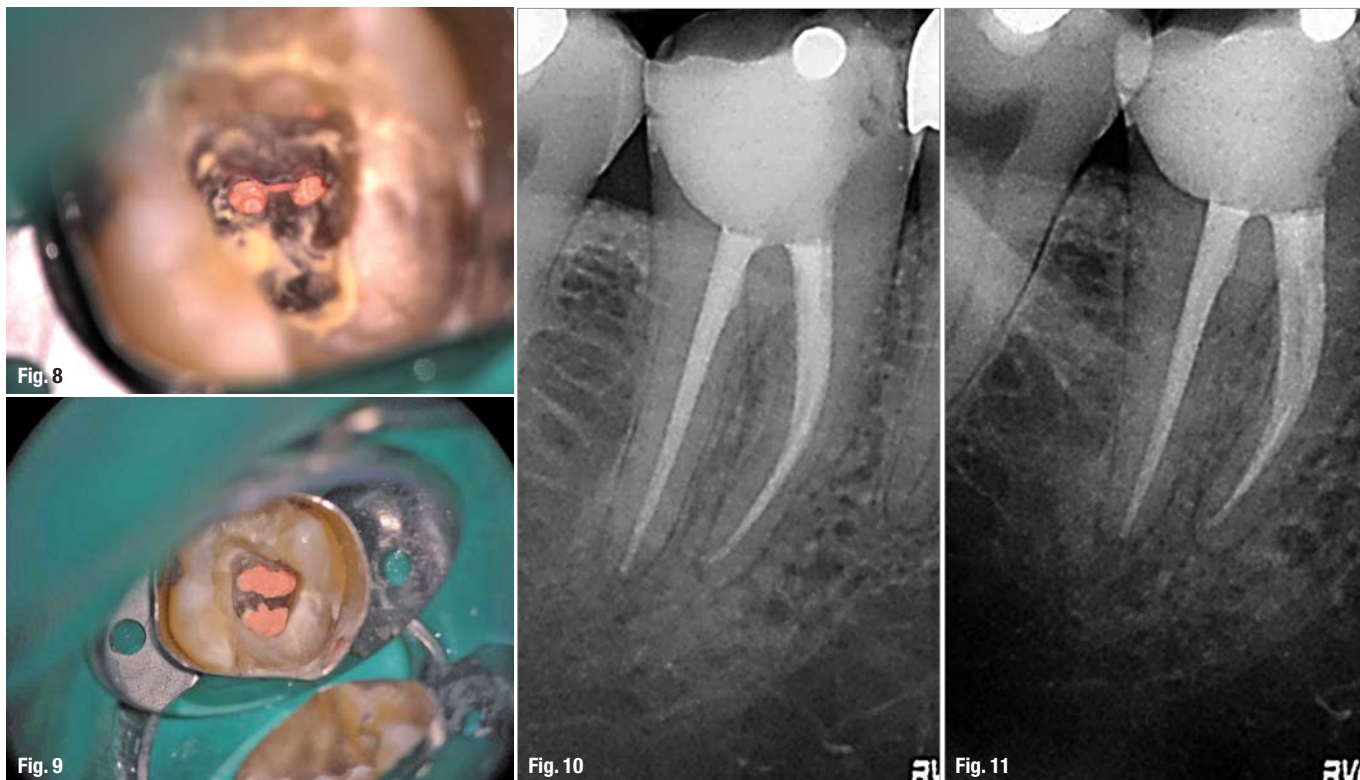


Fig. 7

Fig. 5 \_ Fractured Irrisafe tip.  
Fig. 6 \_ Removed Irrisafe tip.  
Fig. 7 \_ Confirmation radiograph.



**Fig. 8** \_ Obturation of the isthmus.  
**Fig. 9** \_ Pulp chamber after obturation and removal of excess sealer.  
**Fig. 10** \_ Final radiograph.  
**Fig. 11** \_ Final position.

least a size 30 because I rinse with a 30-gauge irrigation needle. That way, the NaOCl comes into direct contact with the apical dentine.<sup>5</sup> This results in a significantly better removal of debris from the apical part of the root.<sup>6</sup> In order to achieve a bigger apical diameter, a ProFile size 30.06 (DENTSPLY Maillefer) was taken to working length in the mesial canals and a ProFile size 35.06 in the distal canal. Utilising an ISO size 10 K-file, patency was maintained in all three canals throughout the entire treatment.

After the canals had been shaped, they were rinsed with 10% citric acid, which was ultrasonically activated three times for 20 seconds with an Irrisafe tip. During the third activation, the tip fractured and became stuck in the isthmus between the mesial canals. Cotton pellets were placed in the mesio-lingual and distal canal to prevent the instrument from falling into the canals during its retrieval (Fig. 5). Retrieval was done with another Irrisafe tip (Fig. 6). A final rinse was performed with 3% NaOCl, which was heated with a few bursts with System B (SybronEndo). Finally, cone pumping was performed with size 06 tapered gutta-percha cones. The literature refers to cone pumping as manual dynamic irrigation that has proven to be more effective than regular irrigation.<sup>7</sup>

A confirmation radiograph was then taken with gutta-percha master cones (DENTSPLY Maillefer) in place (Fig. 7). The canals were dried with paper points (Roeko).

Obturation was performed with a hybrid technique in which cold lateral condensation was used to fill the apical 4 mm. Thereafter, the System B needle was taken 4 mm short of working length into the canal. Backfill was performed with the Elements Extruder in small increments of 2 mm each time to reduce shrinkage. TopSeal (DENTSPLY Maillefer) was used as a sealer. During the backfill, I could see the isthmus being obturated with gutta-percha (Fig. 8), which is a desirable result. Were tissue to have been left in the isthmus, it may have led to failure. After obturation, excess sealer in the pulp chamber was removed with 96% alcohol (Fig. 9). A temporary restoration was then placed with Fuji IX GP Fast A2 (GC Europe).

Final radiographs (Figs. 10 & 11) were taken and the patient was sent home with instructions regarding possible post-operative discomfort and a prescription for 400 mg ibuprofen.

**\_Conclusion**

In the past, there were several revolutions in the field of endodontics, such as isolating with the rubber dam, cleaning with NaOCl and shaping with rotary instruments. Today, we still make use of these principles and are developing them further in order to make treatment easier and safer and to gain more favourable outcomes.

*Editorial note: A list of references is available from the publisher.*

_contact	roots
<p><b>Dr Rafaël Michiels</b>                  Parklaan 119                  2300 Turnhout                  Leopoldplein 14                  3500 Hasselt                  Belgium</p> <p>rafael.michiels@gmail.com                  www.ontzenuwen.be</p>	

# BioRaCe

## New

### NiTi ROTARY SYSTEM

A safe & efficient specific sequence  
TO ACHIEVE REQUIRED  
BIOLOGICAL APICAL SIZES

AS SIMPLE AS 0, 1, 2, 3...



NEW HANDLE AND NEW RUBBER STOP

## CONCEPT

Since root canal infection is the cause of apical periodontitis, the biological aim of endodontic treatment is the prevention or elimination of root canal microbes.

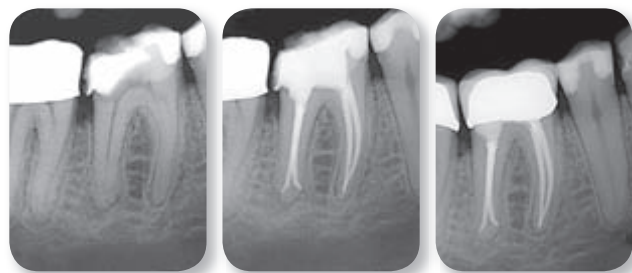
Consistent success in endodontics requires high technical skill in order to achieve a biological aim. It is well established that in order to remove enough microbes from the root canal to ensure predictable success, the apical third of the canal must be instrumented to certain minimum sizes.

Most instrumentation systems require an additional step to achieve minimum sizes in the apical third of the canal. This results in additional files, time and expense for the practitioner.

The BioRaCe sequence is unique, it has been especially designed to achieve the required apical sizes without the need for additional steps and additional files. If used according to instructions, most canals can be effectively cleaned with 5 NiTi files. Thus with the use of the unique BioRaCe system, the biologic aim of root canal treatment is achieved WITHOUT compromising efficiency.

## SELECTED CASES

### Dr. Gilberto Debelian (Norway)



Pre-op

Post-op

1 y. follow-up

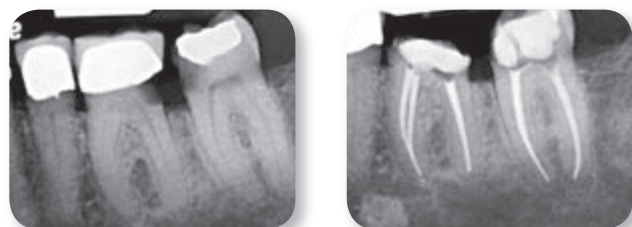
Tooth 46

Dx: Chr. apical periodontitis  
Tx: Pulpectomy

Treatment Details:

MB & ML: BR4 35/04  
DB & DL: BR6 50/04

### Dr. Martin Trope (USA)



Pre-op

Post-op

Teeth 36 and 37

Dx: Symptomatic pulpitis  
Tx: Pulpectomy

Treatment Details:

MB & ML: BR5 40/04  
DB & DL: BR6 50/04

More details and information on  
[www.biorace.ch](http://www.biorace.ch)



# A cavernous sinus infection: A root-canal case

Author\_Dr Philippe Sleiman, Lebanon

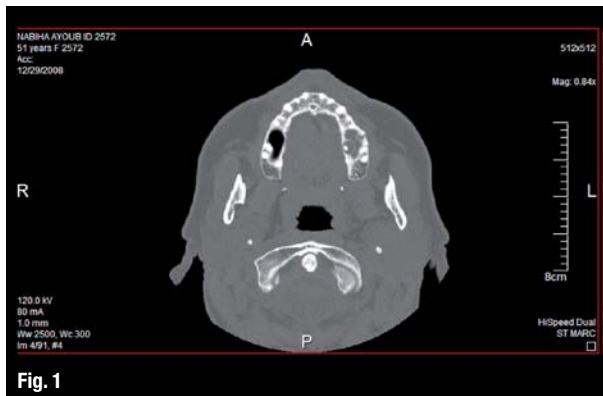


Fig. 1

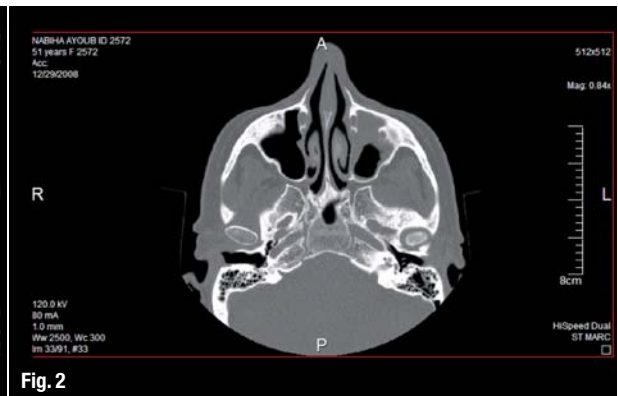

Fig. 2

Fig. 1\_Palatal and mesial roots pierced the sinus membrane.

Fig. 2\_The opening in the middle of the sinus could lead to misdiagnosis.

Once upon a time, a patient walked into my office without an appointment. She introduced herself and said that her otorhinolaryngologist had referred her to my office. I asked my assistant to take the X-rays, conduct computed tomography (CT) scanning and schedule the patient as soon as possible. During coffee break, I was going through the scans and decided to look at not only the printouts but all of the slides burnt on the CD. As I was browsing through the slides, I realised that the palatal and mesial roots were piercing the sinus membrane and there was infection around them (Fig. 1). I went a few millimetres up and saw an opening in the middle of the sinus (Fig. 2). Today I know that it would have been a fatal error on my part had I stopped at this level. I do not know what made me continue my observation, but fortunately I did.

Fig. 3\_The infection occupied the greater part of the maxillary sinus and perforated the sinus.

Fig. 4\_The infection invaded the orbit.

Fig. 5\_Thickening of the cavernous sinus.

A few millimetres higher, the infection was occupying the greater part of the maxillary sinus and perforating the sinus (Fig. 3). Even further up, the infection was invading the orbit (Fig. 4). The really un-

pleasant surprise was a thickening of the cavernous sinus observed in two slides (Fig. 5), and cold sweat covered my face. At this point, any flare-up, inflammation or infection could lead to such severe consequences as thrombosis in the cavernous sinus, bringing about a true life-or-death drama for the patient.

Before presenting the rest of the clinical case, here is a brief summary of the sinuses.

## Sinus definition—physiology

Sinuses are air-filled cavities with classical, pseudo-stratified, ciliated columnar epithelium interspersed with goblet cells. The cilia sweep mucus towards the ostial opening. Obstruction of sinus ostia might lead to mucous impaction and decreased oxygenation in the sinus cavities. During obstruction of the ostia, the pressure in the sinus cavity may decrease, which in turn causes the symptom of pain, particularly in the frontal region.

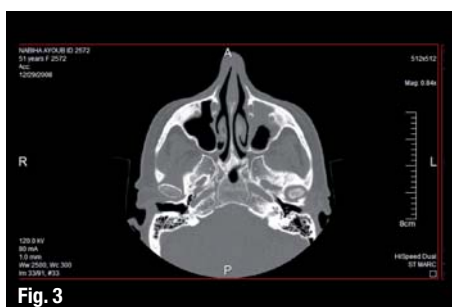


Fig. 3

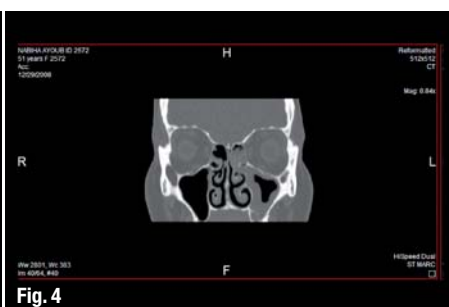


Fig. 4

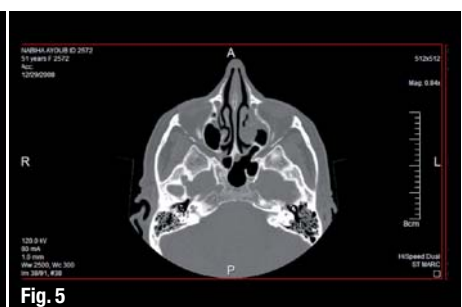

Fig. 5

### Sphenoidal sinuses

The sphenoidal sinuses are located in the body of the sphenoid bone and may extend into its wings. They are unevenly divided and separated by a bony septum. Because of this extensive pneumatization (formation of air cells or sinuses), the body of the sphenoid is fragile. Only thin plates of bone separate the sinuses from several important structures: the optic nerves and optic chiasm, pituitary gland, internal carotid arteries and cavernous sinuses. The sphenoidal sinuses are derived from a posterior ethmoidal cell that begins to invade the sphenoid, giving rise to multiple sphenoidal sinuses that open separately into the sphenoidal recess. The posterior ethmoidal arteries and posterior ethmoidal nerve supply the sphenoidal sinuses.

### Complications of sphenoidal sinusitis (diplopia in childhood)

The most common complication of sphenoidal sinusitis is meningitis. Any surrounding tissue adjacent to sphenoid sinus may be infected. As a result of the close anatomical relationship with the sphenoidal sinuses, cranial nerves II to IV, the dura mater, pituitary gland, cavernous sinus, internal carotid artery, sphenopalatine artery and pterygopalatine nerve have been reported to be infected by dissemination. Complications such as orbital cellulitis, orbital abscess, orbital apex syndrome, blindness, meningitis, epidural and subdural abscesses, cerebral infarcts, pituitary abscess, cavernous sinus thrombosis and internal carotid artery thrombosis have been described in literature.

Clinical suspicion is very important for determining the diagnosis because the symptoms, history and physical examination do not specifically indicate sphenoidal sinusitis. High-resolution axial and coronal CT is recommended for the diagnosis of sphenoidal sinusitis and potential intracranial complications. However, cranial magnetic resonance imaging is superior to CT in terms of detecting the involvement of cranial nerves, cavernous sinus, surrounding neurovascular tissue and the presence of a tumour.

The most common pathogens in the aetiology of sphenoidal sinusitis are *Staphylococcus aureus*, *Streptococcus pneumoniae* and some aerobic and anaerobic *Streptococcus spp.* fungi, particularly *Aspergillus spp.*, should be kept in mind in immunosuppressed patients. Uren and Berkowitz reported eight children with Idiopathic subglottic stenosis, five out of which had been treated successfully with medical therapy. The remaining three children, either unresponsive to medical therapy or complicated cases, had undergone endoscopic sphenoidotomy. At the begin-

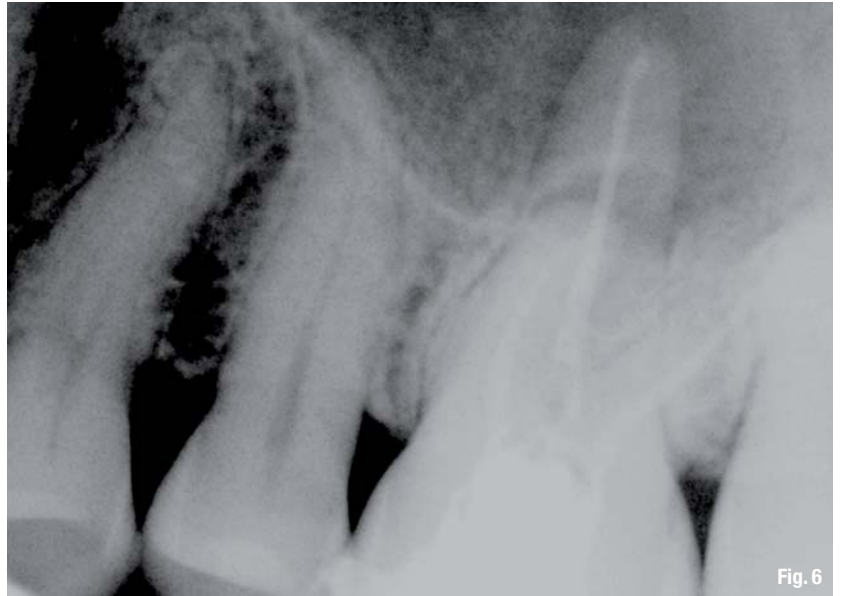


Fig. 6

ning, parenteral antibiotic therapy should be administered, since this infection may cause serious, even fatal, complications. A three- to four-week antibiotic therapy should be completed. Topical decongestants and irrigation with saline solution are recommended as adjunctive therapy.

Fig. 6\_Immediate post-op X-ray.

Since the sphenoid sinus has anatomical relationships with several vital structures, any delay in correct diagnosis and, therefore, in prompt and adequate treatment, can result in severe and life-threatening complications<sup>1</sup>, such as meningitis, pituitary abscess, peri-orbital cellulitis, orbital cellulitis, optic neuritis, carotid artery thrombosis and cavernous sinus thrombosis. Sphenoiditis is generally associated with inflammation of the maxillary and ethmoidal sinuses.

When complications occur, patients also complain of facial pain, paraesthesia at the level of the V1, V2, V3 areas, sixth nerve palsy, ocular signs and symptoms (blurred vision, diplopia, eye tearing, proptosis, visual loss, ptosis) and mental status changes. These complications are due to the anatomical relationship of the sphenoid sinuses with nearby vital structures such as the middle cranial fossa, hypophysis, superior orbital fissure, optical canal and cavernous sinus, which contain the internal carotid artery and cranial nerves III to VI. Thus, when a sinus infection spreads to these structures, it may mimic other neurological disorders, thus delaying correct diagnosis and appropriate treatment.

### Maxillary sinuses

Embryologically, the maxillary sinus is first to appear, initially, as a depression of the nasal wall below the middle turbinate. The growth of the sinus is related to the development and eruption of the maxillary molar teeth, and does not reach full size until the eruption

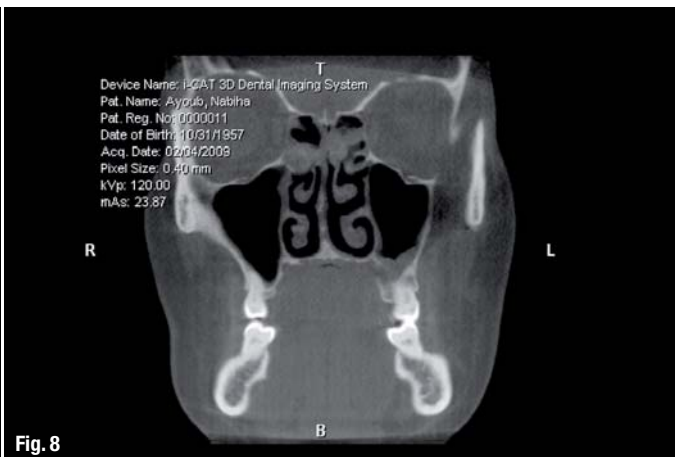
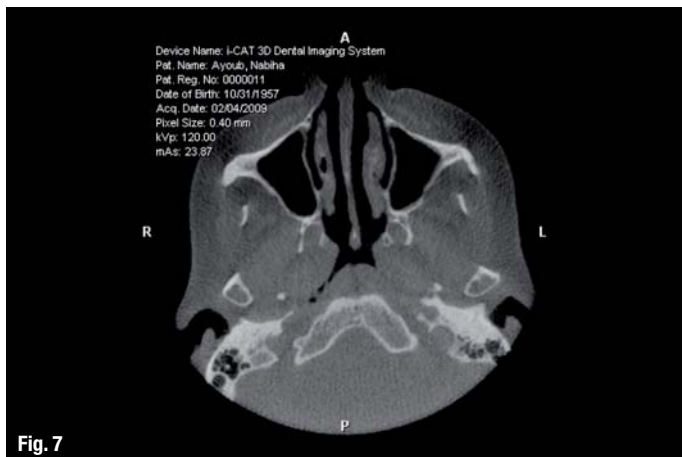
Fig. 7

Fig. 8

**Figs. 7 & 8** i-CAT scan showing healing of the sinuses.

of the permanent dentition. The maxillary sinus, also known as the *antrum of Highmore*, is the largest of the paranasal sinuses. The roof of the maxillary sinus is formed by the alveolar part of the maxilla. The roots of the maxillary teeth, particularly the first two molars, often produce conical elevations in the floor of the sinus.

#### *Infection of the maxillary sinuses*

Maxillary sinusitis (inflammation of maxillary sinus) may be of dental origin. The dental causes of maxillary sinusitis include peri-apical infection, periodontal disease or perforation of the antral floor and antral mucosa at the time of dental extraction. Roots and foreign objects forced into the maxillary sinus at the time of operation may also be the causative factors of sinusitis. The non-dental source of maxillary sinusitis includes allergic conditions, chemical irritation or facial trauma (fracture involving a wall or walls of the maxillary sinus).

The patient may complain of a sense of fullness over the cheek, especially on bending forward. Other complaints with regard to maxillary sinusitis may include headache, facial pain and tenderness to pressure. The pain may also be referred to the premolar and molar teeth, which may be sensitive or painful to percussion.

#### *Relationship of the teeth to the maxillary sinus*

The close proximity of the three maxillary molar teeth to the floor of the maxillary sinus poses potentially serious problems. During removal of a molar tooth or root-canal treatment, root fracture may occur. If proper retrieval methods are not used, a piece of the root may be driven superiorly into the maxillary sinus, while in the case of endodontic treatment overextension or over-obturation of the material may drive material into the sinus. A communication may be created between the oral cavity and the maxillary

sinus as a result and an infection may occur. Because the superior alveolar nerves (branches of the maxillary nerve) supply both the maxillary teeth and the mucous membrane of the maxillary sinuses, inflammation of the mucosa of the sinus is frequently accompanied by a sensation of toothache in the molar teeth.

### Cavernous sinus

The cavernous sinus is located on each side of the *sella turcica* on the upper surface of the body of the sphenoid, which contains the sphenoid (air) sinus. The cavernous sinus consists of a venous plexus of extremely thin-walled veins that extends from the superior orbital fissure anteriorly to the apex of the petrous part of the temporal bone posteriorly. The venous channels in these sinuses communicate with each other through venous channels anterior and posterior to the stalk of the pituitary glands, the intercavernous sinuses and sometimes through the superior and inferior petrosal sinuses and emissary veins to the pterygoid plexuses.

Inside each cavernous sinus is the internal carotid artery with its small branches, surrounded by the carotid plexus of sympathetic nerve(s), and the abducent nerve (cranial nerve VI). The oculomotor (cranial nerve III) and trochlear (cranial nerve IV) nerves, plus two of the three divisions of the trigeminal nerve (cranial nerve V) are embedded in the lateral wall of the sinus. The artery, carrying warm blood from the body's core, traverses the sinus filled with cooler blood returning from the capillaries of the body's periphery, allowing for heat exchange to conserve energy or cool the arterial blood. Pulsations of the artery within the cavernous sinus are said to promote propulsion of venous blood from the sinus, as does gravity.<sup>2</sup>

Cavernous sinus thrombosis usually results from infections in the orbit, nasal sinuses and superior part of the face (the danger triangle). In persons with thrombophlebitis of the facial vein, pieces of an in-



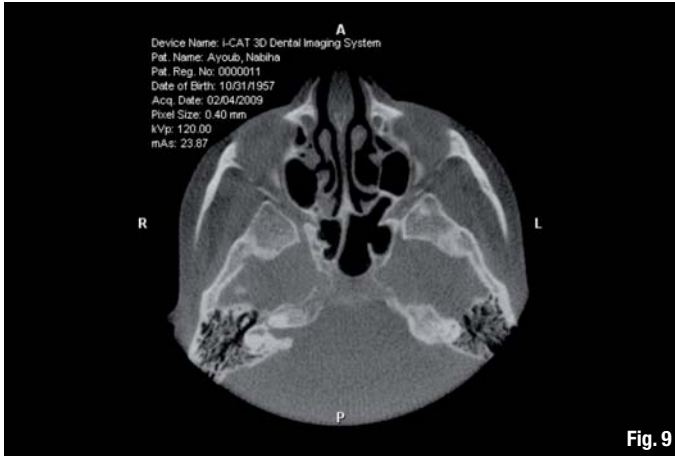


Fig. 9

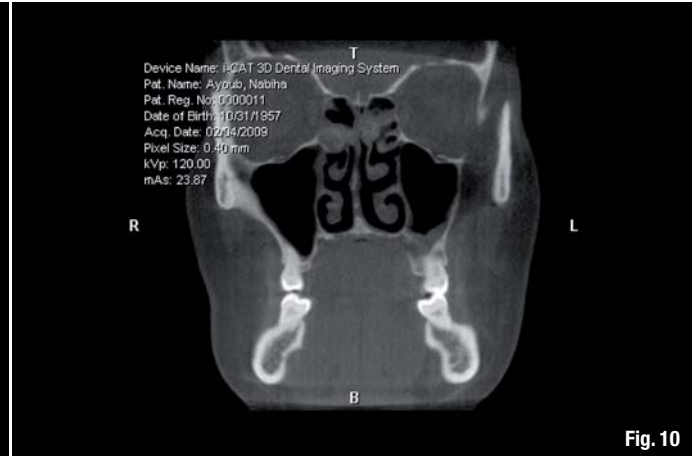


Fig. 10

ected thrombus may extend into the cavernous sinus producing thrombophlebitis of the cavernous sinus. The infection usually involves only one sinus initially but may spread to the opposite side through the intercavernous sinuses.

Thrombophlebitis of the cavernous sinus may affect the abducent nerve as it traverses the sinus and may also affect the nerves embedded within the lateral wall of the sinus. Septic thrombosis of the cavernous sinus often results in the development of acute meningitis and sometimes the life of the patient may be endangered.

### \_ Case report

After examining the patient, I called her otorhinolaryngologist and a neurologist to meet in the evening to discuss the case and we decided to put the patient on antibiotic therapy for three days prior to the beginning of the treatment. In the meantime, a conservative treatment was outlined, including root-canal treatment and tooth restoration.

Three days later, the patient returned to my office where I opened the tooth under strictest infection-control conditions. The canals were enlarged using Twisted Files (SybronEndo) to the size of 40, taper 0.04 in the apical part. No swelling was observed and obturation was done in the same session using RealSeal (SybronEndo), followed by composite coronal restoration placed immediately in order to stop any possible coronal leakage (Fig. 6).

The patient was checked regularly and an i-CAT was performed. I was very pleased to see the positive results and the healing of the greater part of the infection (Figs. 7 & 8). Most importantly, a complete healing of the cavernous sinus was observed (Fig. 9).

At the 18-month check-up, we saw the healing of the sinus above the molar.

### \_ Conclusion

A fatal error may have been made had I decided to extract the tooth. Under these circumstances, we would have potentially caused a flare-up, which could have resulted in severe consequences. It is important to underline that we should trust our root-canal treatment and use strict measures in bacteria and micro-organism control, starting from access cavity opening to the root-canal shaping, especially in the last 3 mm, where a size 40.04 Twisted File was used for apical enlargement. Obturation was done with RealSeal. This highly bio-compatible material is zinc and eugenol free, making aspergillosis and sinus inflammation due to paste extrusion beyond apex highly unlikely. The final results demonstrate a complete healing of the sinuses, of which the patient was very relieved to learn (Fig. 10).

The main message of this article is that we need to take our time in determining the correct diagnosis for each case that is presented to our office. We have to go beyond the oral sphere. The proper approach can ensure excellent results in a simple and straightforward treatment.

I would like to thank Phd Yulia Vorobyeva, interpreter and translator, for her help with this article.

*Editorial note: A list of references is available from the publisher.*

_contact	roots
<p><b>Dr Philippe Sleiman</b>                      Dubai Sky Clinic                      Burjuman Business Tower, Level 21                      Trade Center Street, Bur Dubai                      Dubai, UAE</p> <p>phil2sleiman@hotmail.com</p>	

Figs. 9 & 10\_ Healing of the sinuses.

# “We are constantly trying to maintain our technological lead”

An interview with Audrey Stefani, Dr Stephan Gruner & Dr Khaled A. Balto



Audrey Stefani



Dr Stephan Gruner



Dr Khaled A. Balto

**\_It all started with** a nerve broach in 1907. MICRO-MEGA, whose headquarters are located in Besançon (France), has been manufacturing endodontic tools for over a hundred years and played a decisive role in endodontics through new developments. Internationally, the innovative company has a recognised reputation of being a specialist in dental instruments. At this year's Adviser Group for Endodontics (AGE) meeting, **roots** met with Audrey Stefani, MICRO-MEGA Marketing Manager; Dr Stephan Gruner, Country Manager MICRO-MEGA Germany; and Dr Khaled A. Balto (Saudi Arabia), Associate Professor and moderator of the AGE meeting.

**\_roots:** *Mrs Stefani, for over a century MICRO-MEGA has been operating successfully in the dental market. Could you tell us anything in particular that stands out for you in the company's history?*

**Audrey Stefani:** MICRO-MEGA is proud of having set international milestones with handpieces and contra-angle handpieces, micro-motors, endodontic files and NiTi files.

A fact that perhaps only a few people know is that MICRO-MEGA used to be the sole manufacturer of handpieces and contra-angle handpieces for the large brands in Germany and other countries.

The Citoject, for example, was a MICRO-MEGA product, manufactured under Heraeus' own brand for Heraeus. Today, it is still available as LigaJect from MICRO-MEGA, even after it was phased out of production. To a considerable degree, the company was characterised by being able to launch world-first innovations on the market regularly, and we are able to build on this expertise today.

*Which MICRO-MEGA products have set standards on the international dental markets?*

MICRO-MEGA inventions have set world standards; for example, in 1957 with the first dismountable handpieces with tungsten-carbide bearings; in 1963, Giromatic, the first contra-angle handpiece able to produce an alternating 90° rotation and specially made root-canal tools; in 1964, micro-motors with 40,000 rotations per minute, on the basis of which micro-motors are built today by all manufacturers; in 1974, the Masserann Kit for the removal of fractured endodontic tools from root canals; in 1996, HERO 642, a clear and simple system of rotary NiTi files; in 2002, HERO Shaper, a rotary NiTi file system. I could go on with this list indefinitely.

**“MICRO-MEGA  
is proud  
of having set  
international  
milestones.”**

**Audrey Stefani**

All these experiences led to the development of the Revo-S file system, which was launched in 2009. This system enables a root-canal preparation with only three files. Revo-S is currently state-of-the-art technology; however, development is ongoing, which is why we hold the AGE symposium every year.

*In autumn 2009, MICRO-MEGA joined a group of companies under the management of SycoTec. In March of this year, the Canadian SciCan joined the European duo. The group is now amongst the top ten manufacturers of dental equipment worldwide. What opportunities does such a strong group offer?*

One great asset is that we are able to join forces and learn from one another. Our focus here in Europe naturally lies in Germany and France, but we are also going to enter new markets. If possible, we will use joint marketing, and joint research and development in order to consolidate our position on the market. An important part of the strategy is to maintain and further the SciCan and MICRO-MEGA brands.

*Is the name of the group still under debate?*

Indeed, we have debated this for a while but have finally agreed on a name. I am proud to announce that MICRO-MEGA, SciCan and SycoTec are members of the Sanavis Group.

*MICRO-MEGA sells its products worldwide. Which countries are the most important in terms of turnover? And which regions hold the most potential in your opinion?*

Europe has always played an important role in our corporate development. The most important importing countries are Germany and, in our domestic market, France. North and South America are in the process of development, particularly with the introduction of our rotary NiTi systems. We have also recorded good growth figures in the Asia-Pacific region. Moreover, we are keenly observing the Middle Eastern region. As you can see, MICRO-MEGA as an internationally known brand is in the process of exploiting current potential markets.

There is every chance of success, particularly since research and development in the group have now reached global player magnitude and we know how to take advantage of this.

*Dr Gruner, are you currently working on the development of new products?*

**Dr Stephan Gruner:** Thanks to the above-mentioned synergies, our newly created group is going to get things moving in the dental world. We are constantly trying to maintain our technological lead and thus work hard and intensively. An event like the AGE helps keep MICRO-MEGA's finger on the pulse of world trends.

*Have your expectations of this year's AGE meeting been met?*

The AGE meeting has once again helped us progress scientifically thanks to top-notch research results presented by the speakers. During our internal MICRO-MEGA sessions, we were able to discuss international market demands further, which were then tested for feasibility and formed into projects.

**“The AGE meeting  
has once again  
helped us progress  
scientifically.”**

**Dr Stephan Gruner**

*Prof Shimon Friedman lectured on The endodontic treatment outcome: The impact of the new technologies. Would you please summarise the most important points for us?*

Prof Friedman is world-renowned in the field of endodontics. Together with co-authors Dr Thuan Dao



*et al.*, he authored the world famous *Toronto Study*, a series of articles in the *Journal of Endodontics*. This is an extensive piece of work that illustrates and analyses the status of endodontics, starting with the publication of the first results in the year 2000 up to and including 2010.

In his excellent lecture, Prof Friedman made clear that differences in the evaluation and success or failure of an endodontic treatment greatly depend on the methods and structure of the evaluating studies themselves. If the correct evaluation criteria are applied, the success rate of endodontic treatments over the last ten years is around 88 to 95%. Amongst the various authors, a high consistency of results is noticeable. These studies are encouraging.

*“The new product Revo-S was a part of further presentations. Dr Balto, in connection with the innovative Revo-S concept you also spoke about the ‘third dimension’ of endodontic treatment. Would you please illustrate the main points of the system?”*

**“Revo-S is the result of 17 years of critical performance analysis.”**

**Dr Khaled A. Balto**

**Dr Khaled A. Balto:** In general, endodontic rotary systems are evaluated with regard to the parameters of geometric features, taper, tip size, etc. Therefore, the equation for efficiency of a given file has long been considered to be inner core size and symmetric design (which means perfect geometry), which results in stronger files. After 17 years of using Rotary NiTi files, we have learned that the equation for efficiency is rather the asymmetric design and efficient clearing of dentinal debris. This understanding was applied in the conception of the Revo-S system.

Revo-S is the result of 17 years of critical performance analysis, which for the first time addressed the concept of dynamic asymmetry. As a result, we now have files with better penetration and a better clearing effect. Moreover, it is efficient, with only three files for initial treatment and much less likelihood of separation. To perceive the bio-mechanics of the file in the ‘third dimension’, the canal depth, the kinetics of Revo-S—the way it rotates inside the root canal—are analysed.

*“What is your view of endodontics in the Arabic region compared to the Western world?”*

Endodontics is a rapidly growing speciality in the Arab world in general, particularly in Saudi Arabia. Rotary endodontics, micro-training, warm obturation techniques as well as modern *retro-dontics* are all an integral part of teaching curricula at many universities. However, as in many other countries in the world, there is a wide range of performance results depending on the experience of the dentists and the difficulty of the cases. Individual variation plays a significant role in the treatment standards. For example, being an associate in a practice limited to micro-endodontics in Jeddah, I treat patients from all over the world as well as locals. I have managed failures for treatments rendered domestically and from other countries. All in all, I do not see substantial differences between the different countries in regards to the standard of treatment however, there might be a difference in the number of well qualified individuals.

*“Your comprehensive publications illustrate the wide range of your work. What are you working on at the moment?”*

Being an academic, clinician and researcher at the same time is rather difficult but not impossible. As Deputy Director of the Center of Excellence for Osteoporosis Research in Jeddah, my current research focuses on osteoporosis as it relates to oral health. Since I returned from Harvard Dental School, where I received my D.M.Sc., the essence of my research interest has remained the same, which is in brief: cellular and molecular mediators of infection-induced bone destruction, evidence-based dentistry and other clinical endodontic research.

*“Apart from publishing, how do you exchange information with international colleagues?”*

The world has become a small village thanks to the recent developments in information and communication technology. The Internet is the driving force for today's information exchange. Online publishing, discussion forums, YouTube, etc. make it easy to stay in touch and remain updated on new developments. In my opinion, postgraduate training programmes in endodontics constitute the most important cornerstone. As Director of the Saudi Board of Endodontics, I have the privilege of reviewing articles and thus am constantly kept up to date on what's new. Additionally, I value the international interaction that is possible through conferences and meetings like the AGE meeting.

*“We would like to thank you for this interview and wish you continuing success.”*

*Editorial note: The interview was led by Jeannette Enders and Steffi Goldmann.*

# Everything Endo.

Every step of the way.



**Diagnostics > Shape > Clean > Obturation.**  
**Everything endo from SybronEndo.**

SybronEndo Europe, Basicweg 20, 3821 BR  
Amersfoort, The Netherlands  
Tel: +31 33 4536 159 fax: +31 33 4536 153  
email: [endo@sybrondental.com](mailto:endo@sybrondental.com)

**SybronEndoEurope**  
Sybron Dental Specialties

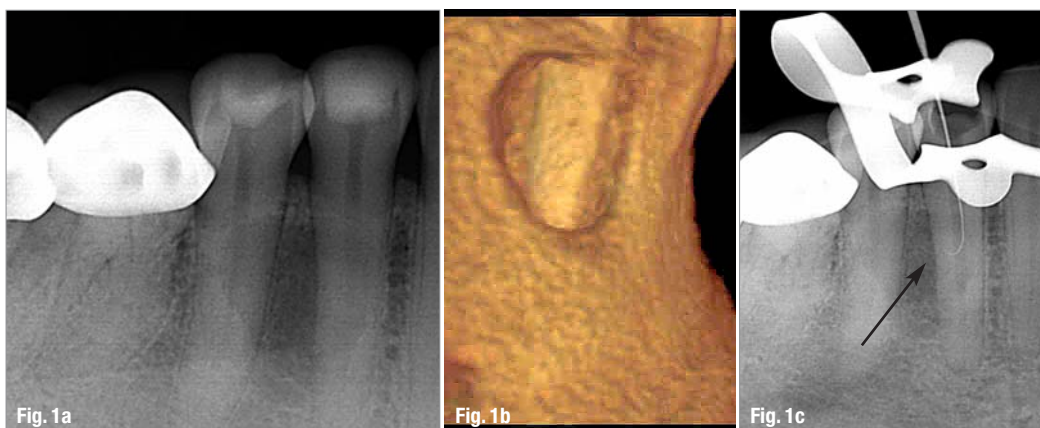
# Endodontic success: The pursuit of our potential

Author\_ Dr Wyatt D. Simons, USA

**Fig. 1a**\_A mid-root, cystic-appearing radio-lucency was noted without peri-apical involvement.

**Fig. 1b**\_Upon CBCT evaluation, a lateral portal of exit can be visualised in the centre of this mid-root radio-lucency. This aided in the diagnosis of disease of endodontic origin and furthered the success of treatment.

**Fig. 1c**\_Lateral system instrumented with a sharp J-curve of a stiff #15 hand file.



**Fig. 2a**\_When the cyst was surgically removed, the mid-root lateral was noted to be sealed with gutta-percha.

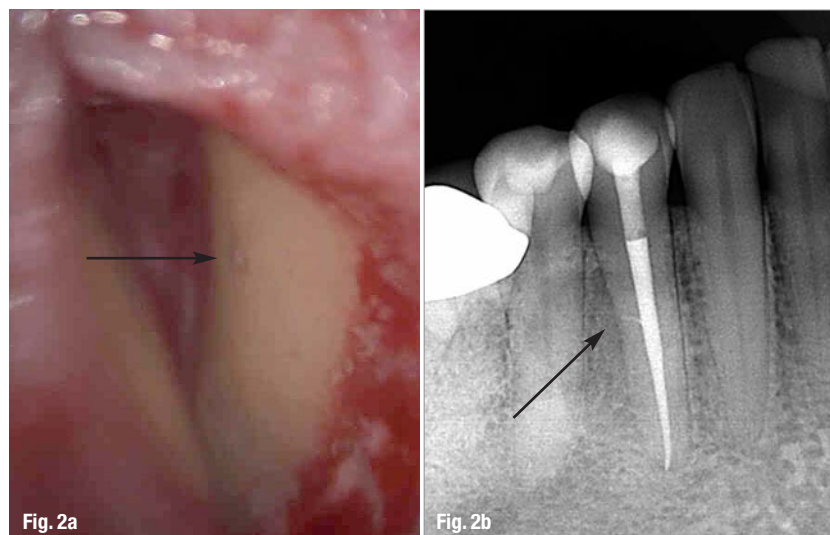
**Fig. 2b**\_The sealed upward-facing lateral can be seen on the post-op digital image.

**\_Endodontics is currently experiencing** an exciting period in its evolution: a period when progressive clinicians have become empowered to increase their rates of success owing to new technologies that enhance vision, disinfection and the protective seal of

the entire root-canal system. Early in my endodontic journey, Dr Herbert Schilder, a pioneering clinician, encouraged me to reach my full potential. We all aspire to reach our individual potential, and it is this collective pursuit of excellence that guides the future success of our specialty.

Our pursuit of higher success rates comes at a time of unique opportunity, a time when the comparative success rates between implants and endodontically treated teeth are being scrutinised<sup>1-2</sup>—and a time when some patients have been known to be advised to make decisions based mainly on a comparison of research-quoted technical success rates.

Dedicated clinicians are able to strive for improved success rates owing to many recent advances in our field. This article focuses on three areas of endodontics that have undergone profound advancement recently. The efficacy of our treatment has improved owing to our increased ability to visualise, disinfect and seal the entire root-canal system in three dimensions.



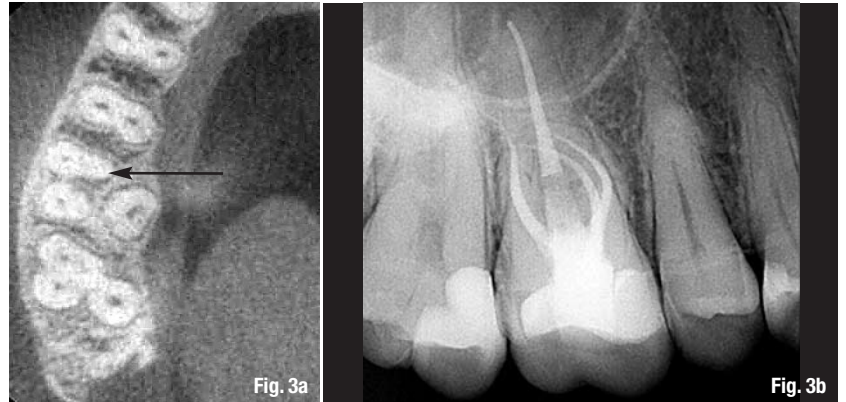

## \_Precise 3-D visualisation

The ability to visualise the complexities of pulpal anatomy has had a tremendous impact on our ability to diagnose and treat complex endodontic disease.<sup>3-6</sup> For decades, the microscope has enhanced the quality of our endodontic treatment. The knowledge that greater expertise and quality outcomes can result from increased visualisation is self-evident. Currently, cone beam computed tomography (CBCT) allows us to visualise the intricacies of individual pulpal anatomy more clearly in 3-D.<sup>7</sup> CBCT uncovers details of anatomy in the pulpal system and bone prior to initiating treatment, which in turn guides diagnosis and contributes significantly to more predictable treatment.<sup>8-9</sup> The following cases illustrate examples of how CBCT can aid the clinician in endodontic diagnosis and treatment.

When a patient presents with swelling of the lower right vestibule, a comprehensive examination is performed, including a 2-D digital peri-apical radiograph. In this case, a mid-root, cystic-appearing, radiolucent lesion was noted without peri-apical involvement (Fig. 1a). Upon CBCT evaluation, a lateral portal of exit was visualised in the centre of this osseous defect, which aided in the diagnosis of a lesion of endodontic origin (Fig. 1b).<sup>10-11</sup> Once comprehensive pulpal testing had been completed, tooth #28 was confirmed to be non-vital.

After analysing the information provided by the CBCT image, the infected lateral system was more easily located and instrumented with the sharp J-curve of a stiff #15 hand file (Fig. 1c). Treatment was enhanced by directly instrumenting this aspect of the pulpal system, as we know that this increases disinfection.<sup>12</sup> After non-surgical treatment had been completed, surgical intervention was performed owing to the appearance and size of the lesion. When the radicular cyst (confirmed histologically) had been removed, the surgical microscope displayed the lateral portal of exit to be sealed with gutta-percha (Fig. 2a). In addition, the sealed upward-facing lateral system can be seen on the post-operative digital image (Fig. 2b).



Comprehensive treatment of the entire pulpal system dictates endodontic success.<sup>13</sup> Figures 3a and b illustrate the common challenge that arises as the result of a second mesio-buccal system (MB2) in upper molars. Once clinicians visualise whether complex pulpal anatomy is present with CBCT, they can confidently and conservatively locate it under the microscope. With utilisation of this new technology, incomplete endodontic therapy should be a thing of the past.

CBCT has a profound impact on our ability to locate and treat calcified pulpal systems.<sup>14</sup> Figure 4a illustrates a calcified molar in need of endodontic therapy. Upon initial microscopic treatment, difficulty in locating the mesio-lingual (ML) system was encountered. Calcium hydroxide was placed and a CBCT image was taken. The location of the elusive canal was visualised as being patent and at the level of the current conservative exploration, but 0.25 mm to the lingual (Fig. 4b). Upon microscopic re-entry into the case, the ML canal was conservatively located and comprehensive treatment was completed (Fig. 4c).

## \_Relentless pursuit of complete disinfection

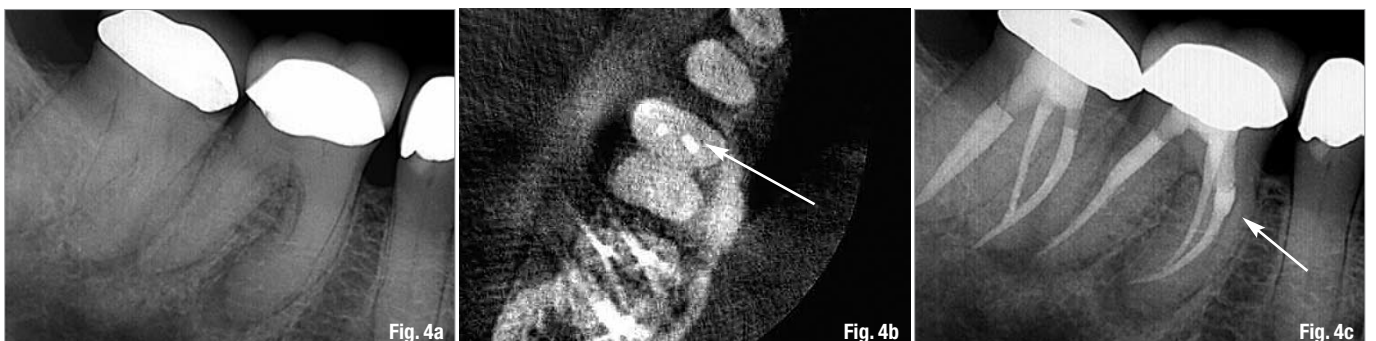Revolutionary advancements in endodontic disinfection have intensified our desire to reach higher levels of disinfection. One such device that facilitates this goal is the EndoVac (Discus Dental; Figs. 5a & b).<sup>15-17</sup> The EndoVac provides thorough irrigation of the complete root-canal system, including the critically

**Figs. 3a & b** CBCT technology is commonly used for confirmation of the presence and location of an MB2. This allows for confident, conservative and comprehensive treatment.

**Fig. 4a** A calcified molar in need of endodontic therapy.

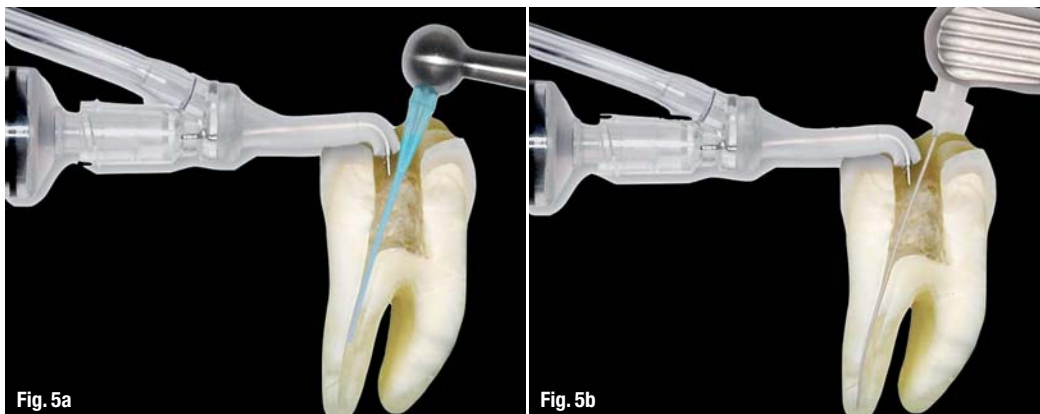
**Fig. 4b** After initial exploration for the calcified ML system, calcium hydroxide was placed and a CBCT image was taken. The location of the elusive canal was visualised to be patent and at the level of the current conservative exploration, but 0.25 mm to the lingual.

**Fig. 4c** CBCT information allowed for the conservative location of the calcified ML system and completion of comprehensive treatment of the entire root-canal system.



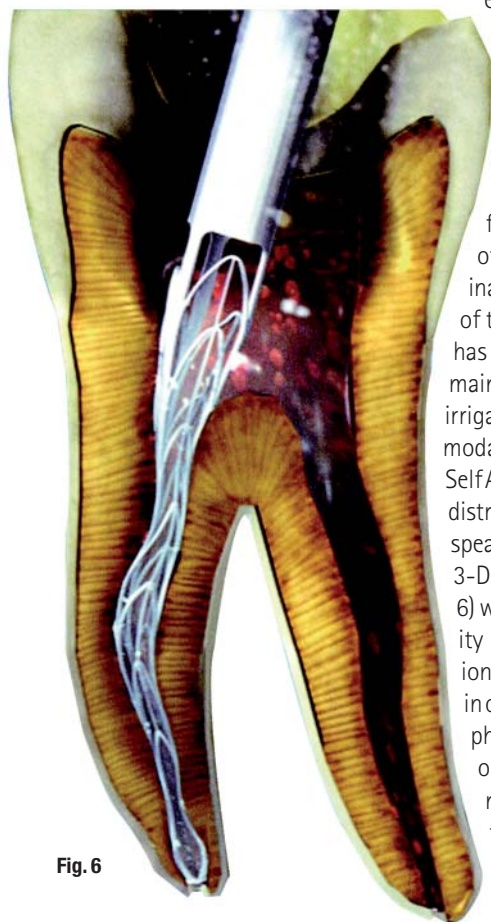
**Fig. 5a** MacroCannula aids in the removal of gross debris during treatment, especially in the mid-root to coronal areas.

**Fig. 5b** MicroCannula facilitates the removal of microscopic debris at the apical 1 mm of the root-canal system.



important apical region.<sup>18-22</sup> The device delivers the disinfecting solution to the coronal aspect of the pulpal system and draws the solution to the apical region of the pulpal system by way of evacuation. This technique allows for a safe, comprehensive irrigation of the entire root-canal system.<sup>23-25</sup> This technology overcomes the limitations of solution surface tensions and apical vapour locks that occur in deep, difficult-to-reach areas of pulpal systems.<sup>26</sup> In addition, the continuous movement of the solution increases microbial hydrolysis.<sup>27</sup>

**Fig. 6** SAF file offers us the ability to shape the morphology of individual pulpal systems in 3-D.



In the pursuit to increase successful outcomes, the progressive clinician must stay at the forefront of new treatment modalities that may increase our efficacy in attaining higher levels of disinfection. Traditional endodontic techniques are based on the theory that files shape and irrigation solutions clean.<sup>28</sup> We know the limitations of current rotary files in shaping the morphology of complex root-canal systems. On average, most file systems reach less than 50% of canal walls.<sup>29</sup> Therefore, our inability to reach many surfaces of the root-canal system physically has dictated that disinfection rely mainly on the many techniques of irrigation. However, a new treatment modality challenges this method. The SelfAdjusting File Endodontic System distributed by Henry Schein, Inc., spearheads this new direction into 3-D shaping. The SAF instrument (Fig. 6) was designed to reach the majority of pulpal walls in a 3-D fashion.<sup>30-31</sup> This potential quantum leap in our ability to reach all pulpal walls physically, significantly increases our efficacy in disinfection.<sup>32</sup> This may set forth a paradigm shift in the way we approach our shaping and disinfecting techniques.

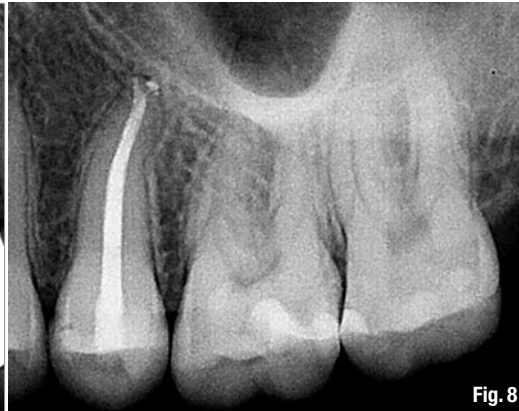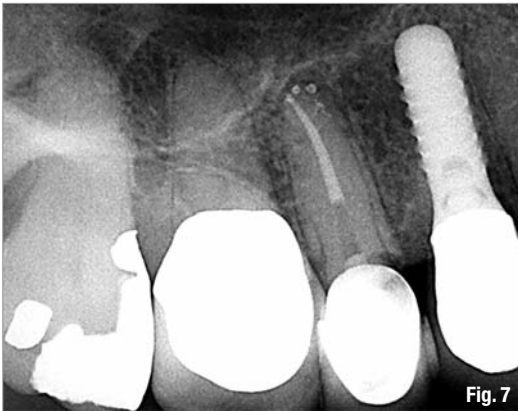### Higher success rates with the 3-D seal of the entire root-canal system—advances in the coronal seal

Once the 3-D intricacies of a root-canal system have been evaluated, shaped and disinfected, then success ultimately lies in our ability to seal this complex and vulnerable system from the pathogenic source of endodontic disease, the oral cavity.<sup>33-34</sup> Overall endodontic success rates would be higher if all clinicians placed the coronal seal immediately after the canals are sealed. This is the time when the isolated pulpal system is at its highest level of disinfection. We know that endodontic disease emanates from the oral cavity and we strive to disinfect and seal the smallest of crevices within canal systems, but what about the main portal of entry for these pathogens? Figure 7 illustrates a lack of respect for this well-understood requirement for success. A relatively similar case treated in Figure 8 has a significantly increased overall prognosis.

In addition to common sense, the amount of quality research that supports this imperative final objective of successful endodontic treatment is staggering.<sup>35-43</sup> A recent, impressive study was performed by one of the largest insurance companies in the US in an effort to evaluate the success of endodontic outcomes. In assessing over 1.4 million endodontic cases over an eight-year period, they found a success rate of 97%. Pretty impressive! However, it was also found that in the 3% of cases that failed, 85% did not have coronal coverage.<sup>44</sup> Imagine the achievable success rate of modern endodontic therapy should an immediate seal of the entire root-canal system become the standard of practice.

Endodontists should diligently educate those in their local dental community of the overwhelming importance of this immediate final phase of successful root-canal therapy. A universal practice of placing the coronal seal as a final phase of treatment will greatly enhance the success of our profession. The prudent endodontic practitioner should exclude any





**Fig. 7\_** This case illustrates a lack in respect for the need to place a proper coronal seal immediately after obturation.

**Fig. 8\_** This relatively similar case illustrates a significantly increased prognosis owing to the fulfilment of this final requirement for success.

knowledgeable clinician contributing to the patient's dental health, who does not respect this imperative objective for a successful outcome. Reasons for having a separate clinician complete the coronal seal at a later time are usually business related. These type of rationalisations do not adhere to our Hippocratic Oath to promote the best interests of the patient. Figures 9a and b illustrate the reproducible healing potential of lesions of endodontic origin when this final objective of successful endodontic therapy is accomplished.

The cornerstone of a successful coronal seal is the ability to obtain deep dentinal bonding. For accurate placement into deep, confined spaces, most-dual cured application tips can be augmented with a securely fastened etchant tip (Fig. 10). The etchant tip by Pulpdent (ref #22D100) works quite well in this regard. In order to maximise deep dentinal bonding, a dual-cured bonding agent should be used in conjunction with a dual-cured resin.<sup>45</sup> The typical sequence to attain maximum deep dentinal bonding after obturation is solvent, etchant, pre-bond, followed by the mixing of A and B. Owing to the compatibility of the materials, this older generation of bonding agents has been shown to have increased bond strength when used in conjunction with a dual-cured resin.<sup>45</sup>

In addition to providing the coronal seal of the root-canal system, deep dentinal bonding must also ensure the retention of the core. Each case should be individually assessed in this regard.

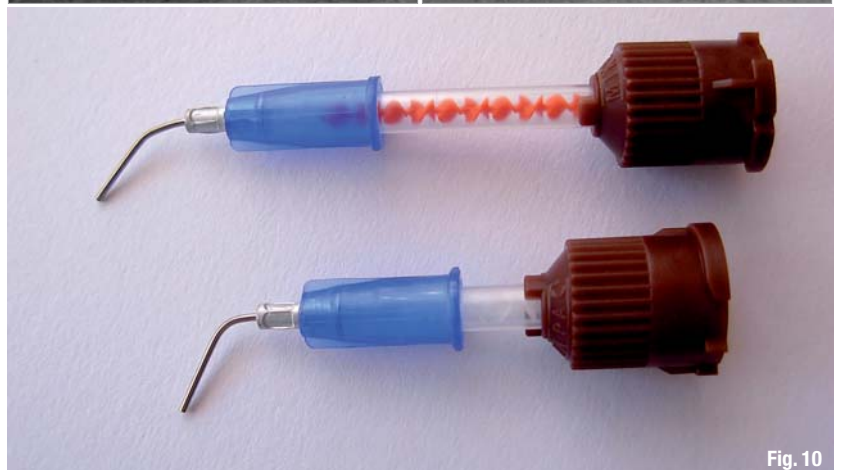
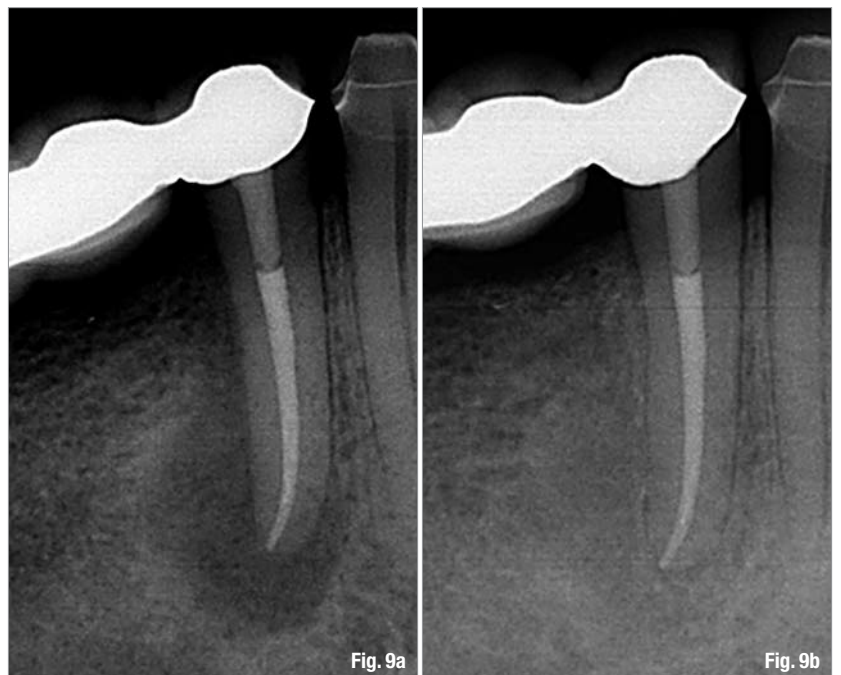### The future of endodontics

Currently, many are in favour of alternatives to the retention of natural teeth through successful endodontic therapy. Not since the focal infection era have we seen such ill-advised loss of viable teeth. These opponents of endodontic therapy feel that the field is a dying profession. They speak of root-canal therapy as a holding pattern for an implant. Indeed, this statement may be true when the requirements for suc-

cessful treatment are not strictly adhered to. Fortunately, dedicated clinicians have never been equipped with so many tools to diagnose correctly and treat complex endodontic disease. The ability to provide endodontic excellence is more attainable today because of our ability to see, disinfect and seal the entire root-canal system in 3-D.

**Figs. 9a & b\_** Deep dentinal bonding was accomplished with a dual-cured resin to complete the final requirement of successful endodontic therapy.

**Fig. 10\_** Most dual-cured application tips can be augmented with a securely fastened etchant tip to allow for deep placement into confined spaces.



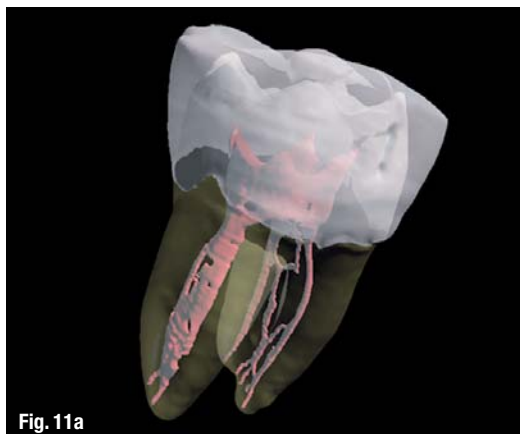


**Fig. 11a**\_Annotated 3-D model of a lower molar that illustrates complex pulpal anatomy.

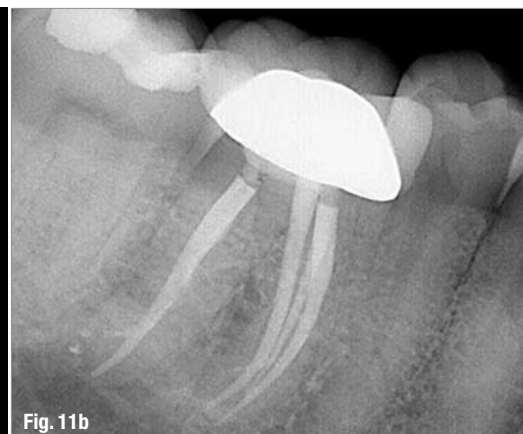**Fig. 11b**\_Endodontic therapy that illustrates the respect for the natural pulpal anatomy present.

**Fig. 12a**\_Post-op image of the ability to seal complicated pulpal anatomy.

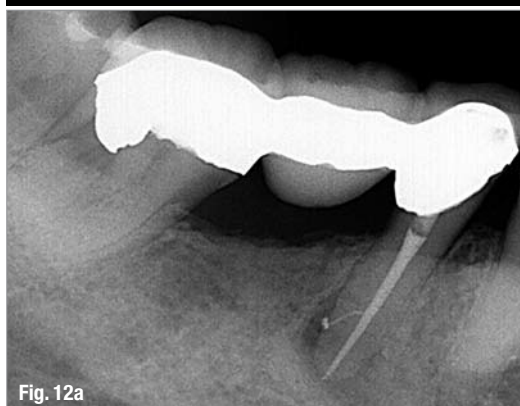**Fig. 12b**\_Healing observed when objectives for successful endodontic therapy are accomplished.



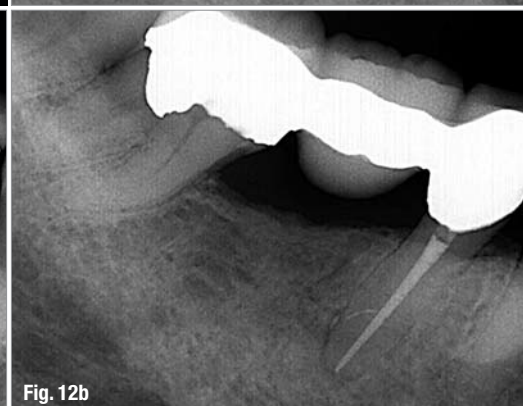
**Fig. 11a**



**Fig. 11b**



**Fig. 12a**



**Fig. 12b**

**Fig. 13**\_Illustration of the objective to have continual seal of the entire root-canal system from the apex to the cavo-surface.

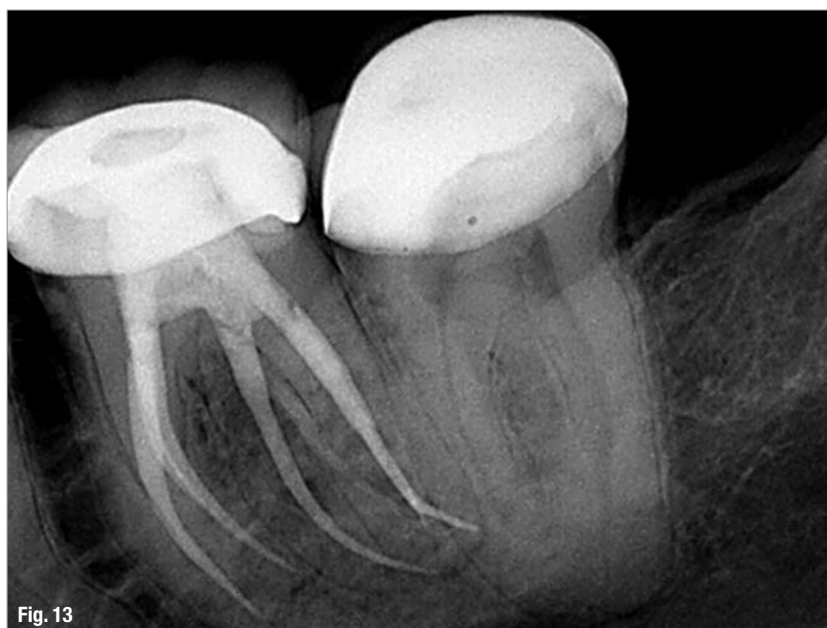Further advancement in our ability to visualise root-canal systems and the surrounding structures in 3-D will continue to revolutionise our capacity to diagnose and treat endodontic disease. The quality of endodontic therapy provided will increase as the science of CBCT develops. Future advancement in this science will focus on our ability to more clearly render and manipulate these images. Figure 11a is an annotated 3-D model of a lower molar that illustrates pul-

pal anatomy that is encountered in clinical practice.<sup>46</sup> Figure 11b displays the endodontic outcomes possible when such natural complexities are respected.

There are many exciting advancements on the horizon to aid in our pursuit of higher levels of disinfection. Further exploration into the potential to shape individual pulpal anatomy on a 3-D basis will continue. The science of irrigation may one day take us from disinfection to sterilisation. Figures 12a and b illustrate the successful outcome that can be accomplished when intricate areas of an infected root-canal system can be disinfected and sealed.

Future advancement in the pursuit of a precise coronal seal will be in the form of products and devices that aid in the technique-sensitive procedure of placing deep dentinal bonding. Figure 13 illustrates this objective of a continuous seal of the entire root-canal system from the apex to the cavo-surface.

These advances in endodontic treatment modalities will undoubtedly have a significant impact on our ability to attain greater success rates. However, the future of our profession is in the hands of skilled and committed clinicians who strive to move our profession forward. Progressive exploration into the areas discussed in this article will keep endodontic therapy at the forefront of treatment options available for patients.



**Fig. 13**

# implants

international magazine of oral implantology

## References

1. Doyle SL, Hodges JS, Pesun IJ, Baisden MK, Bowles WR. Factors affecting outcomes for single-tooth implants and endodontic restorations. *J Endod.* 2007 Apr;33(4):399–402.
2. Iqbal MK, Kim S. For teeth requiring endodontic treatment, what are the differences in outcomes of restored endodontically treated teeth compared to implant-supported restorations? *Int J Oral Maxillofac Implants.* 2007;22 Suppl: 96–116.
3. Estrela C, Bueno MR, Leles CR, Azevedo B, Azevedo JR. Accuracy of cone beam computed tomography and panoramic and periapical radiography for detection of apical periodontitis. *J Endod.* 2008 Mar;34(3):273–9.
4. Patel S, Dawood A, Mannocci F, Wilson R, Pitt Ford T. Detection of periapical bone defects in human jaws using cone beam computed tomography and intraoral radiography. *Int Endod J* 2009 Jun;42(6):507–15.
5. Tyndall DA, Rathore S. Cone-beam CT diagnostic applications: caries, periodontal bone assessment, and endodontic applications. *Dent Clin North Am.* 2008 Oct;52(4):825–41, vii.
6. Stavropoulos A, Wenzel A. Accuracy of cone beam dental CT, intraoral digital and conventional film radiography for the detection of periapical lesions. An ex vivo study in pig jaws. *Clin Oral Investig.* 2007 Mar;11(1):101–6.
7. Patel S. New dimensions in endodontic imaging: Part 2. Cone beam computed tomography. *Int Endod J.* 2009 Jun; 42(6): 463–75.
8. Low KM, Dula K, Bürgin W, von Arx T. Comparison of Periapical Radiography and Limited Cone-Beam Tomography in Posterior Maxillary Teeth Referred for Apical Surgery. *J Endod.* 2008;34(5):557–62.
9. Cotton TP, Geisler TM, Holden DT, Schwartz SA, Schindler WG. Endodontic applications of cone-beam volumetric tomography. *J Endod.* 2007 Sep;33(9):1121–32.
10. Schilder H. Filling root canals in three dimensions. *Dent Clin North Am.* 1967 Nov:723–44.
11. Schilder H. Canal debridement and disinfection. In *Pathways of the Pulp*. 1<sup>st</sup> Ed., St. Louis: Mosby Co., 1976:111–33.
12. Byström A, Sundqvist G. Bacteriologic evaluation of the efficacy of mechanical root canal instrumentation in endodontic therapy. *Scand J Dent Res.* 1981 Aug;89(4):321–8.
13. West JD. The relationship between three-dimensional endodontic seal and endodontic failure. Master Thesis. Boston: Boston University, 1975.
14. Matherne RP, Angelopoulos C, Kulild JC, Tira D. Use of cone-beam computed tomography to identify root canal systems in vitro. *J Endod.* 2008 Jan;34(1):87–9.
15. Hockett JL, Dommisch JK, Johnson JD, Cohenca N. Antimicrobial efficacy of two irrigation techniques in tapered and nontapered canal preparations: an in vitro study. *J Endod.* 2008 Nov;34(11):1374–7.
16. Brito PR, Souza LC, Machado de Oliveira JC, Alves FR, De-Deus G, Lopes HP, Siqueira JF Jr. Comparison of the effectiveness of three irrigation techniques in reducing intracanal *Enterococcus faecalis* populations: an in vitro study. *J Endod.* 2009 Oct;35(10):1422–7.
17. Miller TA, Baumgartner JC. Comparison of the antimicrobial efficacy of irrigation using the EndoVac to endodontic needle delivery. *J Endod.* 2010 Mar;36(3):509–11.



You can also subscribe via  
[www.oemus.com/abo](http://www.oemus.com/abo)

 **Subscribe now!**

I hereby agree to receive a free trial subscription of **implants international magazine of oral implantology** (4 issues per year). I would like to subscribe to **implants** for € 44 including shipping and VAT for German customers, € 46 including shipping and VAT for customers outside of Germany, unless a written cancellation is sent within 14 days of the receipt of the trial subscription. The subscription will be renewed automatically every year until a written cancellation is sent to OEMUS MEDIA AG, Holbeinstr. 29, 04229 Leipzig, Germany, six weeks prior to the renewal date.

▶ Reply via Fax +49 341 48474-290 to OEMUS MEDIA AG or per E-mail to: [grasse@oemus-media.de](mailto:grasse@oemus-media.de)

Last Name

First Name

Company

Street

ZIP/City/County

E-Mail

Signature

Notice of revocation: I am able to revoke the subscription within 14 days after my order by sending a written cancellation to OEMUS MEDIA AG, Holbeinstr. 29, 04229 Leipzig, Germany.

Unterschrift

OEMUS MEDIA AG  
 Holbeinstraße 29, 04229 Leipzig  
 Tel.: +49 341 48474-0  
 Fax: +49 341 48474-290  
 E-Mail: [grasse@oemus-media.de](mailto:grasse@oemus-media.de)

18. Baumgartner JC, Falkler WA Jr. Bacteria in the apical 5 mm of infected root canals. *J Endod.* 1991 Aug;17(8):380–3.
19. Susin L, Parente JM, Loushine RJ, Ricucci D, Bryan T, Weller RN, Pashley DH, Tay FR. Canal and isthmus debridement efficacies of two irrigant agitation techniques in a closed system. *IEJ (In Press)*.
20. Parente JM, Loushine RJ, Susin L, Gu L, Looney SW, Weller RN, Pashley DH, Tay FR. Root canal debridement using manual dynamic agitation or the EndoVac for final irrigation in a closed system and an open system. *IEJ (In Press)*.
21. Nielsen BA, Baumgartner CJ. Comparison of the EndoVac System to Needle Irrigation of Root Canals. *J Endod* 2007; 33(5):611–5.
22. Shin SJ, Kim HK, Jung IY, Lee CY, Lee SJ, Kim E. Comparison of the cleaning efficacy of a new apical negative pressure irrigating system with conventional irrigation needles in the root canals. *Oral Surg Oral Med Oral Pathol Oral Radiol Endod.* 2010 Mar;109(3):479–84.
23. Desai P, Himel V. Comparative Safety of Various Intracanal Irrigation Systems. *J Endod* 2009;35:545–9.
24. Mitchell RP, Yang SE, Baumgartner JC. Comparison of apical extrusion of NaOCl using the EndoVac or needle irrigation of root canals. *J Endod.* 2010 Feb;36(2):338–41.
25. Gondim E Jr, Setzer FC, Dos Carmo CB, Kim S. Postoperative pain after the application of two different irrigation devices in a prospective randomized clinical trial. *J Endod.* 2010 Aug; 36(8):1295–301.
26. Tay FR, Gu LS, Schoeffel GJ, Wimmer C, Susin L, Zhang K, Arun SN, Kim J, Looney SW, Pashley DH. Effect of vapor lock on root canal debridement by using a side-vented needle for positive-pressure irrigant delivery. *J Endod.* 2010 Apr;36(4):745–50.
27. Clegg MS, Vertucci FJ, Walker C, Belanger M, Britto LR. The effect of exposure to irrigant solutions on apical dentin biofilms in vitro. *J Endod.* 2006 May;32(5):434–7.
28. Baker NA, Eleazer PD, Averbach RE, Seltzer S. Scanning electron microscopic study of the efficacy of various irrigating solutions. *J Endod.* 1975 Apr;1(4): 127–35.
29. Peters OA, Schönerberger K, Laib A. Effects of four Ni-Ti preparation techniques on root canal geometry assessed by micro computed tomography. *Int Endod J.* 2001 Apr; 34(3):221–30.
30. Metzger Z, Zary R, Cohen R, Teperovich E, Paqué F. The Quality of Root Canal Preparation and Root Canal Obturation in Canals Treated with Rotary versus Self-adjusting Files: A three-dimensional micro-computed Tomographic Study. *J Endod.* 2010 Sep;36(9):1569–73.
31. Peters OA, Boessler C, Paqué F. Root canal preparation with a novel nickel-titanium instrument evaluated with micro-computed tomography: canal surface preparation over time. *J Endod.* 2010 Jun;36(6):1068–72.
32. Metzger Z, Teperovich E, Cohen R, Zary R, Paqué F, Hülsmann M. The self-adjusting file (SAF). Part 3: removal of debris and smear layer-A scanning electron microscope study. *J Endod.* 2010 Apr;36(4):697–702.
33. Kakehashi S, Stanley HR, Fitzgerald RJ. The effects of surgical exposures of dental pulps in germfree and conventional laboratory rats. *J South Calif Dent Assoc.* 1966 Sep;34(9):449–51.
34. Möller AJ, Fabricius L, Dahlén G, Ohman AE, Heyden G. Influence on periapical tissues of indigenous oral bacteria and necrotic pulp tissue in monkeys. *Scand J Dent Res.* 1981 Dec; 89(6):475–84.
35. Southard DW. Immediate core build-up of endodontically treated teeth: the rest of the seal. *Pract Periodontics Aesthet Dent.* 1999 May;11(4):519–26; quiz 528.
36. Tronstad L, Asbjørnsen K, Døving L, Pedersen I, Eriksen HM. Influence of coronal restorations on the periapical health of endodontically treated teeth. *Endod Dent Traumatol.* 2000 Oct;16(5):218–21.
37. Helling I, Gorfil C, Slutzky H, Kopolovic K, Zalkind M, Slutzky-Goldberg I. Endodontic failure caused by inadequate restorative procedures: review and treatment recommendations. *J Prosthet Dent.* 2002 Jun;87(6):674–8.
38. Weine FS. In *Endodontic Therapy*. 5th Ed., St. Louis: Mosby Co., 1996:4.
39. Ray HA, Trope M. Periapical status of endodontically treated teeth in relation to the technical quality of the root filling and the coronal restoration. *Int Endod J.* 1995 Jan;28(1):12–8.
40. Torabinejad M, Ung B, Kettering JD. In vitro bacterial penetration of coronally unsealed endodontically treated teeth. *J Endod.* 1990 Dec;16(12):566–9.
41. Alves J, Walton R, Drake D. Coronal leakage: endotoxin penetration from mixed bacterial communities through obturated, post-prepared root canals. *J Endod.* 1998 Sep;24(9):587–91.
42. Ricucci D, Gröndahl K, Bergenholtz G. Periapical status of root-filled teeth exposed to the oral environment by loss of restoration or caries. *Oral Surg Oral Med Oral Pathol Oral Radiol Endod.* 2000 Sep;90(3):354–9.
43. Swanson K, Madison S. An evaluation of coronal microleakage in endodontically treated teeth. Part I. Time periods. *J Endod.* 1987 Feb;13(2):56–9.
44. Salehrabi R, Rotstein I. Endodontic treatment outcomes in a large patient population in the USA: an epidemiological study. *J Endod.* 2004 Dec;30(12):846–50.
45. Schwartz RS, Fransman R. Adhesive dentistry and endodontics: materials, clinical strategies and procedures for restoration of access cavities: a review. *J Endod.* 2005 Mar;31(3):151–65.
46. Brown WP, Herbranson EJ. Brown and Herbranson Imaging: [www.brownherbransson.com/tutorial\\_atlas.shtml](http://www.brownherbransson.com/tutorial_atlas.shtml).

*Editorial note: Dr Simons performed all treatments presented in this article. He does not currently have an interest in any products discussed in this article. All CBCT images were taken with the Kodak 9000 3D CBCT and all 2-D images were taken with the Kodak 6100.*

## \_about the author

## roots



**Dr Wyatt D. Simons** is a diplomate of the American Board of Endodontists. After graduating from the University of the Pacific, Arthur A. Dugoni School of Dentistry, in 1999, he completed his specialty training in endodontics at Boston University in 2001. Dr Simons is an Adjunct Assistant Professor of Endodontics at the University of the Pacific and lectures nationally. In 2004, he founded Signature Specialists in San Clemente, California,

where he practises and presents live training seminars. Dr Simons is passionately committed to the advancement of the profession of endodontics. Most recently, he presented live treatment to the American Association of Endodontists (AAE) as part of the Master Clinician Series at the 2010 AAE conference. To learn more about Dr Simons, go to [www.signatureendo.com](http://www.signatureendo.com).

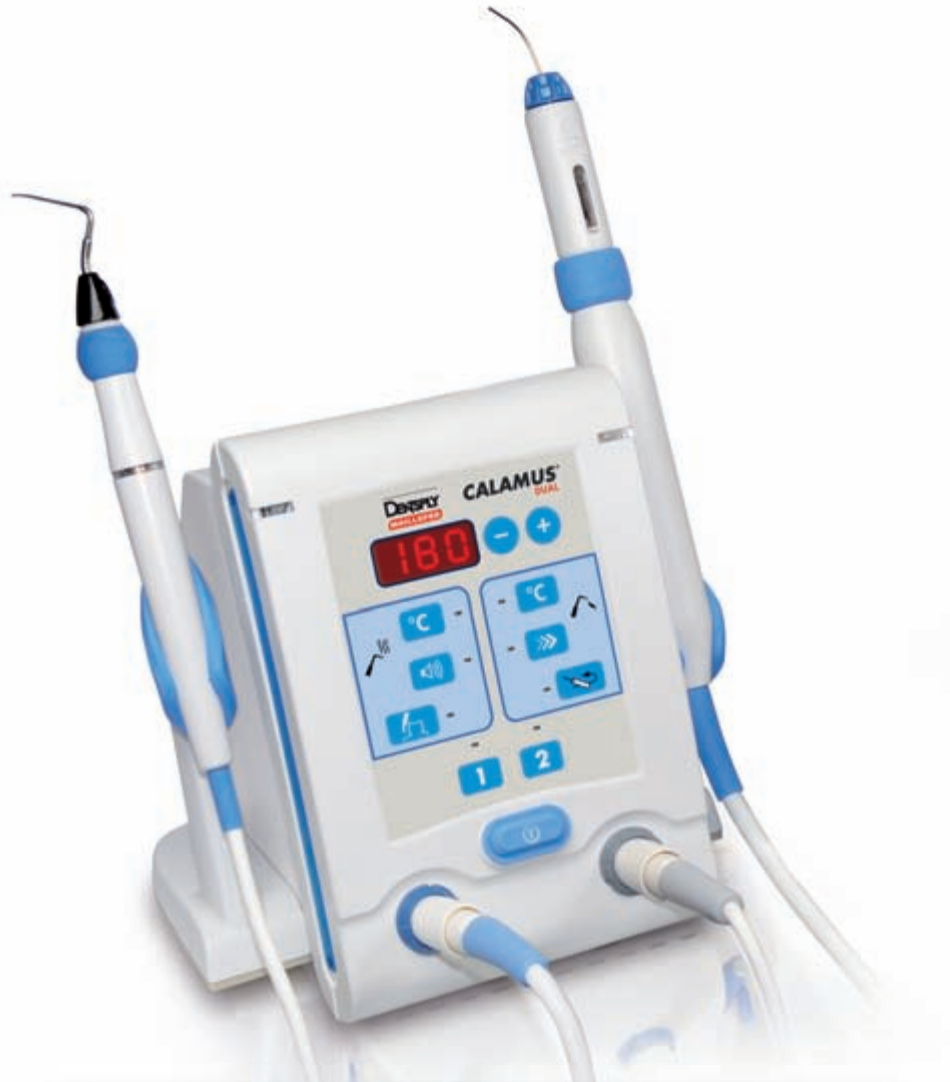



# CALAMUS<sup>®</sup> DUAL

DOWNPACK & BACKFILL

FAST AND TIGHTLY SEALED ROOT CANAL FILLINGS



## TIME-SAVING AND LONG-LASTING 3D OBTURATION OF ROOT CANALS

Filling was never so easy!

- Obturation device for downpack and backfill

Device designed for your comfort

- Ergonomically designed handpieces with large operation angle and feather-touch activation by flexible silicone ring

Lateral or vertical obturation? Better results with Calamus<sup>®</sup>

- Vertical condensation is a faster method to achieve a long-lasting, tightly sealed, three dimensional root canal filling
- Reliable obturation of lateral canals as well as minimal risk of root fractures

**DENTSPLY**  
**MAILLEFER**

[www.dentsplymailefer.com](http://www.dentsplymailefer.com)

# Transparent teeth: A powerful educational tool

Author\_ Dr Sergio Rosler, Argentina

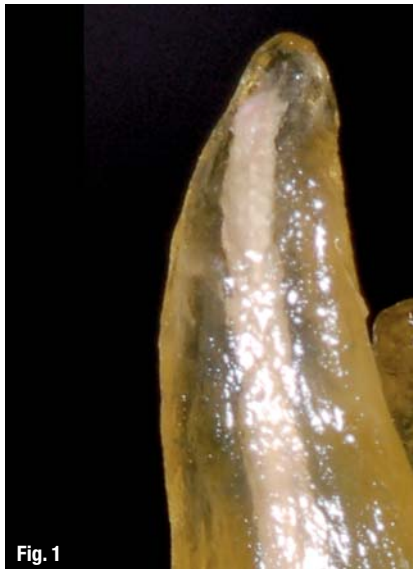

Fig. 1

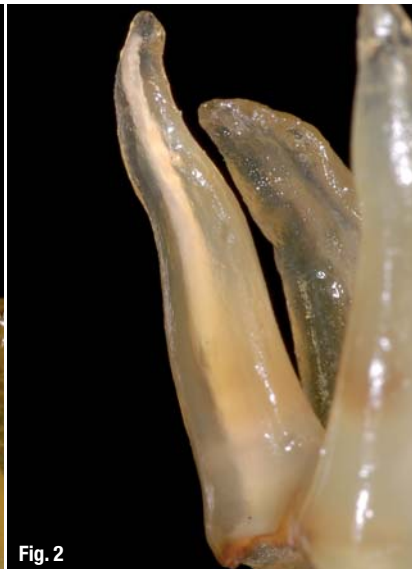

Fig. 2

Since the early days of dentistry, dentists have explored the morphology of the internal root anatomy. From the pre-X-ray period to the technology-driven present, the study and examination of the root-canal system has become an obsession for endodontists. Several methods such as radiographic<sup>1</sup> and histological examinations,<sup>2-3</sup> cross- and longitudinal sectioning,<sup>4</sup> and root-clearing techniques, to name a few, were widely used in the past. Today, different computerised tomography studies<sup>5</sup> and observations under dental operating microscopes<sup>6</sup> are performed to light up the dark confines of the dental pulp.

## The tooth-clearing technique

Over the last 100 years, the tooth-clearing technique was utilised in human dental pulp morphology studies, as it provides a 3-D view of the pulp cavity in relation to the exterior of the teeth and allows a

thorough examination of the pulp chambers and root canals.<sup>7-9</sup> It was also utilised in the study of apical leakage.<sup>10</sup> Today, the clearing technique remains useful only as a teaching and research tool, with little or no clinical applicability.<sup>11</sup>

In 1913, Hermann Prinz successfully cleared teeth using the protocol proposed by Spaltholz in 1906.<sup>12</sup> Okumura performed in-depth studies of the pulp anatomy and classified the canals according to their distribution and prevalence.<sup>13</sup> In order to simplify the canal system visually, he injected ink into the pulp cavity.<sup>13</sup> Samples can also be stained with Haematoxylin and Eosin, which are largely used to colour histological preparations. Compared with other procedures such as radiographic and histological examinations, the tooth-clearing technique has the following advantages:

- \_ retains the original form of the root;
- \_ enables the observation of minute details of the root-canal morphology;
- \_ is inexpensive;
- \_ samples can be conserved for a long time; and
- \_ is easy to perform.

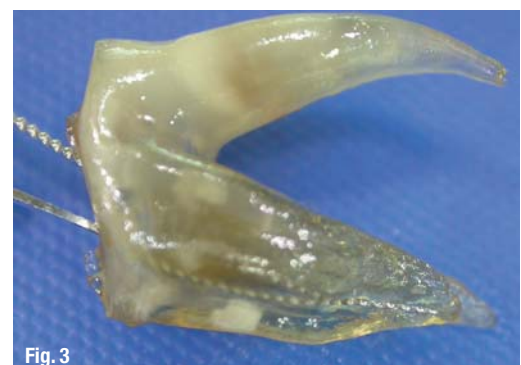


Fig. 3

The clearing process consists of three basic steps: demineralisation, dehydration and clearing of the root structure.<sup>14-15</sup>

#### Sample preparation

- \_ Store extracted teeth in 10% formal saline until use.<sup>11</sup>
- \_ Scale calculus and any remains of periodontal tissue.
- \_ Decoronate samples and negotiate canals with a #10 file (this will enhance acid penetration).
- \_ Store samples in 4.2% NaOCl solution (the organic tissue removal can be enhanced by placing the solution with the samples in the Ultrasonic Cleaner for 20 minutes).
- \_ Wash under running water and dry.
- \_ Indian ink can be drawn through the root-canal system by applying negative pressure to the apical end.

#### Demineralisation

- \_ Store samples in 5% nitric acid (HNO<sub>3</sub>) for three days.
- \_ Change solution every eight hours.
- \_ Manual or mechanical agitation promotes even demineralisation of the root.
- \_ Wash samples under running water for four hours<sup>16</sup> to clean.

#### Dehydration

- \_ Dehydrate samples by using ascending grades of alcohol: 60% ethanol for eight hours, 80% ethanol for four hours, and 96.6% ethanol for two hours.
- \_ Dry samples with paper towels.


#### Clearing

- \_ The sample should be placed in xylene for two hours to harden prior to placing the samples in methyl salicylate to render them transparent.<sup>16</sup> (This step is essential if samples are going to be used for practising instrumentation or obturation techniques.)
- \_ Store samples in methyl salicylate in order to preserve their transparency.

*Please note:* Always use proper protection when handling these dangerous solutions. Disposal of the used solutions should be done according to country regulations.

#### Educational tool

Successful root-canal treatment depends on adequate cleaning, shaping and filling of the root-canal system. However, in order to achieve this goal, it is imperative that the operator has a detailed knowledge of the root-canal morphology of each individual




tooth that is treated. Demineralised and cleared teeth may become a very valuable aid in the teaching of endodontic techniques. Hasselgren and Tronstad<sup>17</sup> used cleared teeth to teach and practise instrumentation and obturation procedures in a preclinical course at Lund University, Sweden. At the end of the course, the students were asked to give their opinions regarding the use of the transparent teeth in the learning process. The reaction was very favourable and encouraged the head of the department to extend the use of cleared teeth in following courses.<sup>17</sup>

Dipping the samples in xylene for two hours, as suggested by Robertson in 1980, prior to placing them in methyl salicylate will return dentine hardness to values slightly lower than those found in normal dentine.<sup>16</sup> This yields new possibilities for dentists eager to learn, who wish to practise new techniques, procedures and protocols, from rotary instrumentation with NiTi files to thermoplastic obturation with warm gutta-percha. Dentists are able to see what is actually happening with much greater detail, which is a significant improvement to working with a simulated canal in plastic blocks. Additionally, the tactile feeling experienced is very similar to the real clinical situation.

In summary, this simple and inexpensive technique will enable dentists to visualise the root-canal morphology in detail while allowing them to practise almost every endodontic procedure desired.

*Editorial note:* A list of references is available from the publisher.

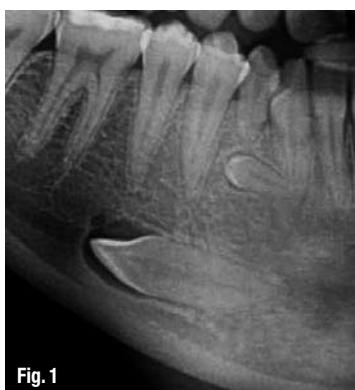_contact	roots
	
<p><b>Dr Sergio Rosler</b> graduated from the University of Buenos Aires, Argentina, in 1996, and had become a specialist in Endodontics by 2005. He has been a specialist in Oral Implantology since 2009 and works in private practice in Buenos Aires. He can be contacted at <a href="mailto:sarosler@hotmail.com.ar">sarosler@hotmail.com.ar</a>.</p>	



# CBCT applications in dental practice: A literature review

**Authors\_** Dr Mohammed A. Alshehri, Dr Hadi M. Alamri & Dr Mazen A. Alshalhoob, Saudi Arabia

**\_Two-dimensional imaging modalities** have been used in dentistry since the first intra-oral radiograph was taken in 1896. Significant progress in dental imaging techniques has since been made, including panoramic imaging and tomography, which enable reduced radiation and faster processing times. However, the imaging geometry has not changed with these commonly used intra-oral and panoramic technologies.



**Fig. 1**

**Fig. 1\_** Impacted teeth in close proximity to vital structures should be evaluated with CBCT.

Cone-beam computed tomography (CBCT) is a new medical imaging technique that generates 3-D images at a lower cost and absorbed dose compared with conventional computed tomography (CT). This imaging technique is based on a cone-shaped X-ray beam centred on a 2-D detector that performs one rotation around the object, producing a series of 2-D images. These images are re-constructed in 3-D using a modification of the original cone-beam algorithm developed by Feldkamp *et al.* in 1984.<sup>1</sup> Images of the craniofacial region are often collected with a higher resolution than those collected with a conventional CT. In addition, the new systems are more practical, as they come in smaller sizes.<sup>2</sup>

**Figs. 2a & b\_** Peri-apical lesion shown as peri-apical radiograph (a) and CBCT (b); images courtesy of Dr Fred Barnett).

Today, much attention is focused on the clinical applications—diagnosis, treatment and

follow-up—of CBCT in the various dental disciplines. The goal of the following systemic review is to review the available clinical and scientific literature pertaining to different clinical application of CBCT in the dental practice.

## **\_Materials and methods**

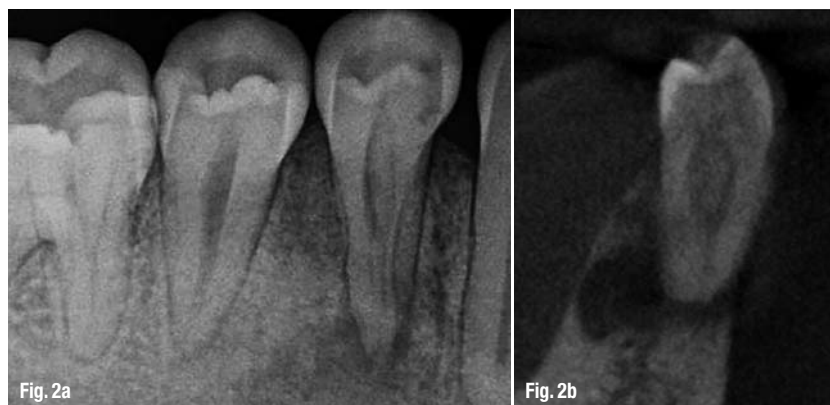
Clinical and scientific literature discussing CBCT imaging in dental clinical applications was reviewed. A MEDLINE (*PubMed*) search from 1 January 1998 to 15 July 2010 was conducted. *Cone-beam computed tomography in dentistry* was used as key phrase to extend the search to all the various dental disciplines. The search revealed 540 papers that were screened in detail. Owing to a lack of relevance to the subject, 406 papers were excluded. Thus, the systemic review consisted of 134 clinically relevant papers, which were analysed and categorised (Table I).

## **\_Analysis**

### *Oral and maxillofacial surgery*

CBCT enables the analysis of jaw pathology,<sup>3-11</sup> the assessment of impacted teeth (Fig. 1), supernumerary teeth and their relation to vital structures,<sup>6,12-21</sup> changes in the cortical and trabecular bone related to bisphosphonate-associated osteonecrosis of the jaw<sup>5,22-23</sup> and the assessment of bone grafts.<sup>24</sup> It is also helpful in analysing and assessing paranasal sinuses<sup>6,25</sup> and obstructive sleep apnea.<sup>27-28</sup>

As the images are collected from many different 2-D slices, the system has proven its superiority in overcoming superimpositions and calculating surface distances.<sup>28-29</sup> This advantage made it the technique of choice in mid-face fracture cases,<sup>30-31</sup> orbital fracture assessment and management<sup>32</sup> and for inter-operative visualisation of the facial bones after fracture.<sup>33-34</sup> Since it is not a magnetic resonance technique, it is the best option for intra-operative navigation during procedures, including gun-shot wounds.<sup>35-36</sup>



**Fig. 2a**

**Fig. 2b**

CBCT is largely used in orthognathic surgery planning when facial orthomorphic surgery is indicated that requires detailed visualisation of the inter-occlusal relationship in order to augment the 3-D virtual skull model with a detailed dental surface. With the aid of advanced software, CBCT facilitates the visualisation of soft tissue to allow for control of post-treatment aesthetics, for example in cleft palate cases to evaluate lip and palate bony depressions.<sup>37-42</sup>

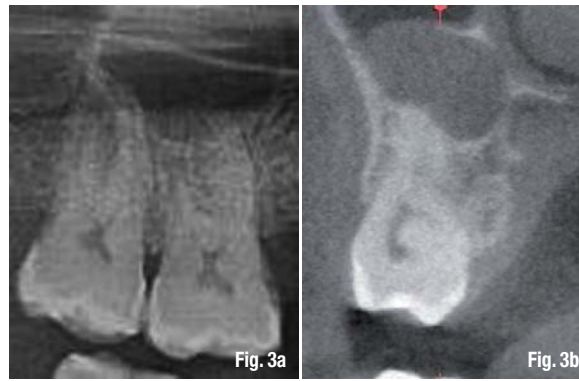Research is underway to assess its ability to detect salivary gland defects.<sup>43</sup> Honda *et al.*<sup>44</sup> describe a clinical case in which the time needed to complete a tooth auto-transplant case was significantly shortened owing to the application of CBCT.

*Endodontics*

CBCT is a very useful tool in diagnosing apical lesions (Figs. 2a & b).<sup>21,45-56</sup> A number of studies have demonstrated its ability to enable a differential diagnosis of apical lesions by measuring the density from the contrasted images of these lesions, in whether the lesion is an apical granuloma or an apical cyst (Figs. 3a & b).<sup>49,55-57</sup> Cotton *et al.*<sup>46</sup> used CBCT as a tool to assess whether the lesion was of endodontic or non-endodontic origin.

CBCT also demonstrated superiority to 2-D radiographs in detecting fractured roots. Vertical and horizontal root fracture detection is described in several clinical cases.<sup>21,46,55-59</sup> It is also agreed that CBCT is superior to peri-apical radiographs in detecting these fractures, whether they are bucco-lingual or mesiodistal.<sup>60-61</sup>

In cases with inflammatory root resorption, lesions are detected much easier in early stages with CBCT compared to conventional 2-D X-ray.<sup>21,62</sup> In other cases, such as external root resorption, external cervical and internal resorption, not only the presence of resorption was detected, but also the extent of it.<sup>21,46,54,56,63-64</sup>



CBCT can also be used to determine root morphology, the number of roots, canals and accessory canals, as well as to establishing the working length and angulations of roots and

**Figs. 3a & b** Apical cyst shown as orthopantomogram (a) and CBCT (b).

Specialty	Number of articles	in %
Oral and maxillofacial surgery	36	26.86
Endodontics	32	23.88
Implantology	22	16.42
Orthodontics	16	11.94
General dentistry	14	10.45
Temporomandibular joint disorder	8	5.97
Periodontics	5	3.73
Forensic dentistry	1	0.75

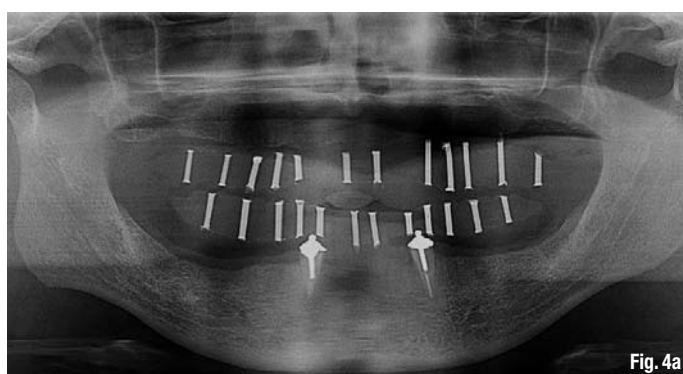
**Table I**

canals.<sup>21,25,46,55-56,58,65-67</sup> It also is accurate in assessing root-canal fillings.<sup>47,51,56,58</sup> Owing to its accuracy, it is very helpful in detecting the pulpal extensions in talon cusps<sup>68</sup> and the position of fractured instruments.<sup>69</sup>

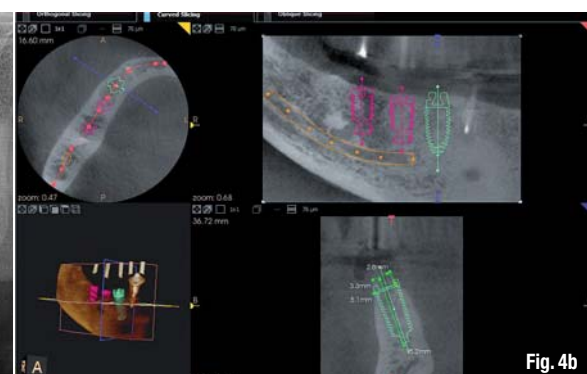
It is also a reliable tool for pre-surgical assessment of the proximity of the tooth to adjacent vital structures, size and extent of lesions, as well as the anatomy and morphology of roots with very accurate measurements.<sup>21,46,48,50,54-58,69-72</sup>

**Fig. 4a** Orthopantomogram for a full-mouth rehabilitation case. Only limited data can be obtained from this image.

**Fig. 4b** CBCT images for the same patient. Data obtained from these images regarding bone quality, implant length and diameter, implant location and proximity to vital structures is magnificent.



**Fig. 4a**


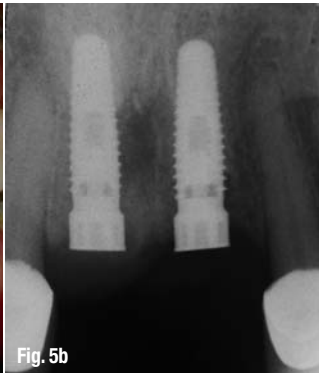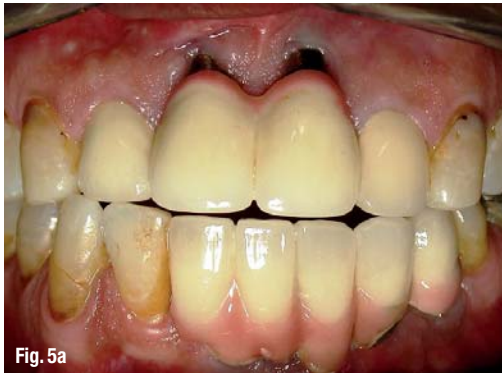


**Fig. 4b**

Additionally, in cases in which teeth are assessed after trauma and in emergency cases, its application can be a useful aid in reaching a proper diagnosis and treatment approach.<sup>46,55,73-74</sup>

Recently, owing to its reliability and accuracy, CBCT has also been used to evaluate the

CBCT is a reliable tool in the assessment of the proximity to vital structures that may interfere with orthodontic treatment.<sup>104-105</sup> In cases in which mini-screw implants are placed to serve as a temporary anchorage, CBCT is useful for ensuring a safe insertion<sup>106-108</sup> and to assess the bone density before, during and after treatment (Fig. 6).<sup>109-110</sup>



**Fig. 5a** Clinical picture of multiple implants placed in 2005.

**Fig. 5b** Peri-apical radiograph for the implants replacing teeth #8 and #9. Little data can be collected from such an image.

**Fig. 5c** The CBCT image clearly demonstrates the amount of bone loss.

canal preparation in different instrumentation techniques.<sup>75-76</sup>

### Implantology

With increased demand for replacing missing teeth with dental implants, accurate measurements are needed to avoid damage to vital structures. This was achievable with conventional CT. However, with CBCT giving more accurate measurements at lower dosages, it is the preferred option in implant dentistry today (Figs. 4a & b).<sup>2,6,11,18,70,77-89</sup>

With new software that constructs surgical guides, damage is also reduced further.<sup>77,84,90-93</sup> Heiland *et al.*<sup>94</sup> describe a technique in which CBCT was used inter-operatively in two cases to navigate the implant insertion following microsurgical bone transfer.

CBCT enables the assessment of bone quality and bone quantity.<sup>18,26,70,80-81,85,88,95-97</sup> This leads to reduced implant failure, as case selection can be based on much more reliable information. This advantage is also used for post-treatment evaluation and to assess the success of bone grafts (Figs. 5a-d).<sup>18,88</sup>

### Orthodontics

Orthodontists can use CBCT images in orthodontic assessment and cephalometric analysis.<sup>6,70,84,98-99</sup> Today, CBCT is already the tool of choice in the assessment of facial growth, age, airway function and disturbances in tooth eruption.<sup>100-103</sup>

Having different views in one scan, such as frontal, right and left lateral, 45-degree views and sub-mental, also adds to the advantages of CBCT.<sup>111,124</sup> As the images are self-corrected from the magnification to produce orthogonal images with 1:1 ratio, higher accuracy is ensured. CBCT is thus considered a better option for the clinician.<sup>113</sup>

### Temporomandibular joint disorder

One of the major advantages of CBCT is its ability to define the true position of the condyle in the fossa, which often reveals possible dislocation of the disk in the joint, and the extent of translation of the condyle in the fossa.<sup>18,56,114</sup> With its accuracy, measurements of the roof of the glenoid fossa can be done easily.<sup>115-116</sup> Another advantage of some of the available devices is their ability to visualise soft tissue around the TMJ, which may reduce the need for magnetic resonance imaging in these cases.<sup>117</sup>

Owing to these advantages, CBCT is the imaging device of choice in cases of trauma, pain, dysfunction, fibro-osseous ankylosis and in detecting condylar cortical erosion and cysts.<sup>70,87,118-120</sup> With the use of the 3-D features, the image-guided puncture technique, which is a treatment modality for TMJ disk adhesion, can safely be performed.<sup>121</sup>

### Periodontics

CBCT can be used in assessing a detailed morphologic description of the bone because it has proved to be accurate with only minimal error



margins.<sup>56,122</sup> The measurements proved to be as accurate as direct measurements with a periodontal probe.<sup>56,123</sup> Furthermore, it also aids in assessing furcation involvements.<sup>20,56,116</sup>

CBCT can be used to detect buccal and lingual defects, which was previously not possible with conventional 2-D radiographs.<sup>56,124</sup> Additionally, owing to the high accuracy of CBCT measurements, intra-bony defects can accurately be measured and dehiscence, fenestration defects and periodontal cysts assessed.<sup>56,125-127</sup> CBCT has also proved its superiority in evaluating the outcome of regenerative periodontal therapy.<sup>124</sup>

*General dentistry*

Based on the available literature, CBCT is not justified for use in detecting occlusal caries, since the dose is much higher than conventional radiographs with no additional information gained. However, it proved to be useful in assessing proximal caries and its depth.<sup>20</sup> Table II shows examples of typical doses of various dental radiological procedures in dental practice.

*Forensic dentistry*

Many dental age estimation methods, which are a key element in forensic science, are described in the literature. CBCT was established as a non-invasive method to estimate the age of a person based on the pulp-tooth ratio.<sup>128</sup>

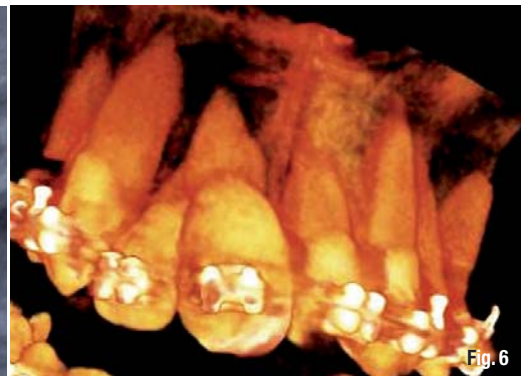
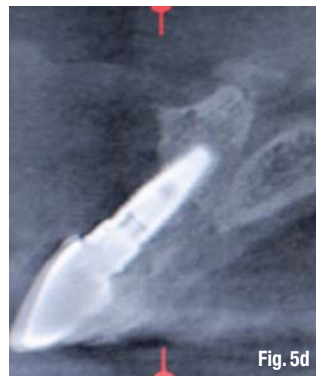**Discussion**

CBCT scanners represent a great advance in dento-maxillofacial (DMF) imaging. This technology, introduced into dental use in the late 1990s,<sup>129</sup> has advanced dentistry significantly. The number of CBCT-related papers published each year has increased tremendously in the last years. The above systematic review of the literature related to CBCT-imaging applications in dental practice was undertaken in order to summarise concisely the indications of this new image technique in different dental specialties.

*Cone-beam computed tomography in dentistry* was used as key phrase in this systemic review. Other terminology encountered in the literature, such as cone-beam volumetric scanning, volumetric computed tomography, dental CT, dental 3-D CT and cone-beam volumetric imaging, did not result in additional relevant papers.<sup>130</sup>

The clinical applications for CBCT imaging in dentistry are increasing. The results of this review

demonstrate that 134 papers were clinically relevant and that the most common clinical applications are in the field of oral and maxillofacial surgery, implant dentistry, and endodontics. CBCT has limited use in operative dentistry owing to the high radiation dose required in relation to its diagnostic value.



The literature on CBCT is promising and needs further research, especially with regard to its use in forensic dentistry, in order to explore more potentially beneficial indications in that area. No literature concerning direct CBCT indications in prosthodontics was found. However, several overlapping indications were found in other dental specialties attributing to the final standard of care in prosthodontic treatment. These indications include but are not limited to bone grafting, soft-tissue grafting, prosthetically driven implant placement, maxillofacial prosthodontics and temporomandibular joint disorder. CBCT images can also be of great value in special cases in which multiple teeth have to be assessed for restorability (Figs. 7a-e).

The latest CBCT units have a higher resolution, lower exposure, are less expensive and designed for use in dentistry. Additionally, the flat-panel detectors appear to be less prone to beam-hardening artefacts. There are, however, several important disadvantages as well, such as susceptibility to

**Fig. 5d** Total buccal plate destruction is evident in this CBCT image.

**Fig. 6** CBCT image to assess the bone density during treatment.

**Table II** Typical doses of various dental radiological procedures.

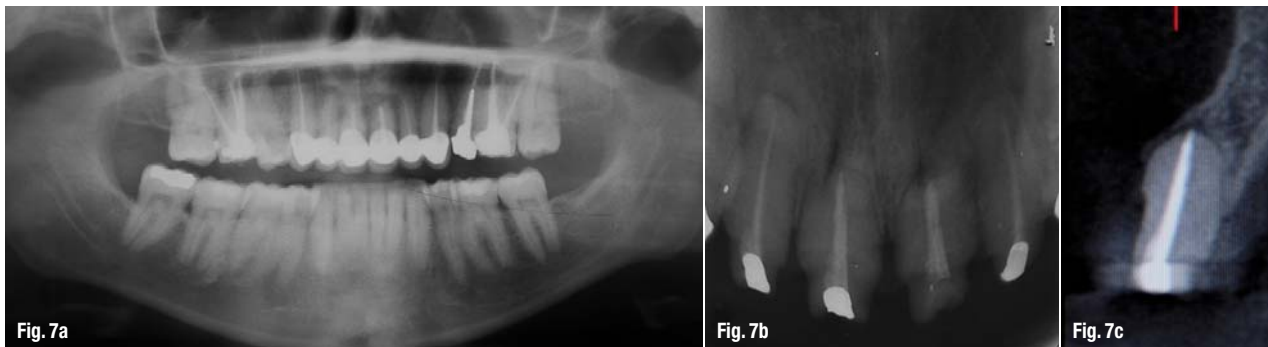
Intra-oral (F speed, rectangular collimator)	0.001 mSv
Intra-oral (E speed, round collimator)	0.004 mSv
Full-mouth set (E speed, round collimator)	0.080 mSv
Lateral cephalogram (F speed, rare-earth screen)	0.002 mSv
Dental panoramic technique (F speed, rare-earth screen)	0.015 mSv
CBCT (both jaws)	0.068 mSv
Hospital CT scan (both jaws)	0.6 mSv

**Table II**

movement artefacts, low contrast resolution, limited capability to visualise internal soft tissues and, owing to distortion of Hounsfield Units, CBCT cannot be used for the estimation of bone density.

It is crucial that the ALARA principle (As Low As Reasonably Achievable) is respected during

3. CBCT examinations should potentially add new information to aid the patient's management.
4. CBCT should not be repeated on a patient 'routinely' without a new risk/benefit assessment having been performed.
5. When accepting referrals from other dentists for CBCT examinations, the referring dentist must supply sufficient clinical information



**Fig. 7a** Multiple endodontically treated teeth with a history of peri-apical surgery.  
**Fig. 7b** Peri-apical image showing a compromised crown-to-root ratio.  
**Fig. 7c** CBCT image showing the absence of the buccal plate and a compromised palatal plate, indicating that the teeth need to be extracted and site grafting performed before implant placement.

treatment, as far as the radiation dose of CBCT imaging is concerned. CBCT imaging will improve patient care, but users have to be trained to be able to interpret the scanned data thoroughly. Dentists should ask themselves whether these imaging modalities actually add to their diagnostic knowledge and raise the standard of dental care or whether they only place the patient at a higher risk. Continuous training, education and thorough research are thus absolutely essential.

One of the most clinically useful aspects of CBCT imaging is the highly sophisticated software that allows the huge volume of data collected to be broken down, processed or reconstructed.<sup>131</sup> This makes data interpretation much more user friendly, if the appropriate technical and educational knowledge is available.

The increasing popularity of CBCT resulted in numerous CBCT-unit manufacturers, frequent presentations at conferences and an increase in published papers. This resulted in an uncontrolled and non-evidence based exchange of radiation dose values and attributed to the limited technical knowledge about medical imaging devices for new-user groups. As a result, the European Academy of DentoMaxilloFacial Radiology has developed the following basic principles on the use of CBCT in dentistry:<sup>132</sup>

1. CBCT examinations must not be carried out unless a history and clinical examination have been performed.
2. CBCT examinations must be justified for each patient to demonstrate that the benefits outweigh the risks.

(results of a history and examination) to allow the CBCT practitioner to perform the justification process.

6. CBCT should only be used when the question for which imaging is required cannot be answered adequately by lower dose conventional (traditional) radiography.
7. CBCT images must undergo a thorough clinical evaluation (radiological report) of the entire image dataset.
8. Where it is likely that evaluation of soft tissues will be required as part of the patient's radiological assessment, the appropriate imaging should be conventional medical CT or MR, rather than CBCT.
9. CBCT equipment should offer a choice of volume sizes, and examinations must use the smallest that is compatible with the clinical situation, if this provides a lower radiation dose to the patient.
10. Where CBCT equipment offers a choice of resolution, the resolution compatible with an adequate diagnosis and the lowest achievable dose should be used.
11. A quality assurance programme must be established and implemented for each CBCT facility, including equipment, techniques and quality-control procedures.
12. Aids to accurate positioning (light-beam markers) must always be used.
13. All new installations of CBCT equipment should undergo a critical examination and detailed acceptance tests before use to ensure that radiation protection for staff, members of the public and patient are optimal.
14. CBCT equipment should undergo regular routine tests to ensure that radiation protection,





# FDI Annual World Dental Congress

NEW HORIZONS IN ORAL HEALTH CARE

14 - 17 SEPT. 2011



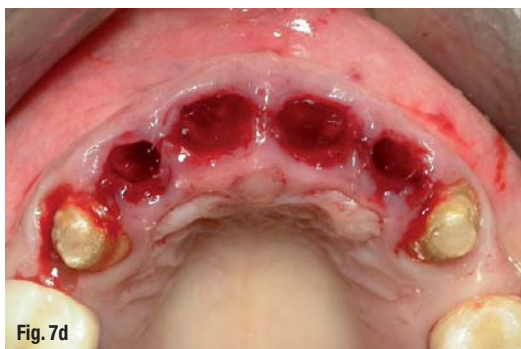[www.fdi2011.org](http://www.fdi2011.org)

[info@fdi2011.org](mailto:info@fdi2011.org)



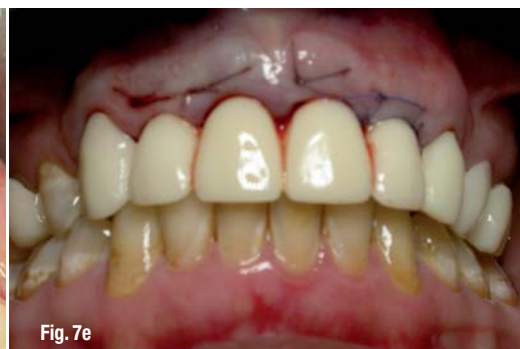for both practice/facility users and patients, has not significantly deteriorated.

15. For staff protection from CBCT equipment, the guidelines detailed in Section 6 of the European Commission document *Radiation protection 136: European guidelines on radiation protection in dental radiology* should be followed.



**Fig. 7d** Extractions done for teeth #7, 8, 9 and 10 were atraumatic and bone grafting was performed.

**Fig. 7e** Temporisation done and healing of the grafted sites for future implant placement is awaited.



logist or by a clinical radiologist (medical radiologist).

## Conclusion

CBCT is most frequently applied in oral and maxillofacial surgery, endodontics, implant dentistry and orthodontics. CBCT examination must

16. All those involved with CBCT must have received adequate theoretical and practical training for the purpose of radiological practices and relevant competence in radiation protection.
17. Continuing education and training after qualification are required, particularly when new CBCT equipment or techniques are adopted.
18. Dentists responsible for CBCT facilities, who have not previously received 'adequate theoretical and practical training', should undergo a period of additional theoretical and practical training that has been validated by an academic institution (university or equivalent). Where national specialist qualifications in dento-maxillofacial radiology exist, the design and delivery of CBCT training programmes should involve a DMF radiologist.
19. For dento-alveolar CBCT images of the teeth, their supporting structures, the mandible and the maxilla up to the floor of the nose (for example, 8 cm x 8 cm or smaller fields of view), clinical evaluation (radiological report) should be done by a specially trained DMF radiologist or, where this is impracticable, an adequately trained general dental practitioner.
20. For non-dento-alveolar small fields of view (for example, temporal bone) and all craniofacial CBCT images (fields of view extending beyond the teeth, their supporting structures, the mandible, including the TMJ, and the maxilla up to the floor of the nose), clinical evaluation (radiological report) should be done by a specially trained DMF radio-

not be carried out unless its medical necessity is proven and the benefits outweigh the risks. Furthermore, CBCT images must undergo a thorough clinical evaluation (radiological report) of the entire image dataset in order to maximise the benefits.

Future research should focus on accurate data with regard to the radiation dose of these units. CBCT units have small detector sizes and the field of view and scanned volumes are limited, which is the reason that CBCT units specific to orthodontic and orthognathic surgery are not yet available. Additional publications on CBCT indications in forensic dentistry and prosthodontics are also desirable.

*Editorial note: A complete list of references is available from the publisher.*

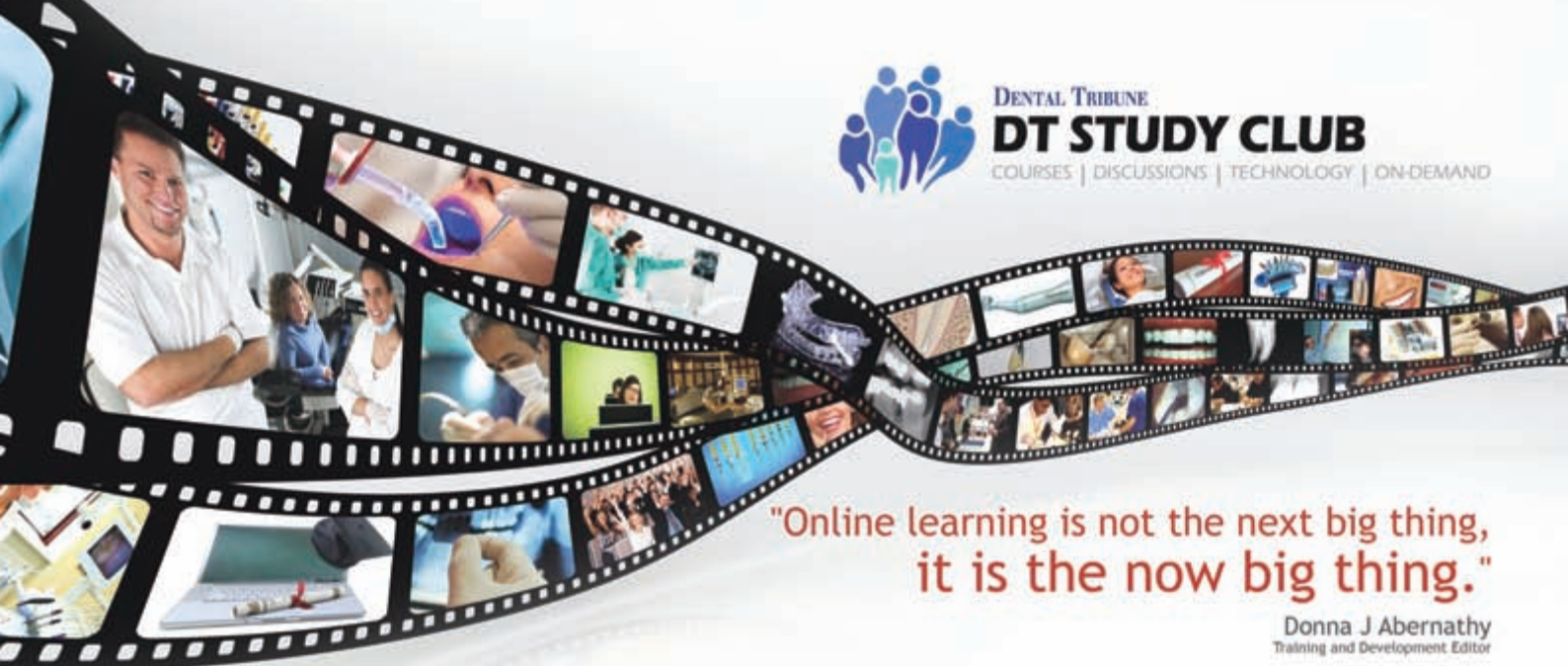<b>_about the authors</b>	<b>CAD/CAM</b>
<p><b>Dr Mohammed A. Alshehri</b> is a Consultant for Restorative and Implant Dentistry at the Riyadh Military Hospital, Department of Dentistry and Assistant Clinical Professor at the King Saud University, College of Dentistry, Department of Restorative Dental Sciences. He can be contacted at dr_mzs@hotmail.com.</p> <p><b>Dr Hadi M. Alamri</b> and <b>Dr Mazen A. Alshalhoob</b> are interns at Riyadh Colleges of Dentistry and Pharmacy.</p>	



DENTAL TRIBUNE

# DT STUDY CLUB

COURSES | DISCUSSIONS | TECHNOLOGY | ON-DEMAND



**"Online learning is not the next big thing,  
it is the now big thing."**

Donna J Abernathy  
Training and Development Editor

## DTSC - COURSES, COMMUNITY, TECHNOLOGY, ON-DEMAND

The DT Study Club makes all of this possible from the comfort of your own computer and without travel expenses. In other words, welcome to the community!

The purpose of this study club is to provide practitioners like yourself an opportunity to learn and network with like-minded colleagues in a friendly, non-threatening environment. We encourage you to take advantage of Dental Tribune's global outreach to access a variety of fresh perspectives and cultures, enhancing your educational mix.

### 24/7 LIVE AND INTERACTIVE ONLINE COURSES

Fulfill your yearly CE requirements with our growing list of archived ADA CERP approved courses.



### DISCUSSION FORUMS

focused on helping today's practitioners to stay up to date. Networking possibilities that go beyond borders to create a truly Global Dental Village



### VIDEO REVIEWS OF PRODUCTS

Our opinion leaders unveil new products, services, and give you their first impressions of the industry's hottest topics.



### PEER REVIEWED CASE STUDIES

Upload, comment, participate. We encourage you to share your cases for review with like-minded practitioners.



**REGISTER FOR FREE ON [WWW.DTSTUDYCLUB.COM](http://WWW.DTSTUDYCLUB.COM)**

CONTESTS WITH CHANCES TO WIN FREE TUITION FOR ADA/CERP C.E. ACCREDITED WEBINARS

SPONSORSHIP AND SPEAKING INQUIRIES:  
JULIA WEHKAMP, [J.WEHKAMP@DTSTUDYCLUB.COM](mailto:J.WEHKAMP@DTSTUDYCLUB.COM), (416) 907-9836.



PRACTICE MANAGEMENT



GENERAL DENTISTRY



COSMETICS



ENDODONTICS



IMPLANTOLOGY



PERIODONTICS



ORTHODONTICS



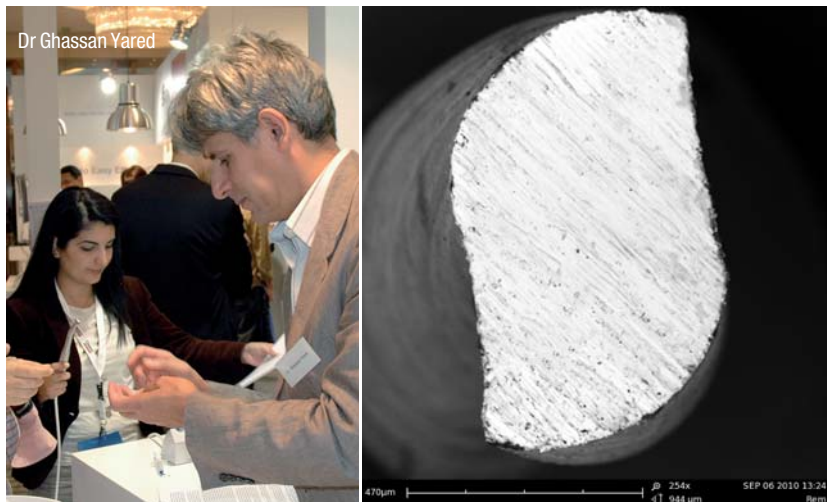
DENTAL HYGIENE

**[WWW.DTSTUDYCLUB.COM](http://WWW.DTSTUDYCLUB.COM)**





# The RECIPROC system



tions are significantly lower than the angles at which a Reciproc instrument would fracture. These angles are stored in the Reciproc endodontic motor, preventing the instrument from rotating past its specific angle of fracture. The centring ability of the reciprocation technique allows the instrument to follow the natural path of least resistance, which is the root canal. Reciproc instruments have been specifically designed for use in reciprocation and are produced with M-wire NiTi in an innovative thermal-treatment process. This alloy has both increased resistance to cyclic fatigue and greater flexibility than common NiTi material. Another advantage of the specific design is an enormous capacity to remove debris from the canal thanks to deep flutes. Additionally, the flexible S-shaped cross-section with two cutting edges provides high cutting ability at reduced friction.

**Canal curvature has always** introduced complexity into canal preparation. Dr James B. Roane's *balanced force technique* (1985) was a promising concept using stainless-steel hand instruments in small clockwise and counter-clockwise movements. Based on Dr Roane's idea but using rotary NiTi instruments and a reciprocating motor, Dr Ghassan Yared (Canada) developed the method to ingenious perfection. After an experimentation phase of more than seven years, he sent his first description of the canal preparation technique with only one rotary instrument to **roots** in March 2007. In the hands of the experienced endodontist, it worked. However, more than three years and a team of engineers, metallurgists and electronic technicians were necessary to turn a great idea into a professional product, consisting of Reciproc instruments, motor, paper points and gutta-percha points. Dr Yared and VDW Germany now introduced the system for the first time at the 8<sup>th</sup> World Endodontic Congress in Athens.

The majority of all canal anatomies can be prepared with the new technique using only one reciprocating file and without glide path or initial instrumentation. In reciprocation, the Reciproc file is initially driven in a cutting direction and then reverses to release the instrument. One rotation of 360° is completed in several reciprocating movements.

Root-canal preparation without creating a glide path goes against the current teaching standard for rotary instrumentation, which requires an initial glide path in order to minimise the risk of fracture due to an instrument binding in the canal. However, in reciprocation, the angles of alternating right and left rota-

From three file sizes—R25, R40 or R50—the one matching the canal size best needs to be selected. The initial taper of each file is larger over the first 3 mm from the tip, enabling a #30 irrigation syringe to be placed close to the apex. The canal shape obtained with each of the three instruments is optimal for all modern obturation techniques.

The Reciproc system is designed for convenience and safety. The instruments are specified for single use, making the work flow more efficient and reducing the risk of contamination. One Reciproc instrument does the job of several hand and rotary instruments. Single use also protects from the risk of material fatigue caused by over-use. The Reciproc system is manufactured by VDW Germany and will be available from January 2011 onwards. Please visit [www.endodonticourses.com/literature](http://www.endodonticourses.com/literature) and check out a number of videos on single file reciprocation with the RECIPROC system and give it a try!



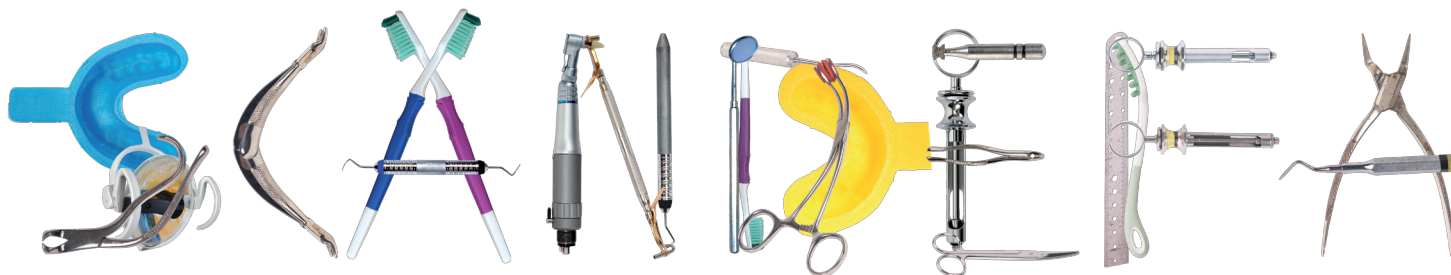## **\_contact**

**roots**

**VDW GmbH**  
Bayerwaldstr. 15  
81737 Munich  
Germany

[info@vdw-dental.com](mailto:info@vdw-dental.com)  
[www.vdw-dental.com](http://www.vdw-dental.com) // [www.reciproc.com](http://www.reciproc.com)





**APRIL 7- 9, 2011 • BELLA CENTER • COPENHAGEN • DENMARK**

**Welcome to the 44th Scandinavian Dental Fair**  
**The leading annual dental fair in Scandinavia**

# SCANDEFA 2011



**The 44th SCANDEFA invites you to exquisitely meet the Scandinavian dental market and sales partners from all over the world in springtime in wonderful Copenhagen**

SCANDEFA, organized by Bella Center, is being held in conjunction with the Annual Scientific Meeting, organized by the Danish Dental Association ([www.tandlaegeforeningen.dk](http://www.tandlaegeforeningen.dk)).

More than 200 exhibitors and 11.349 visitors participated at SCANDEFA 2010 on 14,220 m<sup>2</sup> of exhibition space.

#### **Reservation of a booth**

Book online at [www.scandefa.dk](http://www.scandefa.dk)  
Sales and Project Manager, Jo Jaqueline Ogilvie  
[jjo@bellacenter.dk](mailto:jjo@bellacenter.dk), T +45 32 47 21 25

#### **Travel information**

Bella Center is located just a 10 minute taxi drive from Copenhagen Airport. A regional train runs from the airport to Orestad Station, only 15 minutes drive.

#### **Book a hotel in Copenhagen**

[www.visitcopenhagen.com/tourist/plan\\_and\\_book](http://www.visitcopenhagen.com/tourist/plan_and_book)

# Greece inspired us once again

Author\_ Dr Antonis Chaniotis, Greece



Athens, the home of democracy, philosophy and culture, welcomed evidence-based endodontics from 6 to 9 October for the 8<sup>th</sup> World Endodontic Congress. What an interesting combination for those lucky enough to have attended the meeting! The organising committee and the Greek team tried their utmost to satisfy the expectations of the demanding audience. Honestly, with the impressive list of international keynote speakers the organisers were able to attract—Prof Syngcuk Kim (USA), Paul Abbott (Australia), Craig Baumgartner (USA), Edgar Schäfer (Germany), Ken Hargreaves (USA) and Shimon Fried-

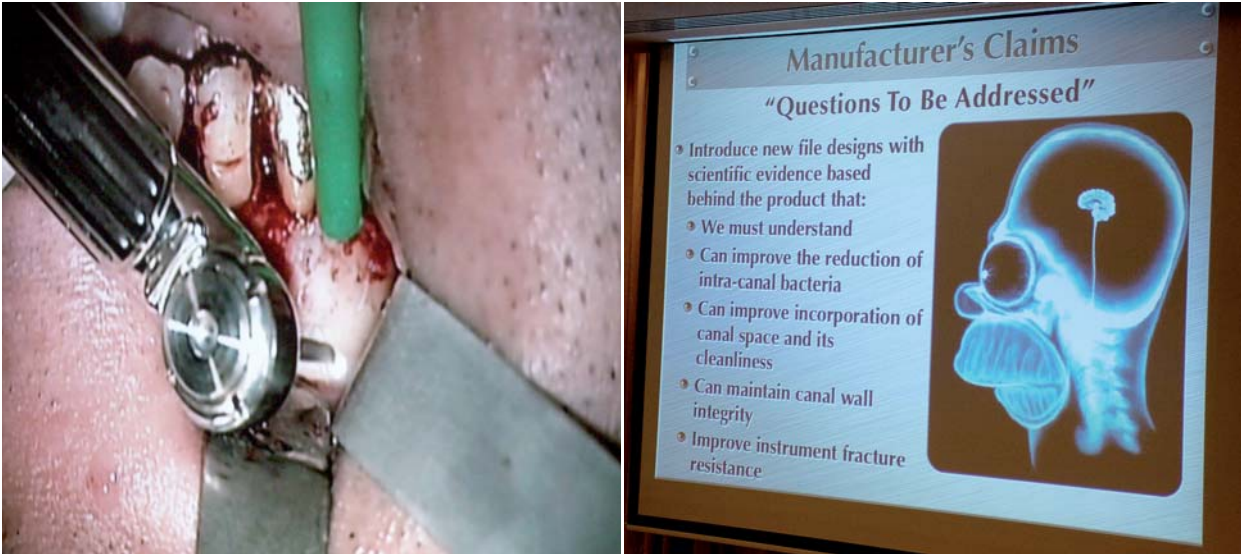
man (Canada)—this was relatively easy. To me, it felt as if chapters of classic endodontic textbooks popped up right in front of me.

The congress was sponsored by major dental industry players. DENTSPLY Maillefer played a key role as gold sponsor of the event. In a pre-congress course with Prof Sergio Kuttler, DENTSPLY launched the new WaveOne reciprocating file. DENTSPLY also organised hands-on courses at their booth and a wonderful cocktail party, which was held on the top floor of the Athens Hilton Hotel. The view of Athens from up there was absolutely breathtaking!

There was a tangible feeling of competition in the entire exhibition hall. The Self Adjusting File team did a great job promoting their new irrigation file structure and VDW and MICRO-MEGA also launched new products. Frankly speaking, promoting anything at this meeting was a difficult task because of the very demanding audience. Each participant sought documentation for just about everything being presented. When appropriate evidence was not yet available, the audience acted with reserve and caution.

The scientific programme was opened with a bit of dental history by Prof John Ingle (USA). Did you know that the first short Walt Disney ever made was on dentistry? In 1922, Walt Disney created *Tommy Tucker's Tooth*, a silent film about children's oral health, while





he was still a struggling cartoonist in Kansas City. Payment for the film allowed Disney to settle debts and head for Los Angeles, where he launched his historic career in animation and moviemaking. I, as well as many others in the audience, enjoyed watching the film for the very first time. Prof Ingle, we are grateful for your contribution to the congress!

Lectures of the highest quality marked the congress in Athens. Prof Hargreaves, Dr Gabriela Martin (Argentina) and many others presented evidence for revascularisation and regeneration efforts. Antibiotic pastes, scaffolds, cells and growth factors performed on the stage under the guidance of the speakers. Researchers and industry leaders are working on these issues and some major advances in this field may be very near.

Dr Enrique Merino (Spain) explored the endo-implant controversy and Dr Giuseppe Cantatore (Italy) lectured on *A critical approach to new NiTi instruments for mechanical glide path*. It was impossible to attend every session, as there were simultaneous lectures in different halls, as well as high-quality poster sessions. One presentation that impressed me in particular was *Three-dimensional photography in endodontics* by Dr Moscoso and colleagues from the University of Catalonia in Barcelona, Spain. Imagine your PowerPoint presentations and your microscope videos being transformed into a 3-D visual experience!

Dr Luc van der Sluis (The Netherlands) and the fluid dynamics team were also present and gave an overview of their interesting research on irrigation dynamics and delivery techniques. "Maybe in the future we will produce some kind of bioactive yogurt to fill the canals effectively," commented Dr van der Sluis in a private conversation. In my opinion, until we

do, we will have to present and seek evidence for everything we do.

Effective root-canal debridement and disinfection techniques were reconsidered by Prof Baumgartner in his inspiring lecture. Are we close to sterilisation of the infected root-canal system? According to Prof Baumgartner we are "pretty close".

On the last day of the congress, Prof Kim held a passionate lecture on evidence-based endodontic microsurgery and Prof Friedman's closing lecture offered the best of current evidence for treatment outcomes, supporting what we do and that about which are passionate—*Evidence-based Endodontics*, which was the theme of the congress.

A lucky few had the privilege of watching Prof Kim perform live surgery on a mandibular molar under the microscope. The event was sponsored by Satelec and Carl Zeiss and took place at the facilities of the University of Athens Dental School.

In closing, I would also like to say a few words about the social programme. The welcome reception took place on a cruise boat, at which the Ouzo and Greek wine served offered attendees the opportunity to relax after the high level but exhausting sessions. The Gala Dinner, which was held at the well-known Aegli Zappiou Restaurant, was so entertaining that many of the participants found it difficult to wake up in time for the morning sessions. Prof Baumgartner, we thank you for waking all of us up in the first ten minutes of your inspiring lecture.

I could write many more pages about what happened in Athens during the 8<sup>th</sup> World Endodontic Congress, but I think I have made my point. Thank you Athens! We will remember you as a wonderful host!\_





# A meeting of minds— Seeing is believing

**Author\_** Dr David English, UK

From 16 to 18 September 2010, over 300 delegates from 30 different countries assembled in Vilnius, Lithuania, for the second congress of the European Society of Microscope Dentistry (ESMD). I have attended several meetings dedicated to microscope dentistry during my career and have to admit that this one was as good as they get.

Simply put, the better you can see something, the better you can understand and treat it, and, thanks to the great imaging ability of microscopes, the better you can document and share the information with your patients and colleagues. For those of us who have already adopted this technology in our daily work, there is no going back. Today, the operating microscope (OM) is no longer only used by endodontists. Prosthodontists and periodontists equally are enhancing their treatments with magnification, illumination and documentation.

On the first day of the programme, delegates were able to select from a variety of hands-on workshops, including microsurgery suturing, non-surgical endodontics, precision preparation techniques for

crowns and veneers, 3-D obturation techniques, soft-tissue management around implants and microsurgical reconstructive procedures. Alternatively, master classes in practice management, digital imaging, matrix-free composite build-ups, laser use, tooth discolouration treatment and 3-D diagnosis were offered. The main programme, which offered introductory workshops on microscope use, allowed international speakers to demonstrate their expertise and the accuracy of their periodontal, prosthodontic and endodontic skills. The wonderful aspect of presentations at today's meetings is the tangible manner in which information can be presented through video and still photography taken through the OM—and not only one or two images but a whole stream of pictures that really convey the techniques, benefits and outcomes of the treatment. This is a level of discussion, education and knowledge transfer that was previously not possible.

An innovative and successful live demonstration of a periodontal surgery, performed by Dr Jan Behring, and a molar preparation, performed by Dr Horst

Behring, was offered via satellite link from a dental clinic in Hamburg, Germany. The presentations, which were moderated by Prof Stefan Ioan Stratul (Romania), alternated between the two treatment rooms in the clinic as the procedures progressed. Most of the images shown in the main lecture hall came from full-HD video cameras mounted on the clinicians' OMs. I have to congratulate my colleagues on presenting these procedures in real time (!) to over 200 eager attendees, who were also able to ask questions throughout the treatment process. In fact, the entire session was a logistical, educational and treatment triumph!

A selection of workshops and lectures on staff and practice management interspersed the programme and was received with much interest. Dentists who use OMs are very focused on their clinical skills. However, microscope use requires a good support team and a securely based business. Additionally, it is true that patients do not judge us based on our clinical skills only, but also on the image of our practice. We need to be aware of the image our practice conveys and not only focus on what we see through our microscopes!

Another real strength of this congress was the opportunity to meet the suppliers and manufacturers in the exhibition hall. Attendees were able to check out the latest in microscope technology, as well as instrumentation and imaging. The industry sponsors, such as Sigma Dental Systems, Global Surgical, DENTSPLY Maillefer, EMS and Nobel Biocare, who help make these meetings possible, must also be recognised.

The social programme was very well organised, with a welcome reception at the National Gallery of Art and a gala dinner at the Vilnius Town Hall the following evening. Vilnius is a most interesting place to visit—



a mix of the very old and the very new and an awareness of the really quite recent changes in Lithuania's political climate.

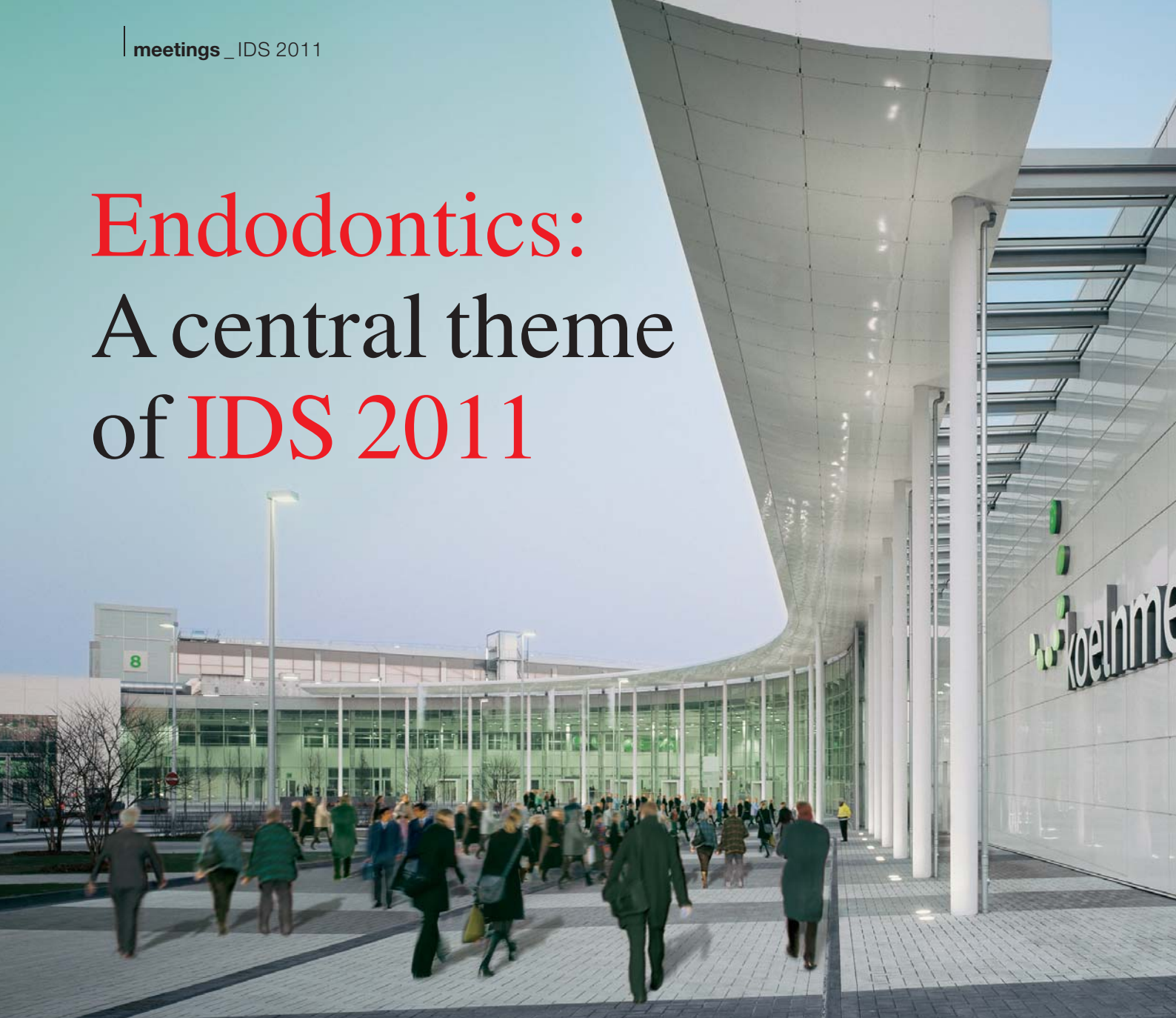
The venue, the Radisson Blu Hotel Lietuva overlooking the Neris river, was just a short walk from the ancient town centre of Vilnius, making it well located and attractive at the same time, with great views over Vilnius and good ambience and customer service overall.

Microscope-using dentists might be seen as a special 'breed', a rather elitist self-selecting group. In my opinion, microscope-using dentists are concerned dental clinicians, following a logical progression of endeavour that modern technology allows. Additionally, they are knowledgeable, open to sharing their experiences and a wonderful group of people to be around. This congress was a great opportunity to gain exposure in this regard and my heart-felt congratulations go to the organisers. I look forward to the 2012 Berlin meeting. \_





# Endodontics: A central theme of IDS 2011



**Endodontics** provides an important foundation for long-term and lasting tooth preservation. In light of an ageing society, this dental discipline is increasingly gaining importance. With evidence-based success rates of up to 85 per cent for treatments performed *lege artis*, endodontics has long been established in the range of therapies offered by general dentists, while at the same time offering a variety of tasks for specialists. According to Dr Martin Rickert, Chairperson of the Board of the Association of German Dental Manufacturers (VDDI), "The impressive scientific and technological progress in the field of endodontics has improved the odds of long-term tooth retention tremendously and puts this speciality at the centre of a prophylactic-conservationist approach to dentistry." The latest methods employed in conservation therapy include manual and automatic root-canal preparation, efficient rinsing methods during disinfection, and modern instruments and materials for obturation. Today, even the treatment of

anterior teeth with fractured crowns and roots is possible through the use of advanced *fiber post systems*, amongst other techniques. Additionally, if root-canal revision should become necessary, endodontic specialists have a range of minimally invasive microsurgical treatment options available to them, including the treatment of complex endo-periodontal lesions.

The many years of intense collaboration between a large number of specialists and companies in the dental industry have resulted in the well-engineered instruments and material systems available today that increase accuracy of diagnosis and, above all, improve treatment of root-canal lesions. Modern imaging techniques, for example, allow the precise visualisation of the root canal and thus enable both endometry up to the apex and the exact determination of the file position during preparation. Digital X-rays and digital volumetric tomography are also becoming increasingly important. Moreover, high-





determined by means of either X-rays or modern electrometric measuring units that cause no additional exposure to radiation. Effective chemicals that can be enhanced via ultrasound-supported or hydrodynamic methods are used to irrigate root canals, which frequently determines the failure or success of the procedure. Modern sealer adhesives and cements based on composites are available for bacteria-tight obturation. Classic methods, primarily gutta-percha techniques, can also be used. There has been significant progress in this regard as well. For example, new equipment systems for warm vertical condensation ensure better adaptation of the thermally plasticised gutta-percha to the canal walls. The 34<sup>th</sup> International Dental Show (IDS) will be a particularly valuable source of comprehensive information for anyone wishing to learn about the entire spectrum of new developments in endodontics.

Aside from routine tasks that can be performed by general dentists, endodontics also offers a challenging field of work for specialists, which includes complex revisions, root-end resections, and the restoration of teeth with fractured crowns and roots. In order to complete these treatments successfully, experts have a wide variety of tools available to them, such as loupe systems or surgical microscopes that permit minimally invasive microsurgical endodontic surgery.

At the next IDS, which will be held from 22 to 26 March 2011, the solutions offered by endodontic specialists and renowned companies in the dental industry will demonstrate the integration of standard endodontic services and specialisation opportunities into the day-to-day routine of a dental surgery. Interested trade visitors can take advantage of this expertise and experience during the fair. Visitors will also have the opportunity to ask questions and discuss problems with the experts at a unique international forum. IDS is the ideal opportunity for dentists and dental technicians to gain the latest information on endodontics, as well as learn to implement it in their dental surgery and to integrate complex treatment systems at an expert level. Successful endodontic treatment increases the likelihood of tooth preservation, makes for satisfied patients and ultimately enhances the image of the dentist's surgery.

"From 22 to 26 March 2011, the International Dental Show in Cologne—the world's largest trade fair for dental medicine and dental technology—will be the best place for dentists interested in endodontics and their assistants to talk to specialists from the exhibiting companies and experienced users about the whole spectrum of modern endodontic concepts and current trends in treatments and diagnostics," concludes Dr Markus Heibach, President of the VDDI.

resolution intra-oral cameras are used for the time-saving online documentation of the treatment, as well as for diagnostic purposes.

Another important trend is the increased use of mechanised root-canal preparation. In particular, computer-designed file geometries with optimised conicities and cutting edges result in greater safety and efficiency. Modern materials, such as nickel-titanium or titanium-niobium alloys, have vastly improved the durability of rotating preparation and revision files, thus virtually revolutionising endodontic treatment options. A conical preparation is now also possible in severely curved root canals. High-performance, electronically controlled drive units with torque control largely help to eliminate fracturing when using the mechanised files.

Technological progress has also been made in other areas of endodontics. The working length is

_contact	roots
<p><b>Koelnmesse GmbH</b>            P.O. Box 210760            50532 Köln            Germany</p>	
<p>Tel.: +49 221 821 0            Fax: +49 221 821 2574</p>	
<p>info@koelnmesse.de            www.koelnmesse.de</p>	

# International Events

## 2010

### **Pulp Fiction 12**

2–5 December 2010  
Jachranka, Poland  
profident@profident.pl  
www.profident.pl/pulpfiction12-e.html

## 2011

### **Penn Endo Global Symposium**

28 & 29 January 2011  
Nuremberg, Germany  
event@oemus-media.de  
www.oemus.com

### **Chicago Dental Society Midwinter Meeting**

24–26 February 2011  
Chicago, IL, USA  
www.cds.org

### **IADR General Session & Exhibition**

16–19 March 2011  
San Diego, CA, USA  
sherren@iadr.org  
www.iadr.org

### **International Dental Show**

22–26 March 2011  
Cologne, Germany  
ids@koelnmesse.de  
www.ids-cologne.de

### **AAE Annual Session**

13–16 April 2011  
San Antonio, TX, USA  
info@aae.org  
www.aae.org

### **ESE Congress**

14–17 September 2011  
Rome, Italy  
info@eserome2011.com  
www.eserome2011.com

### **FDI Annual World Dental Congress**

14–17 September 2011  
Mexico City, Mexico  
congress@fdiworldental.org  
www.fdiworldental.org

### **DGEndo Annual Meeting**

3–5 November 2011  
Bonn, Germany  
sekretariat@dgendero.de  
www.dgendero.de

## 2013

### **IFEA World Endodontic Congress**

23–26 May 2013  
Tokyo, Japan  
ifea2013@convention.co.jp  
www2.convention.co.jp/ifea2013



## submission guidelines:

Please note that all the textual components of your submission must be combined into one MS Word document. Please do not submit multiple files for each of these items:

- \_ the complete article;
- \_ all the image (tables, charts, photographs, etc.) captions;
- \_ the complete list of sources consulted; and
- \_ the author or contact information (biographical sketch, mailing address, e-mail address, etc.).

In addition, images must not be embedded into the MS Word document. All images must be submitted separately, and details about such submission follow below under image requirements.

### Text length

Article lengths can vary greatly—from 1,500 to 5,500 words—depending on the subject matter. Our approach is that if you need more or less words to do the topic justice, then please make the article as long or as short as necessary.

We can run an unusually long article in multiple parts, but this usually entails a topic for which each part can stand alone because it contains so much information.

In short, we do not want to limit you in terms of article length, so please use the word count above as a general guideline and if you have specific questions, please do not hesitate to contact us.

### Text formatting

We also ask that you forego any special formatting beyond the use of italics and boldface. If you would like to emphasise certain words within the text, please only use italics (do not use underlining or a larger font size). Boldface is reserved for article headers. Please do not use underlining.

Please use single spacing and make sure that the text is left justified. Please do not centre text on the page. Do not indent paragraphs, rather place a blank line between paragraphs. Please do not add tab stops.

Should you require a special layout, please let the word processing programme you are using help you do this formatting automatically. Similarly, should you need to make a list, or add footnotes or endnotes, please let the word processing programme do it for you automatically. There are menus in every programme that will enable you to do so. The fact is that no matter how carefully done, errors can creep in when you try to number footnotes yourself.

Any formatting contrary to stated above will require us to remove such formatting before layout, which is very time-consuming. Please consider this when formatting your document.

### Image requirements

Please number images consecutively throughout the article by using a new number for each image. If it is imperative that certain images are grouped together, then use lowercase letters to designate these in a group (for example, 2a, 2b, 2c).

Please place image references in your article wherever they are appropriate, whether in the middle or at the end of a sentence. If you do not directly refer to the image, place the reference at the end of the sentence to which it relates enclosed within brackets and before the period.

In addition, please note:

- \_ We require images in TIF or JPEG format.
- \_ These images must be no smaller than 6x6 cm in size at 300 DPI.
- \_ These image files must be no smaller than 80 KB in size (or they will print the size of a postage stamp!).

Larger image files are always better, and those approximately the size of 1 MB are best. Thus, do not size large image files down to meet our requirements but send us the largest files available. (The larger the starting image is in terms of bytes, the more leeway the designer has for resizing the image in order to fill up more space should there be room available.)

Also, please remember that images must not be embedded into the body of the article submitted. Images must be submitted separately to the textual submission.

You may submit images via e-mail, via our FTP server or post a CD containing your images directly to us (please contact us for the mailing address, as this will depend upon the country from which you will be mailing).

Please also send us a head shot of yourself that is in accordance with the requirements stated above so that it can be printed with your article.

### Abstracts

An abstract of your article is not required.

### Author or contact information

The author's contact information and a head shot of the author are included at the end of every article. Please note the exact information you would like to appear in this section and format it according to the requirements stated above. A short biographical sketch may precede the contact information if you provide us with the necessary information (60 words or less).

### Questions?

Claudia Salwiczek (Managing Editor)  
c.salwiczek@oemus-media.de



# roots

international magazine of endodontology

## Publisher

Torsten R. Oemus  
[oemus@oemus-media.de](mailto:oemus@oemus-media.de)

## CEO

Ingolf Döbbecke  
[doebbecke@oemus-media.de](mailto:doebbecke@oemus-media.de)

## Members of the Board

Jürgen Isbaner  
[isbaner@oemus-media.de](mailto:isbaner@oemus-media.de)

Lutz V. Hiller

[hiller@oemus-media.de](mailto:hiller@oemus-media.de)

## Managing Editor

Claudia Salwiczek  
[c.salwiczek@oemus-media.de](mailto:c.salwiczek@oemus-media.de)

## Executive Producer

Gernot Meyer  
[meyer@oemus-media.de](mailto:meyer@oemus-media.de)

## Designer

Josephine Ritter  
[j.ritter@oemus-media.de](mailto:j.ritter@oemus-media.de)

## Copy Editors

Sabrina Raaff  
Hans Motschmann

## Published by

Oemus Media AG  
Holbeinstraße 29  
04229 Leipzig, Germany  
Tel.: +49-341/4 84 74-0  
Fax: +49-341/4 84 74-2 90  
[kontakt@oemus-media.de](mailto:kontakt@oemus-media.de)  
[www.oemus.com](http://www.oemus.com)

## Printed by

Messedruck Leipzig GmbH  
An der Hebemärchte 6  
04316 Leipzig, Germany

## Editorial Board

Fernando Goldberg, Argentina  
Markus Haapasalo, Canada  
Ken Serota, Canada  
Clemens Bargholz, Germany  
Michael Baumann, Germany  
Benjamin Briseno, Germany  
Asgeir Sigurdsson, Iceland  
Adam Stabholz, Israel  
Heike Steffen, Germany  
Gary Cheung, Hong Kong  
Unni Endal, Norway  
Roman Borczyk, Poland  
Bartosz Cerkaski, Poland  
Esteban Brau, Spain  
José Pumarola, Spain  
Kishor Gulabivala, United Kingdom  
William P. Saunders, United Kingdom  
Fred Barnett, USA  
L. Stephan Buchanan, USA  
Jo Dovgan, USA  
Vladimir Gorokhovskiy, USA  
James Gutmann, USA  
Ben Johnson, USA  
Kenneth Koch, USA  
Sergio Kuttler, USA  
John Nusstein, USA  
Ove Peters, USA  
Jorge Vera, Mexico



Claudia Salwiczek, Managing Editor

roots

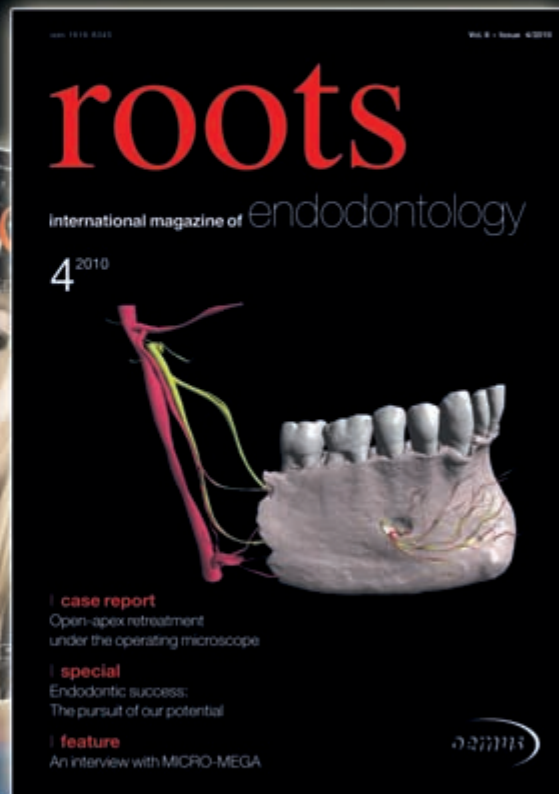
## Copyright Regulations

\_roots international magazine of endodontology is published by Oemus Media AG and will appear in 2010 with one issue every quarter. The magazine and all articles and illustrations therein are protected by copyright. Any utilisation without the prior consent of editor and publisher is inadmissible and liable to prosecution. This applies in particular to duplicate copies, translations, microfilms, and storage and processing in electronic systems.

Reproductions, including extracts, may only be made with the permission of the publisher. Given no statement to the contrary, any submissions to the editorial department are understood to be in agreement with a full or partial publishing of said submission. The editorial department reserves the right to check all submitted articles for formal errors and factual authority, and to make amendments if necessary. No responsibility shall be taken for unsolicited books and manuscripts. Articles bearing symbols other than that of the editorial department, or which are distinguished by the name of the author, represent the opinion of the afore-mentioned, and do not have to comply with the views of Oemus Media AG. Responsibility for such articles shall be borne by the author. Responsibility for advertisements and other specially labeled items shall not be borne by the editorial department. Likewise, no responsibility shall be assumed for information published about associations, companies and commercial markets. All cases of consequential liability arising from inaccurate or faulty representation are excluded. General terms and conditions apply, legal venue is Leipzig, Germany.

# roots

international magazine of endodontology



You can also subscribe via  
[www.oemus.com/abo](http://www.oemus.com/abo)



**Subscribe now!**

## One issue free of charge!

I hereby agree to receive a free trial subscription of **roots** international magazine of endodontology (4 issues per year). I would like to subscribe to **roots** (€ 44 including shipping and VAT for German customers; € 46 including shipping and VAT for customers outside of Germany) unless a written cancellation is sent within 14 days of the receipt of the trial subscription. The subscription will be renewed automatically every year until a written cancellation is sent to OEMUS MEDIA AG, Holbeinstr. 29, 04229 Leipzig, Germany, six weeks prior to the renewal date.

▶ Reply via Fax to +49 341 48474-290  
or via E-mail to [grasse@oemus-media.de](mailto:grasse@oemus-media.de)

Last Name, First Name

Company

Street

ZIP/City/Country

E-mail

Signature

Notice of revocation: I am able to revoke the subscription within 14 days after my order by sending a written cancellation to OEMUS MEDIA AG, Holbeinstr. 29, 04229 Leipzig, Germany.

Signature

Holbeinstr. 29, 04229 Leipzig, Germany, Tel.: +49 341 48474-0, Fax: +49 341 48474-2 90, E-mail: [grasse@oemus-media.de](mailto:grasse@oemus-media.de)

OEMUS MEDIA AG





## ADHESIVE CORE BUILD-UP SYSTEM

Complete set for 15 post-endodontic treatment

- Effective five step system
- Monoblock formation of tooth, post and build-up
- Futurabond and Ceramic Bond for highest stability
- Aesthetic foundation for prosthetic restorations

# Rebilda Post system

