


Use of **Synthetic Bone Blocks** as an Alternative to Autologous Bone Block Grafts

author_ Christian Mertens¹, Helmut G. Steveling¹, Germany
¹ Department of Oral and Maxillofacial Surgery, University of Heidelberg

Fig. 1_ NanoBone® | block.
Fig. 2_ Radiographic situation prior to augmentation (cone beam CT).



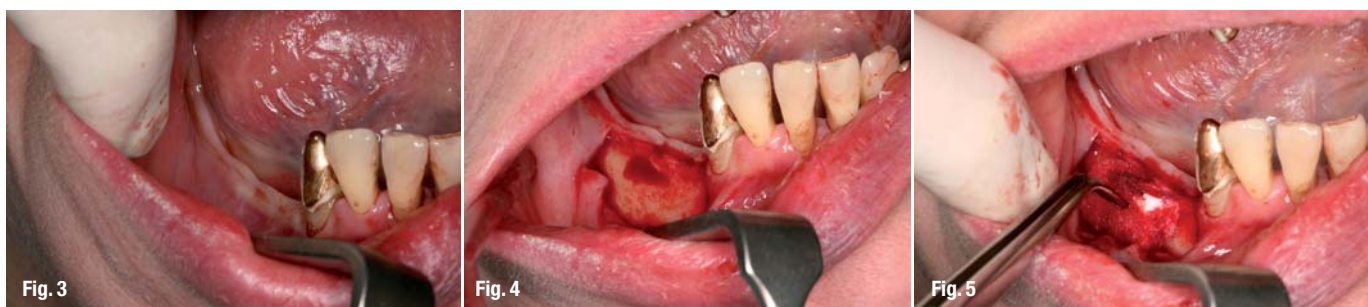_In modern implantology, correct three-dimensional positioning of implants, as well as sufficient bone material are of great importance in order to reach satisfactory and predictable results. Resorption processes, traumatic tooth losses or chronic inflammatory processes such as chronic periodontal diseases, however, often result in severe reduction of bone material. If affected areas are intended to serve as implant beds, augmentation will often be required during the same or in a previous intervention. While autologous bone is still considered to be the gold standard, bone substitute materials have proven successful particularly in cases of rather small defects. Their use may decrease patient's morbidity, shorten treatment duration and reduce treatment costs. However, if the defect exceeds a certain size, autologous bone grafts will have to be used, usually in the form of blocks. Intraoral bone removal poses the problem of limited availability. Extraoral donor sites, however,

require treatment under general anesthesia or under in-patient conditions, which is why patients frequently reject this type of surgery.

In particular in cases of edentulism in the molar and premolar region, patients tend to prefer fixed dental prostheses, however, the problem of a significantly narrowed alveolar ridge often occurs in the molar area of the mandible.

The use of the NanoBone® | block (Artoss, Germany) constitutes a possible alternative to autologous bone blocks. The nanocrystalline material, that has already proven reliable in many trials in a particulate form, has been available on the market in the form of blocks for a short time. Preclinical trials using animal models have shown high rates of bone formation within a relatively short period of time. The following follow-up observation was initiated to find out whether the bone substitute material used in the form of blocks proves successful as a possible alternative to autologous bone.

Fig. 3_ Clinical situation before surgery.
Fig. 4_ Narrow alveolar ridge.
Fig. 5_ Adaptation of NanoBone® | block to local bone.



Material and Methods

The synthetic bone reconstruction material NanoBone® consists of nanocrystalline hydroxylapatite embedded in a silica gel matrix. This matrix has an interconnecting porosity up to the range of nanometer, 50% of which have an average pore size of 35 nm. This creates a large inner surface of 85 m²/g, important for the accumulation of autologous proteins. The fir cone-like granules have a loose packing of a packing-density of approx. 40%, which results in ideal spaces for vascularization.

Since the product is manufactured using the sol-gel process at low temperatures, it is a non-sintered hydroxylapatite, whereas, based upon the manufacturing process conventional ceramics and bioglasses are sintered and thus have a correspondingly reduced inner surface.

Studies have shown that, within approximately two weeks after the implantation of NanoBone®, the silica gel matrix becomes an organic matrix consisting of osteocalcine, osteopontine and BMP-2 (Götz et al. COIR). The structure then corresponds to extracellular bone matrix. Subsequently, the augmented area is remodeled, i.e. osteoclasts decompose the material and, at the same time, osteoblasts produce new natural bone.

The change in matrix described above constitutes the precondition of fast bone regeneration. Trials using animal models have shown a quick angiogenic development of the augmented material (Gerber et al.).

Blocks based on the same technology are now available. The NanoBone® | block used here is 5 mm thick, 10 mm high and 15 mm large (see Fig.). In contrast to the granulate, interconnecting macropores ensure the vascularization of the augmentation area in this case. The pores have a size of approx. 200 µm and account for approx. 50%.

The synthetic bone reconstruction material NanoBone® consists of nanocrystalline hydroxylapatite embedded in a silica gel matrix. The morphology of the hydroxylapatite in the NanoBone® | block is identical to biological hydroxylapatite in bone (plates of a thickness of 3 nm and diameter of approx. 50 nm). This fact and the adapted gel matrix result in an inner surface of 120 m²/g. The interconnecting pores in the silica gel have a size of 10 to 20 nm.

Clinical follow-up

In this follow-up observation, the new synthetic NanoBone® | blocks were used on both sides in the patient's molar and premolar areas of the mandible.

AD



6th

6th Arab-German Implantology Meeting of DGZI

and Second International Dental Congress of Faculty of Oral & Dental Medicine/Cairo University

Cairo, Egypt | March 23–26, 2010

Congress Chairman:
Dr. Rolf Vollmer, Germany

Scientific Chairman:
Dr. Mazen Tamimi, Jordan

The German Association of Dental Implantology (DGZI) presents this meeting in cooperation with Faculty of Oral & Dental Medicine/Cairo University.

Information/Registration:

For other countries:
E-mail: drtamimi@drtamimi.com
drtamimi@dgzi-international.com
www.dgzi-international.com

For Egypt:
E-mail: drazim2001@yahoo.com

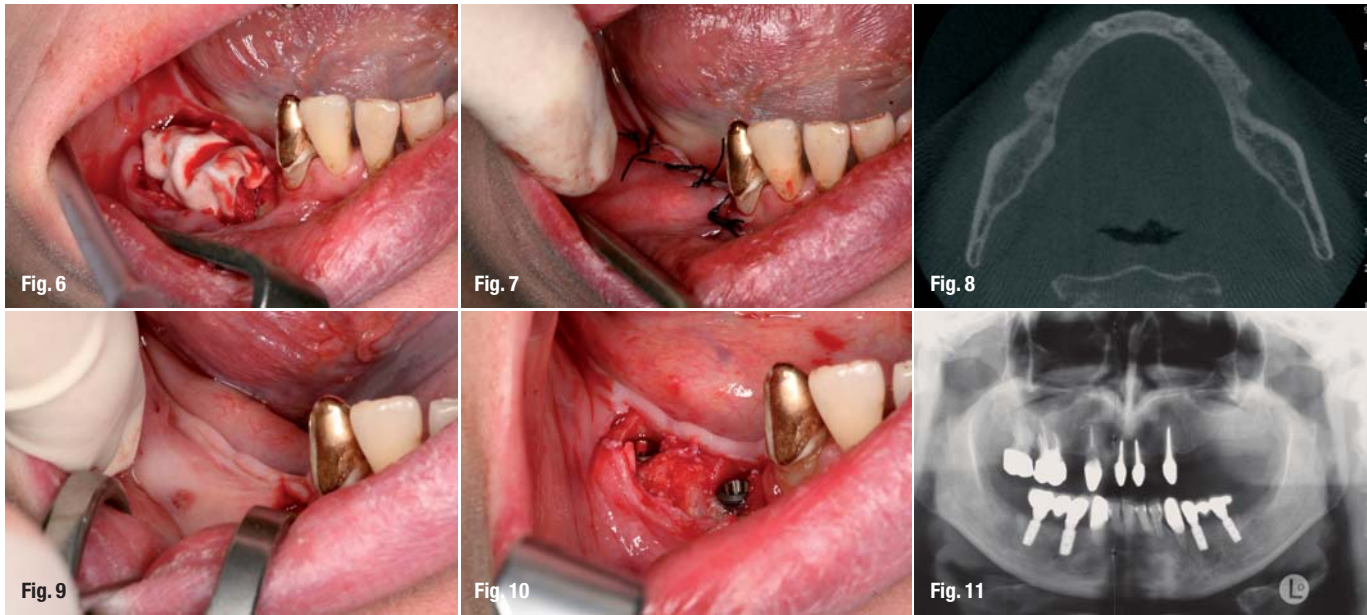


Fig. 6_Block coverage by means of collagen barrier membrane.

Fig. 7_Situation after wound closure.

Fig. 8_Radiographic situation after six months healing period (cone beam CT).

Fig. 9_Clinical situation prior to implant surgery.

Fig. 10_Good osseointegration of the blocks, high primary stability of implants.

Fig. 11_Radiographic follow-up after prosthetic rehabilitation.

Both sides were partially edentulous, starting from region 034 and 044. The jaw areas were atrophied since the teeth had been lacking for a long time and the patient has had a telescopic dental prosthesis retained on teeth 33 and 43 up to present. In the context of the necessary replacement of the prosthesis, the patient asked for a fixed prosthesis. Palpatory examinations showed a very narrow clinical situation, which was confirmed by three-dimensional X-ray analysis using cone beam CT.

Augmentation was carried out under local anesthesia. After crestal incision, vertical relief incisions were carried out in the vestibule and a mucoperiosteal flap was created. After exposure of the bone surface, some bleeding points were created using a fine round bur through the vestibular corticalis. The bone block was then adapted to the base using a scalpel. When the block lied flush against the base, it was fixed by gently tightening the osteosynthesis screws. In the present case, a single mini-screw was used in each case. Since the block is fragile, the fixing has been changed over to a 2-hole microplate and two microscrews in the meantime in order to avoid the breaking of the block. Subsequently, the edges were rounded. In the present case, the block was covered using a collagenous membrane and the buccal mucosa flap was advanced and then sutured with black silk sutures.

Four Astra Tech implants (Astra Tech, Mölndal, Sweden) were inserted six months after the augmentation—again under local anesthesia. Again, a crestal incision with minimum distal relief was carried out. After exposure, the material presented good osseointegration, without fibrous infiltration. During the drilling process, the newly formed bone showed high stability and all implants were inserted with good primary stability.

Results

After a healing time of six months, the NanoBone blocks used showed good bone infiltration, making it possible to retain implants with sufficient primary stability. Thus, the procedure used in this case may constitute a possible alternative to autologous block grafts. However, this will have to be verified by studies covering a correspondingly large number of cases.

Discussion

The nanocrystalline blocks used constitute a possible alternative to autologous bone blocks. The block provides a sufficient primary stability to be used safely for augmentation. The clinical procedure, however, differs from the use of e.g. autologous blocks removed from the retromolar space. The special structure of the block provides for the complete osseointegration of the augmentation material and thus for a sufficient gain in volume for safe implantation.

contact

implants

Dr Christian Mertens

Department of Oral and Maxillofacial Surgery,

University of Heidelberg

Im Neuenheimer Feld 400

69120 Heidelberg, Germany

Phone: +49-62 21/56 73 03

Fax: +49-62 21/56 42 22

E-Mail: christian.mertens@med.uni-heidelberg.de



Legacy™3 Implant System



Conical Connection with Platform Switching All-in-one Packaging Including SBM Implant, Cover Screw, Healing Collar, Transfer and Final Preparable Abutment = € 130

THE NEXT GENERATION
in Implant Technology



FEATURES AND BENEFITS

- 1. Body Design:**
Evenly Tapered with self-tapping grooves from mid-point to apex.
- 2. Thread Design:**
Micro-threads with progressively deeper, double-lead, buttress threads.
- 3. Surface Options - 17 year history:**
SBM - medium rough texture;
HA Coating below micro-threads.
- 4. Diameter Options:**
Six Diameters from 3.2mmD to 5.7mmD in 0.5mmD increments.
- 5. Conical Connection:**
Lead-in Bevel above Internal Hex -
23 year history (Niznick #4,960,381)
Color Coded for easy Identification;
Platform Switching on 3.2mmD,
4.2mmD and 5.2mmD Implants.
- 6. Fixture-mount Packaging:**
Fixture-mount standardizes
insertion tools, serves as
Transfer and can be shortened
for use as Final Abutment.



Straight Contoured, HLA Abutment, 15° Angled Contoured, Straight Snap-On, Gold/Plastic, Titanium Temporary Abutment, Plastic Temporary Abutment, Ball Attachment, Screw Receiving, Locator Abutment

Prosthetic compatibility with Screw-Vent, BioHorizons® and MIS Implants

Legacy™3



Implant Direct Europe AG • Förlibuckstrasse 150,
8005 Zürich, Switzerland • Phone: 00800 4030 4030

Implant Direct USA • 27030 Malibu Hills Road,
Calabasas Hills, CA 91301 • Phone: +1 818 444 3333
www.implantdirect.com