

Implant fracture:

A look at the physical mechanisms for failure

Authors_Dr Dov M. Almog, Dr Odalys Hector, Dr Samuel Melcer, Dr Kenneth Cheng, USA

The etiology and physical mechanism of fractured dental implants phenomenon have been reviewed and studied at length in recent years.¹⁻⁹ For the most part, the studies concluded that the crown-to-root ratio guidelines associated with natural teeth should not be applied to a crown-to-implant restorations ratio. According to these studies, the crown-to-implant ratios of those implants that were considered successful at the time the reviews took place were similar to those implants that failed. Apparently, according to some of these studies, the guidelines that are used by some clinicians to establish the future prognosis of implant supported restorations are usually empirical and lack scientific validation as far as the possible causes for implant fractures. However, as oral implantology has been the fastest growing segment in dentistry, the gaining of insight into these failure processes, including the accurate understanding of critical anatomical, restorative and mechanical information, might stimulate the clinicians' implementation of preventive action that may avoid the future fractures outcome with dental implants.

Case report

A 72-year-old Caucasian male recently presented to

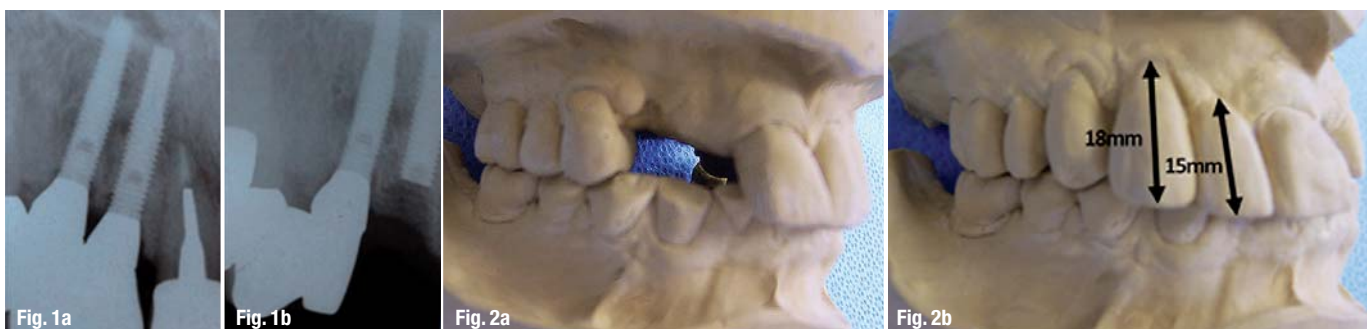our clinic. Consistent with the patient's chief complaint, a comprehensive oral and maxillofacial examination, including full-mouth X-rays, revealed, among other things, two fractured endosseous implants #6 and #7 (Fig. 1).

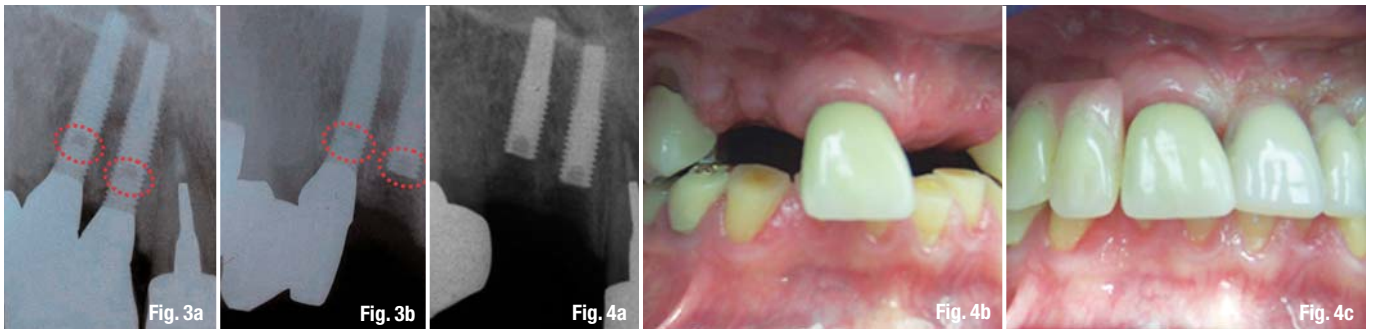
These 3.3 mm x 15 mm implants (Lifecore Biomedical, Chaska, Minn.) were placed and restored in 2003. The implants were placed as per protocol, utilizing a surgical template consisting of two guiding sleeves (De-Plaque, Victor, N.Y.). The implants were allowed to integrate for six months. No surgical complications were noted during this time. At the conclusion of the six-month waiting period, the implants were uncovered in the normal manner and healing abutments placed.

The implants were subsequently restored with implant-supported crowns that were functional for approximately six years until the implants fractured. While this treatment option was developed with an appreciation of the patient's occlusal and mechanical circumstances and habits, following the implants' fracture, a retrospective analysis of the site planned for the implants revealed extended inter-occlusal space on the articulated models and widespread occlusal wear of the opposing dentition (Fig. 2).

Figs. 1a & b_Implants #6 and #7 (Lifecore Biomedical, 3.3 mm x 15 mm) before (A) and after the fracture (B).

Figs. 2a & b_Retrospective analysis of the site planned for the implants #6 and #7 (A) revealed an extended overbite, requiring long crowns (B) to meet esthetic needs, and at the same time, the opposing occlusion presented extensive occlusal wear.





When the patient presented recently to our clinic, the only portion of the restoration that was still present in his mouth was abutment #6, which was still connected to one of the fractured implants, and was removed with a hex driver (Fig. 3). Proceeding with careful assessment of all the available retrospective diagnostic information and upon further discussion with the patient, several diagnostic assumptions and one follow-up treatment option were established that included replacement of the implant-supported crowns by a removable cast partial denture.

Considering the need for the removal of fractured implants must be balanced against the risk of increasing damage, a decision was made to remove the remaining abutment and the fractured piece of implant #6 allowing for primary closure of the soft tissue over the remaining implant bodies #6 and #7, i.e., "put them to sleep" (Fig. 4). This was followed by insertion of an immediate acrylic removable partial denture, and subsequently, a cast partial denture will be fabricated. This report attempts to provide an argument in favor of the consideration of physical mechanisms as potential contributors to implant fractures.

While controversy continues to exist as to whether crown-to-root ratio can serve as an independent aid in predicting the prognosis of teeth,⁹ the same certainly applies to crown-to-implant ratio, unless multiple other clinical indices such as opposing occlusion, presence of parafunctional habits and material electrochemical problems, just to name a few, are considered. Implant fractures are considered one potential problem with dental implants, especially delayed fracture of titanium dental implants due to chemical corrosion and metal fatigue.²

Following careful review of the referenced articles, which are very enlightening, we realized that to a great extent they support our theory that there are multiple factors involved in implant fractures. These factors include magnitude, location, frequency, direction and duration of compressive, tensile and shear stresses; gender; implant location in the jaw; type of bone surrounding the implant; pivot/fulcrum

point in relation to abutment connection; implant design; internal structure of the implant; length of time in the oral environment as it relates to metallurgical changes induced in titanium over time; gingival health and crown-to-implant ratio. Considering the multiple factors involved in implant fractures, both physical and biological, we can only assume that it can happen especially if the forces of the opposing occlusion and/or parafunctional habits are greater than the strength of the implant, especially over time. Therefore, it is imperative that the clinician be knowledgeable about the diversity of factors before recommending dental implants. Errors in diagnosing potential contributors to implant fractures are the most common reason that dental implants fail.

Conclusion

Although, according to the literature, the use of the crown-to-implant ratio in addition to other clinical indices does not offer the best clinical predictors, and even though no definitive recommendations could be ascertained, considering that dental implants are becoming increasingly popular, an increase in the number of failures, especially due to late fractures, is to be expected.⁸ This report attempted to provide an argument in favor of consideration of physical mechanisms as potential predictors to implant fractures. Therefore, it is essential for us to familiarize ourselves with the understanding, and diagnostic competence of the multiple factors involved in implant fractures. Once observed, this predictor would certainly lead to better diagnosis and treatment planning.

Editorial note: The literature list can be requested from the editorial office.

Figs. 3a & b By default, based on physical principles, once an implant has integrated in the bone, the weakest point is the fulcrum where the internal screw engages the implant (A). Note the fracture level in implant #7 and fracture line in implant #6 (B).

Figs. 4a, b & c The remaining abutment and the fractured piece of implant #6 were removed, allowing for primary closure of the soft tissue over the remaining implant bodies #6 and #7 (A, B), followed by an insertion of an immediate acrylic removable partial denture (C). (Photos/Provided by Dr Dov M. Almog)

contact

implants

Dr Dov M. Almog, DMD

Chief, Dental Service (160)
VA New Jersey Health Care System (VANJHCS)
385 Tremont Ave., East Orange, N.J. 07018
E-mail: dov.almog@va.gov