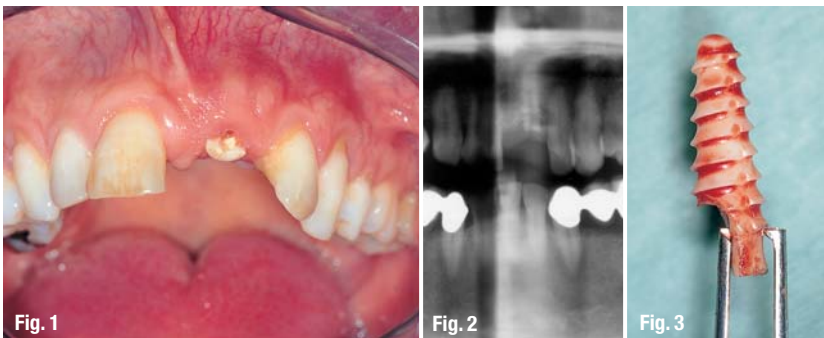

# Second implantation after **implant fracture**

**Authors**\_Dr Michael Hopp, Andreas Klar, Prof Dr Reiner Biffar, Germany



influenced by bone availability and, potentially, fractures to the alveolar process as well as inflammations. These properties determine the temporal and technical approach for a replacement implant. Attention must be paid to the primary stability of second implants, which is easily achieved through the use of implants with a larger diameter, if possible of the screw type.

## \_Case description

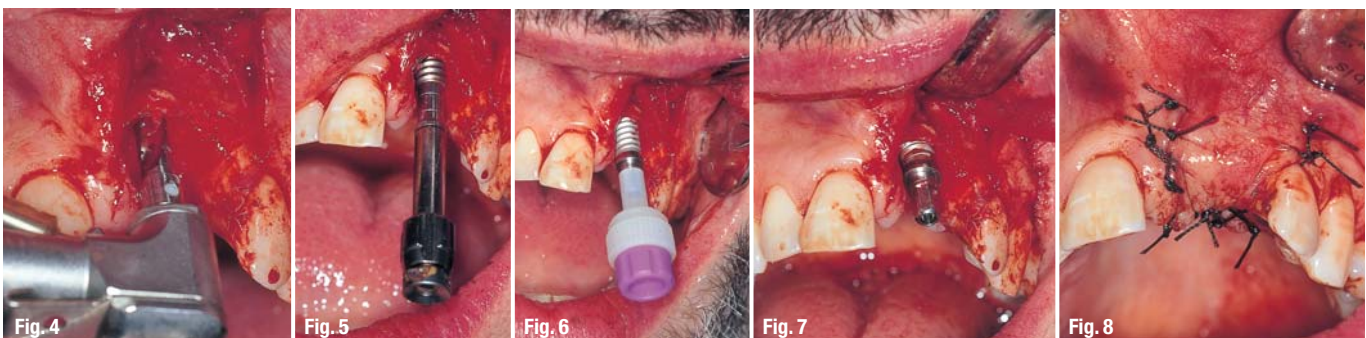
The first implant was placed in region 21 in the now 54-year-old patient after a front tooth had been lost in 1992. An  $Al_2O_3$  implant manufactured by Cerasiv was inserted. It is interesting to note that the first implant fractured during placement and was replaced with an implant of the same structure. The healing process was without complications and occurred over a period of 6 months. After the location had been opened up, a titanium insert was cemented into the implant, this was then shaped and a metal ceramic crown added. The diastema had been left after the first implant, in accordance with the patient's wishes.

Over the 12-year period of the implant being in place, the non-inflammatory peri-implant tissue was of note, the sulcus of which extended down epithelially over the years, thus reducing the amount of active bony interface. The patient fell off a bicycle at the end of 2003 and fractured the implant in the re-

**\_To date, implant fractures** are regarded as an extreme situation, to be feared due to the severe injuries to the jaw and the destruction of the supra-contruction. The reality is often different in cases of the effects of force (fall, blow, etc.). Fracture of the implant often remains the exception, as screws or abutments fracture instead, or the damage to the bone remains manageable and repeat treatment is possible. The following case shows the procedure for a replacement implant with an IMPLA screw implant after fracture of a ceramic implant.

Ceramic implants are susceptible to fracture due to their hard and brittle properties.<sup>1</sup> Furthermore, surrounding epithelial growth into the depths of the alveolus has been observed for such implants<sup>2</sup>, which can result in subsequent loss of the entire implant with no bleeding. The possibility of a replacement implant is therefore generally always an option and

- Fig. 1**\_Original situation following fracture, frontal view.
- Fig. 2**\_X-ray (section) of the fractured implant.
- Fig. 3**\_Fractured implant.
- Fig. 4**\_Pilot drilling to extend the depth of the implant cavity.
- Fig. 5**\_After mechanical preparation of the implant cavity the cutter is now applied.
- Fig. 6**\_After the thread is cut the implant is placed in the bony cavity.
- Fig. 7**\_Implant in situ.
- Fig. 8**\_Suture closure of the trapezoidal flap.



# 42<sup>ND</sup>

## INTERNATIONAL ANNUAL CONGRESS OF THE DGZI



October 5–6, 2012


Hamburg//Elysee Hotel



Gold Sponsor:



Silver Sponsor:



Bronze Sponsor:



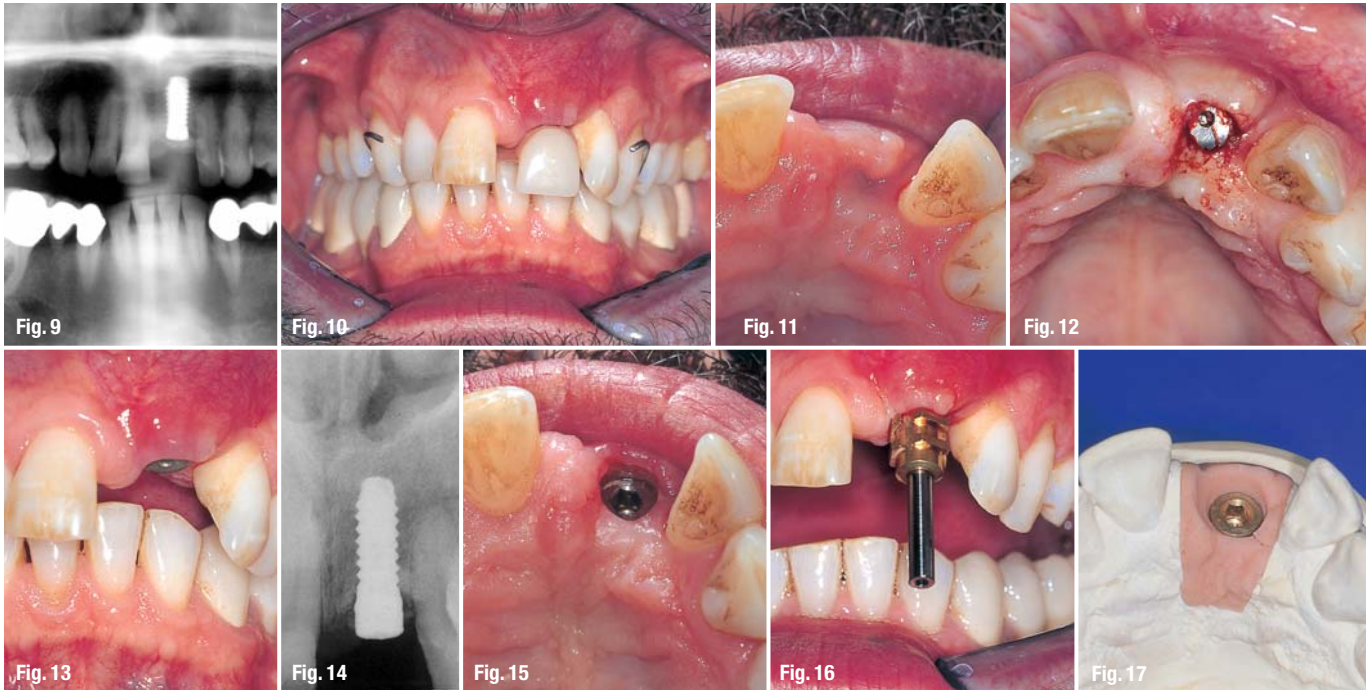
### FAX REPLY

**+49 341 48474-390**

Please send me further information on the  
42<sup>ND</sup> INTERNATIONAL ANNUAL CONGRESS  
OF THE DGZI October 5–6, 2012, in Hamburg, Germany.



Office Stamp



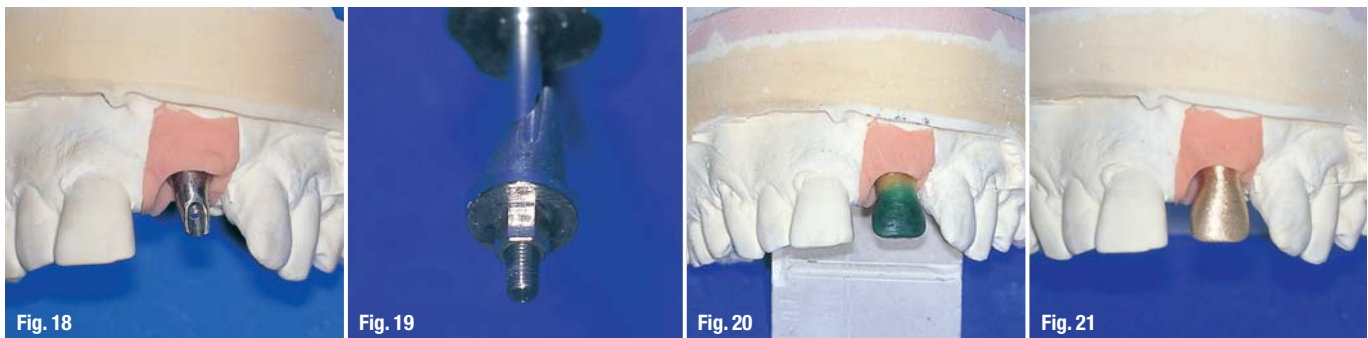
**Fig. 9** OPG after implantation.  
**Fig. 10** Temporary restoration with a removable denture.  
**Fig. 11** Situation after healing process, seen from occlusal view.  
**Fig. 12** After opening up.  
**Fig. 13** Situation with the gingiva former.  
**Fig. 14** Implant with good osseointegration.  
**Fig. 15** Gingival situation after opening up.  
**Fig. 16** Inserted impression post.  
**Fig. 17** After taking the impression the model with gingiva mask is produced.  
**Fig. 18** Adapted abutment.  
**Fig. 19** Internal hexagon to prevent rotation.  
**Fig. 20** Model of the crown.  
**Fig. 21** Processed crown cap prior to application of the ceramic.

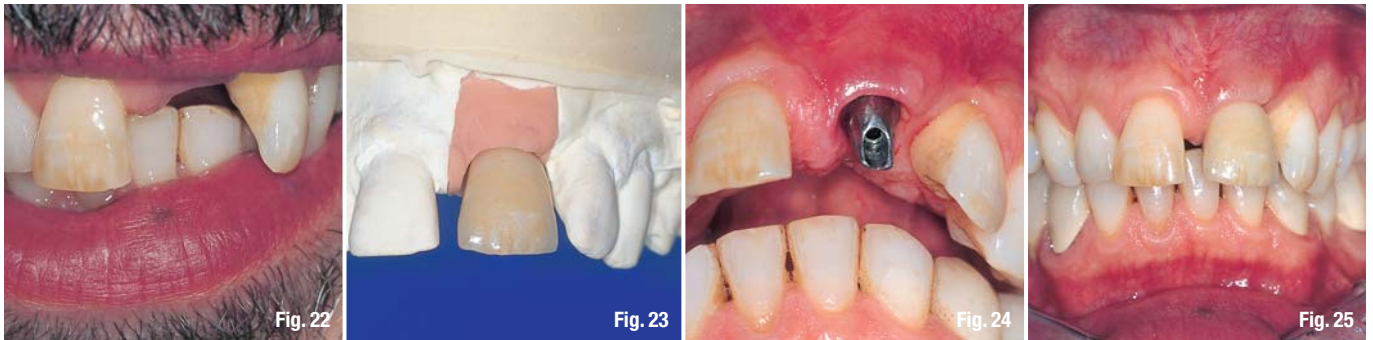
gion of the neck, losing the prosthetic crown (Fig. 1). Figure 2 shows the situation on an X-ray image. The patient was treated with antibiotics (Clindamycin 900 mg/d), the planned intervention was explained to the patient and the removal of the implant and new implant planned for two days later. After preparation of a trapezial flap with a crestal incision and removal of the ceramic implant (Fig. 3), the deep-seated epithelium and connective tissue was removed and the remaining bony cavity prepared for the placement of a new implant with a greater diameter (Fig. 4). The remaining implant bed was revealed to be a very solid cortical structure, such that a thread had to be pre-cut for the new implant (Fig. 5). The IMPLA implant (Schütz Dental Group, Rosbach), 14.5 millimetres in length and with a diameter of 5.3 millimetres, was inserted and the insertion aid was removed (Figs. 6 & 7). To compensate for the loss in bone height in the crestal region, an augmentation was carried out using BioOss (Geistlich) and covered with the resorbable membrane, Ossequest (W. L. Gore, Putzbrunn). The membrane was fixed in place using the implant's cover screw and the margins of

the muco-periostal flap. The site of the operation was closed with 9 simple interrupted sutures (Fig. 8) after mobilization of the muco-periostal flap through periost slitting and a control X-ray was taken (Fig. 9).

During the 6-month healing phase, a denture with a prosthetic tooth anchored with a clamp was worn (Fig. 10), which had been relined underneath with Flexor CC (Schütz Dental, Rosbach) to prevent any pressure on the site.

Following healing (Fig. 11), the covering mucosa was opened with a semi-circular cut with a scalpel under local anaesthetic (Fig. 12) and a cylindrical gingiva former, 2 mm in height, was inserted (Fig. 13). The X-ray shows an implant with good osseointegration (Fig. 14) and, to a large extent, maintenance and restoration of the gingival structures (Fig. 15). Only the papillary region between 21 and 22 is reduced. The prosthetic treatment was conducted after the gingival tissues had healed. The impression was made using Impregum (3M ESPE, Seefeld) and





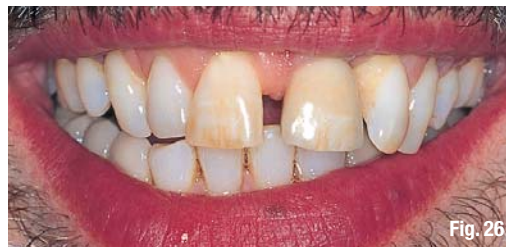the open tray technique (Fig. 16). The model made from type-IV gypsum with a gingival mask permits the production of an aesthetically high-quality crown (Fig. 17). An angled abutment was selected to correct the angulation and adapted to follow the line of the gingiva (Fig. 18). The internal hexagon connection prevents rotation (Fig. 19). A cementable metal ceramic crown, based on an alloy with a high gold content that can be fired, completes the restoration (Fig. 20). The diastema at the front was left in accordance with the patient's wishes, as was the slightly rotated and paradontally worn no. 2 (Fig. 21). The otherwise triangular crown of the no.1 was rounded off distally so that the papillary triangle between 21 and 22 was less prominent. The colour was adjusted to the lively colour of 11 in the laboratory in the presence of the patient (Figs. 22 & 23). The abutment (Fig. 24) was screwed in at a torque of 20 N/cm and the crown was inserted for three weeks on a provisional basis (Fig. 25).

Final cementing has not yet been carried out as the temporary cementing is very stable and it was not possible to remove the crown using adequate means. Figure 26 shows the lips and a portrait of the patient. The functional and aesthetic restoration was therefore successful.

## Discussion

Rapid treatment in cases of second implantations is advantageous, as the alveolar bone is not changed any further or resorbed. Treatment with an antibiotic such as Clindamycin, that penetrates into the bone, should always be administered first to restrict the peri-implant inflammation and inflammation due to the fracture. A closed approach and adherence to the standard required healing time is to be favoured in cases of an additional fracture of the alveolar bone or differences between the geometry of the implant and bone availability, which both require augmentation procedures. Situations where a diastema is present are particularly complicated from an aesthetic perspective. The division of the gap when using conventional prosthetics usually produces unsatisfactory results as the teeth with a replacement crown

are wider than those without. In such cases, an implant is the only viable alternative. The no. 2 that was rotated in the current case was fashioned more aesthetically through application of a direct or indirect veneer and build-up of the papilla. However, the patient's consent is prerequisite to this.



**Fig. 22** The gap requiring restoration.  
**Fig. 23** Fired ceramic crown.  
**Fig. 24** Inserted abutment.  
**Fig. 25** Crown in situ.

**Fig. 26** Oral situation.

Dispensation with or a temporal delay to conventional permanent cementing does not constitute a contradiction to the production of a cemented crown. The timing of the final restoration can easily be delayed as the abutment is not susceptible to attack by caries and loosening of the crown is rapidly noticed. The crown is checked for loosening at the regularly spaced recall appointments.

*Editorial note: A list of references is available from the publisher.*

## contact

## implants

### Dr Michael Hopp

Kranoldplatz 5, 12209 Berlin, Germany

### ZTM Andreas Klar

Certified Dental Technician  
 Dental Laboratory Rübelling & Klar  
 Ruwersteig 43, 12681 Berlin, Germany

### Prof Dr Reiner Biffar

Ernst Moritz Arndt University of Greifswald  
 Centre of Dentistry and Oral Health  
 Dept. of Prosthetic Dentistry and Dental Materials  
 Rotgerberstr. 8, 17475 Greifswald, Germany