

CAD/CAM patient-specific abutments and a new implant design

Authors_Prof Dr Frank Liebaug & Dr Ning Wu, Germany

Introduction

The objective of any dental reconstruction is the natural, functional reconstruction of the stomatognathic system and the functionally unimpaired or functionally treated masticatory organ. This objective can only be achieved if individual patient parameters and distinctive anatomical features are incorporated into surgical planning and the subsequent prosthetic restoration.

Implant-prosthetic care methods must be established as independent therapy alternatives for specialists and patients, and the possibility of achieving this objective is high. With attention focused on the prosthetic functional aspects of implantology, the prosthetic therapy objective is currently becoming the focal point of all efforts.

From the point of view of the practising dentist, the main emphasis in treatment planning for implant-supported dentures is placed on the prosthetic specialist. If said specialist is also trained in implants and surgery, he will place the implant him-

self as a support measure for his prosthetic therapy, which results in great simplification with regard to planning and the treatment process. As a rule, however, a dentist who deals with prosthetics will complete his implant prosthesis in close collaboration with an oral surgeon or oral-maxillofacial surgeon.

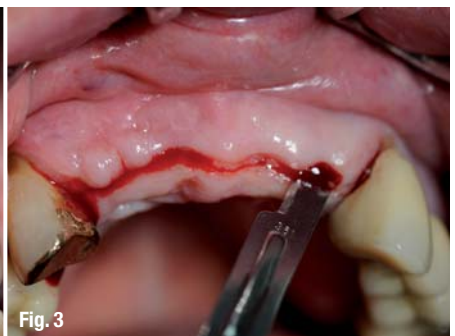
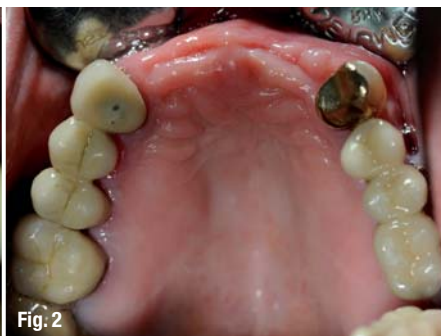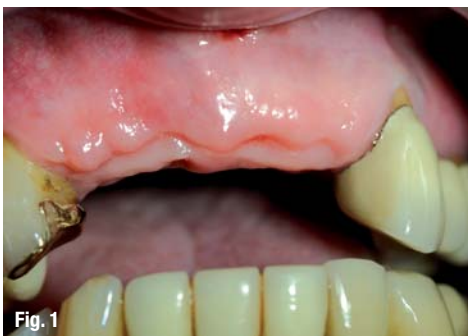While surgeons are concerned with the best possible implant procedure or implant design, prosthetic specialists bring us back to the starting point of implantology: the patient's wishes. Patients do not want implants; rather they want beautiful new teeth with which they feel confident in day-to-day life.¹

Team-work is gaining increasing importance in this regard, since, depending on the functional prosthetic objective, prosthetic specialists, dental technicians and implant surgeons might have to work together on the optimal implementation of the planned results using navigation and CAD/CAM systems. In the future, this method of integrating implantology will be found in just about every practice. As the hardware for 3-D planning is currently very

Fig. 1 Maxillary anterior gap in regions 12, 11, 21 and 22 (Kennedy Class IV), four months after implant insertion.

Fig. 2 Occlusal view of the maxilla with an interdental gap between teeth #13 and 23.

Fig. 3 Implant exposure four months post-op.



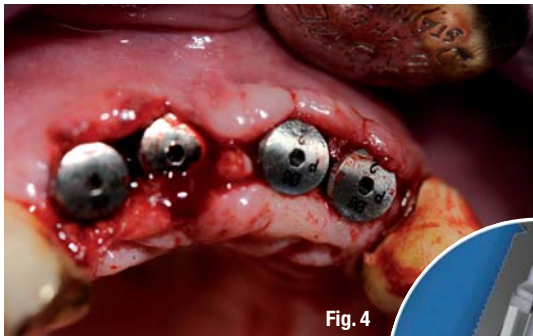


Fig. 4

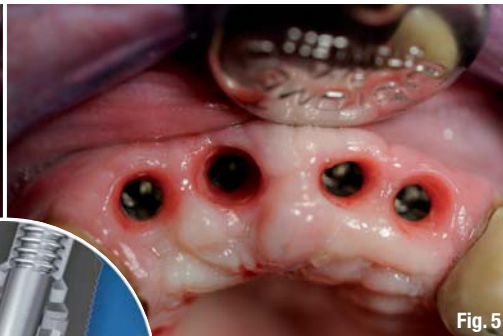

Fig. 5

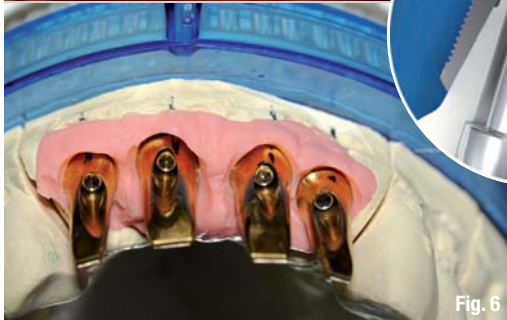

Fig. 6

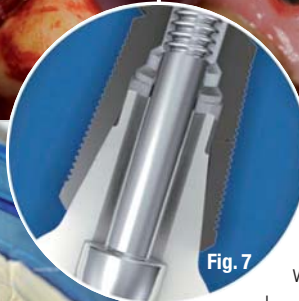


Fig. 7

Fig. 4_ Condition immediately after the healing abutments were placed (height of 2 mm).
Fig. 5_ Three weeks of good healing and moulding of the peri-implant soft tissue.
Fig. 6_ Schematic depiction of the Conical Seal Design for a custom-fitted conical connection between the implant and abutment.
Fig. 7_ Abutments on the master cast with the gingival mask.

tures using the CNC (computer numerical control) procedure began more than ten years ago. Attempts with this kind of CAD/CAM technology demonstrated that the achievable precision of current constructions—between 20 and 30 μm —is better than the precision of fit achieved with cast precious metal structures.³

expensive, dentists should seek suitable partners to support them in the integration of current therapy options.

Furthermore, from a biological and an economic perspective, production should rely on the most biologically compatible material with sufficient mechanical stability, for example titanium and cobalt-chromium alloys. Zirconium oxide is also an option. However, in terms of casting engineering, the processing of these alternative materials does not offer sufficient precision of fit. Cast implant structures manufactured from non-precious metals have been found to exhibit gaps with an average width of 200 to 230 μm between the superstructure and the implant abutment.² In contrast, cast structures manufactured from precious metal alloys have been found to have gaps with an average width of 40 to 50 μm .³ The use of alternative materials thus requires the use of alternative production technologies, if only to obtain the required precision.

Ideally, a superstructure is milled from an industrially prefabricated solid material in order to eliminate inhomogeneities safely. Following this line of thought, milling-based manufacture of superstruc-

With modern scanning and software technology, this production principle has been extended to the area of virtual construction. Thus, the CNC milling procedure, which has been used for years, is supplemented with the possibility of a purely virtual construction. This technology is now offered by various manufacturers.

_Objective

Our objective as specialists must not only be the replacement of a lost tooth as soon as possible after extraction, but also be the satisfaction of our patients' constantly increasing aesthetic demands—with regard to the anterior tooth area in particular—through suitable bone and soft-tissue management.

Thus, even when the implant is being inserted, preference must be given to keeping the crestal bone structure as unchanged as possible because in this way the interdental papilla and the peri-implant gingiva can be maintained in the long term.⁴

_Case presentation

The realisation of the patient's wish was facilitated in the following case in close collaboration

Fig. 8_ Virtual 3-D model for abutment planning below the subsequent crowns.
Fig. 9_ Virtual 3-D model for patient-specific abutment planning.
Fig. 10_ Occlusal view of the abutment and adjustment thereof.

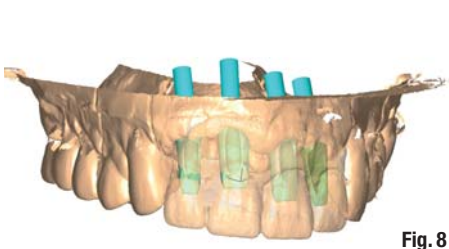


Fig. 8

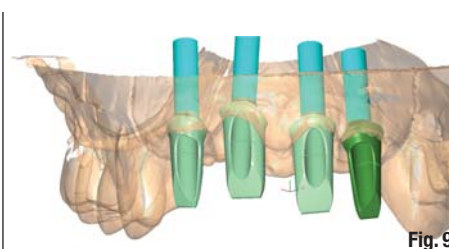


Fig. 9

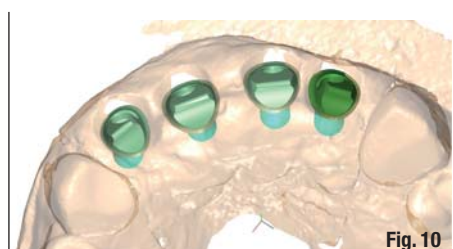

Fig. 10



Fig. 11 Patient-specific abutment prior to insertion.

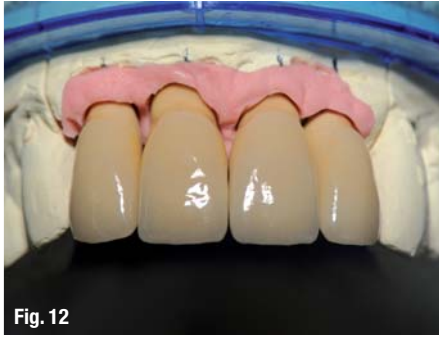

Fig. 12 Complete individualised crown restoration on master cast.

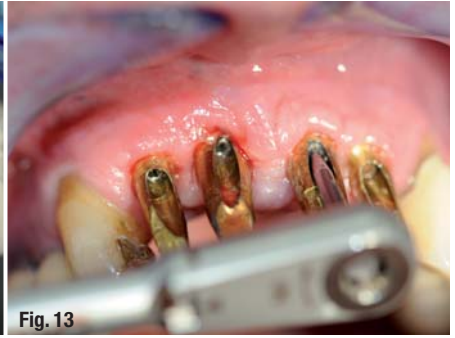

Fig. 13 Abutment insertion and mounting with a torque wrench at 25 Ncm.

Fig. 11 Patient-specific abutment prior to insertion.

Fig. 12 Complete individualised crown restoration on master cast.

Fig. 13 Abutment insertion and mounting with a torque wrench at 25 Ncm.

with Zahntechnik Zentrum Eisenach after the tooth replacement was firmly in place, despite alveolar bone loss and difficult gingival conditions (Figs. 1 & 2). The surgical procedure for this case is described in Liebaug and Wu (2011).⁵

The anatomically formed and bevelled OsseoSpeed TX Profile implants (DENTSPLY Implants) were used in regions #12, 11, 21 and 22. These implants are specially designed to preserve the marginal bone in an alveolar ridge with angular atrophy both vestibularly and orally, that is, 360 degrees around the implant.⁶ Restoration with patient-specific ATLANTIS abutments (DENTSPLY Implants) was planned in order to complete prosthetic restoration optimally after successful implantation and osseointegration. As described in Noelken (2011),⁷ the marginal bone can be preserved cheaply by the use of these implants, which are new to the dental market. Optimal soft-tissue support can be achieved with individualised manufactured abutments.

Challenge in terms of maxillary anterior tooth loss

While replacing a missing tooth with an implant can now be considered routine, rehabilitation in the maxillary anterior region still represents a particular challenge for the treatment team. In addition to successful osseointegration of the implant, particular attention must be given to functional and aesthetic parameters to achieve a restoration that perfectly harmonises with natural teeth.⁸

Prior to surgery: Addressing the patient's wishes and providing information

The patient's wishes must always be considered before treatment begins. The patient should be offered clarification prior to treatment, particularly in difficult initial situations with evident hard-tissue loss and unfavourable gingival conditions. For forensic reasons, photographic documentation of the initial situation is an indispensable aid in addition to diagnostic casts. It should also be used as the basis for discussion with the patient.

If bone on the labial side has already been lost and the optimal bone contours have not been restored with a bone transplant, achieving the desired aesthetic result is nevertheless often not difficult.

In terms of this 67-year-old patient, the implants were exposed by incision to the middle of the alveolar ridge from regions #12, 11, 21 and 22 after a four-month healing phase (Fig. 3).

It should be noted that, owing to the bevelled design of the implants used, an almost seamless insertion into the natural osseous alveolar process is achieved, and thus the plastic cover and the primary wound closure are simplified for the surgeon. This is also the basis for a quick and smooth healing process.

Three-dimensional bone structures can be preserved using the above-mentioned OsseoSpeed TX

Fig. 14 Occlusal view of the inserted abutment.

Fig. 15 Closing of the screw opening with Cavit (3M ESPE) prior to cementing the superstructure.

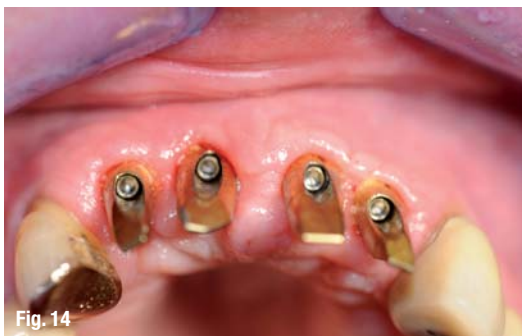

Fig. 14

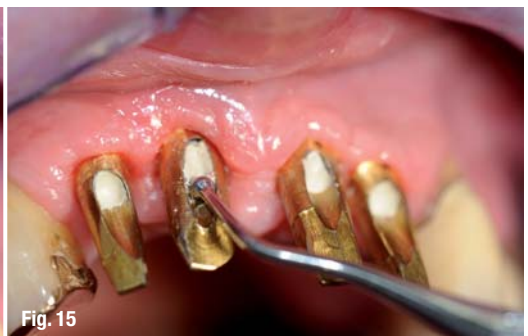

Fig. 15

Profile implant. Healthy bone is a prerequisite for optimal prosthetic restoration with regard to aesthetics. The otherwise often necessary hard- and soft-tissue transplants can now mostly be avoided.⁵

The extent to which a temporary restoration can be screwed together after prosthetic pretreatment and after the implant region has been moulded, or whether a removable device can be used temporarily, depends significantly on the patient's financial resources. In addition to the use of gingiva formers native to the system, temporary restorations aid the moulding, preparation and stabilisation of the peri-implant soft tissue during and after the healing phase. As the interim prosthesis guaranteed functionality and aesthetics that satisfied the patient, additional moulding of the soft tissue was achieved through special gingiva formers or healing abutments (Figs. 4 & 5).

The results obtained in terms of preservation of the marginal bone using the AS-TRA TECH Implant System (DENTSPLY Implants) are documented in Palmer et al. (2000) and Wennström et al. (2005).^{9, 10} Preservation of the marginal bone level and healthy soft tissue are indispensable for the long-term success of implant treatment both clinically and aesthetically. The bone provides the soft tissue with stability, while the soft tissue protects the bone from micro-organisms.

A special feature of the implant system used is the patented Conical Seal Design, which prevents micro-movements and micro-gaps at the interface between the implant and abutment, reliably protecting the implant and bone from bacteria. The clinical relevance of the pump effect caused by micro-movement and possible crestal bone resorption were experimentally tested by Zipprich et al. (2007).¹¹ Furthermore, arising stress is distributed farther into the bone and peak loads are simultaneously reduced.^{12, 13} In this regard, the preference for preserving the marginal bone level must be clarified as well. The implant-abutment connection is thus reliably sealed against bacteria and the bone is thereby protected from external influences. Maintenance of the superstructure is also made easier for the patient.

The integration of the abutment is simplified by the conical implant-abutment connection (Fig. 6). However, with regard to the bevelled OsseoSpeed TX Profile implants, particular attention must be given to the precise transfer of the clinical situation to the model being manufactured using moulding aids and transfer posts during precision moulding, which requires specific experience and a good instinct.

The individualised ATLANTIS abutments are a good solution for cemented crowns or bridges, as they guarantee optimal functionality, are the basis for sophisticated prostheses and are easy to use.

ATLANTIS abutments fabricated from titanium, titanium nitride-coated titanium (ATLANTIS GoldHue) or zirconium oxide are available for all established implant systems. All abutments are supplied by the manufacturer with the corresponding abutment screws. The ATLANTISVAD (virtual abutment design) software allows the production of abutments that are based on the final tooth form and thus guarantees not only a natural, aesthetic result but also optimal functionality. A model was produced from the impression following healing, implant exposure (Fig. 3) and insertion of temporary gingiva formers (Fig. 4).

The master cast should have a stable removable gingival mask made of silicone (Fig. 7). Casts should be placed onto articulators before the dentist or dental laboratory sends them in to Astra Tech so they can subsequently be sent with the ATLANTIS CaseSafe shipping box. The models can be converted into a virtual image using a 3-D scanner after the model has been produced in a high-tech dental lab-

Live, Interactive Webinars and On Demand Courses

A growing education platform where you can find more than 400 dental courses, live Webinars, live Education Symposia.

Interested in C.E. credits and quality learning?

Learn from the experts:

| | |
|----------------------|----------------------|
| Richard Niederman | Marius Steigmann |
| Louis Malcmacher | David Hoexter |
| Eduardo Mahn | Dwayne Karateew |
| Robert Horowitz | Fotinos S. Panagakos |
| Paul Weigl | George Freedman |
| Shamshudin Kherani | Howard S. Glazer |
| Christian Coachman | Lynn Mortilla |
| Ron Kaminer | Maria Emanuel Ryan |
| Edgar Garcia Hurtado | Michael Glick |
| Glenn van As | Peter Barry |
| Marc Gottlieb | Barry Levin |
| John Fluke | Fay Goldstep |

Interested in sponsoring education?

Some of our partners:



Register for FREE on www.DTStudyClub.com

How to receive your C.E. Credits?

1. Go to www.DTStudyClub.com and log in.
2. Not a member yet? Register for a free account.
3. Find the courses you're interested in and register to access them.
4. Watch the course.
5. Take the Quiz and print the C.E. certificate.

ADA CERP® | Continuing Education Recognition Program

ADA CERP is a service of the American Dental Association to assist dental professionals in identifying quality providers of continuing dental education. ADA CERP does not approve or endorse individual courses or instructors, nor does it imply acceptance of credit hours by boards of dentistry.

Fig. 16 Condition immediately after placement of the individualised crown restoration.

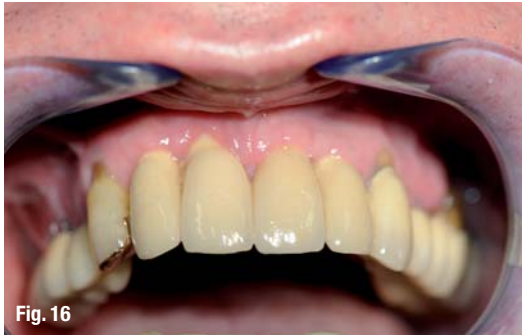
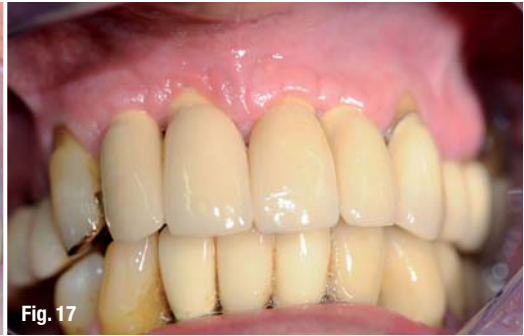
Fig. 17 Despite difficult soft-tissue conditions, a good gingival stippling effect was achieved in the cervical area, which attests to sufficient osseous support.



oratory or after the model has been sent, should no scanner be available immediately (Figs. 8–10).

After the specialist has confirmed the virtual abutment design, which is sent via e-mail, the ATLANTIS abutment is manufactured, verified and sent to the attending dentist (Figs. 7 & 11). Individualised prostheses can be manufactured in the dental laboratory after the precision of fit and the position of the patient-specific abutment have been verified (Fig. 12).

It must always be ensured that the abutment screw delivered with the abutment is used for the final insertion of the abutment in the mouth. The ATLANTIS abutments are designed to correspond to the form of the dentine core of natural teeth. Of course, the ATLANTIS VAD software allows for consideration of the specialist's preferences, which should take the patient situation into account, with regard to the production of the individualised abutment. The size of the abutment is determined by the average profile created by the form and size of the healing or temporary abutment.

The mucosa may be temporarily anaemic when the abutment is inserted into the patient's mouth (Figs. 13–15). ATLANTIS abutments are manufactured with standard gingival moulding if the specialist does not select or provide any particular options when the order is placed.

Considering the extremely unpromising initial situation (Figs. 1 & 2), a result that was satisfying in terms of functionality and aesthetics for both the patient and the dental/prosthetic specialist was achieved after the individualised crown restoration had been placed (Figs. 16 & 17).

The patient's wish for stable and natural-looking teeth was fully satisfied, which was ultimately the main criterion and motivation for our efforts as the treating team. Additional improvement of the soft-tissue situation is expected if the patient adheres to the appropriate cleaning technique.

Conclusion

Implantology is a central component of modern therapy procedures in dentistry. Continuous development of materials, implant design and the relevant technologies seeks to obtain high reliability with a good long-term prognosis for a wide range of indications. Careful diagnosis and detailed planning are indispensable if patients' increasing demands are to be satisfied. In particular, care in aesthetically demanding clinical situations requires interdisciplinary treatment in many cases. The possibilities presented by this case report for the production of patient-specific abutments on anatomically formed and bevelled OsseoSpeed TX Profile implants constitute a gain and are the basis for long-term success, even in the event of reduced bone and difficult soft-tissue conditions.

Acknowledgement

The authors would like to thank Z.T.M. Blum from the Zahntechnik Zentrum Eisenach for his collaboration and laboratory work, as well as Franzisko Fischer from Astra Tech for his support during planning. Finally, we would like to offer special thanks to my father, Manfred Liebaug, who supported us throughout, from surgery to prosthetic placement, as well as while exploring new methods.

| | |
|--|-----------------|
| _contact | implants |
| <p>Prof Dr Frank Liebaug Praxis für Laserzahnheilkunde und Implantologie Arzbergstr. 30 98587 Steinbach-Hallenberg Germany</p> <p>Tel.: +49 36847 31788</p> <p>frankliebaug@hotmail.com</p> | |

Under the Patronage of
H. H. Sheikh Hamdan Bin Rashid Al Maktoum
Deputy Ruler of Dubai, Minister of Finance
President of the Dubai Health Authority

تحت رعاية
سمو الشيخ حمدان بن راشد آل مكتوم
نائب حاكم دبي، وزير المالية
رئيس هيئة الصحة بدبي



UAE INTERNATIONAL DENTAL CONFERENCE & ARAB DENTAL EXHIBITION

5 - 7 February, 2013

Dubai International Convention & Exhibition Centre

Delivering Science & Technology

www.aeedc.com

- Excellent platform to network with over **28,000** dental professionals and oral health care providers.
- More than **900** exhibitors from **80** representing countries.
- **3 days** of quality education and business opportunities.



Find AEEDC Dubai on

BlackBerry
PIN: 286FC1C7



twitter



facebook



LinkedIn



YouTube



Organised by



In Cooperation with



Strategic Partner



Supported by

ADA CERP Continuing Education
Recognition Program

INDEX Conferences & Exhibitions Organisation Est is an ADA CERP Recognized Provider.
ADA CERP is a service of the American Dental Association to assist dental professionals in identifying quality providers of continuing dental education. ADA CERP does not approve or endorse individual courses or instructors, nor does it imply acceptance of credit hours by boards of dentistry.
INDEX Conferences & Exhibitions Organisation Est. designates this activity for continuing education credits on an hour for hour basis.

INDEX® Conferences & Exhibitions Organisation Est.

Dubai Healthcare City, Ibn Sina Medical Complex #27, Block B, Office 203 | P.O. Box: 13636, Dubai, United Arab Emirates
Tel: +971 4 3624717, Fax: +971 4 3624718 | E-mail: info@aeedc.com, Website: www.index.ae