

The early abutment technique

Author_Dr S. Marcus Beschmidt, Germany

Information on patient and treatment

The female patient was 40 years old at the beginning of the treatment. The high smile line and the thin gingival phenotype significantly complicated the case. Tooth 11 and tooth 12 had grayish crowns and livid gums. The roots of both of the two teeth had been treated, before a metal pin had been inserted in tooth 11 alio loco. An apicoectomy had also been conducted on tooth 12, which had left scarring with partial retraction of the gingiva. The apicoectomy was not fully healed when the medical history was taken, and the root canal filling at tooth 12 appeared too short apically.

Tooth 11 had to be atraumatically removed, and we decided in favor of an immediate implant placement followed by a temporary restoration using a temporary shell crown. An impression was taken during the procedure with the "early abutment technique" to allow the implant position to be transferred to the master cast for early manufacture of the final abutment.

After regenerative measures for rebuilding hard and soft tissue by the pouch technique and delivery of the long-term temporary denture, the patient was discharged. The final abutments were placed only two days later and were not unscrewed, again. This was the only way of establishing a thick periimplant soft-tissue collar and minimizing the soft-tissue retrac-

tion. The final full-ceramic crown was placed twelve months later.

Initial situation

The patient had a smile line level with and above the cervix. The line of the gingiva and upper lip appeared irregular (Fig. 1). Incipient papilla loss could be seen in regions 11 to 13. The gum showed scarring as a result of a previous apicoectomy. The crowns appeared gray. The gingiva had a livid discoloration, where the dark root stumps showed through because of the thin phenotype (Fig. 2). The crowding of teeth 11 and 12 and the convoluted dentition made the situation implantologically and esthetically difficult (Fig. 3).

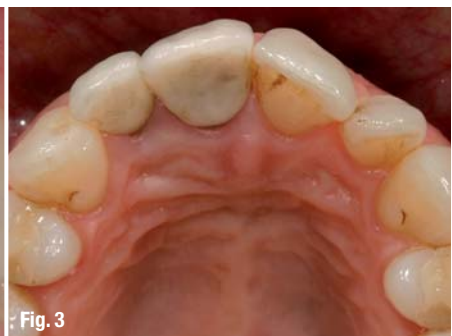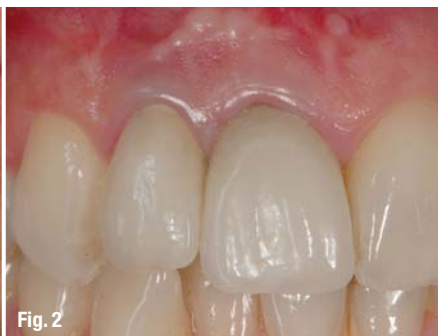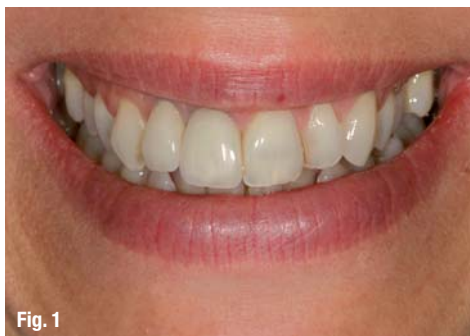Atraumatic removal of the residual root

A metal pin placed alio loco was visible at tooth 11. The apicoectomy had not yet healed. The root canal filling at tooth 12 appeared too short at the apex (Fig. 4). To remove tooth 11, a computer-controlled injector (The Wand, Milestone) was used for a palatal injection. This protects the scarred tissue almost completely and does not affect the blood supply (Fig. 5). Atraumatic removal of the residual root 11 followed. The inflamed tissue was completely scraped out (Fig. 6).

Fig. 1 Initial situation: smile line level, line of the gingiva and upper lip.

Fig. 2 Scarring of the gum as a result of a previous apicoectomy.

Fig. 3 Crowding of teeth 11 and 12, convoluted dentition.



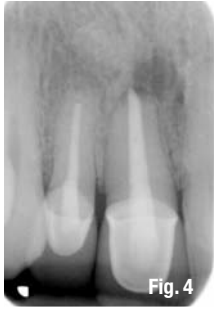

Fig. 4

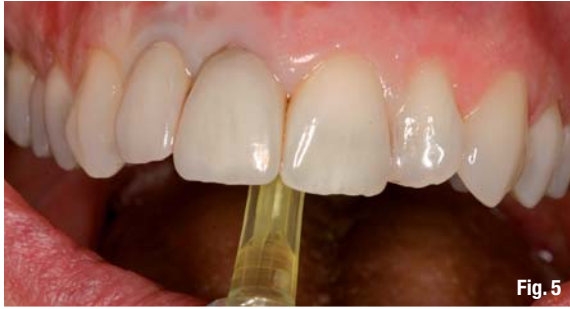

Fig. 5

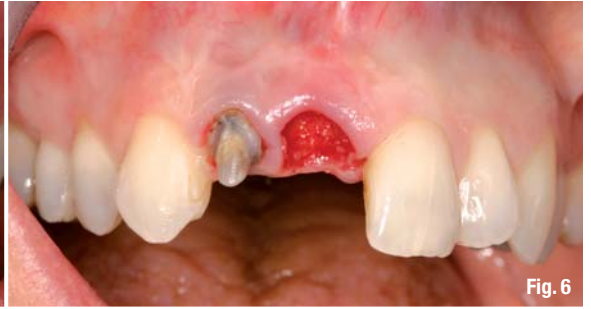

Fig. 6

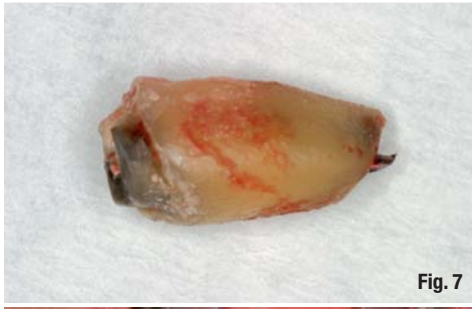

Fig. 7

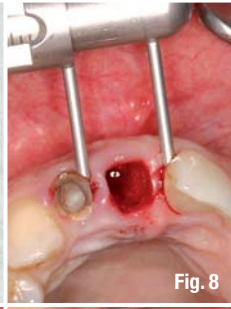


Fig. 8

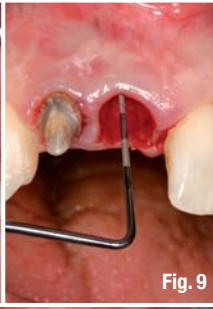

Fig. 9

Fig. 4 Metal pin placed alio loco visible at tooth 11.

Fig. 5 Palatal injection via computer-controlled injector (The Wand, Milestone).

Fig. 6 Atraumatic removal of the residual root 11.

Fig. 7 Metal pin on the apex of the removed root.

Fig. 8 Measuring of the implant diameter with a vernier caliper (Zepf Medizintechnik).

Fig. 9 Probing of the alveolar cavity with the periodontal probe.

Fig. 10 Insertion of the form drill into the alveolar cavity.

Fig. 11 Insertion of a CAMLOG® Screw-Line Promote® implant.

Fig. 12 Impression-taking.

Fig. 13 Details of the impression.

Fig. 14 Relining of a temporary shell crown on a titanium abutment.

Fig. 15 Positioning of the temporary shell crown via insertion key.

Fig. 16 Filling of the labial gap with a non-resorbable bone replacement material.

Fig. 17 Compression of the soft tissue with a free subepithelial connective tissue graft.

Fig. 18 Connective tissue graft in situ.

Fig. 19 Cementation of the trimmed provisional crown.

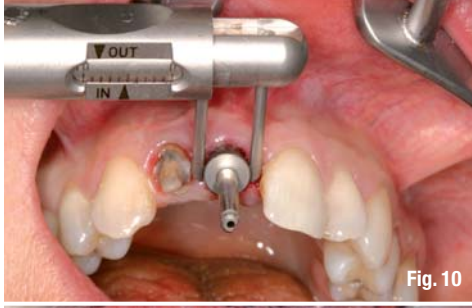

Fig. 10

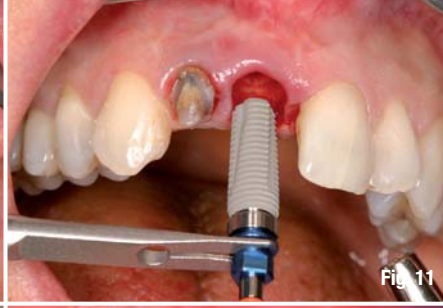

Fig. 11

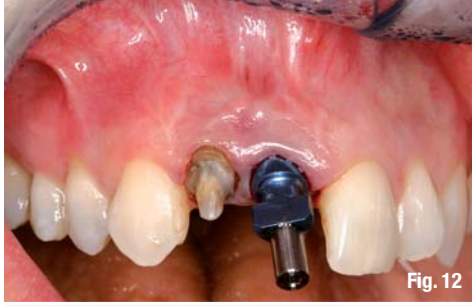

Fig. 12

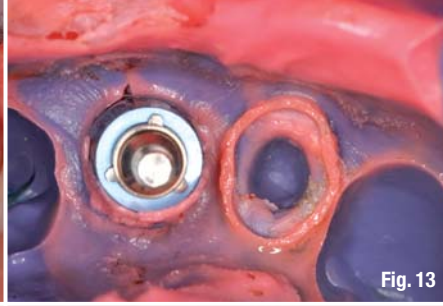


Fig. 13

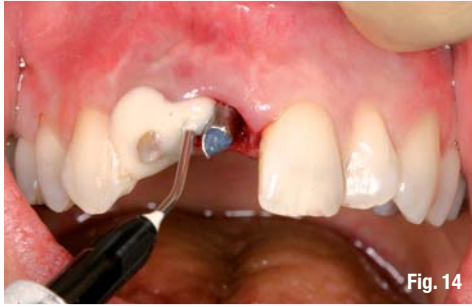


Fig. 14

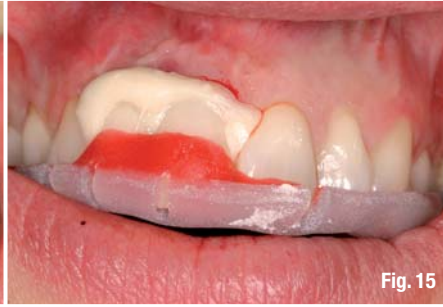

Fig. 15

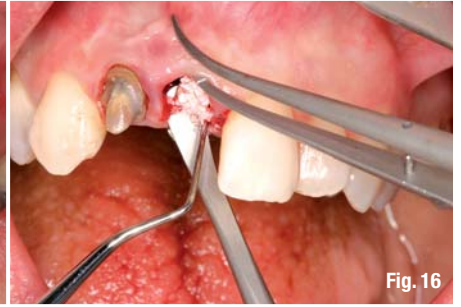

Fig. 16

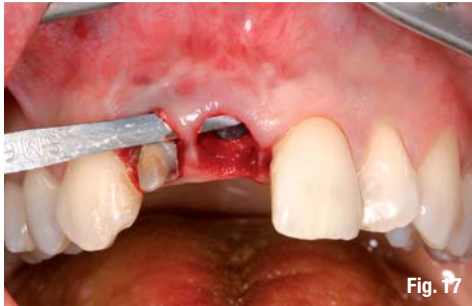

Fig. 17

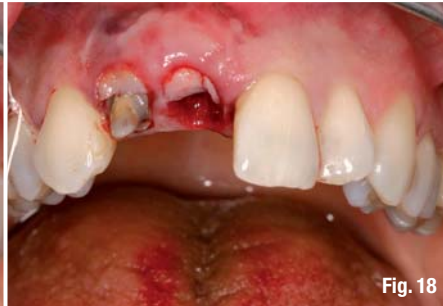

Fig. 18

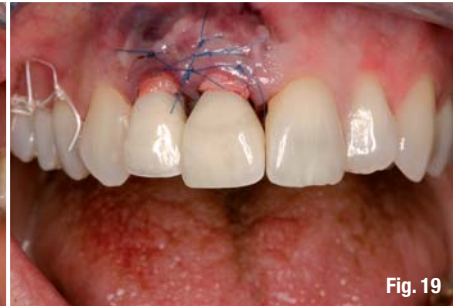

Fig. 19

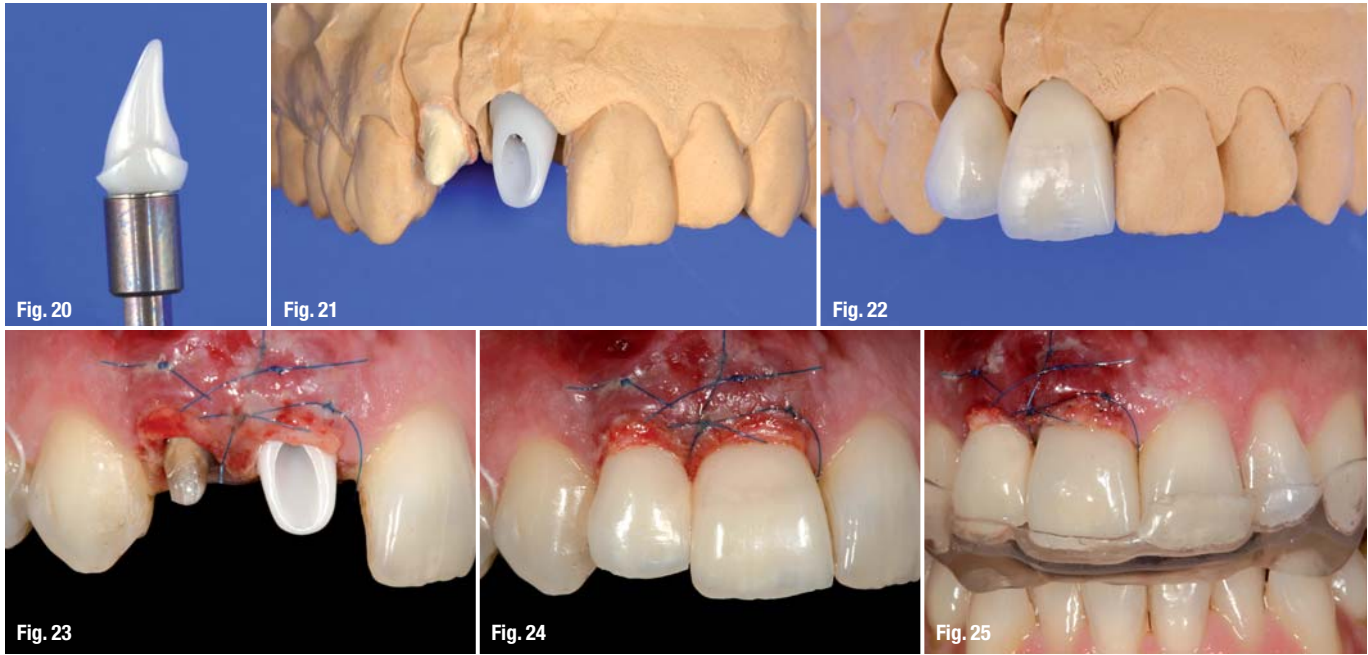


Fig. 20

Fig. 21

Fig. 22

Fig. 23

Fig. 24

Fig. 25

Fig. 20_Ceramic abutment cemented to a titanium base.

Fig. 21_Definitive screw-retained abutment on the lab analog.

Fig. 22_Splinting of the long-term temporary crown in region 11 with the crown on the natural stump.

Fig. 23_Two days post-op.

Fig. 24_Fixed long-term temporary crown.

Fig. 25_Michigan splint to protect the surgical site from pressure.

_Implant placement

The metal pin was clearly visible on the apex of the removed root (Fig. 7). Accurate measurement of the alveolar cavity is essential with immediate implant placement. This is the only way to find out where the bone is and whether it is intact. The implant diameter was measured with a vernier caliper (Zepf Medizintechnik, Fig. 8). The alveolar cavity was also probed with the periodontal probe to detect any defects on the alveolar margin. The gingival height was analyzed as well in order to allow an estimate of future resorption (Fig. 9).

_Impression and temporary abutment

The planned implant axis and the distances to neighboring structures can be checked with the form drill inserted into the alveolar cavity (Fig. 10). Figure 11 shows the insertion of a CAMLOG® SCREW-LINE Promote® implant 5 mm in diameter and 16 mm long. Impression-taking with an impression post and open tray followed for fabrication of the "early abutment" and long-term tempo-

rary crown (Fig. 12). Fig. 13 gives the details of the impression for precise transfer of the implant position to the master cast. The temporary shell crown was relined on an intraorally marked and laboratory-customized titanium abutment. In low heights, titanium with its greater stability is more suitable than PEEK (Fig. 14). The temporary shell crown was positioned with the aid of an insertion key (Fig. 15). The labial gap between implant and alveolar cavity should be filled with a non-resorbable bone replacement material for bone and soft-tissue regeneration (Fig. 16). The soft tissue was compressed with a free subepithelial connective tissue graft. A pouch was prepared without vertical incision and without injuring the papillae (Fig. 17).

_Early abutment and long-term temporary denture

Figure 18 shows the connective tissue graft in situ; it is important to keep the papillae intact. In the meantime, the provisional crown was trimmed in the laboratory; it can be cemented in after screwing in the titanium abutment (Fig. 19). A ceramic abutment cemented to a titanium base was fabricated within two days. The zirconium-oxide-ceramic has a smaller diameter for platform switching (Fig. 20). Figure 21 depicts the definitive screw-retained abutment on the lab analog.

The long-term temporary crown in region 11 was splinted with the crown on the natural stump (Fig. 22). Two days post-op, the temporary titanium abutment was replaced with the definitive ceramic abutment (Fig. 23) and the long-term temporary

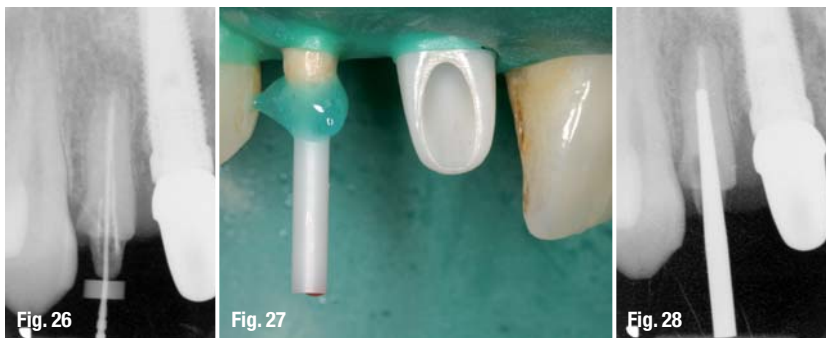

Fig. 26

Fig. 27

Fig. 28

Fig. 26_Revision of the root-canal treatment in region 12.

Fig. 27_Ceramic pin, fitted into the root canal and cemented in.

Fig. 28_X-ray examination of the inserted ceramic pin.

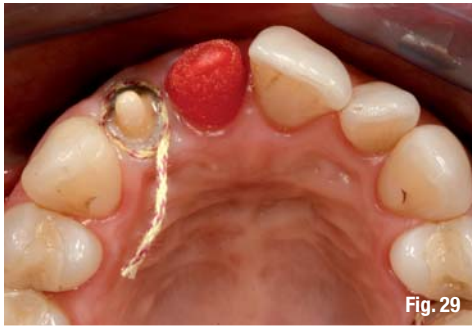

Fig. 29

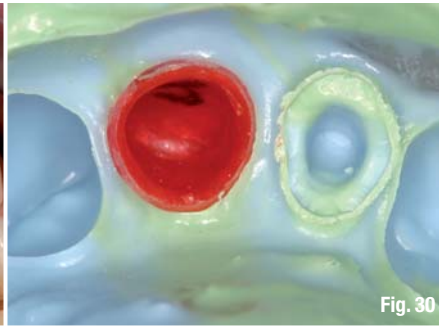

Fig. 30

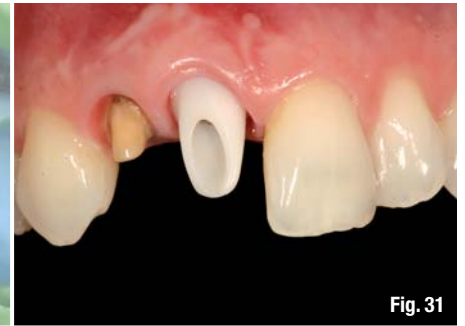

Fig. 31

crown was fixed (Fig. 24). It will remain in situ for at least six months, in this case, even for twelve months.

_Additional measures

A Michigan splint protects the surgical site from pressure. It should be worn for eating and sleeping for at least four weeks. Figure 26: The root-canal treatment in region 12 was revised. After revision of the root-canal treatment and internal bleaching, a ceramic pin was fitted into the root canal and cemented in (Fig. 27). Figure 28 gives the results of the X-ray examination of the inserted ceramic pin. In addition, impression-taking of the definitive abutment was conducted and the natural post for manufacture of the definitive full ceramic restoration was placed (Fig. 29). Figure 30: The position of the abutment was transferred to the master case with the aid of a plastic coping. Figure 31 shows the situation twelve months after implant placement: The tissue has matured and the gingival recession was minimal. Also, the definitive full-ceramic crowns were placed; the dentition was compensated to the contralateral teeth (Fig. 32). Care was taken not to crush the papillae between 11 and 21. Figures 33–35 give the results one year, two and five years after loading.

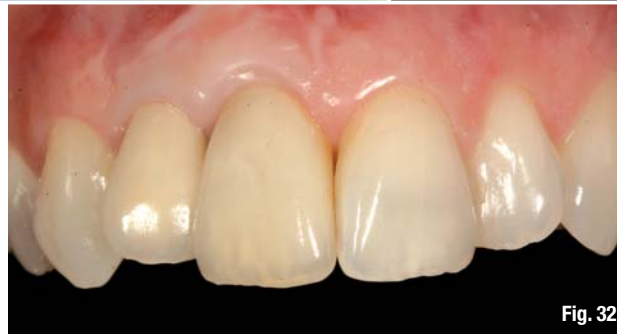

Fig. 32

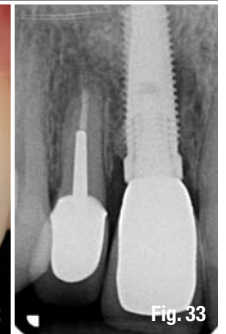


Fig. 33

crossurgery: few vertical incisions, minimal incisions, checking the bone and soft-tissue situation by probing. The healing phase should last at least six to nine months to allow the tissue to mature. In our experience, platform switching is also required after formation of the soft tissue, because the soft tissue has more space with this technique. The combination of techniques described here offers a way of increasing the probability of optimum tissue retention with the right indications.

Fig. 29 Impression-taking of the definitive abutment and the natural post.
Fig. 30 Transfer of the abutment position to the master case.
Fig. 31 Twelve months post-op.
Fig. 32 Twelve months post op: placement of the definitive full-ceramic crowns.
Fig. 33 X-ray one year after loading.

_Conclusion

In esthetically high-risk cases (high smile line, thin gingiva, prior operations), it is important to carry out all required measures in only one surgical procedure, if possible at all: atraumatic tooth extraction, scar correction, gingiva thickening, implant placement and possibly bone grafting. In this case, a partial socket preservation was conducted. Using the "early abutment technique" after two days –during the healing phase–the definitive ceramic abutment was placed and left in situ. As a result, the wound adhered to the abutment, and there was a tissue adhesion in the implant shoulder region.

This procedure has been in use in our practice since 2002 and has proven successful. A decisive factor is the application of minimally invasive mi-

_contact	implants
<p>Dr S. Marcus Beschnidt Privatpraxis für Zahnheilkunde Lichtentaler Allee 1 76530 Baden-Baden, Germany Tel: +49 7221 3939719</p> <p>info@beschnidt.com www.beschnidt.com</p>	

Fig. 34 Two years after immediate implant placement.
Fig. 35 Five years after loading.

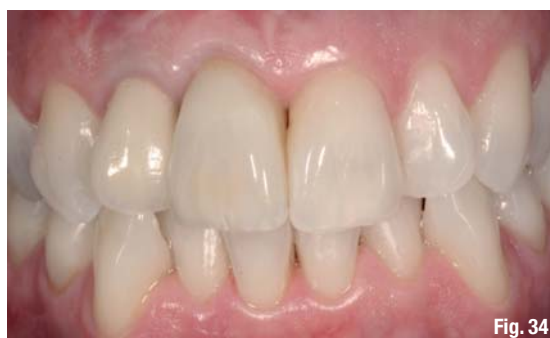

Fig. 34

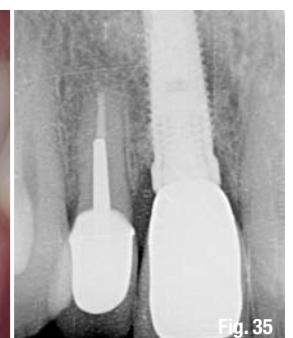

Fig. 35