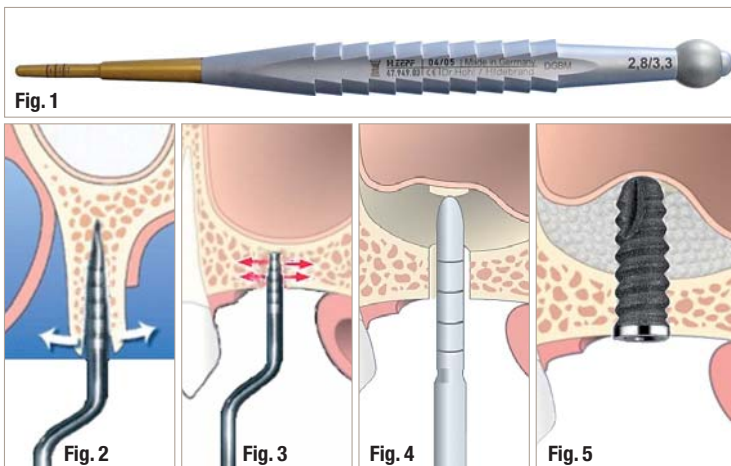


# Applications of hollow osteotomes in dental implantology

**Authors** Dr Rolf Vollmer, Dr Mazen Tamimi, Dr Rainer Valentin, Dr Suheil Boutros & Dr Martina Vollmer, Germany



**Fig. 1** Example of an osteotome.  
**Fig. 2** Bone expansion (splitting) by osteotome.  
**Fig. 3** Bone density via osteotome.  
**Fig. 4** Indirect sinus lift according to Summers' osteotome technique.  
**Fig. 5** Indirect sinus lift according to Summers' augmentation and implant insertion.

## Introduction

In the early days of implant dentistry, the main objective was to achieve a good stability for removable dentures. However, the range of indications has changed quickly. Today, patients are treated although they have thin crestal bone or a poor bone quality. Poor bone quality is found in the categories D3 and D4 (according to Carl E. Misch, Table 1). In contrast to the lower anterior region, which often corresponds to category D1, categories D3 and D4 are found mainly in the posterior maxilla, but also in the premaxilla (Table 1, green marks).

## Materials and methods

Bone of the qualities D3 or D4 can be improved and is thus made available for dental implantation. Osteotomes (Fig. 1) of different shapes were developed to help enhance bone density. They compress the cancellous bone and thus provide good primary

stability of an endosseous implant (Fig. 2). This way, the bone quality can be improved by one category.

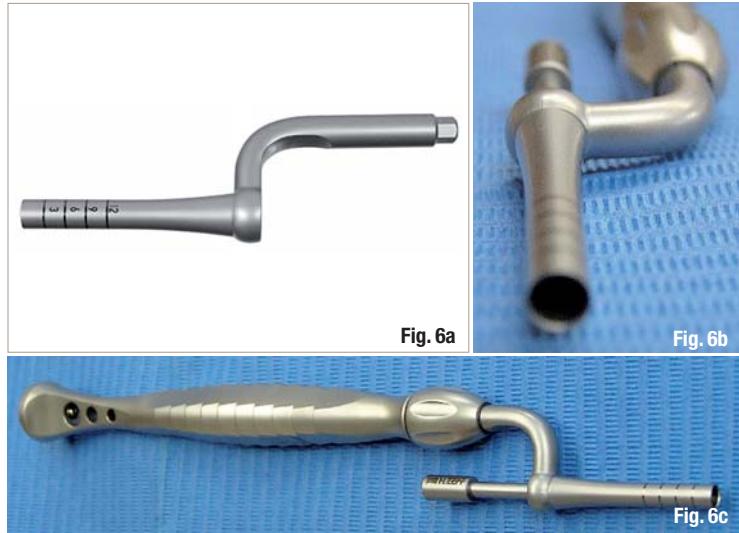
The primary stability is a "sine qua non" and necessary for a strong bone-implant bond (osseointegration). Further applications of specially modified osteotomes are splitting or bone spreading in cases of single-tooth implantation (Fig. 3). Additionally, osteotomes can be used in indirect sinus lift procedures (Figs. 4 and 5). Note that the implant screw shown in Figure 5 is a sample drawing (source: Impla, Schütz Dental GmbH).

All methods using osteotomes depend on the initial drilling of a pilot hole with a minimal diameter (2 mm). Drilling the pilot hole always goes along with a loss of bone mass, which only rarely is available in abundance. For this reason, hollow osteotomes have been developed, which combine the advantages of conventional osteotomes with the simultaneous removal of bone at the implant site. Additional bone can also be harvested easily via hollow osteotome (Figs. 6a-c) in other appropriate sections of the jaw.

The authors have already published this bone extraction technique with a bone trephine drill. In this way, a circular hole is drilled into the jaw bone. A bone cylinder is stuck inside the drill or remains in the jaw. As a result, a cylindrical piece of bone can be removed for later use, e.g. as autogenous augmentation material. The design of the trephine drill (Figs. 7a and b) requires a relatively solid wall thickness, so only a bone cylinder which is relatively small when compared to the outer diameter of the trephine drill can be applied. Furthermore, there are disadvantages and substantial difficulties in positioning that

arise when placing the saw tooth portion of the trephine drills head on an uneven surface. The drill can drift off when starting to move. Therefore, it is very difficult to create the implant site exactly in the desired location. Conditional remedies here are the use of drill sleeves, a switch of the engine to reverse turn and a higher speed. However, an excessive heat production and the associated potential damage of the bone is a disadvantage.

In the field of dental implantology, it is important that an accurate hole is placed exactly at the desired position in the jaw bone in order to insert an implant. The desired accuracy cannot be achieved with a trephine drill. Furthermore, significant inaccuracies can occur and injury to the soft and hard tissue can be caused when starting the drill as described previously.



**Fig. 6a-c** Hollow osteotome (Design H. Zepf).

Bone density	Hounsfield units	Upper front	Upper posterior	Lower front	Lower posterior
D1	>1,250	0	0	3	6
D2	850-1,250	25	10	66	50
D3	350-850	65	50	25	46
D4	150-350	10	40	3	1
D5	<150				

**Table 1** Bone densities in Hounsfield units. Occurrence and frequency of bone density (in %) in the jaw area, according to Carl E. Misch.

**Results**

The task ahead was to develop an instrument for the removal of bone without causing any injury. In particular, an implant osteotomy exactly at the desired position was to be achieved with the greatest possible accuracy and safety and without bone or mucosal damage. It should also be noted that this instrument must be applicable in navigated implantation procedures. The newly developed instrument, which was named hollow osteotome, is designed in the manner of a punch and has an operating element, which essentially is a hollow cylinder. At its distal end, the cylinder has a peripheral cutting edge. The cutting edge of a hollow os-

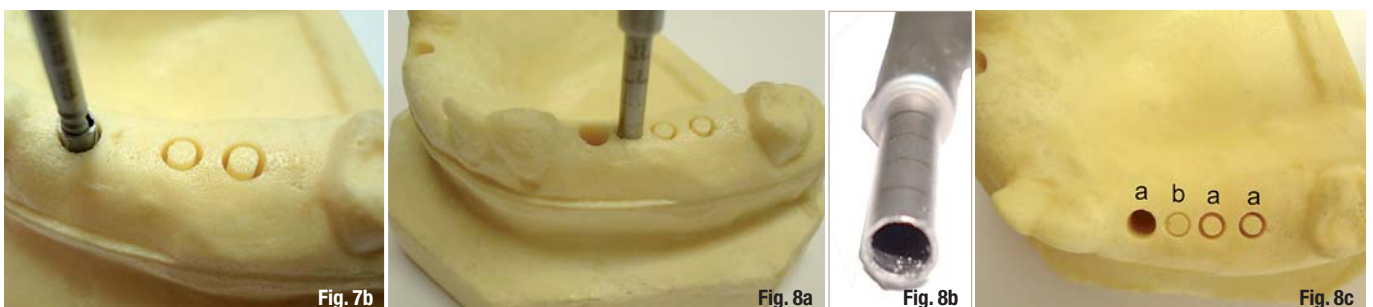
teotome like this can be seated precisely in the desired implant position (Figs. 8a-c). Note that the larger bone core is formed with an outer diameter of the instrument smaller than the trephine drill site. The hollow osteotome succeeds in creating a "standard-implant-cavity" with an outer diameter of 3 mm and the extraction of a bone cylinder with a diameter of 2.4 mm.

The hollow cylinder can be held exactly at the preferred position since it is not driven to rotate. Therefore, it can be placed exactly at the desired point for the respective cavity preparation and/or bone removal. Also, the implant axis can be specified exactly. The sharp edges of the hollow instrument can be pushed



**Fig. 7a**

**Figs. 7a and b** Trephine drill. **Fig. 8a-c** Implant cavity preparations (a) via trephine drill (b) and hollow osteotome (c).



**Fig. 9**\_Osteotome set (Design H. Zepf).

**Figs. 10a-c**\_Bone harvesting via hollow osteotome.

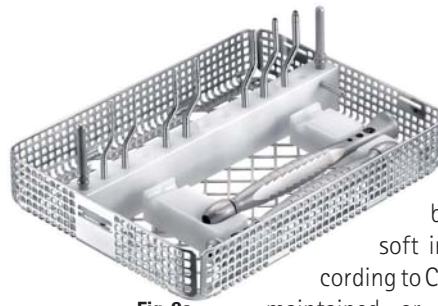
**Fig. 11**\_Transmucosal punching and simultaneous preparation of a bone cavity for dental implantation.

**Figs. 12**\_Application of hollow osteotomes in navigated implantology in order to avoid overheating by drilling with reduced irrigation.

**Figs. 13a-c**\_Preparation and transformation of an extraction site for the removal of autologous bone and simultaneous immediate implant placement.

**Fig. 14a-c**\_Application of the indirect sinus lift technique by hollow osteotome: a) extraction of the bone core; b) pushing in the cortical plate; c) augmentation and simultaneous implantation.

**Fig. 15**\_Final X-ray.



**Fig. 9a**

manually or inserted in the alveolar bone with the aid of gentle taps on the proximal end of the working element because the jaw bone is relatively soft in some areas (D3/D4 bone, according to C.E. Misch). The implant axis can be maintained or corrected. Larger hollow osteotomes are available for bigger implant diameters. Further additional compression of the surrounding bone can be done with a full thickness osteotome.

On the one hand, the cutting edge helps to keep and fix the osteotome in the desired position. On the other hand, it facilitates pushing or driving the osteotome into the jaw bone. When inserting the osteotome into the alveolar bone, the plates are displaced outwards.

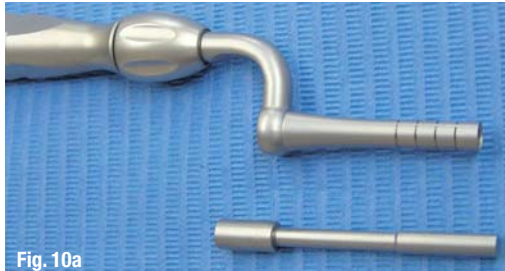As a result, the surrounding bone is condensed. A bone core penetrates into the lumen of the hollow cylinder. Upon removal, this bone cylinder inside the cutting element of the osteotome usually remains in the instrument and can then be used as an autologous bone graft. As there is no rotation of the hollow cylinder while seated and inserted into the jaw bone, no injury to the soft tissue or jaw bone can arise.

In addition, the cutting edge of the instrument is bevelled to the distal end of its outside wall. In this way, a three dimensional chisel or wedge-like circumferential distal working end results. This facilitates the introduction of the osteotome operating element into the jaw bone.

Markers (Fig. 6a) are arranged around the outside of the operating element, which show the distance to the distal end of the working element on a scale. Thus, the user is provided with information of how far the operating element of the hollow osteotome has already penetrated into the jaw bone.

The wall thickness is significantly lower than in the known trephine drills because of the non-rotating application. Reduced or no loss of bone material is achieved and a bone cylinder of a larger diameter can be removed by using the osteotome. The wall thickness of the hollow cylinder instrument is less than 0.3 mm (Fig. 6b).

This version of the osteotome is designed as a two-piece entity, so that the handle can also be used for other osteotomes. This means that the number of instruments (Fig. 9) can be kept relatively small since only the operating element has to be exchanged.

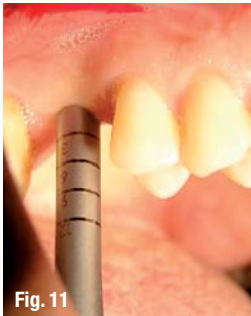

**Fig. 10a**

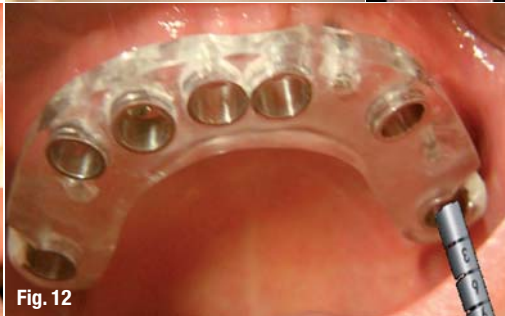

**Fig. 10b**

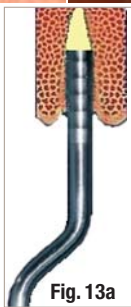**Fig. 10c**



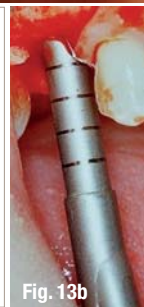**Fig. 11**



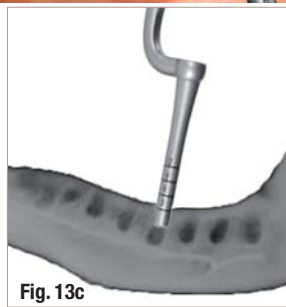**Fig. 12**



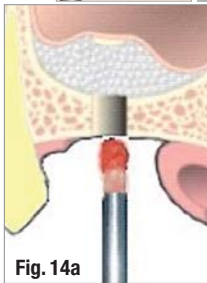
**Fig. 13a**



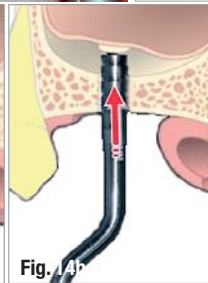
**Fig. 13b**



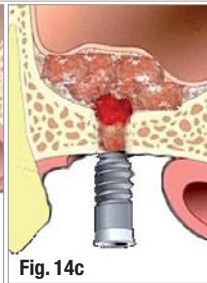
**Fig. 13c**



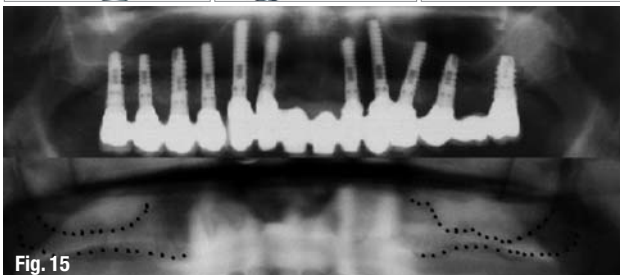
**Fig. 14a**



**Fig. 14b**



**Fig. 14c**



**Fig. 15**



## Collagens and suture materials for dental surgery

In order to push the bone material out of the operating element, a special ejector has been developed which can be inserted into the lumen of the working element. In this way, the bone material can be removed from the lumen of the hollow osteotomes easily and without damage. The bone material then is ready to be used for autogenous augmentation (Figs. 10a–c). Since there is a special indication for the application of osteotomes in the posterior jaw bone at a bone quality of D3 and D4, the operating element was formed with an angle, thus designed to be universally applicable both in the front and in the posterior jaw regions.

### Indications for use of the hollow osteotomes

1. Bone quality D3 or D4
2. Mucosal punch (Fig. 11)
3. Preparation of a bone cavity for a dental implant
4. Preparation of a bone cavity using a navigation template (Fig. 12)
5. Preparation and transformation of an extraction site for immediate implant placement (Fig. 13)
6. Preparation of a bone cavity and simultaneous removal of autologous bone material (Figs. 10a–c)
7. Preparation of a bone cavity with simultaneous compression (improvement of bone quality) of the surrounding bone and bone harvesting
8. Preparation and application during indirect sinus lift procedures (Figs. 13a–c and 14a–c)

### Discussion

Maximum autologous bone harvesting from the jaws, performed in a minimally invasive surgical procedure, is an advantage of the above-presented instrument. Another advantage is the low risk of overheating the bone compared to rotating instruments, particularly when using navigation templates due to non-existent irrigation.

### Risks and side effects

Vertigo may occur in the application of traumatising instruments in exceptional cases of a pre-damaged patient. The subsequent and relatively simple non-invasive treatment is performed by an ENT doctor. However, side effects can occur in all dental procedures, even in treatments with turbines, as well as in the leisure sector, for example with mountain bikers. Because these side effects occur only rarely, they are outweighed by the benefits of the method described above.

### Summary

Hollow osteotomes broaden the spectrum of autologous bone removal, especially from the jaw, while the bone structure is condensed simultaneously. They have proved effective in the minimally invasive removal of autologous bone at the same time as an exact preparation and quality improvement of the local bone of a density of D3 or D4 (Carl Misch).

### contact

### implants

**Dr. Rolf Vollmer**  
Nassauer Str. 1  
57537 Wissen, Germany

Tel.: +49 2742 968930  
Fax: +49 2742 2547  
info.vollmer@t-online.de



**PARASORB Sombrero®**  
Absorbable Membrane-Cone



**PARASORB RESODONT®**  
Absorbable collagen membrane



**PARASORB® Cone**  
**PARASORB® Cone Genta**  
Collagen-cone for the treatment of extraction sockets



**RESORBA® sutures**  
The optimal suture for each indication

2013-01 A0019

**RESORBA®**  
REPAIR AND REGENERATE

RESORBA Medical GmbH  
Am Flachmoor 16, 90475 Nürnberg, Germany

Tel. +49 9128 / 91 15 0  
Fax +49 9128 / 91 15 91  
www.resorba.com

SILVERSPONSOR  
OF THE **DGI**