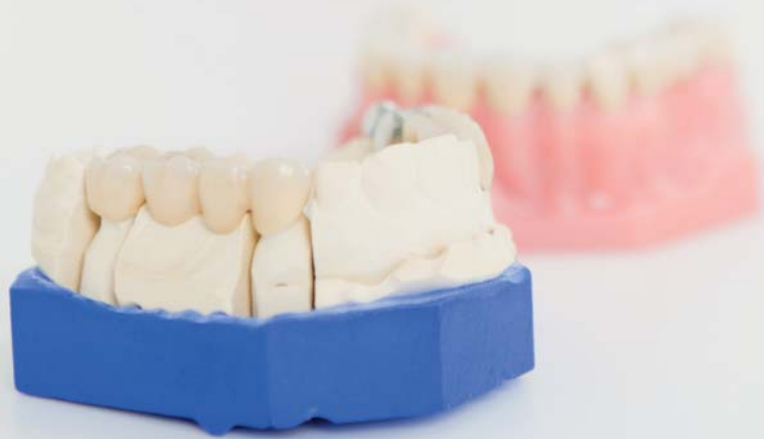

Comprehensive prosthetic restoration

Authors Michael Peetz & Dominik Büchi, Switzerland



[PICTURE: ©RACORN]

Introduction

In clinical practice, cases are often much more complex than described in textbooks and selection of the best treatment option is not always straightforward.

Dental Campus contains numerous clinical cases that are structured in a standardised format. You can follow every treatment phase, from the initial findings to the maintenance therapy, and you can discuss with colleagues from all over the world.

Fig. 1 Screenshot of the initial findings. The case presentation simulates the situation on the desk of the practitioner.

Would you like to expand your clinical knowledge, be able to discuss your cases and the various treatment solutions with your colleagues while collecting CME credits? These features are brought to you by the new e-learning platform Dental Campus.

Discover the second case of the Dental Campus series presented below in which other practitioners may have chosen different "optimal" therapies and create your own treatment plan online. The full case can be found at: www.dental-campus.com/cases/comprehensive-case-in-a-woman.

Fig. 2 Intraoral radiographs.

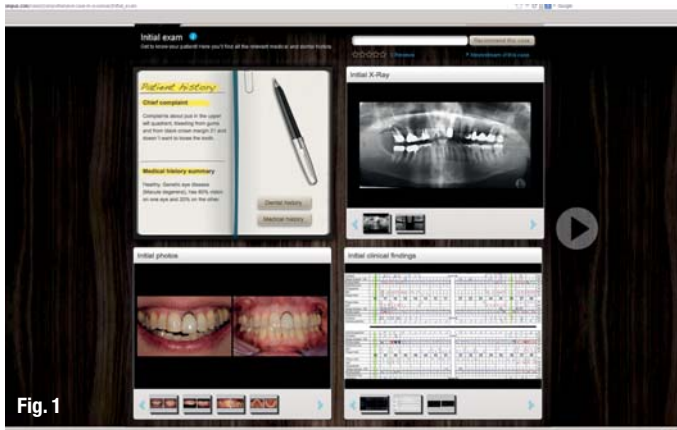


Fig. 1

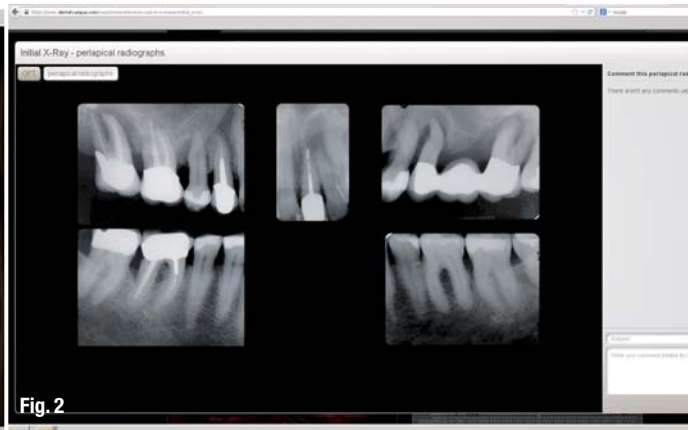
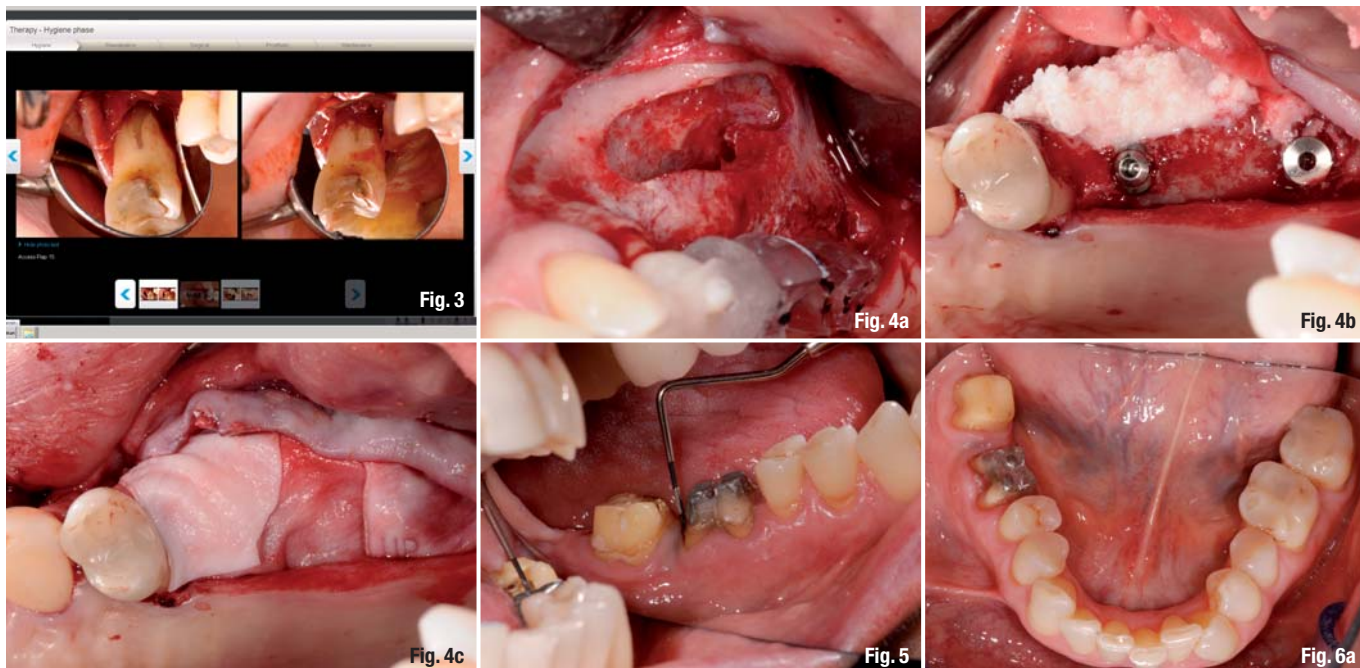


Fig. 2



Clinical findings

The patient complains about a purulent inflammation in the left upper quadrant and gingival bleeding (Fig. 1). Metal crown margins in the aesthetic zone on tooth 21 are visible and cause a significant dissatisfaction for the patient. The patient expresses a strong interest in keeping this tooth. Generally, she suffers from macular degeneration with vision loss of 20 and 80 per cent.

The periodontal examination shows increased probing depths of up to 12 mm in the mandible and up to 13 mm in the maxilla, with a BOP of 36 per cent. Vertical bone loss and apical radiolucency are evident from the OPTG and the intraoral dental X-ray images (Fig. 2).

The teeth 17, 25, 27 and 38 are not worth retaining and prognoses of the teeth 16, 15, 21, 24 and 46 are questionable.

How would you proceed?

A chronic aggressive periodontitis is diagnosed. The detailed diagnosis of the case can be found online at Dental Campus. At the e-learning platform, you can also create your own diagnosis for this patient with a few mouse clicks, define the prognosis for each tooth and plan the treatment using the digital dental chart. Then, you may compare your planning with the planning of other users and with the actual therapy option chosen by the treating practitioner. Optionally, you can discuss the treatment options in the forum.

Therapy

a) Periodontal pretreatment with tooth extraction

Which teeth should be extracted before the periodontal treatment? Teeth 17, 16, 25, 27 and 38 are to be extracted. During periodontal therapy, the patient is given a partial denture anchored on teeth 15 and 24.

For teeth 15 and 46, an open procedure is chosen. Here we observe that tooth 15 is also not worth preserving, although the tooth during the cold test responded as vital (Fig. 3). At tooth 46, the probing depth has decreased but still amounts to 6 mm distolingually and 7 mm distobuccally.

b) Surgical phase

After periodontal therapy, the sinus floor is bilaterally augmented (Fig. 4a). In order to improve the bone volume, a horizontal ridge augmentation in quadrant 2 is also performed (Figs. 4b-c). Implants are placed in regions 17, 16, 25 and 27.

c) Prosthetic restoration

Selected stages of the prosthetic restoration are shown in Figures 5–8. The entire detailed procedure is illustrated online with numerous images.

Tooth 21 is re-crowned on the original post and abutment. Teeth 46 and 47 each receive single crowns. Teeth 24, 36, 37 and 45 get new composite fillings.

Would you have chosen the same approach, or would you recommend a different therapy option for the patient? Instead of large-scale fillings on teeth 24,

Fig. 3 The open periodontal therapy shows that tooth 15 is not worth preserving. The tooth is extracted.

Figs. 4a–c Bilateral sinus floor elevation, implantation and horizontal ridge augmentation. Only Quadrant 2 is shown.

Fig. 5 Preparation of tooth 46 and 47.

Figs. 6a & b Clinical situation at impression-taking.

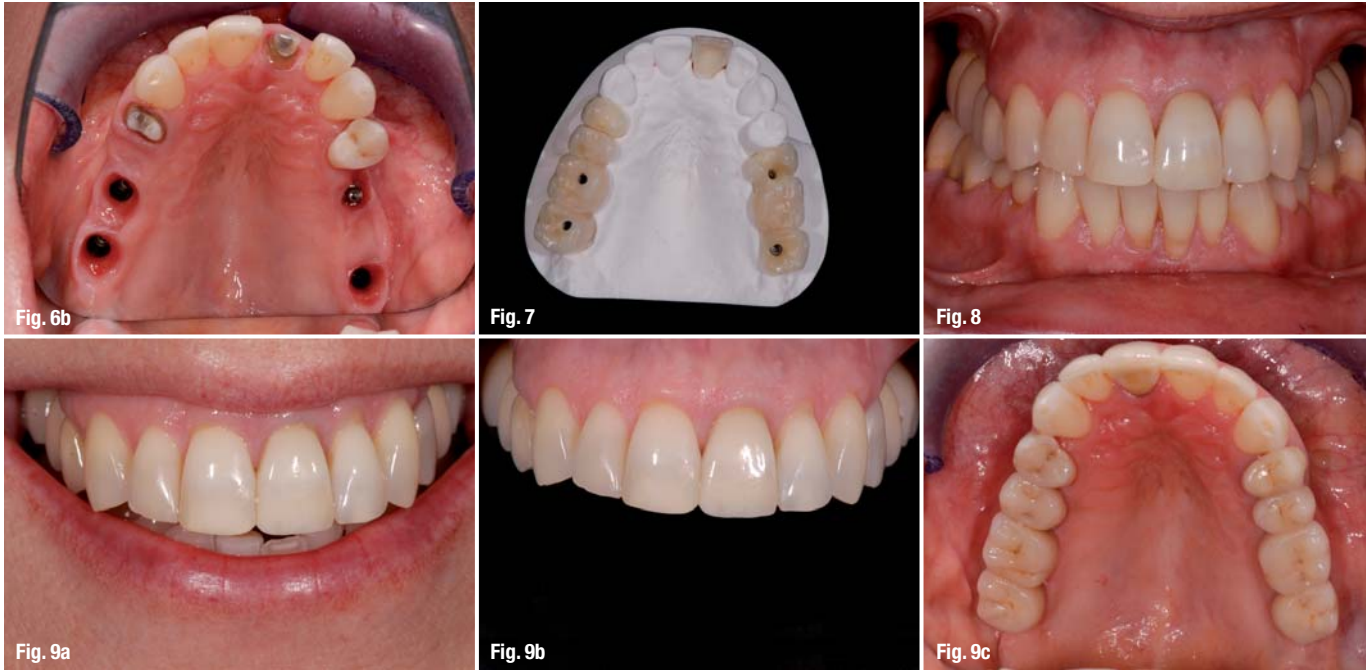


Fig. 7_Wax-up maxilla. 36, 37 and 45, partial crowns could have also been a solution.
Fig. 8_Try-in.
Figs. 9a–d_Final results.

How would you have treated tooth 46? This tooth has a questionable prognosis and additional costs are associated with the open periodontal therapy. Instead of the single crown, would you rather have chosen to extract the tooth and place a bridge over teeth 44, 45 and 47? Or would you have replaced tooth 46 with an implant? Log on to Dental Campus and discuss this case!

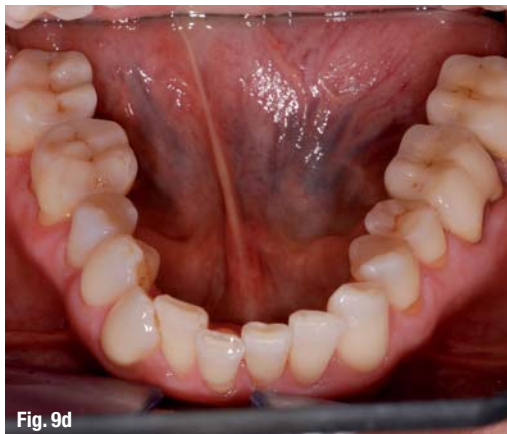**_Treatment outcome—
 What do you think?**

The patient has an appealing restoration with which she is satisfied (Fig. 9). Periodontal therapy enabled the probing depth at tooth 46 to be reduced to 4 mm distolingually and 3 mm at all other points measured.

The implant in region 25 has a mesiobuccal probing depth of 6 mm. The patient received detailed oral hygiene instructions and was integrated into a regular recall program.

The case described here is an example of a typical case and documentation found on Dental Campus. Extensive background information and a detailed presentation of each treatment step allow you to closely follow the treatment planning, understand its implementation, with high practical relevance for your daily practice.

How do you rate the choice of treatment and the outcome of this case? Would you have handled the case differently? Register as a Dental Campus user, discuss the treatment with your dental colleagues and receive 2 CME credits for your work on the case.



_contact	implants
<p>Dental Campus Englischviertelstr. 32 8032 Zurich, Switzerland</p> <p>Tel.: +41 44 5156010 Fax: +41 44 5156911</p> <p>info@dental-campus.com www.dental-campus.com</p>	



5TH INTERNATIONAL

CAMLOG CONGRESS

26TH – 28TH JUNE 2014

VALENCIA, SPAIN



CONGRESS OF THE YEAR

REGISTER
NOW

No claims without proof! And proof we have! Not only do the delegates give us enthusiastic feedback, they keep registering again and again. Not surprising, having attended once, you never want to miss another congress! Focused competence, practical benefits and the lively atmosphere at the congress speak for themselves. Register for the congress - we look forward to welcoming you!

THE EVER EVOLVING WORLD OF IMPLANT DENTISTRY

camlogfoundation

More information and registration:
www.camlogcongress.com

