

# Jawbone cavitation and its implication in implant dentistry

Author\_Prof. Dr Mauro Marincola, Italy

## Introduction

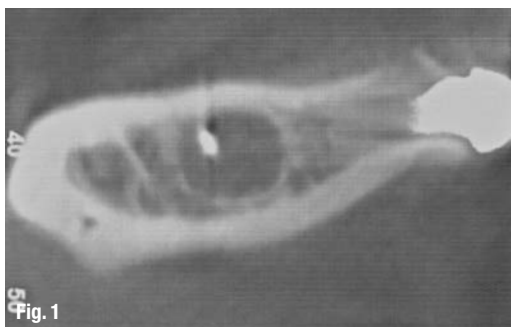
A cavity is a hole in a tooth, whereas a cavitation is a hole in bone. Unlike most tooth cavities, bone cavitations cannot be detected by simply looking at the bone, rather they must be determined radiographically and the interpretation thereof requires an expert eye, consequently many cavitations are missed.

In the last several years, the term "cavitation" has been used to describe various bone lesions that appear both as empty holes in the jawbones and holes filled with dead bone and fibrous marrow. The term "cavitation" was created in 1930 by an orthopaedic researcher who described a disease process in which a deficiency in blood flow into the area resulted in a hole in the jawbone

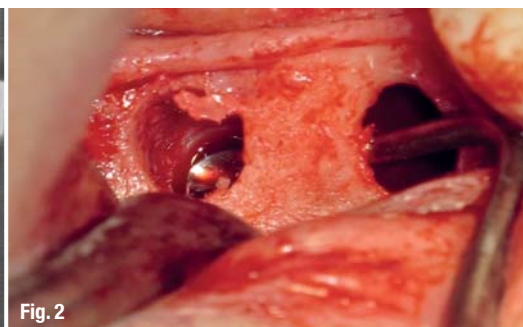
and other bones. Dr G.V. Black described this cavitation process in 1915 as a progressive process in the jawbone in which bone cells are destroyed, generating large cavitation areas within the jawbones.<sup>1</sup> Black found it striking that this disease produces vast jawbone damage without redness in the gingiva, pain, swelling of the jaw, or a rise in body temperature. In effect, this disease process produces small blockages or infarctions of the small blood vessels in the jawbones, leading to areas of dead bone or osteonecrosis. These dead areas are today called neuralgia-inducing cavitational osteonecrosis lesions.

The results of recent research by Dr Boyd Haley, former Chairman of the Department of Chemistry at the University of Kentucky, show that the cavitation tissue

**Fig. 1** Only a cavitation that has formed with additional calcification around a well-defined border will be visualized on X-ray. Observe the encapsulated extraneous body.



**Fig. 2** An explored channel might be counted as only one cavitation when it actually developed from more than one unhealed extraction site. Larger cavitations can extend below the mandibular nerve.



**Figs. 3a & b** 15 mm mesio-distal and 10 mm vertical bone cavitation filled with  $\beta$ -TCP graft. The distal hole was a third of dimension and a Short Implant (Bicon) could be placed immediately.

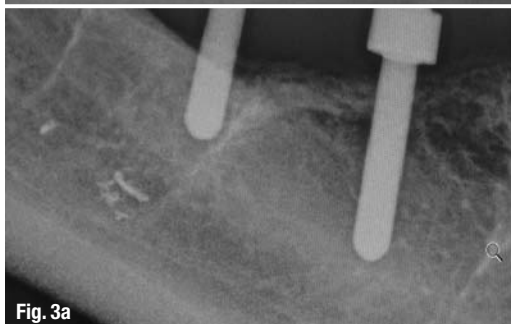

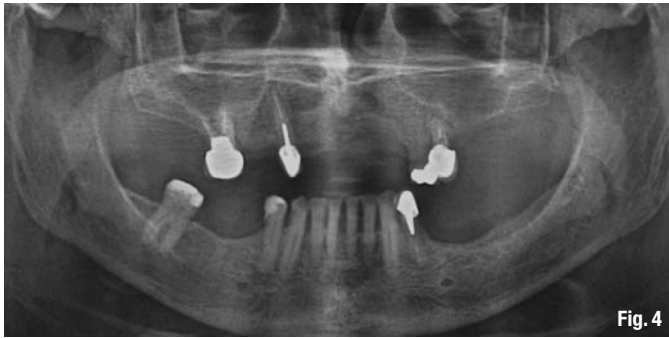


Fig. 4

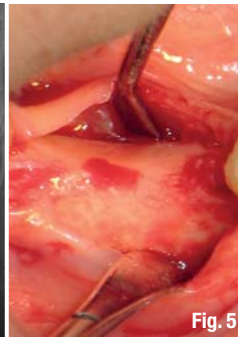


Fig. 5

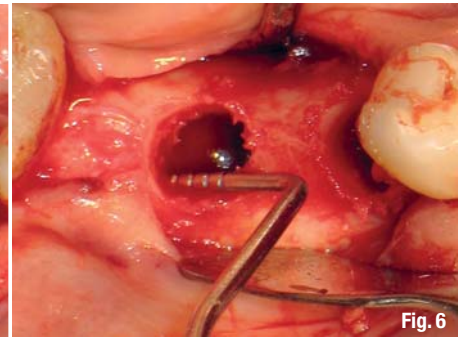


Fig. 6

samples he tested contained toxins that significantly inhibit one or more of the five basic body enzyme systems necessary for the production of energy.<sup>2</sup> These toxins, which are most likely metabolic waste products of anaerobic bacteria, may produce significant systemic effects, as well as play an important role in localised disease processes that negatively affect the blood supply in the jawbone. There are indications that when these toxins combine with certain chemicals or heavy metals (e.g. mercury), much more potent toxins may form.

### **Factors associated with cavitation bone lesion development**

Cavitation lesions can be caused by many factors, most likely a combination of these will characterise occurrence, type, size, progression and growth patterns.

#### **Initiating factors**

Probably the major initiating factors are of dental origin in terms of physical, bacterial and toxic traumas.

- Physical trauma: tooth extractions, dental injections, periodontal surgery, root canal procedures, grinding and clenching, electrical trauma from dissimilar metal restorations, incomplete removal of periodontal ligament after tooth extraction, overheat from high-speed drilling.
- Bacterial trauma: periodontal disease, cysts, abscesses, root canal bacteria from non-vital teeth, infected wisdom teeth.
- Toxic trauma: dental materials, root canal toxins, anaesthetics with vasoconstrictors, chemical toxins.

#### **Risk factors**

Predisposing factors encompass antiphospholipid antibody syndrome; blood clotting disorders (thrombophilia and hypofibrinolysis); age; changes in atmospheric pressure owing to occupation; Gaucher's disease; gout; haemodialysis; homocystinaemia; hyperlipidaemia; lymphoma or bone dysplasia; osteoporosis; physical inactivity; radiation or chemotherapy; rheumatoid arthritis; sickle-cell anaemia; systemic lupus erythematosus; and thyroid or growth hormone

deficiencies. Cavitation lesions are prompted by many factors. Many of them affect the occlusion or blockage of small blood vessels of the jawbone. In addition to minor risk factors, the most prominent are alcoholism, heavy smoking, long-term high-dose cortisone use, oestrogen use, pancreatitis or pregnancy.

Research shows that 45–94 per cent of all cavitation lesions are found at wisdom teeth extraction sites.<sup>3</sup> These areas contain many small blood vessels, making them an ideal developing site for bony lesions, as these vessels are easily affected by trauma in surgical procedures. As a result, osteonecrosis can develop. In addition, numerous local anaesthetic solutions contain vasoconstrictors (particularly epinephrine). Vasoconstrictors are applied in order to restrict or reduce the blood supply to bone, teeth or gingival tissue, thus prolonging the anaesthetic effect and minimizing bleeding. As many local anaesthetics are injected in the wisdom teeth area, their application increases the occurrence of cavitation lesions in this region.

Another frequent cause of ischemic osteonecrosis in the jawbone is improper endodontic treatment. Few endodontic treatments are performed by a specialised dentist and the result is that the root canals become loaded with anaerobic bacteria or chemically toxic material used for the canal filling. The pathogenetic substance reaches the bone, eventually causing loss of bone density and holes inside the cancellous bone (Fig. 1). Since there is no longer a sufficient blood supply, the body cannot fight the toxins and the bony structure degenerates into necrotic bone and fibrous marrow.

As a reminder, neuralgia-inducing cavitation osteonecrosis is not so much an infection in the bone as necrosis or gangrene (dead tissue) of the bone marrow as a result of impaired blood flow (ischemia). A cavitation often develops because of incomplete healing after routine extraction.

When the periodontal ligament is not entirely removed from the socket after extraction, the surrounding bone receives no notification that the tooth is gone. The continued presence of any portion of the ligament gives the biological message to the surrounding jaw-

**Fig. 4** A trained eye is needed to recognise the circular bone cavitation mesial to the lower right molar. Observe the capsulation, the thin crestal cortical and the lack of trabecular geometry.

**Fig. 5** Intra-oral view of the cavitation region. No defect can be observed clinically.

**Figs. 6 & 7** Depth gauge demonstrating the absence of trabecular bone. The distal extension of the hole is approx. 10 mm.

**Fig. 8**\_Solid, healthy bone must be reached to allow the normal regeneration of bone. When infection or necrosis remain throughout the socket and adjacent bone, with or without condensing osteitis, healing will rarely ever be completed.

**Figs. 9 & 10**\_The hole is filled with a synthetic graft material (Synthograft) after elimination of fibrous marrow and disinfection of the cavity.

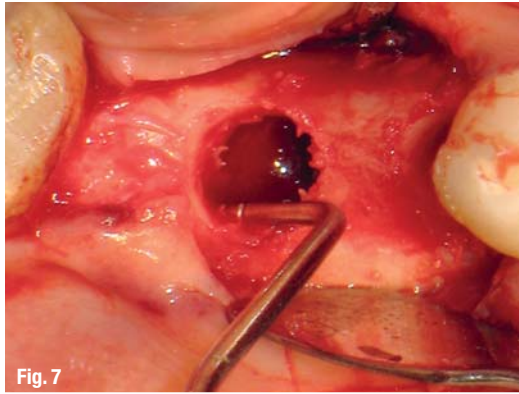


Fig. 7

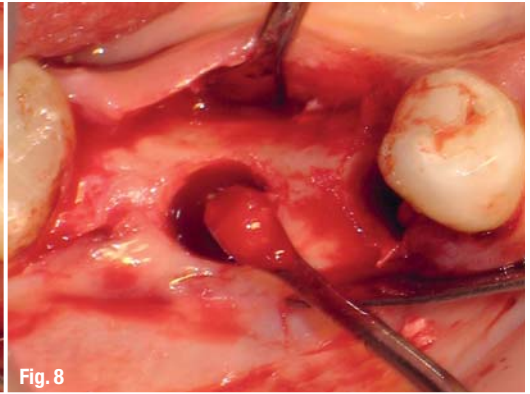


Fig. 8

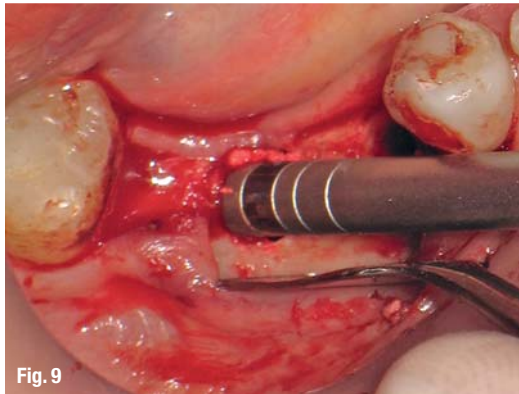


Fig. 9

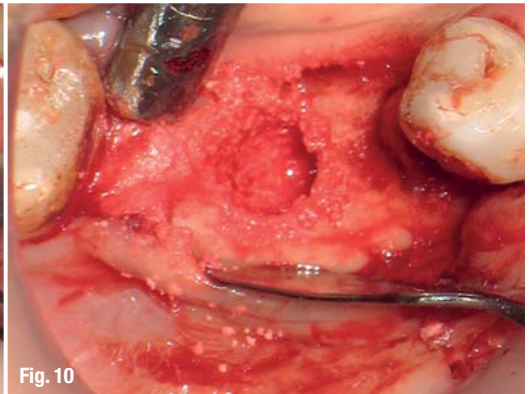


Fig. 10

bone that all is well, and no new bone growth is needed. Bone cells thus do not start new growth and then migrate through a barrier naturally designed to limit such growth. The jawbone determines that if the ligament is still there, the tooth must be there as well.

Since the periodontal ligament does not extend to the upper edge of the extraction site, new bone growth activity will not be inhibited at the top of the socket, and a characteristic thin cap of bone will eventually extend over the extraction hole. Larger cavitations often have only a cap of gingival tissue over them. Even the thin overlying cap of bone does not form in these cases. In routine dental extraction, portions of the periodontal ligament will sometimes be more strongly attached to the tooth than the bone and be removed along with the tooth. When partially removed in this fashion, the haphazard absence of the ligament will permit equally haphazard growth of bone, resulting in the wide variety of cavitation shapes and sizes (Fig. 2).

### Treatment

Surgery is often necessary to clean out a cavitation site properly and thoroughly, for there is no other way to remove dead bone. The key to bone healing and regeneration is the removal of the necrotic tissue. If the necrotic tissue is not thoroughly removed, the necrosis will spread and cause further destruction to the bone, nerves and blood vessels. This kills teeth in the process, for they are cut off from their blood supply. Once the necrotic tissue has been cleaned out, healing can then

take place and new bone cells will fill in the cavitations. Neither antibiotic injections into the bone nor laser treatments will stop the progressive necrosis if not all debris has been thoroughly curetted out of the cavitation.

The next treatment step is a bone grafting procedure to fill the cleaned and disinfected cavity. If the cavitation is limited to 5–6 mm in diameter, a plateau press fitted root form implant can be placed into the grafting material immediately. Otherwise, the implant will be placed in a larger grafted area after three months of healing (Figs. 3a & b).

### Clinical implications

The following case is representative of many other cases I have encountered during 25 years of clinical experience in numerous clinics in various countries. A 52-year-old female patient came to the practice with 19 missing teeth in both the maxillae and the mandible. The second premolars and first molars had been extracted between five and 12 years ago, after incorrect endodontic treatment. She noted that the molars had had abscesses and the premolars had fractured a few years after the poor endodontic treatment.

The treatment plan was to insert four short implants to replace the second premolars and first molars of the mandible. The dental panoramic tomogram showed a circular formation of 5–6 mm in diameter mesial to the second molar root on the right side of the mandible

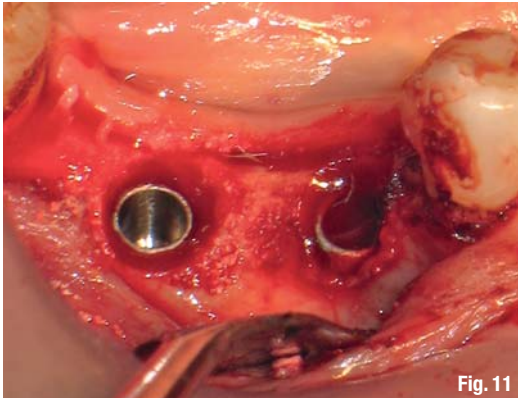


Fig. 11

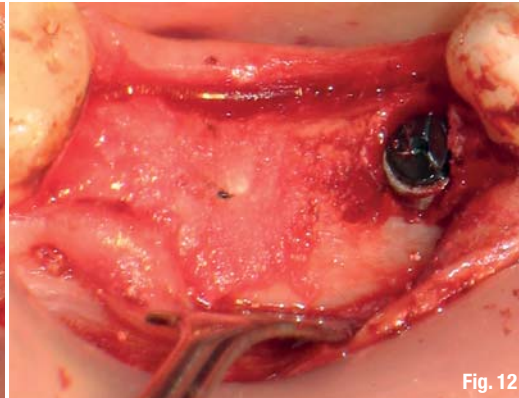


Fig. 12

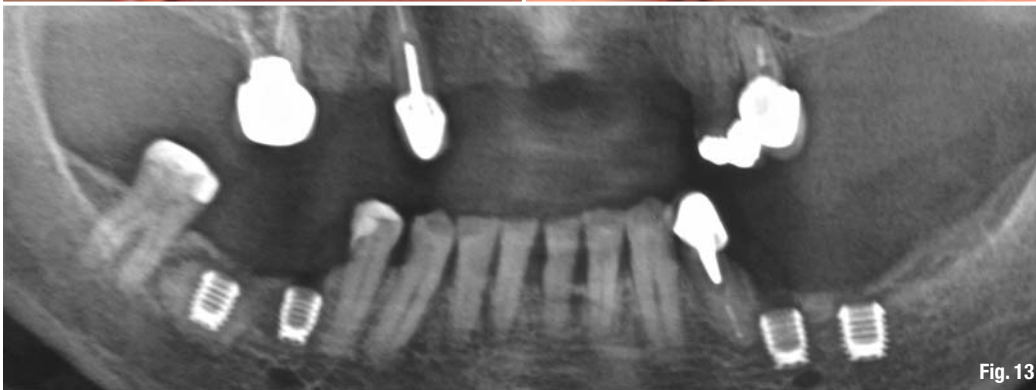


Fig. 13

**Figs. 11 & 12**\_Two 5 x 6 mm Short Implants (Bicon) are directly placed into the graft and buried under the crestal bone.

**Fig. 13**\_Evidence of the grafted bone cavitation and implant placement. Mandatory is the use of Short Implants in order to avoid proximity to the mental nerve and the alveolar nerve.

(Fig. 4). My experience with bone cavitations suggested a surgical approach that would entail performing an osteotomy and afterwards cleaning, disinfecting and filling the cavitation before placing the implant. Bone cavitations are not visible at crest level (Fig. 5) because the bony defect is located inside the bone marrow.

Once the diameter of the planned implant size (5 mm) had been achieved, the walls and floor of the osteotomy were controlled with a depth gauge. All walls except the lingual plate were missing and no floor limited the 8 mm length of the osteotomy. The depth gauge established a distal hole of 10 mm. The mesial and buccal defects extended for only a few millimetres (Figs. 6 & 7).

The fibrous tissue was removed from the cavity with a Lucas curette (Fig. 8). Multiple applications of a diode laser combined with local antibiotics were performed before proceeding to fill the cavity.

The graft material should be 100 per cent synthetic in order to avoid cross infection, as may be the case with xenografts. The beta-tricalcium phosphate ( $\beta$ -TCP; SynthoGraft, Bicon) was mixed with the patient's blood and injected into the cavity (Figs. 9 & 10). Once the cavity had almost been filled, two Short Implants ( $\varnothing$  5 mm, length 6 mm) were placed into the graft (Fig. 11). Finally, the implants were completely buried under the crestal bone (Fig. 12), in accordance with the characteristics of the implant design (plateau press fitted root form implant).

Short implants were necessary in this case because of the reduced vertical jaw dimension and the proximity to the mental nerve and the inferior alveolar nerve (Fig. 13).

### **\_Conclusion**

It is paramount for a good clinician to be able to recognise bone cavitation. Performing a correct osteotomy depends on the integrity of the four walls and the floor. If one or more of the structures mentioned are missing during inspection with the depth gauge, the quality and consistency of the bone marrow should be tested.

In some cases, a screw-retained implant may be retained in the crestal bone only while most of the implant body is unstable because of the presence of a hole. Owing to the multifactorial causes listed in this article, the cancellous bone in that specific area has become necrotic tissue, creating the cavitation.

*Editorial note: A list of references is available from the publisher.*

**\_contact**

**implants**

**Prof. Dr Mauro Marincola**

Via dei Gracchi 285  
00192 Rome, Italy