

# The Effect of Antimicrobial Photodynamic Therapy in the Treatment of Chronic Periodontitis: First Results of a Long-Term In Vivo Study

authors\_Tilman Eberhard, Jörg Neugebauer, Joachim Zöller, Freimut Vizethum, Germany

Periodontitis is characterised by the presence of inflammatory processes in the oral cavity, which can sometimes attack the whole periodontium. Inflammation itself of the periodontium manifest in increased probing depth or bleeding diathesis on light irritation of the gum. If left untreated, periodontitis can lead to bone resorption, which can be documented by X-ray, or even to the loss of the tooth. The primary cause of periodontitis is bacterial tooth deposits (microbial plaque).<sup>1,2</sup> Marker bacteria, eg, *Actinobacillus actinomycetemcomitans* (A.a.), *Porphyromonas gingivalis* (P.g.) and *Prevotella intermedia* (P.i.) are among the highly pathogenic bacterial spectrum of these deposits.

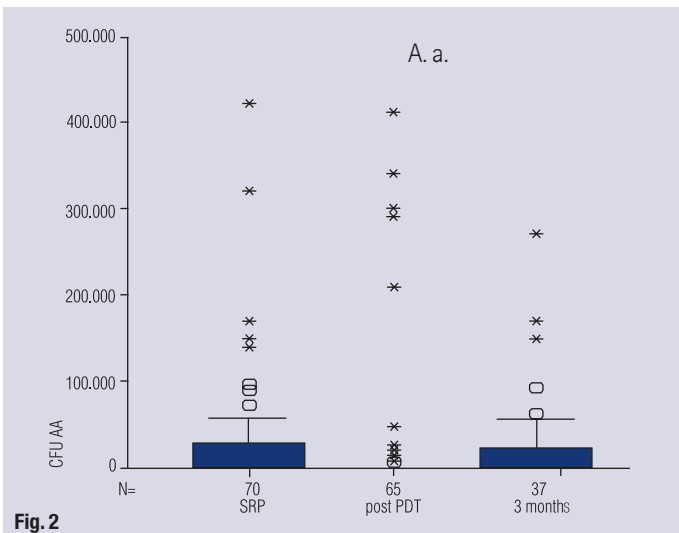
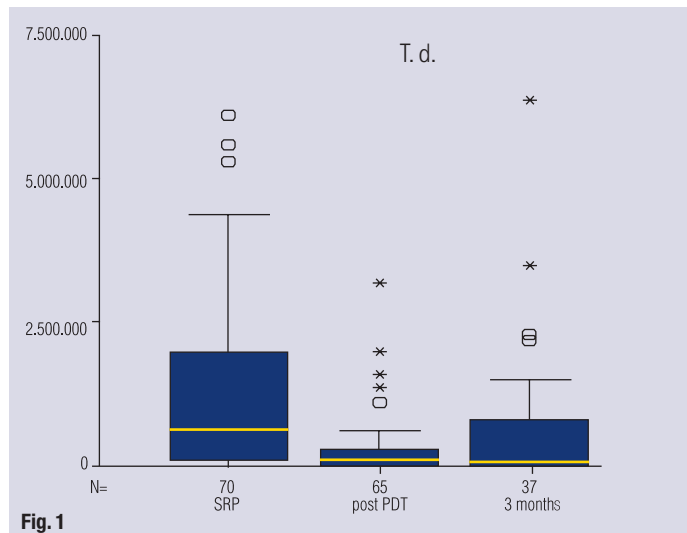
Chronic periodontitis is an infectious disease, which involves the inflammation of the periodontium and leads to progressive attachment and bone

loss. It is also characterised by the formation of periodontal pockets and/or gingival recessions, and is the most commonly occurring form of periodontitis.<sup>3</sup> Different methods of treating chronic periodontitis are used in practice and are being discussed in scientific publications. The aim of the particular method of treatment is to reduce bacteria and regenerate any lost periodontal tissue.

A conventional procedure is the mechanical removal of supra- and subgingival plaque using the corresponding hand instruments. In this procedure the plaque and concretum attached to the exposed tooth necks and root surfaces are first removed with a curette (scaling), and then the tooth surfaces are smoothed (root planing). Alternatively, the mechanical removal of plaque can also be carried out using ultrasound devices.

Fig. 1 CFU of *Treponema denticola* at different treatment times.

Fig. 2 ... of *Actinobacillus actinomycetemcomitans* ...



In the case of probing depths over 5 mm or bone pockets, and in the case of furcation involvement, tooth scaling and/or root planing using SRP is only possibly under certain circumstances due to the complicated anatomical situation.<sup>4-6</sup> The additional use of an antibiotic as part of mechanical therapy for chronic periodontitis should be questioned.

Indeed, several authors, eg, Slots<sup>8</sup>, currently doubt the rationale of using systemic antibiotic therapy. Ramberg et al.<sup>35</sup> also examine the long-term effect of systemic antibiotics after 3.5 years. No difference from the initial situation could be determined. Feres et al.<sup>37</sup> also reached this conclusion. Further disadvantages of antibiotic therapy include bacterial resistance and the occurrence of side effects after systemic use.<sup>8</sup>

A modern type of treatment for periodontitis is therapy using a high-energy laser device. This "hard laser" will use its thermal effect to reduce the periodontal pathogenic bacteria in the periodontal pockets, or even to eliminate them completely, to remove pocket epithelium and to support tissue regeneration. The use of lasers in periodontitis therapy has been researched in a number of clinical studies, using various study formats and different lasers.<sup>9-15</sup>

Different results were achieved from the studies in which a group of patients were treated solely with conventional methods and were compared with a group treated with a laser. Whilst some studies showed that conventional treatment achieved better<sup>9,10,16</sup> or equally good<sup>11</sup> results, Schwarz et al.<sup>12</sup> determined significantly better results in the clinical parameters when using a hard laser. Other studies show that evidence of a significant reduction in periodontal pathogenic bacteria can always be provided, irrespective of the wavelength of the laser.<sup>17,18</sup>

Clinical studies, which use a laser device in combination with a conventional procedure, show that

the additional use of the laser produces promising results in the treatment of periodontal diseases.<sup>17,19-23</sup>

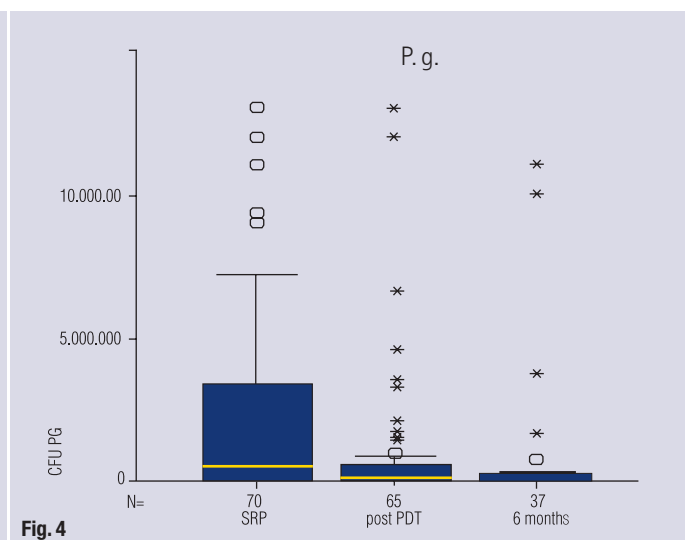
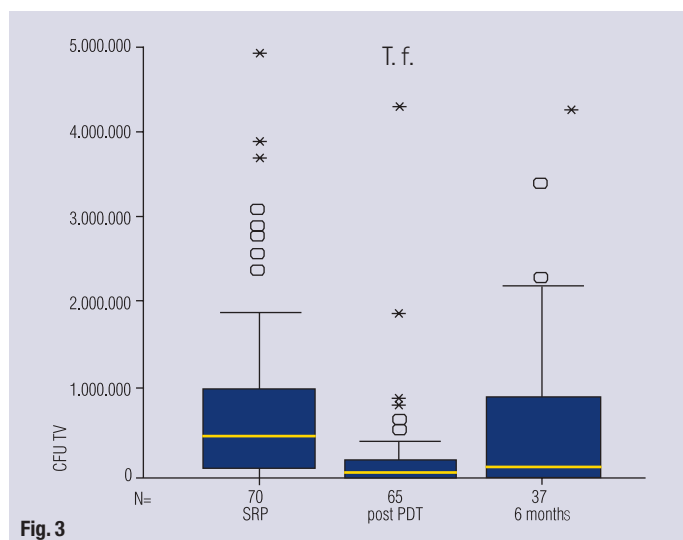
In their investigation, El Yazami et al.<sup>20</sup> reached the result of a significant improvement in all important clinical parameters, such as the plaque index, pocket depth and clinical attachment level, through the combined use of the SRP procedure and laser treatment in comparison to conventional treatment alone. In another in vivo study, evidence of a 25-30% bacteria reduction was produced with a Nd:YAG laser through the use of combined treatment with hand instruments and lasers.<sup>17</sup>

Some, eg, Liu<sup>9</sup>, saw problems in the fact that these results could not be systematically reproduced in practice. Antimicrobial photodynamic therapy (aPDT) is an innovative treatment concept in the area of periodontitis therapy, in which a low-energy laser is used in combination with a light-sensitive dye solution. Biofilm and bacteria are selectively dyed by the photosensitizer. When illuminated with light of a suitable wavelength, energy density and energy distribution, the stimulation of the photosensitizer in the triplet state will result in singlet oxygen formation on the bacteria membrane. The reaction of the high-energy oxygen molecule with the membrane lipid chain will lead to direct bacteria destruction. So far, various studies have confirmed the positive effect of aPDT on the successful treatment of periodontal and also peri-implant diseases.<sup>26-29</sup>

In a clinical study carried out by Dörtbudak-Kneissl et al.<sup>26</sup>, a significant reduction in the number of pathogenic bacteria such as *Actinobacillus actinomycetemcomitans*, *Porphyromonas gingivalis* and *Prevotella intermedia* could be determined in the treatment of periodontal inflammations with the aPDT procedure. The aim of the current prospective long-term study is to examine the effect of

Fig. 3 ... of *Tannerella forsythensis* ...

Fig. 4 ... of *Porphyromonas gingivalis* ...



antimicrobial photodynamic therapy (aPDT) in the area of conventional treatment of patients with chronic periodontitis.

**Material & methods**

Fifty-five patients who had been diagnosed with chronic periodontitis were included in the research group. The average age of the patients was 54. Thirty-nine of the patients were female, and 16 were male. In total, 1,320 units (teeth and implants) with periodontal infections were treated. Within the course of the initial treatment, the probing depth (PD) was measured and a modified sulcus bleeding index (SBI, scores 0–3) determined, both of which are reliable parameters for the diagnosis of chronic periodontitis, but are also suitable for assessing the progress of the disease regarding future attachment loss. In addition, a molecular biological procedure “real-time PCR” (PCR = polymerase chain reaction; Meridol® Perio Diagnostics, GABA International AG) was selected for the quantitative recording and evaluation of the microbiological load of the teeth.

Using this procedure it was possible to quantify the amounts of important periodontal pathogenic bacteria—such as *Actinobacillus actinomycetemcomitans* (A.a.), *Porphyromonas gingivalis* (P.g.), *Tannerella forsythensis* (T.f.), *Fusobacterium nucleatum* (F.n.), *Treponema denticola* (T.d.) and *Prevotella intermedia* (P.i.). In order to do this, subgingival plaque samples were taken from the infected teeth of each patient using paper points and then all samples were analysed together (pooling). The analysis took place in a fully automatic, validated process. The measuring unit for the quantitative recording and presentation of the bacterial load is the colony-forming unit (CFU).

The treatment of the patient population took place in two stages. In the first stage, each patient

received the conventional periodontitis therapy (SRP or professional scaling procedures) over the course of 2–20 years (average 14 years) in check-up appointments roughly every six months, ie, all hard and soft tooth deposits were removed using normal hand instruments. The tooth root was then smoothed to impede renewed plaque formation and support the apposition of the clinical attachments. In the case of SRP, since 1998 there has also been systematic use of Nd:YAG laser decontamination of the periodontal pockets, meaning that resective surgical intervention was reduced to a minimum. In isolated cases, the SRP was repeated or antibiotic treatment was carried out during the observation period.

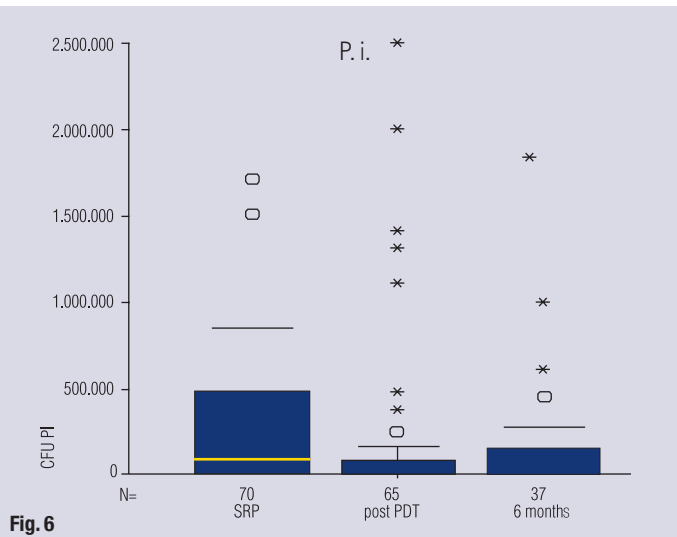
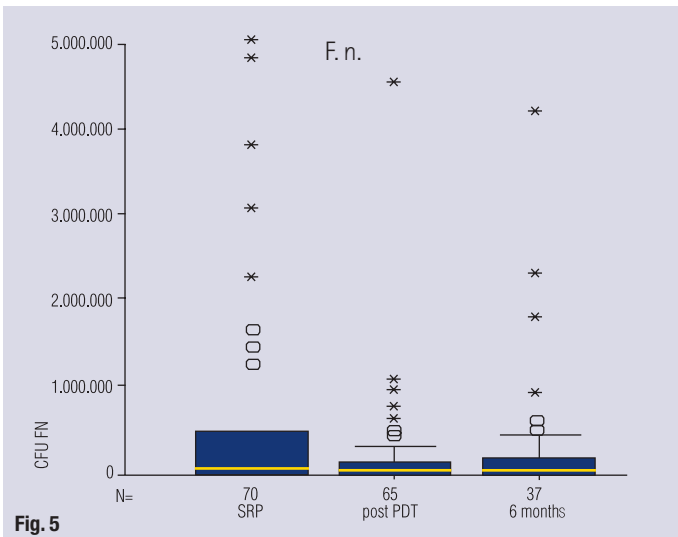
After the abovementioned treatment period, in which the patients generally all reached a stable condition, periodontitis therapy was extended, as follows, for the same patient population. First, the conventional therapy described above of professional scaling and smoothing of the tooth root was carried out again. After a period of 1–3 days—determined individually based on bleeding diathesis—all teeth were additionally treated using antimicrobial photodynamic therapy.

The first step of this process is applying a photosensitiser (HELBO® Blue Photosensitiser, HELBO Photodynamic Systems GmbH & Co KG, Grieskirchen, Austria) to the periodontal pockets. This is a bacteria-sensitive, light-active dye solution that dyes the microorganisms blue. After a photosensitiser reaction time of three minutes, the dyed area of the tooth is illuminated using a diode laser with a wavelength of 660 nm and a diode power of 100 mW (HELBO Thera Lite Laser) for a minute each.

One week after and 6-months after the antimicrobial photodynamic therapy, follow-up examinations were carried out on the patients. The parameters of probing depth and modified sulcus bleeding

Fig. 5... Fusobacterium nucleatum ...

Fig. 6... Prevotella intermedia ...



index were determined, and once again the most important periodontal pathogenic bacteria were quantified using the molecular biological procedure previously described. In the case of most of the patients, once the data had been collected in the 6-month check-up, another treatment was carried out that included treatment with a photosensitiser and the HELBO TheraLite Laser in addition to the obligatory professional scaling.

In order to facilitate a direct comparison of the distribution of the values of the different marker bacteria over time, the results of the microbiological examinations were displayed using a boxplot. The significance of the differences in the results of the clinical parameters during the different treatment stages was determined using the Tukey HSD post hoc test. Significant statistical differences were accepted with a confidence interval of 95%.

## Results

The results of the microbiological examinations are shown in Figures 1–6. The condition at the end of the first stage, which showed a typical individual steady condition in terms of periodontal health, was compared with further developments of the described parameter after the introduction of aPDT.

During a comparison of the results of aPDT with the condition at the end of phase I (conventional therapy alone), it could be seen that immediately after treatment with aPDT there was a significant reduction in all periodontal pathogenic bacteria. When the 6-months check-up was carried out in the second treatment stage, there was a tendency for the levels of the marker bacteria A.a., T.f. and T.d. to increase again, but in the majority of cases this was not to the same level as at the end of the first treatment stage after the use of conventional therapy alone.

The results for the marker bacterium A.a. must be interpreted cautiously as it is also possible to achieve false negative results. To ensure samples were reliable they had to be taken from approximately 25 teeth, which is often too laborious in daily clinical practice.<sup>36</sup> The median of the bacterial contamination reduced systematically over the course of treatment in stage two.

The results of the clinical parameters (see Figs. 7–11 & Table 1) support the tendency of positive results for the microbiological analyses. In comparison to conventional treatment of chronic periodontitis alone, the average probing depth could be significantly reduced at the end of the observation period (6-months check-up) of the second treatment stage using conventional therapy and aPDT (Fig. 9). The modified sulcus bleeding index had also significantly improved by the 6-months check-up of the second treatment stage (Fig. 10).

The occurrence of periodontal pockets with a probing depth of 4–6 mm had significantly reduced by the end of the observation period of the second treatment stage (Fig. 7). Periodontal pockets with a depth over 6 mm could also be significantly reduced after the 6-months check-up using the combined

	Tukey HSD			
	SRP	post SRP / PDT	6-months recall	
Pocket 4–6 mm	<b>0,000</b>	<b>0,000</b>	<b>0,000</b>	SRP
<b>Significance</b>	<b>0,000</b>	0,250	0,250	post SRP / PDT
Pocket > 6 mm	<b>0,000</b>	<b>0,001</b>	<b>0,001</b>	SRP
<b>Significance</b>	<b>0,000</b>	0,951	0,951	post SRP / PDT
Probing depth	<b>0,000</b>	<b>0,000</b>	<b>0,000</b>	SRP
<b>Significance</b>	<b>0,000</b>	0,046	0,046	post SRP / PDT
Sulcus blood index	<b>0,000</b>	<b>0,000</b>	<b>0,000</b>	SRP
<b>Significance</b>	<b>0,000</b>	0,971	0,971	post SRP / PDT
				6-months recall

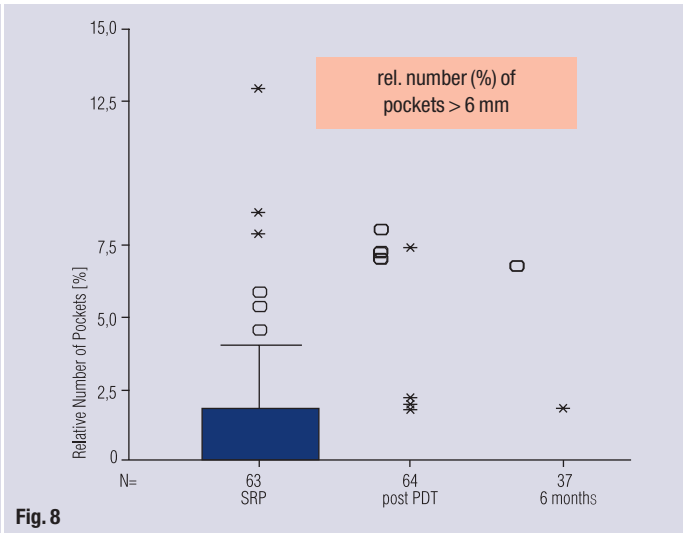
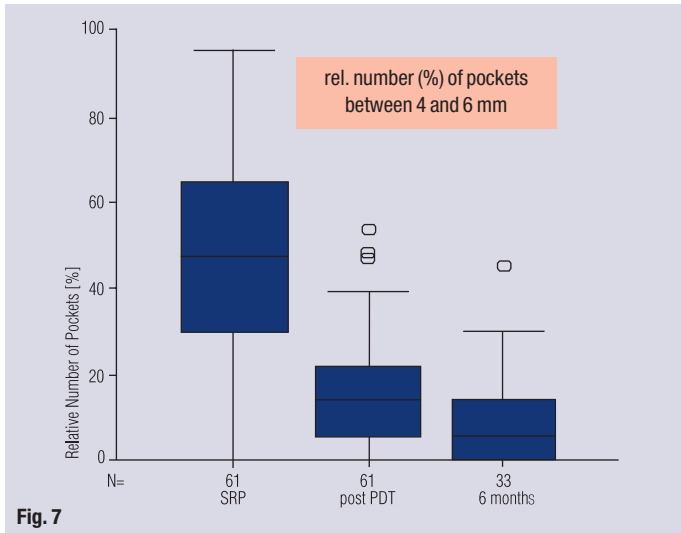
Table 1

procedure of SRP and aPDT (Fig. 8). The significance is shown in Table 1. Both the SBI and the occurrence of probing depths 4–6 mm and > 6 mm were statistically significant in the considered periods after SRP/aPDT, and after 6 months (fields highlighted in grey).

## Discussion

This clinical study examines the effect that the adjunctive use of photodynamic therapy can be expected to achieve as part of conventional treatment of patients with chronic periodontitis. The results of the current investigation show that the treatment of teeth with periodontal infections with a photosensitiser and subsequent illumination with a suitable laser led to a significant improvement in the clinical parameters of the occurrence of probing depths of 4–6 mm and > 6 mm, and the SBI. Microbiological examinations have also shown a reduction in the bacterial load. Median values sank systematically.

The available results confirm the results of other studies, whereupon a significant reduction in periodontal pathogenic microorganisms could be achieved through the combined use of a photosensitiser and a laser.<sup>28, 29</sup> A clinical study carried out by



Dörtbudak-Kneissl et al.<sup>26</sup> proved that there was a significant reduction in the marker bacteria A.a., P.i. and P.g. when a photosensitiser was used with a soft laser. According to Dörtbudak-Kneissl et al.<sup>26</sup>, total sterility is not an absolute prerequisite for the cure of an inflammation.

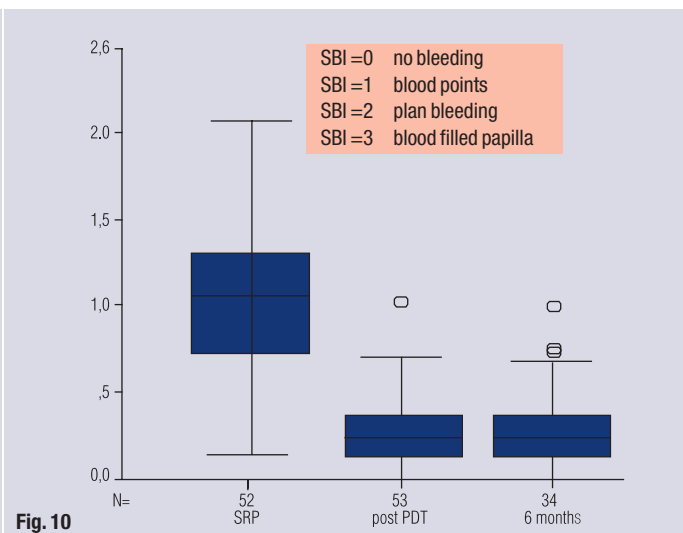
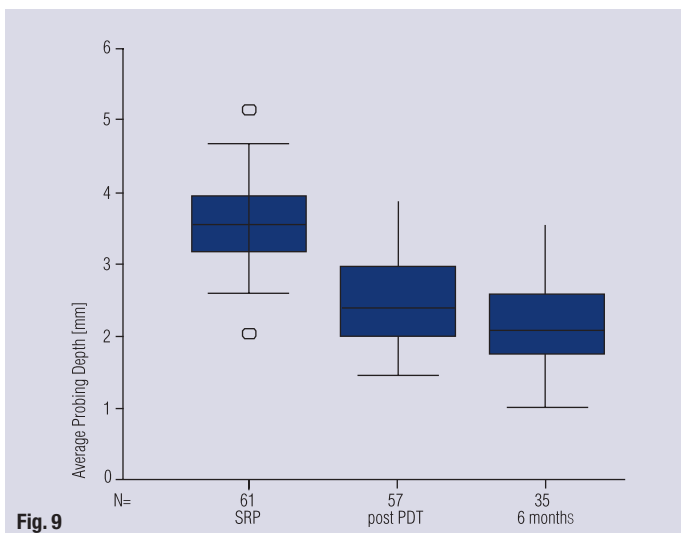
The clinical parameters used to assess the actual periodontal condition are the pocket depth measurement, bleeding on probing, the degree of loosening, and pus discharge from the pocket. When there are probing depths of more than 5 mm, there is a clear correlation to the amount of periodontal pathogenic bacteria.<sup>30</sup> After scaling and root smoothing, there is more frequent re-infection of deep pockets.<sup>31</sup> However, what is ultimately decisive for the progress of the course of an illness is bleeding on probing. This parameter is the decisive sign for the reaction of the tissue to the integrative stimulus effects (pocket depth, bacteria composition, number of bacteria).

Therefore, bleeding on probing is the most important parameter for a risk prognosis regarding fu-

ture attachment loss.<sup>32-34</sup> As a result, during this study both the frequency distribution of the probing depths (risk of re-infection) and a modified bleeding index were taken as the decisive criteria for coming to a definite conclusion on the further progress of the loss of periodontal supporting connective tissue. During the observation period a statistically significant reduction of individual risk could be achieved and proved for these decisive parameters when using aPDT.

### Conclusion

As part of the current, prospective long-term study on patients it could be shown that in comparison to first using conventional treatments of chronic periodontitis alone—with mechanical removal of supra- and subgingival plaque and then smoothing the tooth roots—a subsequent combination of conventional professional scaling or SRP treatment and antimicrobial photodynamic therapy resulted in significant, sustained improvement



of the levels of important clinical success parameters for the treatment of periodontitis. The microbiological examination also showed an immediate reduction in the number of important periodontal pathogenic bacteria when a combination of conventional therapy and aPDT was used.

The use of the antimicrobial photodynamic procedure could be integrated into the treatment process very simply and without any complications. It did not result in any side effects in the patients tested apart from a short-term discolouration of the gum lasting a few hours due to dyeing the plaque with the photosensitiser. Further clinical long-term studies are needed to be able to provide reliable, verified proof of a differentiated conclusion on the frequency of use of aPDT for patients with a high periodontal pathogenic bacterial load, combined with a marked defence weakness.

This research is a precursor, with temporal and contextual parts, of a major comprehensive study. The publication presents the data held by the author in spring 2006. As a result of the keen interest among colleagues, these first results are hereby published in advance. The extended version, containing the complete first annual results and treatment of aggressive periodontitis and peri-implantitis with a tested treatment plan will be published soon. The duration of the entire study is therefore intended to be 5 years.

### Summary

The aim of the study was to find out how antimicrobial photodynamic therapy (aPDT) would affect microbiology, pocket depth and the bleeding index when used as an addition to conventional therapy for chronic periodontitis. Fifty-five patients who had been suffering from periodontitis for an average of 14 years (2–19 years) were given a full examination as part of a regular check-up (microbiology, pocket depth, modified SBI). Then, most continued to be treated with professional scaling, and a few with SRP (scaling and root planing), but now in combination with aPDT. The results 1-week and 6-months after the combined therapy showed a considerable remission of the pathogenic marker bacteria, and a lasting, substantial decrease in pocket depth and bleeding index among patients previously treated with conventional therapies. This therefore proved the very positive therapeutic effect of HELBO Photodynamics.

*The literature list can be requested from the editorial office.*

### contact

laser

#### **Dr Tilman Eberhard, MSc**

Untere Zeiselbergstraße 18  
73525 Schwäbisch Gmünd, Germany  
Phone: +49-71 71/24 35  
Fax: +49-71 71/49 54 83  
E-mail: dr.tilmaneberhard@web.de



**cosmetic**  
**dentistry** \_ beauty & science

**\_ your 'hands-on' guide  
to international cosmetic dentistry**

**dti** dental  
tilman  
eberhard

Dental Tilman Eberhard GmbH  
Hohelstraße 20 | 04229 Leipzig | Germany  
Phone: +49. 891. 484 74-802 | Fax: +49. 891. 484 74-178  
Info: info@dti-online.com | www.dti-online.com