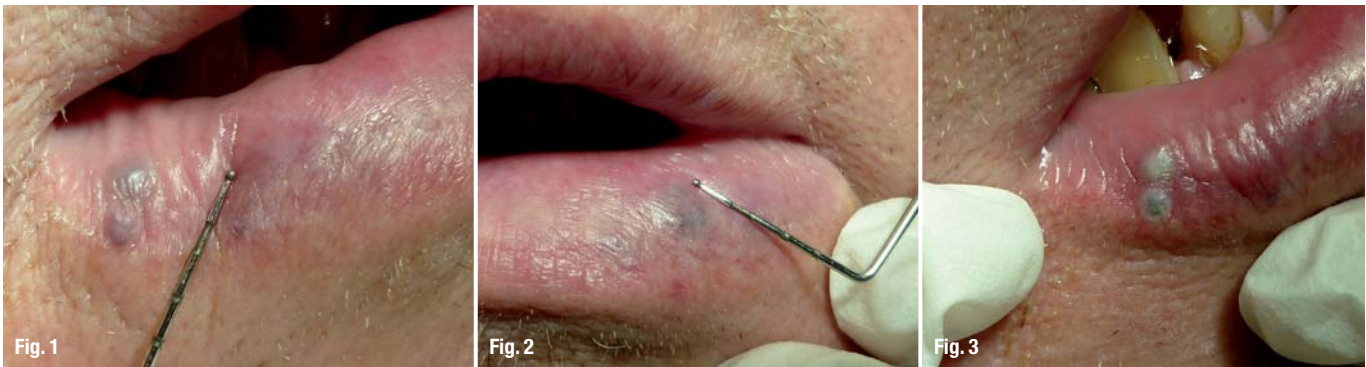


# Laser therapy of oral haemangiomas

## A case report

Author\_Friedrich Müller & Dr Maximilian Schmidt-Breitung, Germany



**Figs. 1 & 2**\_Haemangiomas prior to treatment.

**Figs. 3 & 4**\_Immediately after treatment.

### \_Introduction

Owing to demographic changes, eruptive or so-called senile haemangiomas have become more frequent among our patients. Haemangiomas are benign endothelial tumours found more often in women than men. Congenital capillary or cavernous haemangiomas are characterised by remission in more than 50%. Eruptive haemangiomas occur spontaneously in patients of 60 or older, especially on the lips, but they can also be found elsewhere. Remission of eruptive haemangiomas is observed more seldom than in capillary or cavernous haemangiomas. Owing to their localisation and the fact that older patients have more serious general health problems, non-surgical and non-invasive modalities for haemangioma treatments are favoured in order to minimise the risk of prolonged bleeding and scarring. Therefore, the use of lasers is nowadays the best option for removing haemangiomas easily. This article demonstrates the removal of three oral eruptive haemangiomas using an Nd:YAG laser with a wavelength of 1,064 nm.

### \_Case presentation

Prior to treatment, differential diagnostic aspects must be investigated. Lymphangiomas, retentions,

cysts and tumours of the salivary glands sometimes have a similar appearance to haemangiomas. Even haematomas can be mistaken for haemangiomas. The diagnosis is based on clinical parameters and can be confirmed by the use of a small glass plate that renders the haemangioma anaemic. Aspiration can also be helpful. Angiographic investigations have no clinical relevance in dentistry because of their poor benefit–cost ratio.

A 67-year-old male patient presented with three eruptive haemangiomas. He was treated with an Nd:YAG laser with a wavelength of 1,064 nm. The irradiation time applied was two minutes and the power output was 1.75 W and 15 Hz in non-contact mode. Three eruptive haemangiomas in the lower lip regions 34 and 45 with a diameter of 3 mm were treated in one appointment. The treatment was stopped when the surface of the haemangiomas turned whitish.

Figures 1 & 2 show the haemangiomas in regions 34 and 45 before the treatment. In order to enhance patient comfort, a local anaesthetic was administered. Figures 3 & 4 give an impression of the three haemangiomas immediately after laser treatment. One week after laser irradiation, a central induration with a marginal bulge was observed. This can be seen

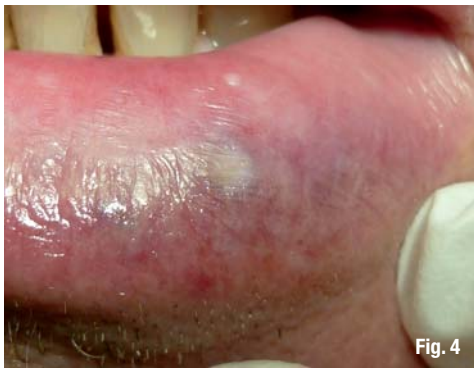

Fig. 4

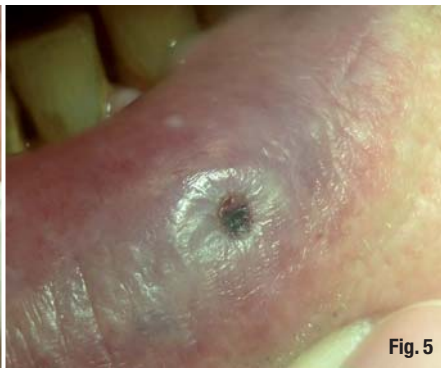


Fig. 5

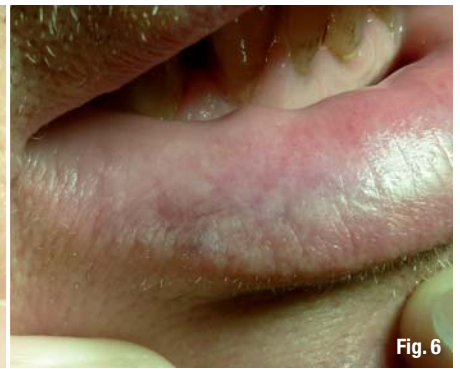

Fig. 6

from figure 5. The complete removal of the haemangiomas was followed up 11 weeks after treatment. As can be seen from figure 6, neither differences in the colour of the lip mucosa occurred, nor in its texture. Although our patient reported stinging pain during laser irradiation, no complications or pain arose during the healing process.

### Conclusion

This case report demonstrates that the removal of haemangiomas can be done with very little effort even in the dental practice. We suggest that this procedure can also be used for coagulation of intra-oral lesions of hereditary telangiectasis like morbus Osler-

Rendu-Weber to reduce the risk of spontaneous bleeding.

*The authors declare no conflict of interest.*

**Fig. 5** One week after laser irradiation.

**Fig. 6** 11 weeks after laser irradiation.

<b>_contact</b>	<b>laser</b>
<p><b>Friedrich Müller</b>                  Tannenring 76                  65207 Wiesbaden (Auringen)                  Germany</p> <p>praxis@muellerzahnarzte.de                  www.muellerzahnarzte.de</p>	

AD

*become an author  
for "laser"*

Please contact Claudia Jahn  
 ✉ c.jahn@oemus-media.de