

A combined device for optimal soft tissue applications in laser dentistry

Authors Hans J. Koort, Dr Michael Hopp, Germany & Prof. Dr D. Gabrić Panduric, Croatia

_Introduction

The use of alternating electric current for bloodless interventions in the oral soft tissues has been established for nearly a century, first in the form of the electric knife (cauter), then later as radiofrequency devices. Laser devices were introduced in the 1980s as new, additional tools and they have strongly gained in importance today. One particular question often emerges: What are the similarities between diode lasers and radiofrequency generators and what makes them different? What is their value for dental applications?

_Similarities

The laser light as well as the electric current of the radiofrequency device make use of the spatially concentrated and very fast heating of cells in the tissue. Thus they both are able to cut and coagulate in a precise way. Bleeding is stopped with high efficacy, allowing the surgeon a clear view of the surgical field.

_Differences

While the laser radiation is passed through an optical fiber and emits from the fiber tip to the tissue surface, the radiofrequency current is directed

through a metal electrode into the tissue. The main difference: A priori, the laser fiber can not be inserted deeply into the tissue to produce a cut. The laser radiation emits from the front end of a fiber and thus heats only the uppermost layer of the tissue and ablates it. Therefore, the tissue must be removed in a layer-by-layer procedure to get into the depth.

In contrast, the metal electrode of a radiofrequency device can be inserted into the tissue in one step in an intended depth. The radiofrequency current heats the targeted area simultaneously and uniformly to the entire physical length of the electrode. It allows a one-step precise, stressless and almost athermic procedure with an excellent tactile feel. The cutting speed especially in larger and deeper areas is much faster than with a laser.

In intraoral use, the radiofrequency technology is positively received because the local increase in temperature is less than 60 to 80 °C. Using a laser or an electric knife, respectively, a temperature increase of more than 400 °C must be considered.

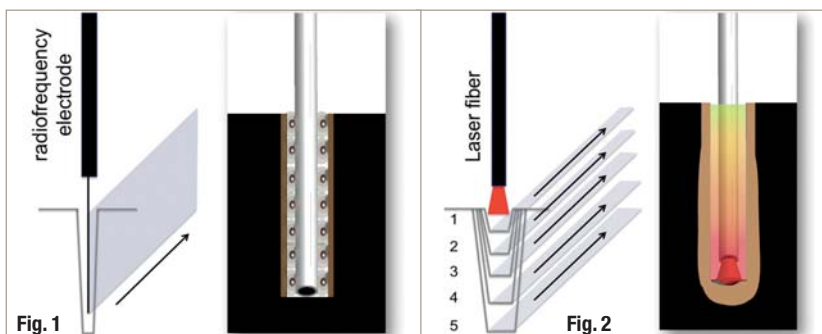
_Useful applications

The strength of a laser lies in the treatment of superficial soft tissues, such as the removal or reshaping of thin skin layers: i.e. exposure of overgrown implants, gingiva streamlining, in periodontic treatments, in endodontics as well as in special applications like bleaching, photodynamic therapy (PDT) and low level laser therapy (LLLT).

A significant disadvantage, however, can be seen in deeper surgical applications. The oral tissue is very thin, it is delicate and has complicated structures and in addition it usually is in close proximity to jaw bones and tooth structures. Laser radiation

Fig 1 Cutting of tissue with radiofrequency: The tissue is removed with only one precise, uniform cut in the entire length of the inserted electrode. The metal electrode remains cold at its frequency of 2.2 MHz.

Fig. 2 The cutting process with a laser is a layer-by-layer removal of superficial tissue.



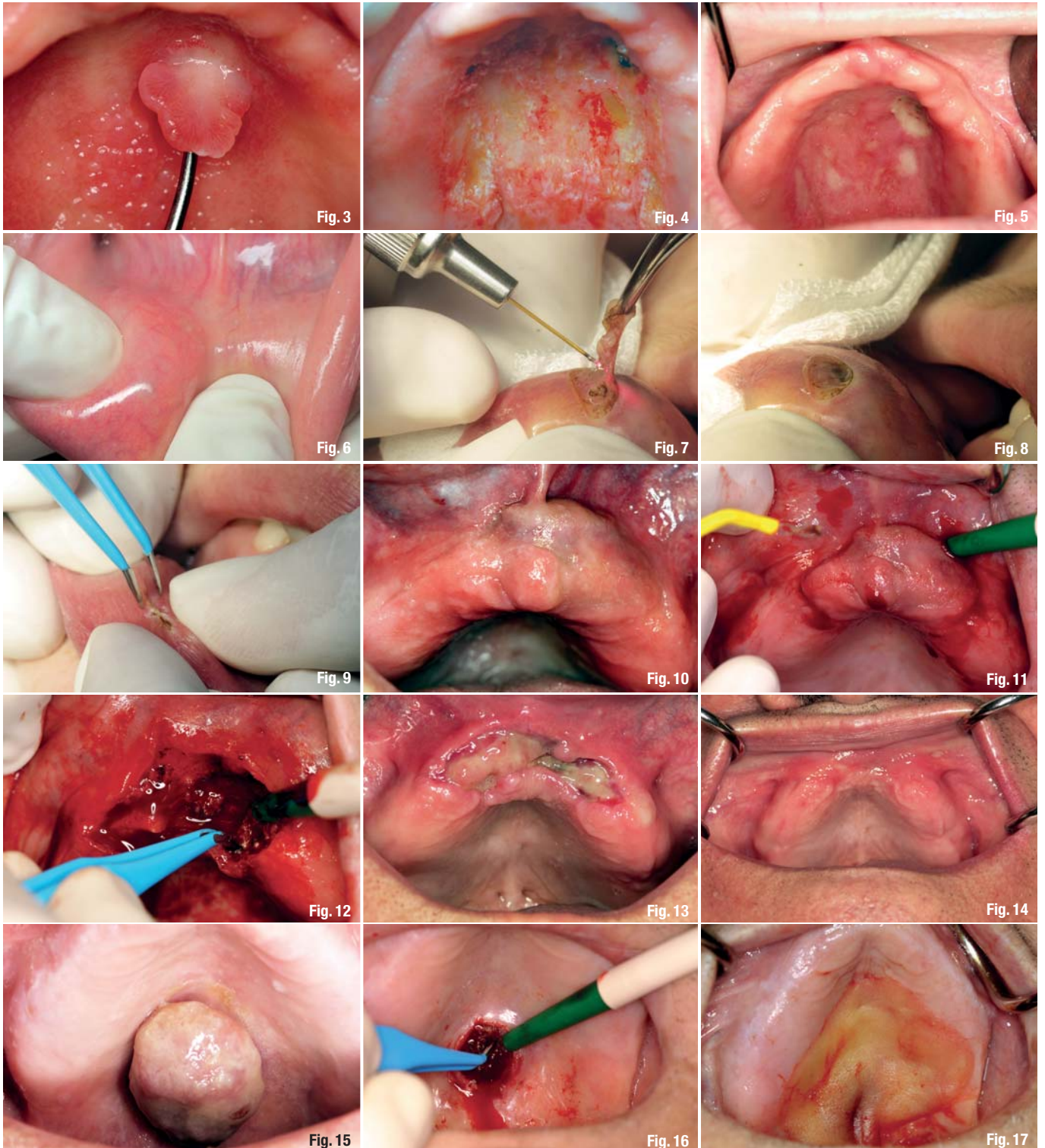


Fig. 3 Clinical appearance of the palatal fibroepithelial polyp and inflammatory papillary hyperplasia of the hard palate.

Fig. 4 Immediate postsurgical view.

Fig. 5 Follow up, third day after surgery.

Fig. 6 Clinical appearance of the mucocele at the lower lip, before surgery.

Fig. 7 Surgical procedure performed using diode laser.

Fig. 8 Immediate postsurgical view.

Fig. 9 Closing of the incision lines with bipolar forceps using radiofrequency technology.

Fig. 10 Clinical appearance of the maxillary giant cell granuloma.

Fig. 11 Removal of giant cell granuloma with radiofrequency.

Fig. 12 Bleeding control using bipolar forceps immediately after excision.

Fig. 13 Follow-ups, two weeks after surgery.

Fig. 14 Follow up, five weeks after surgery.

Fig. 15 Clinical appearance of metastasis at the hard palate.

Fig. 16 Immediate postsurgical view, bleeding control using bipolar forceps.

Fig. 17 Wound covered with a dressing.

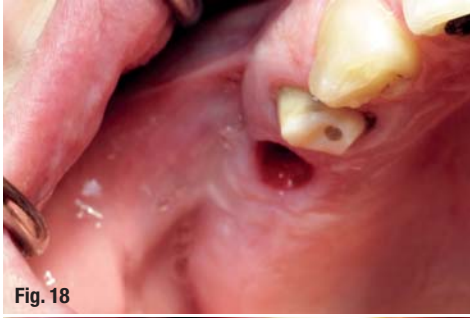

Fig. 18

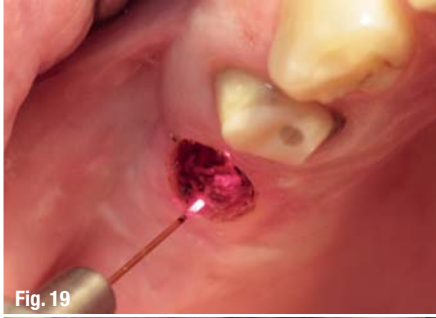

Fig. 19

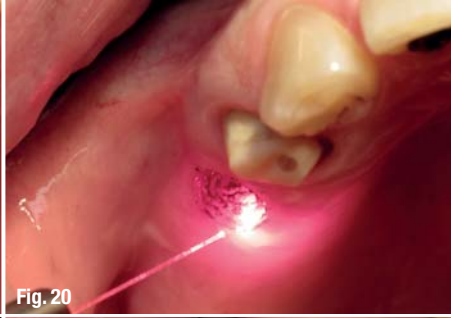

Fig. 20

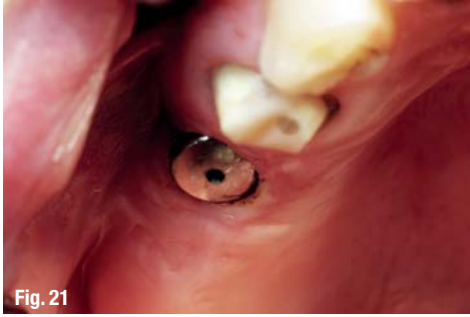

Fig. 21

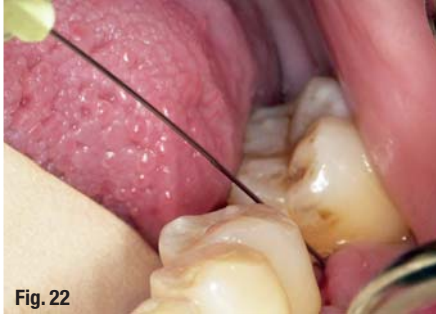

Fig. 22

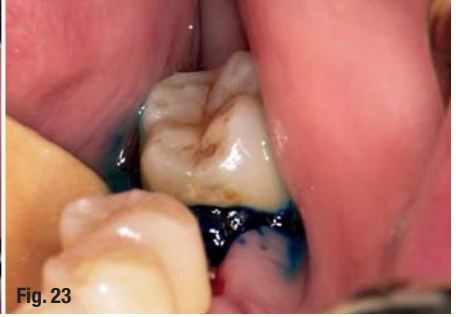

Fig. 23

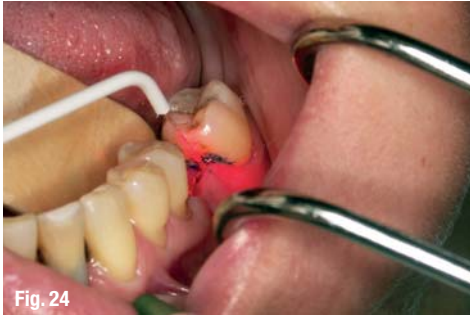

Fig. 24

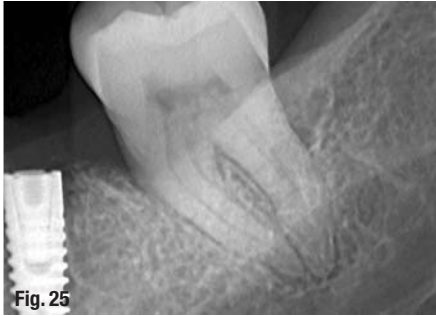


Fig. 25

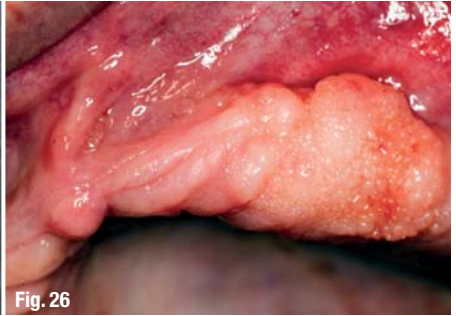

Fig. 26

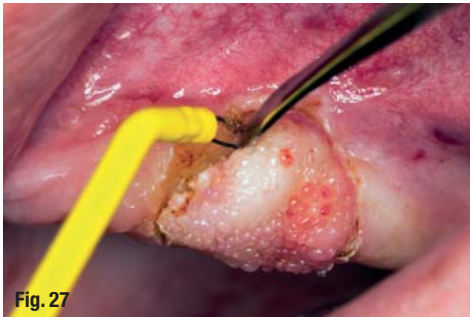

Fig. 27

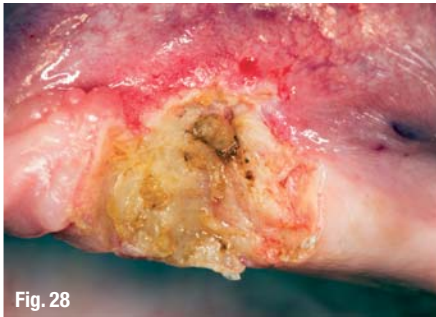

Fig. 28

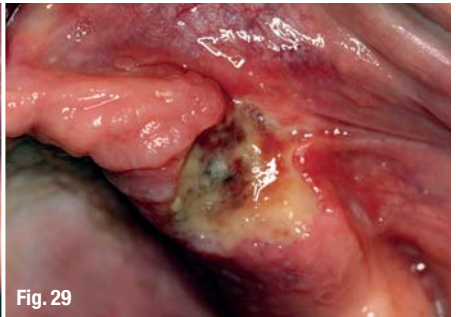

Fig. 29

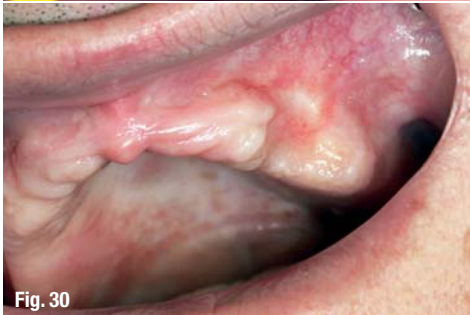

Fig. 30

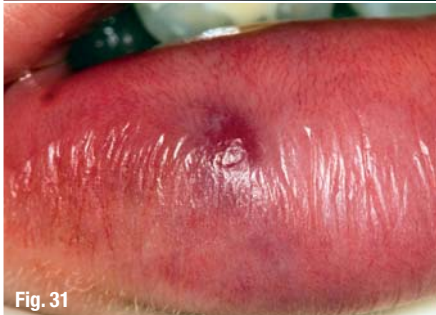

Fig. 31

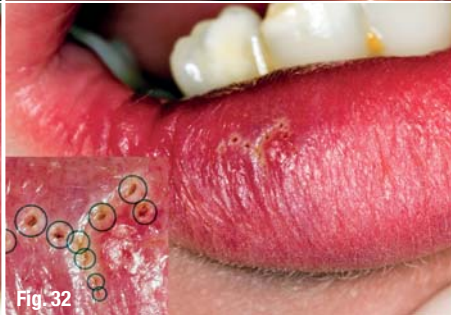

Fig. 32

Fig. 18 Pre-surgical clinical view.

Fig. 19 Re-contouring of the soft tissue using diode laser.

Fig. 20 Application of aPDT before abutment fixation.

Fig. 21 Immediate postsurgical view.

Fig. 22 Application of photosensitiser gel through periodontal space and central ridge incision line.

Fig. 23 Distribution of photosensitiser gel around the periimplantitis area.

Fig. 24 aPDT, using red 660 nm diode laser.

Fig. 25 Control radiograph, four weeks after finishing the treatment.

Fig. 26 Presurgical clinical view.

Fig. 27 Radiofrequency electrode cuts the carcinoma.

Fig. 28 Immediate postsurgical view.

Fig. 29 Follow-up after five days.

Fig. 30 Follow-up, five weeks after surgery.

Fig. 31 Pre-surgical view of hemangioma in the lower lip.

Fig. 32 About ten single punctures with a thin needle electrode (see magnification).

is not only absorbed in the tissue and converted into heat, it also will be partially transmitted through the tissue and may cause unpredictable and undesired side effects in adjacent healthy areas. Furthermore, the cutting speed of a laser beam is limited by the fact that the tissue can only be removed in layers. Neither increasing the laser power nor using pulsed laser radiation can eliminate this problem.

A promising approach

The combination of a diode laser and a modern radiofrequency generator in one unit is a useful and perfect tool for an extensive soft tissue management. The laser can treat the relatively thin and complicated oral tissue very selectively and shows promising and successful results in periodontics, endodontics and implant surgery. The radiofrequency technology on the other hand, because of its significantly higher cutting speed and perfect coagulation, has benefits in oral surgery. Tissue will be heated and cut simultaneously, homogeneously and very fast in the entire length of the inserted metal electrode. Damage to adjacent healthy areas are unlikely. If they do occur, they are predictable and can be planned. Photodynamic therapy (PDT), low level laser therapy (LLLT) and tooth bleaching make new, additional treatments possible. At the

Department of Oral Surgery at the University of Zagreb, Croatia, a clinical study was performed to demonstrate the use of the combined LaserHF® unit, consisting of a 975 nm diode laser with 8 W power (cw, pulsed), a 2.2 MHz radiofrequency generator with 50 W power (monopolar and bipolar) and a 660 nm diode laser with 100 mW power (cw), in various treatments of oral soft tissue lesions (Figs. 1 & 2). To all patients, local anaesthesia was administered before the procedures. Patients in this study showed significantly less oedema and hematoma as well as significantly less pain and higher satisfaction compared to conventionally treated patients ($p < 0.05$).

Case presentation

Out of these patients we present the following cases:

Case 1

A female patient aged 67 presented with palatal fibroepithelial polyp and inflammatory papillary hyperplasia of the hard palate (Fig. 3). The soft tissue surgery was performed with a radiofrequency loop electrode at 35 W and diode laser 975 nm with a power of 5 W in continuous mode (cw). Low level laser therapy (LLLT) at 660 nm followed for 90 s im-

AD

*become an author
for "laser"*

[PICTURE: ©SHUKHVA]



Please contact Claudia Jahn
✉ c.jahn@oemus-media.de

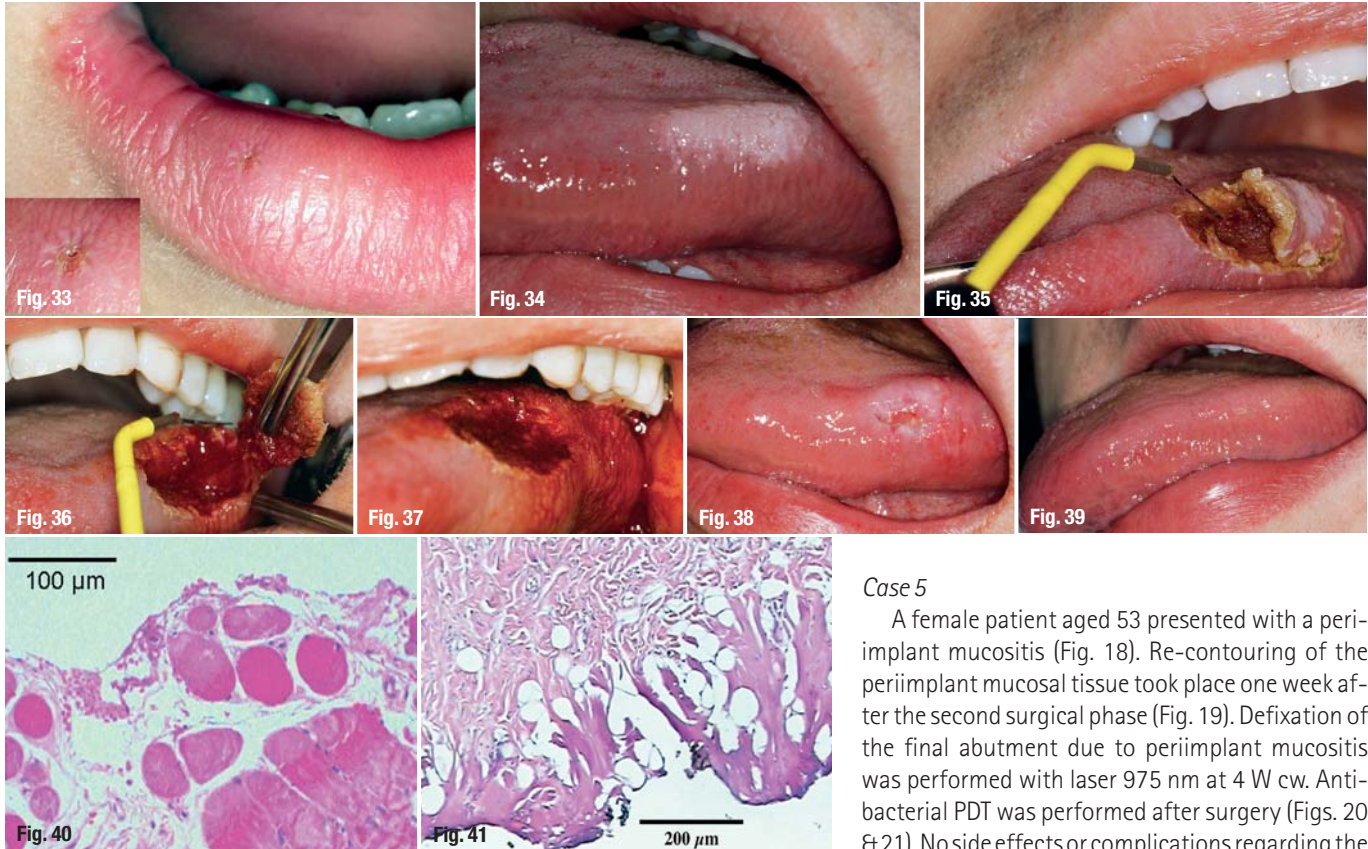


Fig. 33 Following up after five days.

Fig. 34 Leukoplakic, exophytic growing alteration (12 x 25 mm) at the left side of the tongue.

Fig. 35 The tissue was very deeply removed from the tongue muscle to prevent any recurrences.

Fig. 36 Due to the repeated growth and the unclear etiology, the tissue was deeply removed from the tongue muscle to prevent any recurrences.

Fig. 37 This method allows an almost pressure-free work, resulting in straight-cut edges in the muscle.

Fig. 38 Increasing epithelialisation two weeks postoperatively

Fig. 39 An impressive macroscopic scar-free result eight months after surgery.

Fig. 40 Alterations like thermal induced vacuoles in the striated muscle could not be seen after using radiofrequency technology.

Fig. 41 Histological comparison of the thermal reaction zone produced with a 980 nm laser at 3 W cw. The broad and partially melted reaction zone is a result of a significant temperature effect

mediately after the surgical (Fig. 4) procedure was performed. Neither side effects nor complications occurred after surgery (Fig. 5).

Case 2

A female patient aged 23 presented with a mucocele in the lower lip (Fig. 6). The surgery was performed with the laser 975 nm at a power of 5 W in cw-mode (Figs. 7 & 8). The lesion was closed using a bipolar radiofrequency forceps (Fig. 9). LLLT application 660 nm with a power setting of 90 mW followed immediately for 90 s.

Case 3

A male patient presented with a giant cell granuloma of the upper jaw, central type in the frontal region of the maxilla (Fig. 10). The surgery was performed with radiofrequency cutting-mode (35 W) and laser 975 nm, 5 W cw. LLLT application followed immediately after surgical procedure (660 nm, 90 mW for a period of 90 s, Figs. 11 & 12). Follow-ups were taken two (Fig. 13) and five weeks after surgery (Fig. 14).

Case 4

A male patient, aged 82, presented with a metastasis of adenocarcinoma of the kidney (Fig. 15). Surgery was performed using radiofrequency cutting (35 W), coagulation grade 3 as well as laser 975 nm, 5 W cw, in combination (Figs. 16 & 17).

Case 5

A female patient aged 53 presented with a peri-implant mucositis (Fig. 18). Re-contouring of the peri-implant mucosal tissue took place one week after the second surgical phase (Fig. 19). Defixation of the final abutment due to peri-implant mucositis was performed with laser 975 nm at 4 W cw. Antibacterial PDT was performed after surgery (Figs. 20 & 21). No side effects or complications regarding the implant-bone interface after surgery were reported. Systemic antibiotic therapy was also included.

Case 6

A female patient with periimplantitis: Treatment of initial periimplantitis using closed technique was performed with systemic antibiotic therapy (Figs. 22 & 23) and aPDT (660 nm, 100 mW, 3 x 10 s) for ten consecutive days (Figs. 24 & 25).

Case 7

Male patient, aged 66, presented with verrucous carcinoma (Fig. 26). The surgery was performed with radiofrequency 35 W, coagulation grade 3—elliptic loop electrode and laser 975 nm, 5 W cw, in combination (Figs. 27–30).

Case 8

An 11-year-old girl presented with a haemangioma in the lower lip (Fig. 31). Low power radiofrequency application was conducted with 15 W, coagulation grade 2. A fine needle electrode (diameter 0.2 mm, length 5 mm) has been inserted into the tissue at about 10 points around the lesion, resulting in shrinkage of the tissue (Figs. 32 & 33). This treatment is not possible using the laser device.

Case 9

A 33-year-old patient presented with a leukoplakic, exophytic growing alteration (12 x 25 mm) at the left side of the tongue (Fig. 34). Considering the par-

ticular topography and anticipated depth of the lesion, the treatment was performed with radiofrequency at 2.2 MHz and a power of 50 W, using little coagulation (grade 1–2) simultaneously (Figs. 35–37). Monopolar operation was chosen with the neutral electrode on the shoulders of the patient. With a laser such a deep surgical operation would not be possible. After anaesthesia of the left N. lingual, the surgical area was marked with a fine, very thin electrode and the cutting line was defined in the range of the healthy mucosa. Follow-ups were taken two weeks (Fig. 38) and eight months (Fig. 39) after surgery.

The healing was without complications or serious swelling, but with moderate post-operative pain. There were no functional limitations, form and function of the tongue have been preserved or fully restored. The histological evaluation of the excised tissue showed no changes; only in the direct section area, a low thermal reaction zone was found (Figs. 40 & 41).

Conclusion

For precise applications in dental soft tissues, especially surgical incisions, scalpel, laser and radiofrequency are appropriate tools. The right choice must be made by the dentist and is based on various criteria: If the lesions are relatively small and if they are more in the depth of the tissue, and no previous histopathologic evaluation is possible or useful, laser or radiofrequency are suitable devices. In contrast to the scalpel, a flushing out of abnormal cells and distant metastasis can be substantially averted. Besides, the scalpel always induces some mechanical stress to tissues which may lead to unprecise healing and thus cannot always claim a good cosmetic result. On the opposite, thermally produced incisions made by radiofrequency are fast and stress-free, providing excellent cosmetic results. They also deliver convincing results in more complicated procedures in the depth of the tissue. With appropriate coagulation, just minor tissue alterations are found, thus promising a good healing. The laser is more to be seen as a tool with strong importance in the treatment of superficial lesions due to its mode of layer-by-layer operation. Apart from treatments in periodontics, in endodontics, in PDT, Bleaching and LLLT, the laser is a perfect instrument for reshaping and smoothing of wound edges, for removal of overgrown implants, trimming of gingiva, drying and shrinking of tissue and of course even for small superficial surgery (Fig. 42).

Laser and radiofrequency technology show some delay in the epithelial regeneration. A wound

	LASER	Radio frequency	L + RF
Oral surgery	●	●	●
Periodontics	●	●	●
Implantology	●	●	●
Endodontics	●	●	●
Bleaching	●	●	●
PDT	●	●	●
LLLT	●	●	●

Fig. 42



Fig. 42_ The laser is not perfect in oral surgery and the radiofrequency is not suitable in many other dental applications. However, in the combined device, they both can perform as perfect tools for the dental soft tissue management.
Fig. 43_ The LaserHF® device.

takes some more time to re-epithelialise than following conventional surgery with a scalpel. However, they offer a minimally invasive technique with an intention to make surgical applications less extensive. They may reduce the need for general anaesthetics or hospital care, and therefore can lower the overall costs.

Considering the potential applications, the combination of a diode laser with a radiofrequency device meets the desire for a perfect system in the dental soft tissue management. The LaserHF® (by Hager & Werken, Germany, Fig. 43) is the worldwide first combination device. It consists of a 975 nm laser with a power of up to 8 W, combined with a 2.2 MHz radiofrequency generator—monopolar and bipolar—with a power of 50 W. An additional 660 nm laser with a power of 100 mW completes the device as therapy supplement for photodynamic (PDT) and low level laser therapy.

_contact	laser
<p>Hans-H. Koort MedLas Consult Auf der Schleide 18 53225 Bonn, Germany</p> <p>www.medlas.com</p>	