Fluorescence-guided caries excavation of decayed teeth

An *ex vivo* study

Authors: ZA Martin Augenstein & Prof. Dr Matthias Frentzen, Germany

Introduction

The goal of caries excavation is the elimination of bacterially infected dentin to give the maximal conservation of healthy dental hard tissue as well as to maintain the vitality of the dental pulp.[1] Dentin layers near the pulp which can be remineralised—affected dentin—should be preserved in terms of an atraumatic therapy.[2,3] There are several techniques to determine the endpoint of the excavation clinically. One of these techniques is the examination of the hardness of the cavity floor using a dental probe. For this type of test, the dental probe must not infiltrate the material further; the "Crie dentaire" must be audible. However, this test is not objectifiable and does not correlate with bacterially infected dentin.[2] Additionally, Fusayama et al. observed that dentin areas close to the pulp show a significantly lower hardness than dentin of a chronical carious lesion.[2]

Fig. 1: SIROInspect® with filter glasses, accessory parts and charging station (Sirona Homepage, 2014).

Fig. 1

Studies with dye solutions, which are supposed to mark infected dentin, do not show unambiguous results either, since hypomineralised dentin areas and porosities are stained as well.[4] This often results in an overexcavation under clinical conditions, since even non-infected hypomineralised areas such as the dentino-enamel junction or healthy areas near the pulp are stained.[5,6]

A fluorescence-based optical method may be considered an alternative.[7] Optical phenomena in the tooth structure damaged by caries or the spectroscopic detection of metabolic products of a microbial infection of the dentin are used.[8,9] Examples for this procedure are the DIAGNOdent®-system,[10] intraoral camera systems with blue light excitation[11] as well as feedback controlled Er:YAG laser systems.[12] The previously-mentioned systems are difficult to implement in practice. The technology is very complex.

Devices which stimulate the dentin with a blue-light diode (405 nm) present an alternative; the examiner gives an evaluation with the help of filter glasses, making the fluorescence visible during the treatment of caries excavation. This treatment technique is called the FACE® method (Fluorescence Aided Caries Excavation).[7] The present study attempts to examine histologically under *ex vivo* conditions whether

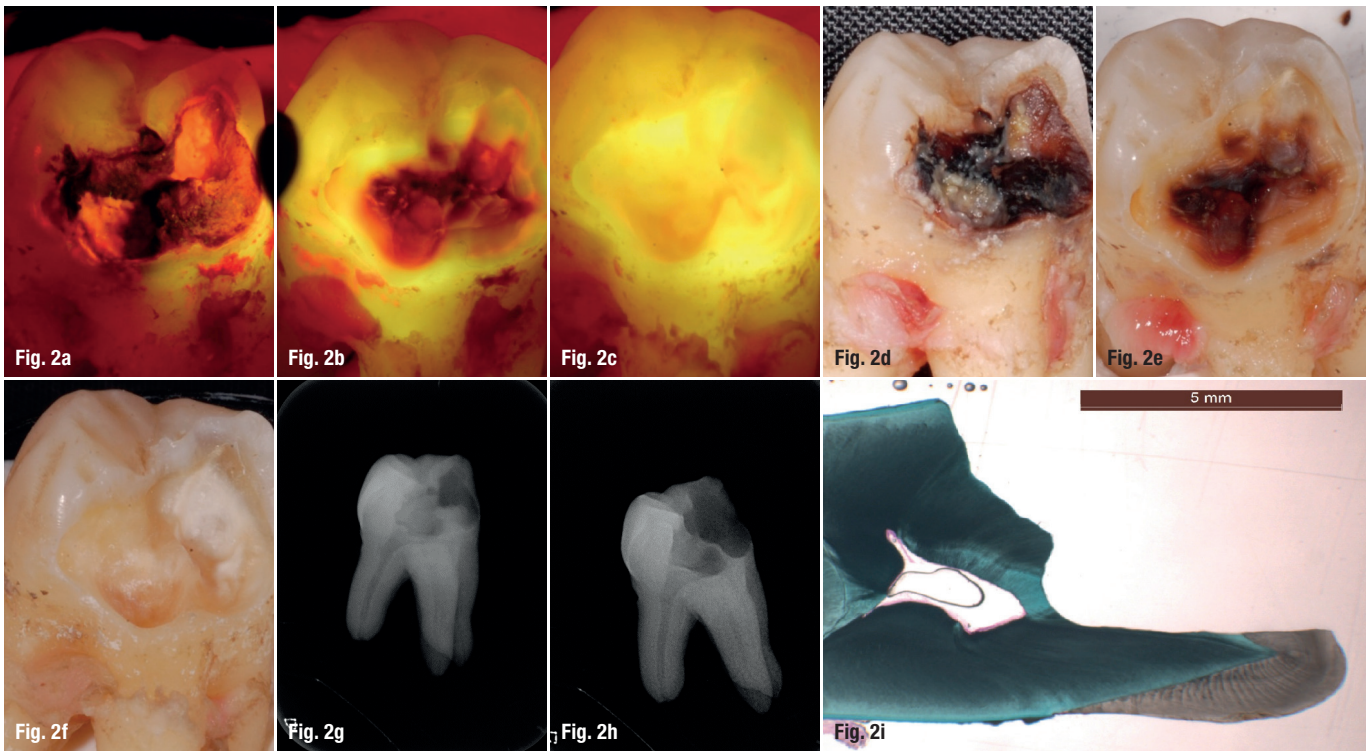

Fig. 2 a–i: Case example I—Documentation of a tooth sample in process of the examination; before excavation a daylight shot and a fluorescene shot (through a high-pass filter > 500 nm) of the cavitated decayed lesion were taken; intermediate steps **(b)**, **(e)** as well as the complete excavation **(c)**, **(f)** using the SIROInspect® were documented; additionally X-rays were taken after extraction and after the complete treatment **(g)**, **(h)**; the histological examination of the thin sections was evaluated microscopically **(i)**.

an atraumatic, complete excavation of bacterially infected dentin is possible.

Material and methods

In this study, 31 human teeth with carious lesions were examined. The indication for the extraction of the teeth was made independently from this trial. Patients gave their informed consent for the scientific use of the samples. All in all, 27 teeth were treated with the FACE®-System (SIROInspect®, Sirona, Bensheim, Germany) directly within two hours after extraction (Fig. 1); four untreated teeth served as reference for the histological evaluation.

The initial state was recorded by a photo as well as X-ray. After that, the teeth were fixed in a stage. Then the cavity was illuminated using the SIROInspect®-light probe (405 nm, 60–250 mW)

AD

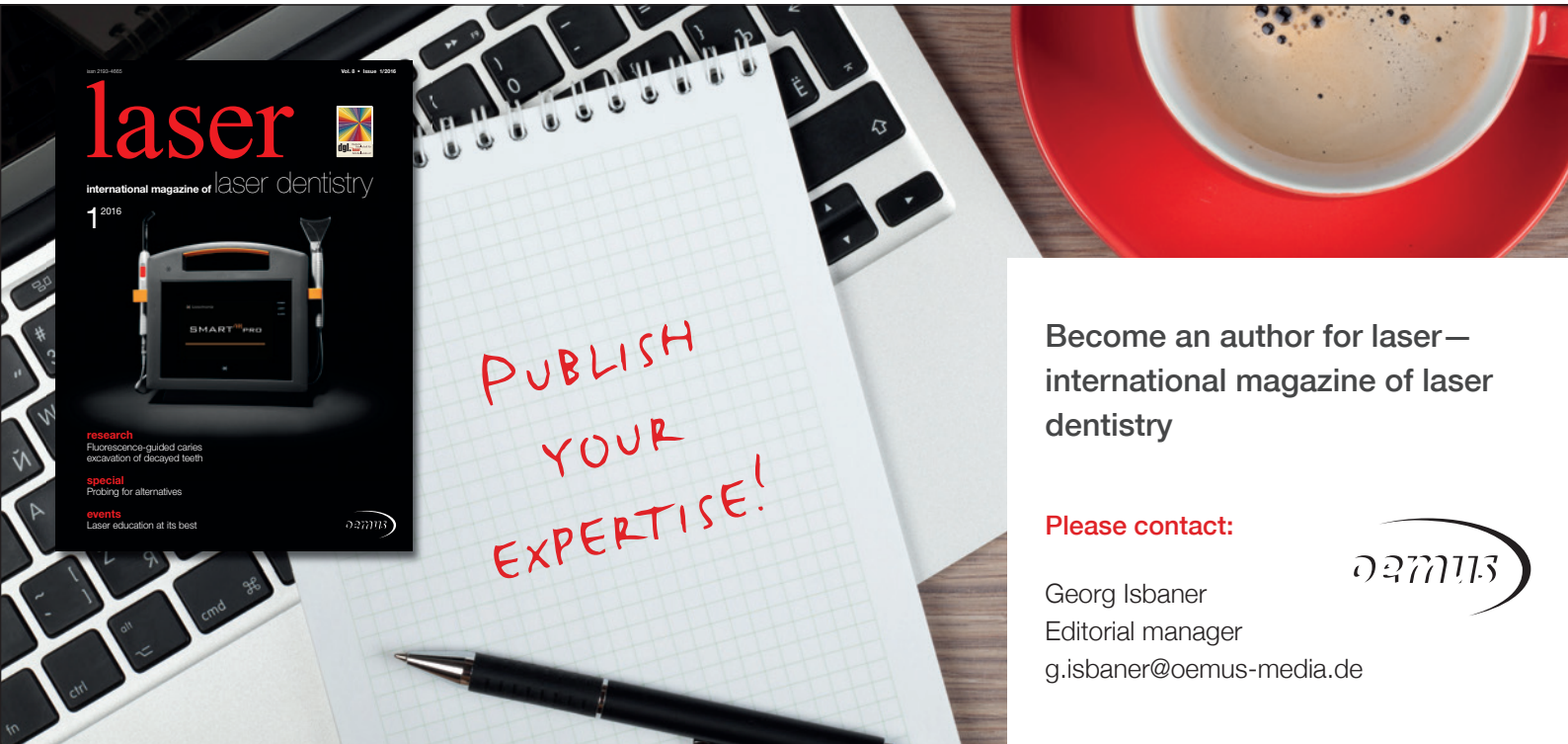

Become an author for laser—international magazine of laser dentistry

Please contact:

Georg Isbaner
Editorial manager
g.isbaner@oemus-media.de

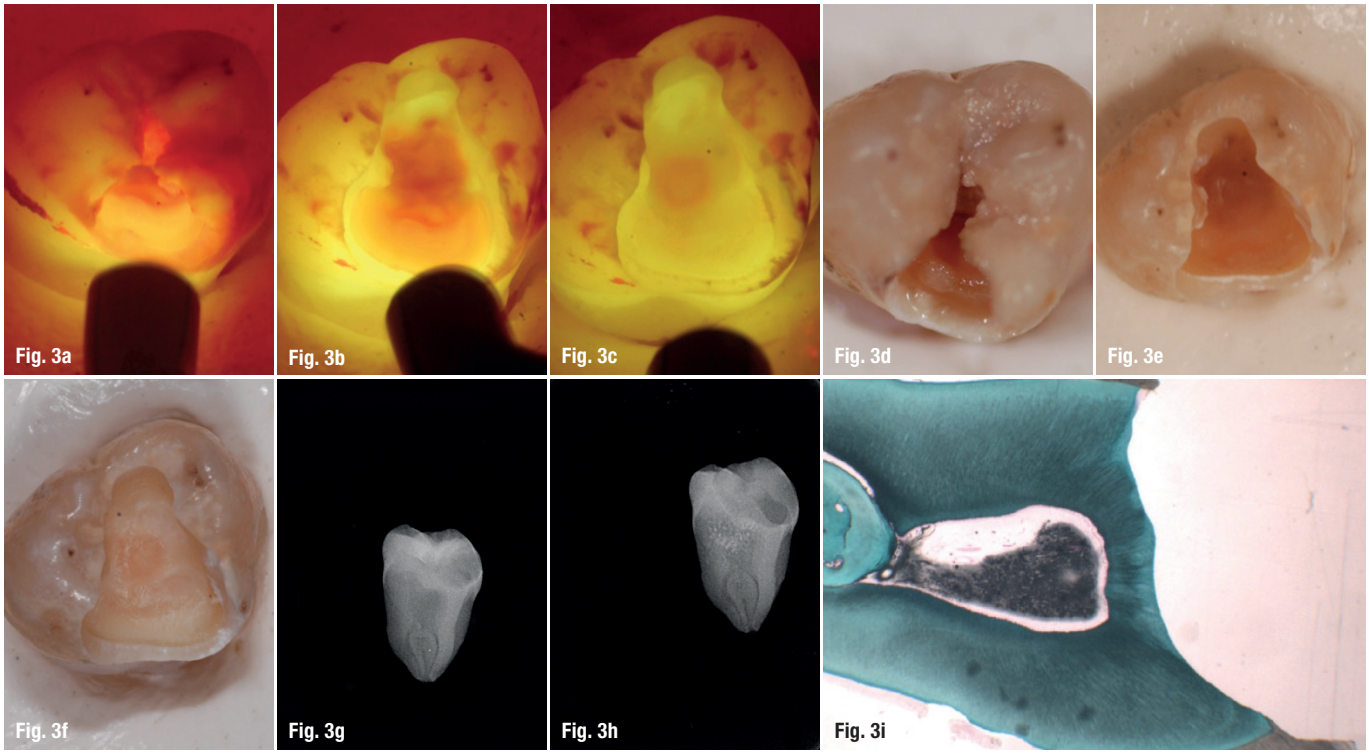

Fig. 3 a–i: Case example II— Documentation of a tooth sample in process of the examination; before excavation a daylight shot and a fluorescene shot (through a high-pass filter > 500 nm) of the cavitated decayed lesion were taken; intermediate steps **(b)**, **(e)** as well as the complete excavation **(c)**, **(f)** using the SIROInspect® were documented; additionally X-rays were taken after extraction and after the complete treatment **(g)**, **(h)**; the histological examination of the thin sections was evaluated microscopically **(i)**.

and was photographed through a high-pass filter which had the same properties as the filter glasses of the goggles (Figs. 2a, d, g and 3a, d, g). This filter system only lets waves with a wavelength larger than 500 nm pass. Subsequently, an access cavity was prepared with a diamond bur and the carious changed tissues were excavated with a carbide bur with 1,600 rpm using the laser system according to the manufacturer information until no more red fluorescent dentin was visible. The examiner used magnifying glasses to control the treatment. An X-ray and photographic documentation as well as a fluorescence image of the tooth were made according to the initial photographs (Figs. 2c, f, h and 3). The teeth were stored in isotonic saline solution during all steps of the examination. Before histological thin-section preparations were made, the teeth were stored in formalin solution (4 %) and stained with rhodamine fuchsine fast green. Overview pictures were made of all dental probes with a magnification of six times (Figs. 2i and 3i). The identification of histological caries zones (Fig. 4), until which an excavation was performed under the control of the laser system, was carried out at a magnification of 12 times and 18 times respectively. Untreated teeth with cavitated decayed lesions served as histological reference.

Results

In 93 % of the teeth with cavitated caries lesions, red fluorescence were detected in the area of the lesion. Two samples did not show red fluorescent features, but only fluoresced in the brownish spectral range. These two teeth were also excavated until there was no more brownish fluorescence. The sections of these teeth did not show any abnormalities of structure in the periphery of the carious lesions.

The X-rays revealed a complete excavation for all teeth. 96 % of the teeth were identified histologically free from bacteria (Figs. 2 and 3). In 37 % of the samples, parts of sclerotic dentin were preserved. After the excavation using the laser system, carious dentin (microbiological contamination) was identified histologically only in one sample.

Discussion

In 2002, Lennon et al. already examined whether red fluorescence corresponds to bacterially infected dental hard tissue.[7] In his study, the FACE® method was compared to other methods of excavation. DNA labeling of the samples was assessed by means of CLSM (Confocal Laser Scanning Microscopy) as objective evidence. The study showed a sensitivity of 94 % and a specificity of 83 % for the FACE® method. The results of a conventional excavation method were distinctly below those values and the excavation method using carious detector dye were rated the worst with 65 % for sensitivity and a were only 17 % for specificity.[7] Another significant finding is that if there was a

SIROLaser Blue

UNENDLICHE MÖGLICHKEITEN.



Der neue SIROLaser Blue:
Maximale Schneidleistung trifft
auf höchste Behandlungsvielfalt.
3 Dioden. Mehr als 20 Indikationen.
Unendliche Einsatzmöglichkeiten.

SIRONA.DE/LASER

The Dental Company

sirona.

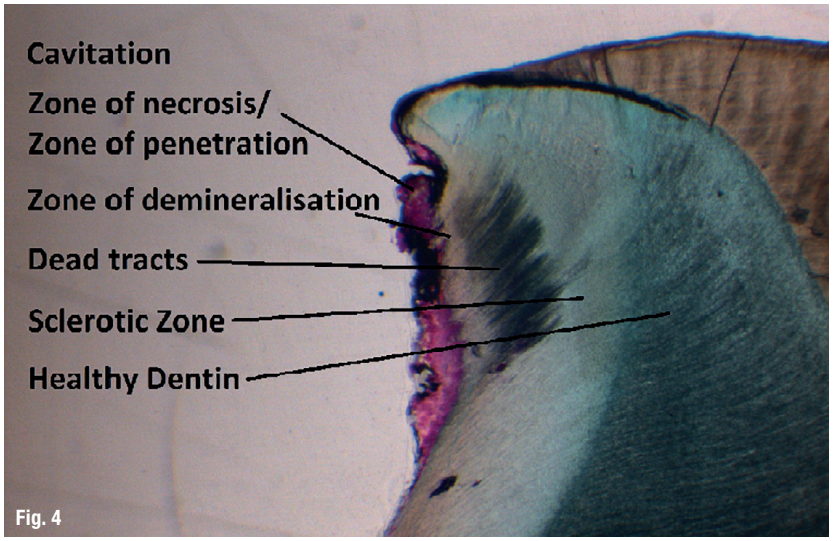

Fig. 4: 18x magnification; extended cavitation; histological image which served as reference for the determination of histological layers of caries.

lack of red fluorescence on the dental hard tissue, 95% of the tooth samples were documented clear from bacteria. This study confirms these results for the fluorescence guided carious excavation using SIROInspect®.

In addition, excavation using FACE® could be completed in a shorter period of time than the chemomechanical excavation or the use of Caries Detector®.[13] The cavity size did not increase and the number of remaining bacteria was significantly lower for the use of FACE®.[14]

In a comparative study, the FACE® method using a VistaProof camera was examined in contrast to the conventional excavation with a probe and the excavation using Caries Detector®.[15] While other treatment methods were often completed when the hard, healthy dentin was reached, in this study the FACE® method made it possible to selectively excavate bacterially infected dentin. These results coincide with the findings of the present study. After laser excavation, 96 % of the teeth were histologically caries-free and in 37 % of the samples, sclerotic dentin could be detected indicating a gentle excavation. Due to the small layer thickness of the sclerotic dentin in extended cavities, its conservation provides evidence of the method being tooth conserving.

Conclusion

The SIROInspect®-tool offers an easy, practicable system for the examiner to visualise carious hard tissue during the excavation. In addition, the easy handling of the system allows for a time-optimised excavation while minimising the risk of increasing cavity size under clinical conditions._

contact

Prof. Dr Matthias Frentzen
Welschnonnenstraße 17
53111 Bonn, Germany
Tel.: +49 228 287-22470
Fax: +49 228 287-22694
frentzen@uni-bonn.de

Kurz & bündig

Das Ziel der Kariesexkavation ist die Eliminierung des durch Bakterien infizierten Dentins; gesundes Hartgewebe soll in größtmöglichem Umfang erhalten werden, um die Vitalität der Pulpa zu bewahren. Es gibt verschiedene Methoden, um den Endpunkt der Exkavation klinisch zu bestimmen. Dazu zählt u. a. die Untersuchung der Härte des Kavitätenbodens mithilfe einer Dentalsonde. Bei vollständiger Exkavation sollte der „Crie dentaire" deutlich hörbar sein. Alternativ wird die Möglichkeit einer Farbkodierung des Dentins beschrieben. Diese Tests sind jedoch nicht objektivierbar und zeigen nicht an, ob infiziertes Dentin vollständig entfernt wurde bzw. ob bereits eine Überexkavation im gesunden Gewebe vorliegt.

In der vorliegenden Studie wurden 31 menschliche Zähne untersucht, die kavitierte kariöse Läsionen aufwiesen. Die Indikation zur Zahnextraktion wurde unabhängig von dieser Studie gestellt; die Patienten stimmten der wissenschaftlichen Untersuchung der Zähne zu. Insgesamt 27 der 31 Zähne wurden mit Unterstützung des FACE®-System (SIROInspect®, Sirona/Bensheim) innerhalb von zwei Stunden nach der Extraktion exkaviert, vier der Zähne blieben unbehandelt und dienten als Referenzzähne für die histologische Evaluierung.

Nach Exkavation mit Unterstützung des FACE®-Systems konnten 96 Prozent der Zähne histologisch als kariesfrei eingestuft werden, bei 37 Prozent der Zähne wurde die Zone des sklerotischen Dentins im Rahmen der Kariesentfernung belassen, was auf ein schonendes Vorgehen hindeutet.

WFLD 2016

WFLD 2016
Nagoya, Japan

The 15th Congress of the World Federation for Laser Dentistry

Light to brighten the future

in collaboration with:

The 28th Annual Meeting of Japanese Society for Laser Dentistry

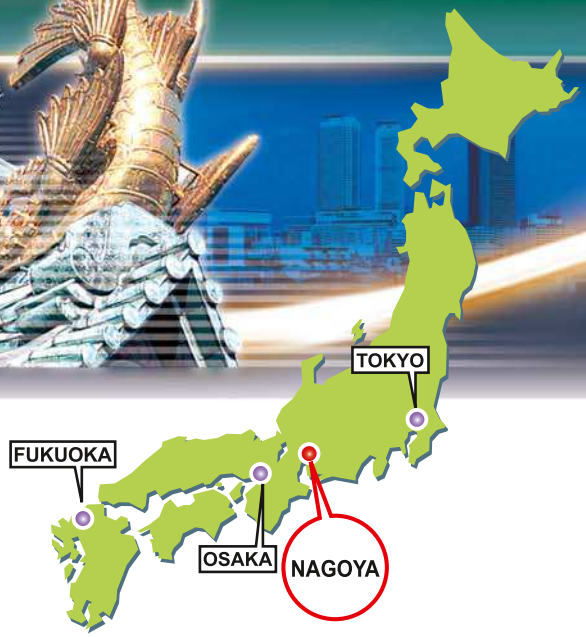

July 17(Sun)-19(Tue), 2016
Nagoya, Japan

Venue Aichi Industry & Labor Center (WINC AICHI)

Chairperson Kenji Yoshida, D.D.S., PH.D.
Department of Oral & Maxillofacial Surgery,
School of Dentistry Aichi-Gakuin University

Secretariat

WFLD 2016 Secretariat
c/o Convention Linkage, Inc.
Asahiseimei Bldg., 3-32-20 Sakae, Naka-ku,
Nagoya 460-0008, Japan
Phone: +81-52-262-5070 Fax: +81-52-262-5084
E-mail: wfld2016@c-linkage.co.jp

http://www.c-linkage.co.jp/wfld2016/