

The diagnosis of Hyperplastic Follicular Tissue, Early Dentigerous Cysts, Dentigerous Cysts and Paradental Cysts associated with symptomatic third molar teeth with emphasis on age of treatment and possible complications

Brian M. Berezowski BDS, M Dent (MFOS), FDSRCS, PhD, FFD (SA), FFD RCS (IRE), FCMFOS (SA)¹
 Gary C. Cousin BDS, MBChB, FDSRCS, FRCS (OMS), FDSRCP (GLASG), FRCS (Ed)²

Abstract

Diagnose verschiedener Zystenarten bei symptomatischen Weisheitszähnen

In zahlreichen Beiträgen wurde gezeigt, wie unzuverlässig eine Diagnose ist, wenn sie sich allein auf ein Röntgenbild stützt.¹⁻⁵ Vorherige Arbeiten zeigten mit zunehmendem Alter eine Tendenz zur weichgeweblichen, pathologischen Veränderung bei Symptomen im Bereich der dritten Molaren.⁶ Solche Veränderungen schließen hyperplastische Follikel, frühe dentogene Zysten, dentogene Zysten, paradentale Zysten und weitere verschiedene pathologische Befunde sowie Ameloblastome

mit ein.^{1,6} Da man in der dritten Lebensdekade eine Erhöhung pathologischer Befunde feststellte, kam es zur Forderung, alle Weisheitszähne mit Symptomen rechtzeitig in der zweiten und dritten Dekade zu entfernen und histologisch zu untersuchen.^{1,6} Da eine alleinige röntgenologische Untersuchung als für nicht ausreichend für eine genaue Bestimmung möglicher pathologischer Veränderungen gehalten wird und ein solches Vorgehen zu Komplikationen führen kann, wird nachdrücklich empfohlen, alle Proben histologisch zu untersuchen.⁶ Die Studie wurde in der chirurgischen Abteilung der Universität Kapstadt, Süd-

afrika durchgeführt. Die Studie erstreckte sich über eine Periode von über 20 Jahren, in welcher 3.437 dritte Molaren (Weisheitszähne) in Verbindung mit Weichgewebe entfernt und zur histologischen Untersuchung eingeschickt wurden. Die Eingriffe wurden alle durch denselben Chirurgen vorgenommen und die Proben wurden immer durch denselben Oral-Pathologen begutachtet (Anmerkung der Redaktion: In Südafrika gibt es einen eigenen Oral-Pathologen). Nicht die OP-Buch-Aufzeichnungen, sondern die aktuellen Patienten-Akten dienten als Quelle akkurater und vollständiger Informationen des Autors.

Introduction

There is uncertainty for maxillofacial surgeons, oral surgeons and dentists with regard to young patients who present with symptoms related to symptomatic third molars (wisdom teeth). These teeth often show radiolucent areas and occur in the late second and early third decades. It was shown in numerous articles that radiographic imaging alone was unreliable in making a diagnosis.¹⁻⁵ Previous work showed that there was a tendency for soft tissues around symptomatic third molars to demonstrate pathological change with increasing age.⁹ Such changes

included hyperplastic follicular tissue (HFT), early dentigerous cysts (EDC), dentigerous cysts (DC), paradental cysts (PC) and other miscellaneous pathologies including ameloblastomas.^{1,6} As there was an associated increase in pathology in the third decade, it was recommended that all symptomatic wisdom teeth be removed early in the second and third decade, and sent for histology.^{1,6} As radiological examination alone was not accurate for the determination of possible pathological lesions leading to complications it was strongly recommended that all specimens should be sent for histological examination.⁶

Method

The study was conducted in the Department of Surgery at the University of Cape Town in South Africa. This department follows the Helsinki Declaration. The study was conducted over a 20-year period in which 3,437 symptomatic third molar teeth (wisdom teeth) and associated soft tissue were removed and sent for histological examination. The surgery was performed by one surgeon and the specimens examined by one oral pathologist. The cases were contemporaneously sourced from actual patient files from which accurate and complete records were taken and not from theatre records.

Results

The total number of cases of the complete study was 3,427 cases (Fig. 1). The four lesions of hyperplastic follicular tissue (HFT), early dentigerous cyst (EDC), dentigerous cyst (DC) and paradental cyst (PC) accounted for 3,093 cases or 90.25 % of all cases sent for histological investigation. Percentage wise, the HFT accounted for 31.25 %, the EDC for 14.44 %, the DC for 8.11 % and the PC for 42.80 %. EDC and DC together represented 22.55 % of all the lesions removed; these are what would have been reported together as DC prior to the description of the EDC (Fig. 2).⁵ When the number of EDC and DC were combined (22.55 %), this is still less than the PC (42.80 %). This corresponds favourably with the number of cases reported by Mesgarzadeh et al.¹ A large number of studies do not include HFT, but this still accounts for a significant portion of associated pathology (Fig. 3).

Number of cases vs age of various pathologies

All the soft tissue samples came from patients aged 13–75 years, but most of the patients were in the 14–29 year range with a peak incidence late in the second decade. There was a decrease in HFT, EDC, DC and PC from the age of 40 years (Fig. 4).

1. Hyperplastic follicular tissue

Number of cases vs age of hyperplastic follicular tissue

The age range of patients with HFT was from 13–75 years with most in the 14–29 age groups. There was a peak incidence at 16–18 years of age (Fig. 5).

Number vs position and gender of hyperplastic follicular tissue

HFT was identified dominantly in females in the 28, 38 and 48 positions. Male patients had fewer lesions and they were more evenly distributed between all third molar sites with fewer lesions in the 18 and 28 positions (Fig. 6).

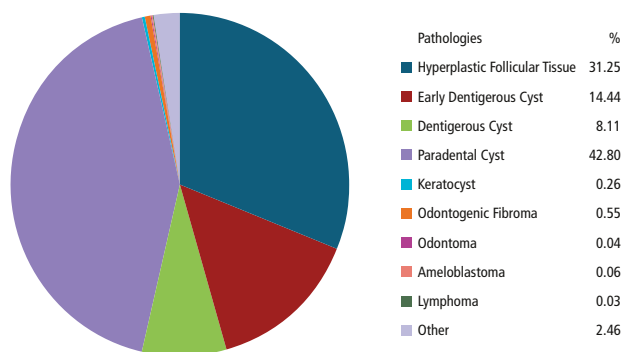


Fig. 1: Pathologies in the third molar area.

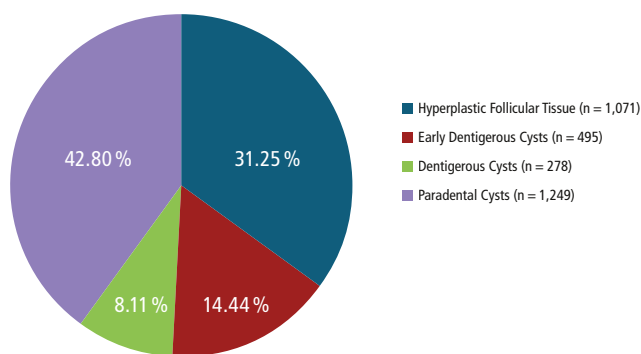


Fig. 2: Pathologies including the early dentigerous cyst.

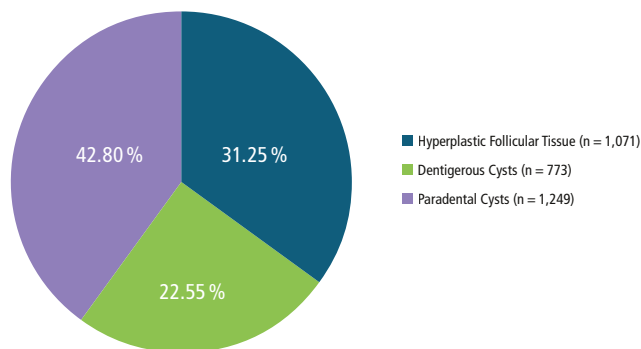


Fig. 3: Pathologies combining the early dentigerous cyst and dentigerous cyst.

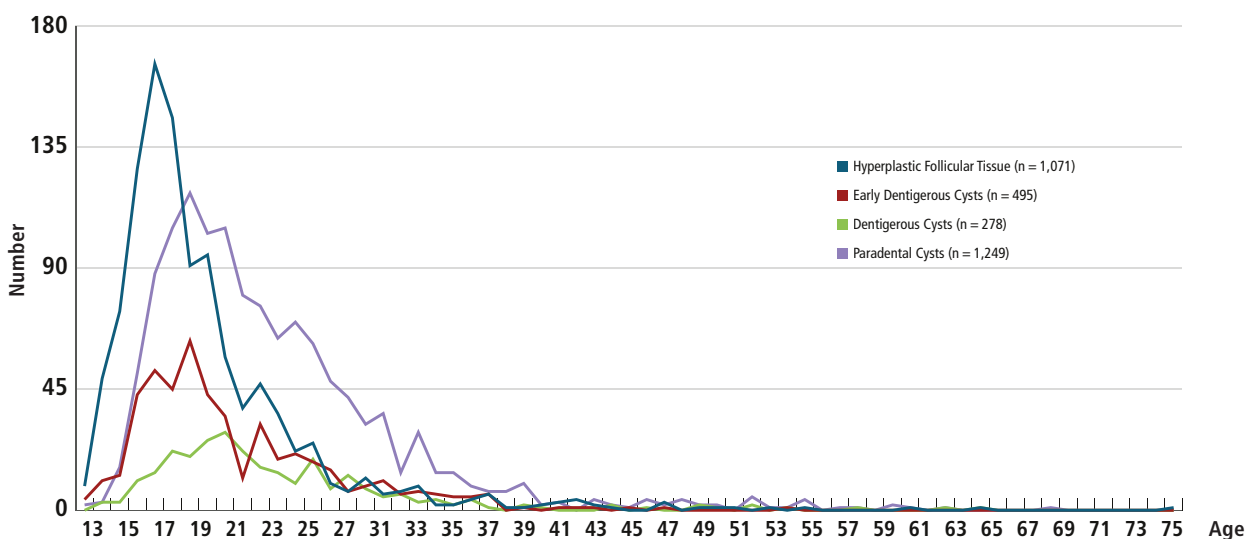


Fig. 4: Number of cases vs various pathologies.

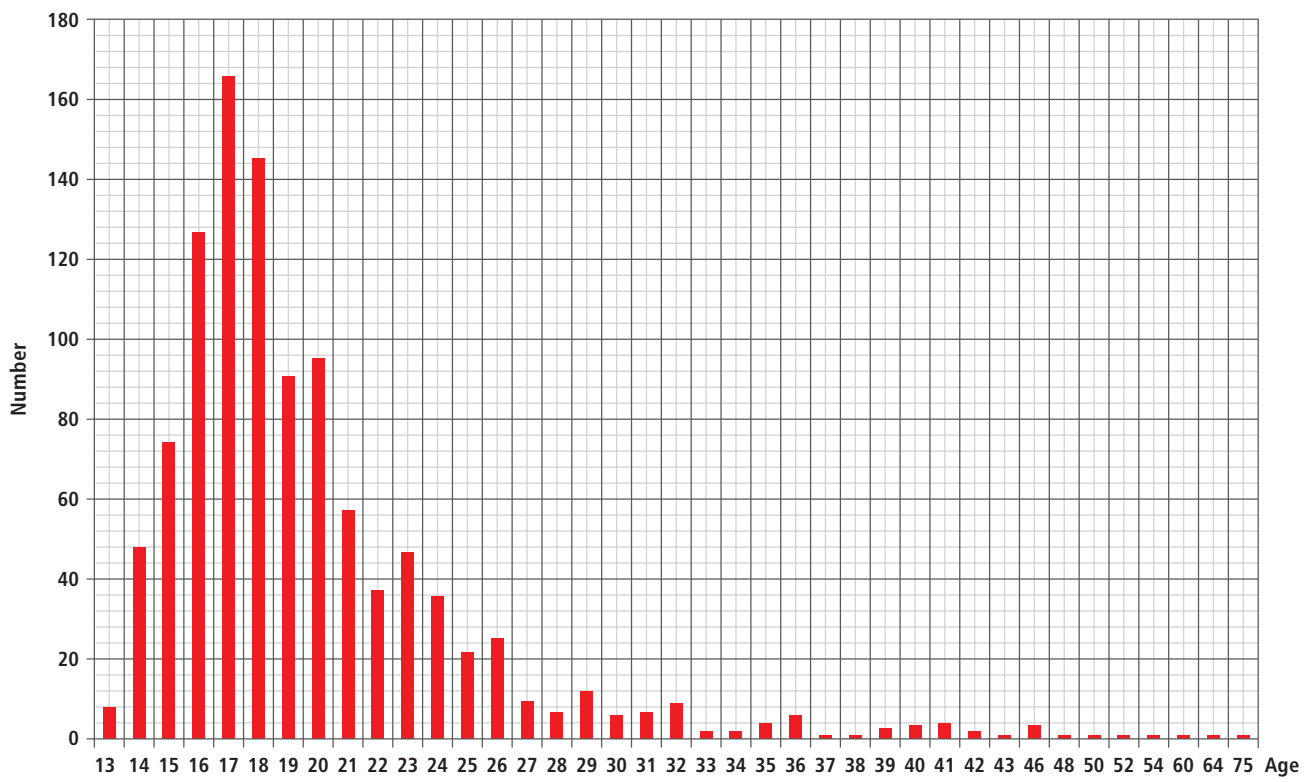


Fig. 5: Age of patients vs incidences of hyperplastic follicular tissue.

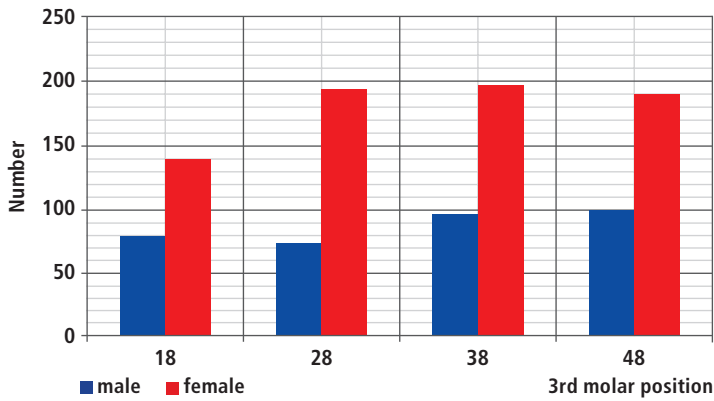


Fig. 6: Number of cases vs position and gender of hyperplastic follicular tissue.

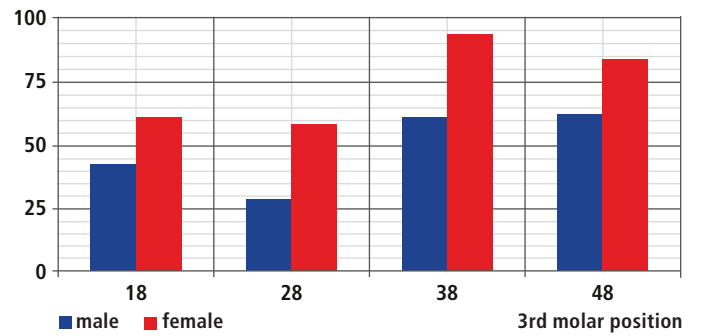


Fig. 8: Number of cases vs position and gender of early dentigerous cysts.

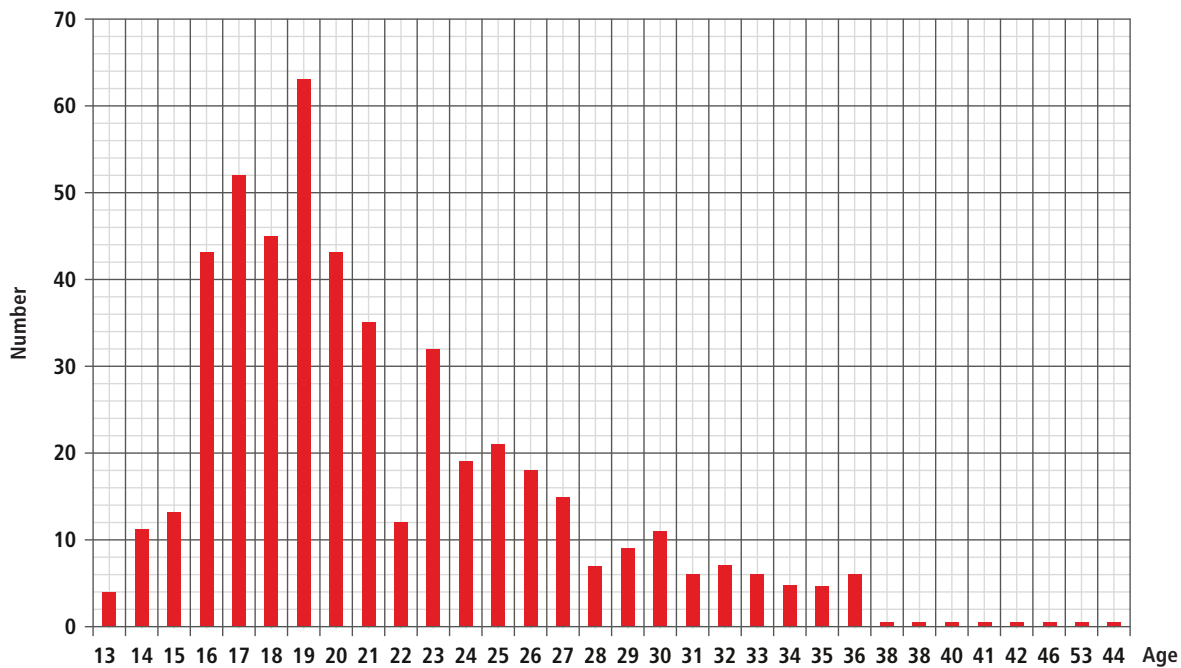
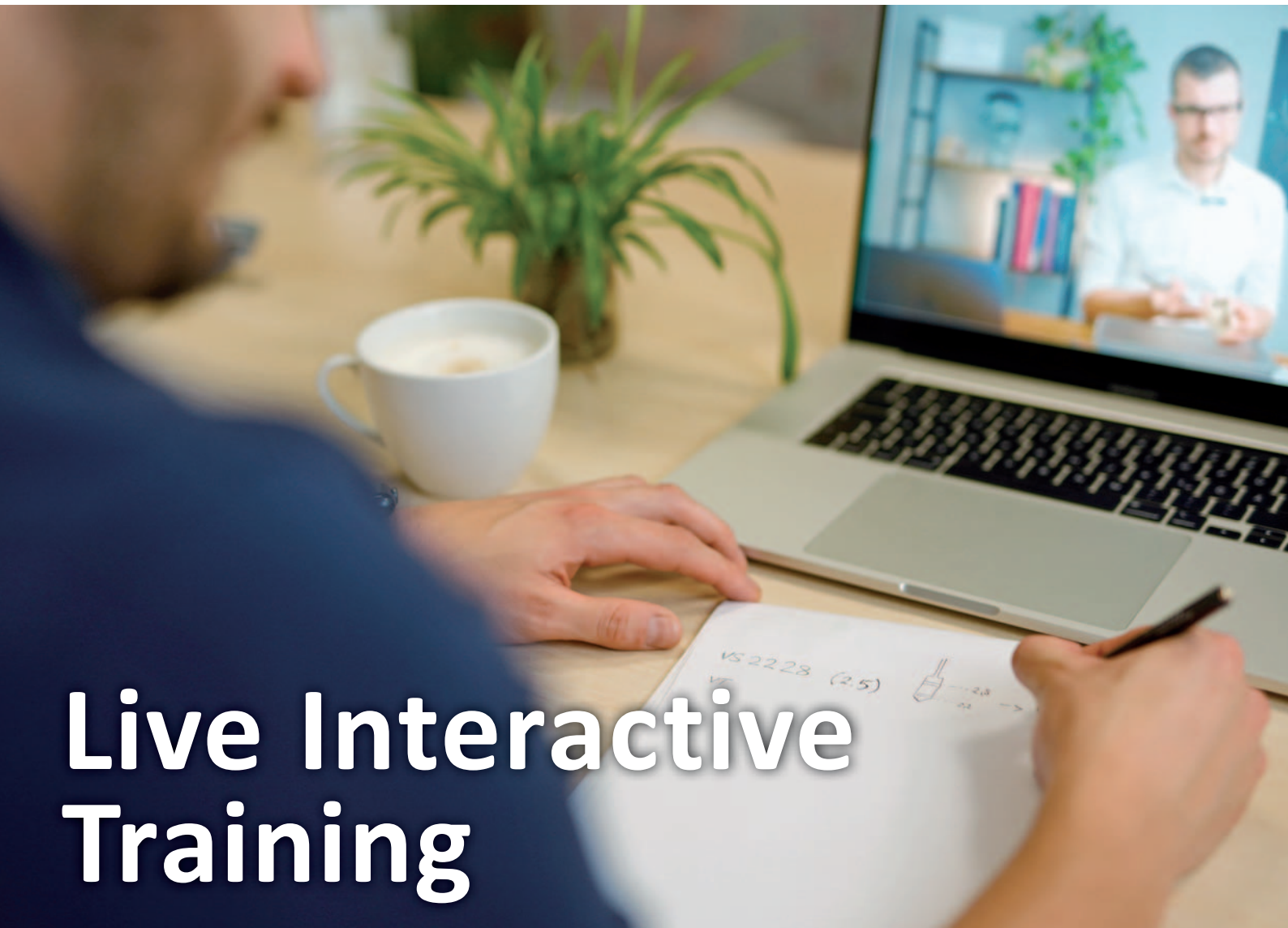

Fig. 7: Number of cases vs age of early dentigerous cysts.



Live Interactive Training

ePractice32 steht für Live Dental Hands-On-Training:

- ✓ Qualitativ hochwertig
- ✓ Schnell und leicht umsetzbar
- ✓ Kostengünstig

Ihre Vorteile: Topreferenten, Hands-On mit der Dentory Box, Präsentation von Behandlungsvideos und klinischen Fällen, Live-Diskussionsrunden, Teilnahme als Participant oder Observer, Punktesammeln nach BLZK.

Jetzt anmelden unter
www.ePractice32.de

 **AMERICAN**
Dental Systems

INNOVATIVE DENTALPRODUKTE

#AmericanDentalSystems



 **QUINTESSENCE PUBLISHING**

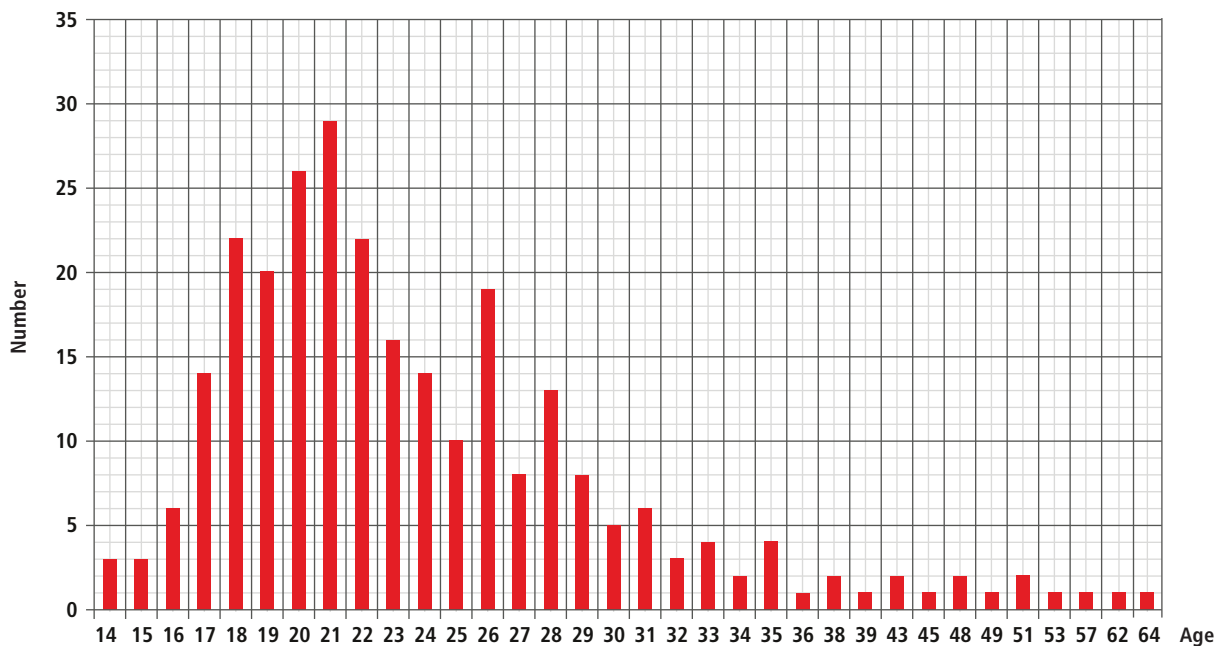


Fig. 9: Number of cases vs age of dentigerous cysts.

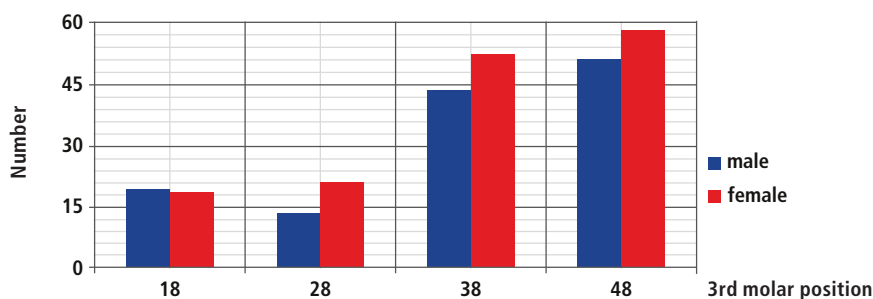


Fig. 10: Number of cases vs position and gender for dentigerous cysts.

2. Early dentigerous cyst

Number vs age of early dentigerous cysts

The age range of patients with EDC was from 13–44 years of age. Most patients were between 16 to 20 years with a peak incidence at 19 years (Fig. 7).

Numbers vs position and gender of cases of early dentigerous cysts

EDC were diagnosed most frequently in females. In both genders the 38 and 48 sites were most frequently affected (Fig. 8).

3. Dentigerous cyst

Number of cases vs age of dentigerous cysts

Age range at presentation of DC was from 14–64 years. The peak of DC occurred at 21 years but significant numbers occurred from 18–22 years. It would be easy to dismiss the spike in incidences at 26 years of age, but this was notable. After 35 years the number of cases of DC was minimal (Fig. 9).

Number vs positions and gender of cases of dentigerous cysts

In both genders the lower third molar sites were almost twice as affected as the upper third molar sites. Female patients were more affected than male patients except in the 18 position where they were about equal (Fig. 10).

4. Paradental cysts

Number vs age of paradental cysts

The age of patients with PC ranged from 13–68 years. The peak number of cases was seen at 19 years with smaller, but significant numbers from 17–22 years. The numbers gradually decreased after this age to 38 years and thereafter the numbers were small (Fig. 11).

Number vs location and gender

PC was seen predominantly in the mandible in both female and male patients (Fig. 12). Female patients had 318 cases in the 38 area and 338 in the 48 area. Male patients had 290 pa-

radental cysts and 248 paradental cysts in the 38 and 48 areas, respectively. In the maxilla, the numbers were notably smaller. Since pericoronitis was more frequently associated with lower third molars, it was proposed that the inflammation might trigger the development of PC in a situation similar to the development of apical cysts, when infection around non-vital teeth was thought to be the factor that was the cause of the proliferation of dormant cell rests of Malassez.¹⁵

Discussion


There are three factors which must be considered in these lesions. These are age, potential complications and radiological appearance. It is clear to see from the graphs that the four common dental cysts peak between 17 and 21 years (Figs. 13 & 14). Most patients start early formation of HFT in the second decade, peak at 17–21 years and then fall rapidly in the third decade. There is progression from HFT peaking at 17 years to be followed by EDC at 19 years. PC also occurred at 19 years, and DC at 21 years. If EDC and DC are combined, then the peak of DC and PC are almost equal at 20 years, whilst HFT is still earlier at 17 years. Fukuta et al. reported the average age of HFT was even younger at 15 years with a range of 10–23 years.⁷



neoss® | ProActive Edge Implantat

Stabilität im Handumdrehen

- Hervorragende Primärstabilität
- Vereinfachtes Bohrprotokoll
- Minimale Aufbereitung



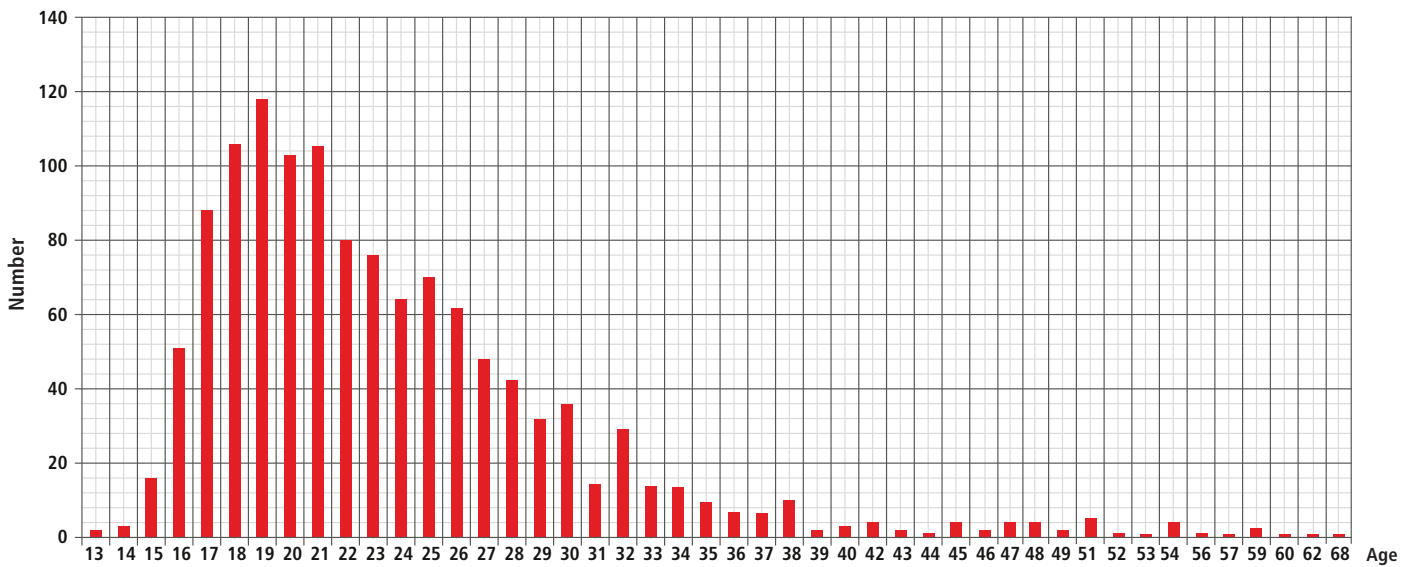


Fig. 11: Number of cases vs age for paradental cysts.

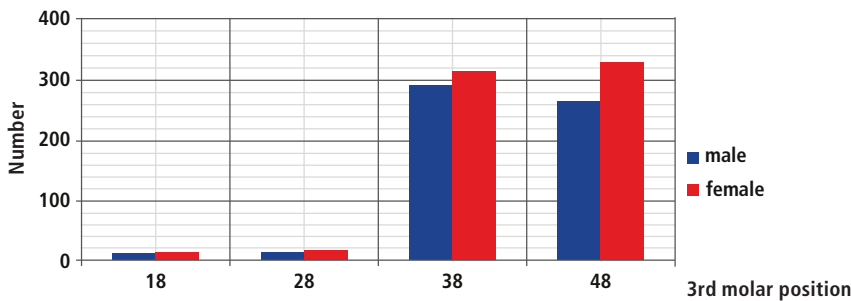


Fig. 12: Number of cases vs position and gender for paradental cysts.

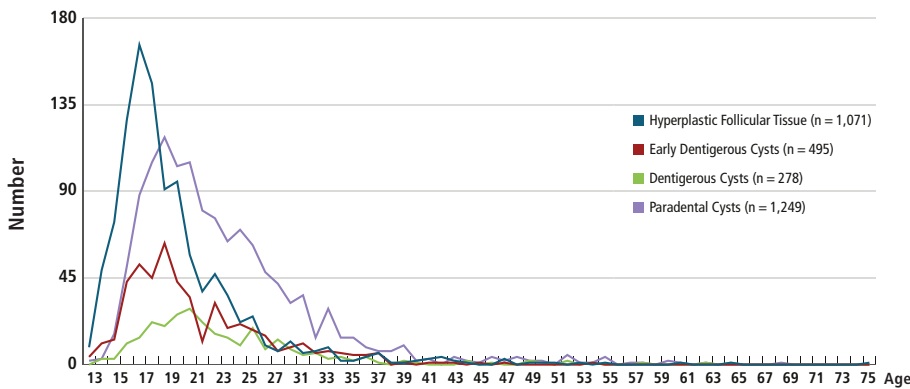


Fig. 13: Number of cases vs age of patients with four pathologies including early dentigerous cysts.

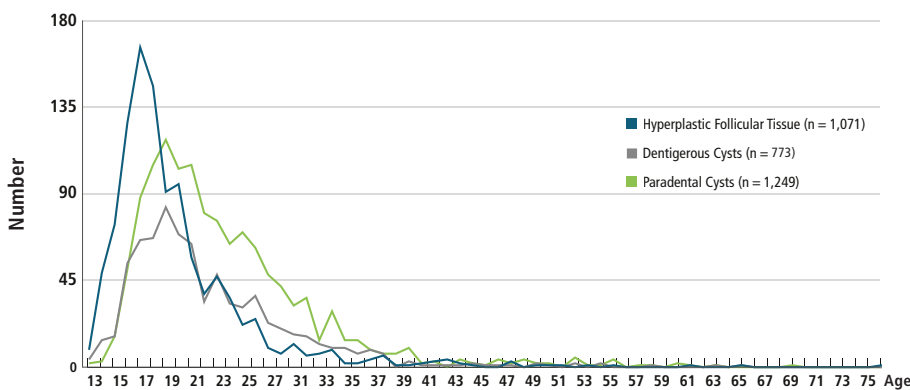


Fig. 14: Number of cases vs age of patients with three pathologies combining early dentigerous cysts and dentigerous cysts.

Possible complications

1. *Hyperplastic follicular tissue*

The importance of differentiating these lesions cannot be overemphasised.

Fukuta et al. found no tumours such as odontogenic fibroma, myxofibroma, or myxomas.⁷ However, Azna-Romeo et al. reported an odontogenic fibroma associated with HFT in a 16-year-old.⁸ Mesgarzadeh et al. found a high number of various pathologies associated with follicular tissue.¹ They found 80% of cases had some sort of pathology, and Berezowski found even higher numbers totalling 96% as shown in Figure 15.⁹

2. *Early dentigerous cysts and dentigerous cysts*

The EDC was differentiated from the DC as a separate entity by Berezowski et al.⁵ Kalburge et al. reported that tumours occurring in dentigerous cysts included ameloblastoma, squamous cell carcinoma, mucoepidermoid carcinoma, adenomatoid odontogenic tumour and odontomas.¹⁰ Berezowski and Phillips reported a primary B cell lymphoma in a dentigerous cyst associated with an impacted third molar.¹¹

3. *Paradental cysts*

The PC was analysed in detail by Berezowski and Cousin.⁶ Complications of this lesion were local and included pain, trismus, swelling and halitosis. However, the histology was very similar to the radicular cyst, and could include dentigerous cyst formation, cemen-

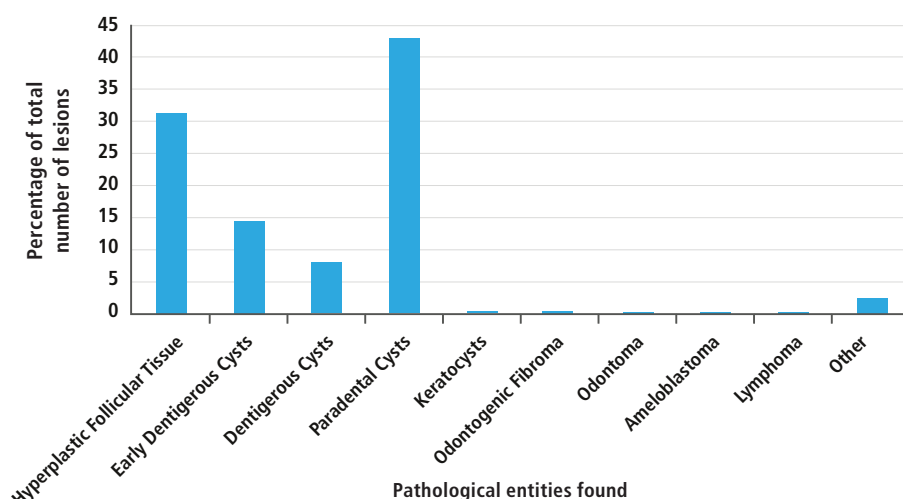


Fig. 15: Percentage of total number of lesions vs different pathologies found.

toma, calcifying epithelial odontogenic tumour, ameloblastomas, odontogenic fibromas and keratocyst formation.

Radiological considerations

Radiographic appearances of radiolucencies around impacted teeth were not sufficiently sensitive to allow definitive diagnosis. Fukuta et al. reported that dentigerous cysts were clinically diagnosed but normal dental follicular tissue was found on histology.⁷ Mesgarzadeh et al. noted that follicles had pathologic change in 80% of cases.¹ They stated categorically that "The overall results from the current study indicate that clinical judgement based solely on radiographic appearance may be quite deceptive and could jeopardise our ultimate goals as dental professionals in providing high quality oral care." Other authors echoed this view and included Shear et al., Saravana et al., Meric et al. and Berezowski.^{9, 12-14} All authors recommended that in addition to imaging, histological investigation of soft tissue was needed to establish an accurate diagnosis.

Conclusions

The study found that there was a definite progression from HFT to EDC and then to DC as well as formation of PC. All the lesions occurred in the second and early third decades. The first lesion to occur was HFT which had its peak incidence at 17 years of age. The other lesions followed this. The EDC had a peak incidence at 19 years of age and

shortly thereafter the PC. This was followed by the DC at the age of 21 years. It was noted that the HFT was found at an early age, but the incidences decreased rapidly after the peak incidence and only few cases were seen by the end of the third decade. The EDC followed shortly afterwards and had a peak incidence by the age of 19 years and thereafter rapidly declined. The DC occurred and rose steadily from the mid second decade, had peak incidence at about 21 years of age then decreased to also reach negligible numbers at the end of the third decade. The PC was the last of these four lesions which had a peak incidence at the same age. It also started in the middle second decade and incidence peaked at about 19 years of age, but the decline was at a slower rate and only finished in the late fourth decade. It was therefore important that the PC was identified at the same time as the other lesions.

The data in this study obtained from the third molar area confirmed the findings by numerous authors that all these lesions tended to occur in the middle of the second and into the third decade with the paradental cysts continuing to be found at a later age. Numerous complications with the formation of both the benign and malignant tumours and cysts were identified. It was important to identify the exact nature of the lesion that had been removed and it was highly recommended that all the specimens concerned be

sent to an oral pathologist for determination of the exact diagnosis. It was impossible to tell whether any tumours were associated with the soft tissue removed until histology was performed. From the literature and data analysed, it was seen that there was no correlation between pathology present and the widths or size of the dental follicle around a symptomatic impacted third molar. Our recommendation is that all symptomatic impacted third molars should be promptly removed at an early age, preferably before 24 years, and be sent for histological examination.

Acknowledgements


The authors would like to thank Dr Horst Luckey for the German translation of the abstract. The authors also wish to express their grateful thanks to Mr Rafael Berezowski for his invaluable computer assistance and to Ms Hayleigh Murray for typing of the manuscript.

References

All references (1–15) can be accessed in the electronic form of this paper and via the following link: qr.oemus.com/9065

Author affiliations

- 1 Brian M. Berezowski: Part time Consultant in Oral & Maxillofacial Surgery in the Department of Maxillofacial & Oral Surgery, University of the Western Cape, and Private Practise, Cape Town, South Africa
- 2 Gary C. Cousin: Consultant, Oral & Maxillofacial Surgeon, Clinical Director and Head of Department, East Lancashire Teaching Hospitals NHS Trust, UK



Kontakt

Dr Brian M. Berezowski PhD

8 Mount Pleasant Road, Newlands
Cape Town, 7700
South Africa
berezbc@mweb.co.za