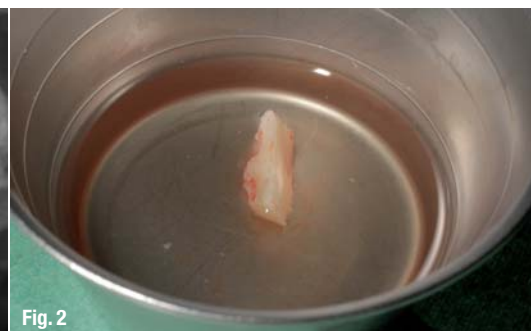
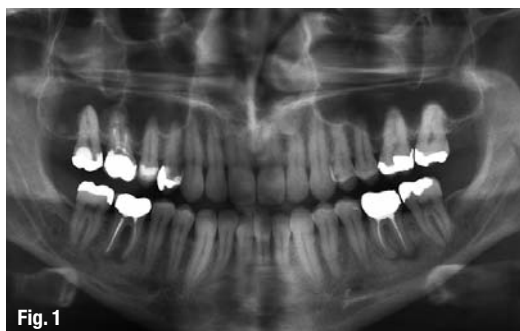
Efficient and ergonomic apical resection using the Kaiserswerth algorithm

Author_ Prof Marcel Wainwright, Germany

Fig. 1_OPG showing active infection at sites 16, 36 and 46.

Fig. 2_Bone block, stored in Ringer's solution.



Thanks to minimally invasive techniques, such as ultrasonic surgery and the availability of reliable restorative materials, the surgical revision and rehabilitation of endodontically treated teeth have a significantly better prognosis than only ten years ago. Apical resection is a challenging surgical procedure—not least because of the limited accessibility of the surgical field. Instrumentation of an apical resection case therefore requires a surgical technique that is as simple as it is safe and ergonomic.

_Case I

A 34-year-old male patient presented at our clinic for the first time. The orthopantomogram (OPG) yielded an accidental finding of apical translucencies at teeth #14, 36 and 46, which had been insufficiently treated endodontically. Clinically, these translucencies were asymptomatic and diagnosed as instances of chronic apical periodontitis or apical osteitis (Fig. 1).

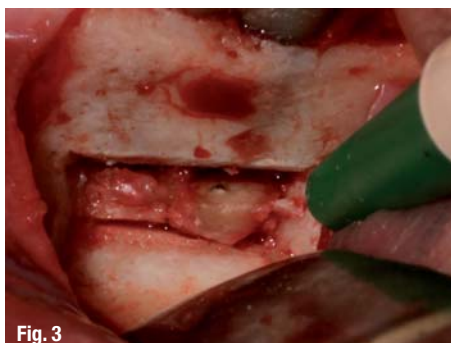
Together with the patient, we planned for an apical resection of tooth #36 in conjunction with a retrograde root-canal filling with subsequent removal of the non-salvageable teeth #16 and 46.

Fig. 3_Surgical site after removing a bone block and performing apical resections on tooth #36.

Fig. 4_The MAP System.

Fig. 5_Autoclavable box with syringe, mixing cup and tips.

This report presents two clinical cases in illustrating a system for applying retrograde endodontic filling materials that has proven a consistently viable option in our clinical practice.



Following extensive consultation and patient education, surgery was performed under local infiltration anaesthesia. With our protocol, block anaesthesia is unnecessary in 98 % of all surgical interventions in the mandible, and dispensing with it minimises the risk of iatrogenic nerve damage.

An incision was performed in the marginal gingiva, with a mesiodistal relief incision, followed by preparation of a full flap for adequate access to the surgical site. Using the Piezotome 2 (Acteon), a buccal bone window of adequate depth was prepared to gain access to the apical region at tooth #36 in order to perform the apical resection. It is helpful for the preparation to provide for undercuts in order to facilitate subsequent removal of the bone block. As no rotary instruments were used and because ultrasonic surgical instruments have a vaso-constrictor effect, the surgical field remained impressively free of bleeding and afforded a clear view of the site. The bone block was stored in Ringer's solution to facilitate subsequent repositioning (Fig. 2). The root apices were then exposed and ultrasonically removed (Fig. 3).

After apical resection, our protocol called for thorough removal of all soft tissue using instruments, followed by complete decontamination of the cyst lumen using a diode laser. Care had to be taken to ensure that the laser tip did not make direct contact with the bone. Retrograde preparation of the root canals was also performed ultrasonically, which only takes a few seconds when using the Piezotome 2.

Following chlorhexidine-digluconate and sodium-hypochlorite rinses, the retro-prepared root canals

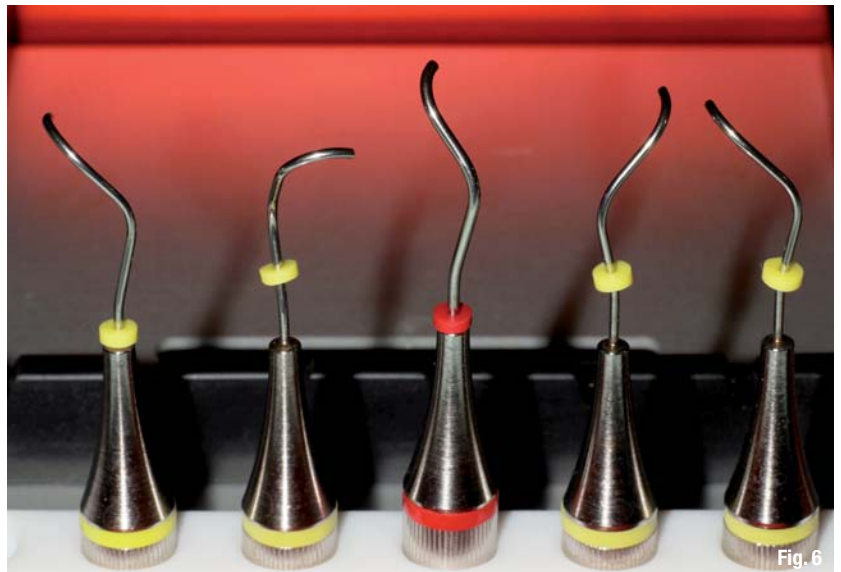


Fig. 6

were dried with paper points. In our clinic, we have had excellent success with the MAP (Micro-Apical Placement) retro system (PDSA), which has been on the market for many years (Fig. 4). The system comes in a sterilisable metal container (Fig. 5). The triple-angled endo tips (Fig. 6) greatly simplify the uptake and application of the material, with the syringe facilitating "injection" (retrograde obturation) of the root canal to a depth of several millimetres. This well-targeted application of the restorative material keeps the surgical field open (Fig. 7).

On application of ProRoot MTA (DENTSPLY Maillefer), the material was allowed to set, the cross-section surface of the resected area was smoothed and polished, the resection lumen was filled with a

Fig. 6 Endo tips with different angulations.

Fig. 7 Applying MTA using the MAP System.

Fig. 8 The bone block is repositioned and secured with bone cement (VitalOs).

Fig. 9 Post-op OPG detail following apical resection of tooth #36.

Fig. 10 Base-line status of tooth #14 following apical resection *alio loco* and reinfection.

Fig. 11 Surgical site 14 following the semilunar incision.

Fig. 12 Retrograde ultrasonic preparation (Piezotome 2).

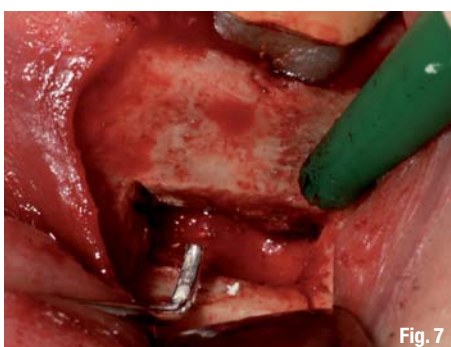

Fig. 7

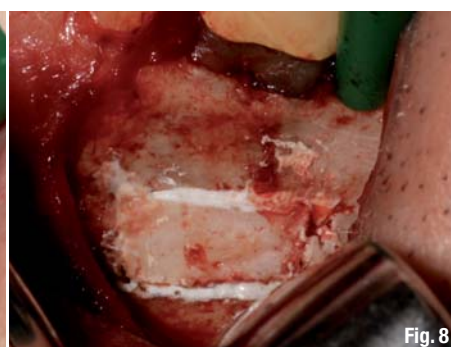

Fig. 8

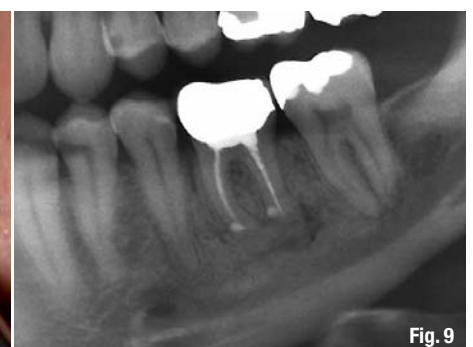

Fig. 9

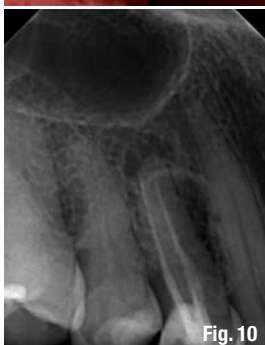

Fig. 10

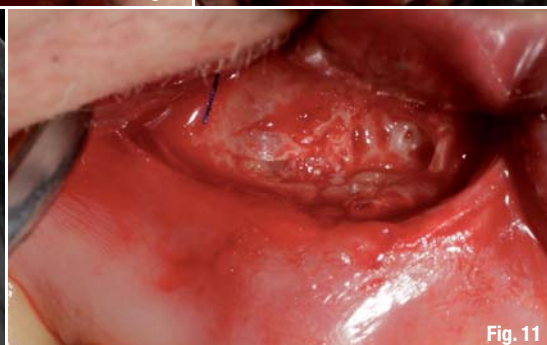

Fig. 11

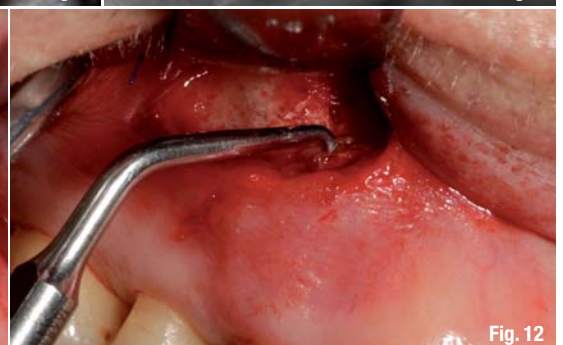

Fig. 12

Fig. 13 _Mixed ProRoot MTA prior to application.

Fig. 14 _Applying the MTA using the MAP System.

Fig. 15 _Resected and retro-filled tooth #14.



Fig. 13

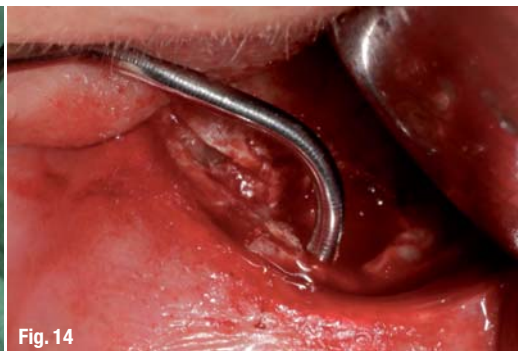

Fig. 14

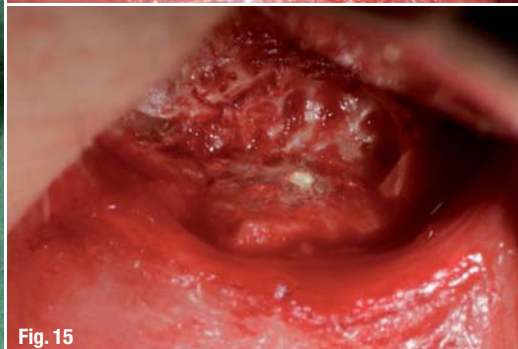

Fig. 15

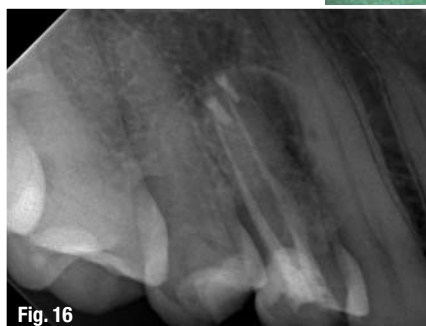

Fig. 16

Fig. 16 _Revision treatment outcome for tooth #14.

quick-hardening bone cement (VitalOs, PDSA), and the bone block was returned to its place (Fig. 8). The post-operative radiograph shows the site following apical resection and retro-grade root filling (Fig. 9).

radiograph (Fig. 16) shows an efficient retrograde filling of both root canals following revision of tooth #14. Owing to a projection artefact, the restorative appeared beside the canals, when it was in fact clinically located exactly within.

_Conclusion

Apical resection is a routine procedure in our clinic. Thanks to the use of ultrasonic surgery, the surgical laser and the MAP System, this procedure is reliable, predictable and simple, and we have preserved the natural teeth of many patients. Being an oral implantologist myself, I do not perceive anything contradictory in looking at these treatment methods; rather, apical resection is a complementary treatment mode and an attempt to preserve teeth over the longer term that would otherwise be considered lost.

Editorial note: A complete list of references is available from the author.

_Case II

A 65-year-old female patient presented with an apical resection on tooth #14 that had been performed *alio loco* five years before. The patient was looking for help because the site had become infected again. She reported pain at tooth #14 on occlusal contact and percussion. A local digital radiograph clearly showed the area of apical resection, the two root-canal fillings, and a cystic peri-apical radiolucency (Fig. 10). Since this was a surgical re-entry case, the same incision technique was used as chosen by the primary treatment provider, i.e. a crescent-shaped incision as described by Pichler (Fig. 11). The procedure was otherwise the same as in Case I. Following retro-grade ultrasonic preparation (Fig. 12), ProRoot MTA was mixed to a working consistency and applied using the MAP System (Figs. 13 & 14). This clean and efficient application mode and controlled handling shortened the surgical procedure and reduced post-operative complaints (Fig. 15). The post-operative

| _contact | roots |
|--|-------|
| Prof Marcel Wainwright Dental Specialists and White Lounge Kaiserswerth Kaiserswerther Markt 25–27 40489 Düsseldorf Germany www.dentalspecialists.de | |



Simplicity is the real innovation



wave•one™

- Only one sterile NiTi instrument per root canal in most cases
- Decreases the global shaping time by up to 40%
- Reciprocating technology respecting the root canal anatomy
- Single use as new standard of care