

Vital amputation of permanent teeth

Author_Dr Robert Teeuwen, Germany

The vital amputation (VA) of deciduous teeth with the goal of maintaining their functionality for a limited period is a widely accepted measure. Vital amputation of permanents, however, is only approved for limited indications. While therapeutic agents such as calcium hydroxide (Ca(OH)₂) and mineral trioxide aggregate (MTA) are recommended for VAs, formaldehyde (CH₂O) containing agents are a controversial subject.

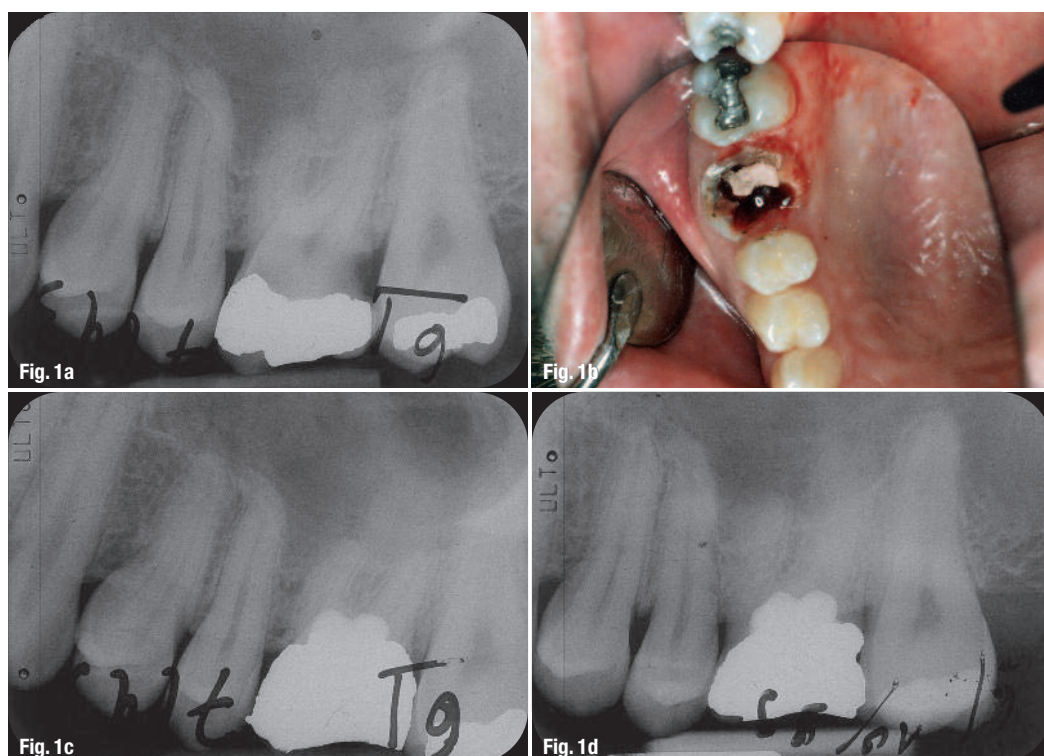
The European Society of Endodontology (ESE) defines pulp amputation as a procedure during which part of the exposed vital pulp tissue is removed with the aim of maintaining vitality and function of the remaining parts of the pulp.¹ ESE recognises the following indications for VAs (i.e. pulpotomy):

1. treatment of deciduous teeth;
2. treatment of permanents with incomplete root growth; and
3. emergency measure.

Indications 2 and 3 include the option of a later definitive root-canal treatment (RCT).

Seidler recommends VA for the accidentally opened pulp of young molars and extremely curved, narrow root canals.² Stern considers difficulty in opening the mouth an indication for VAs as well.³ McDougal *et al.* extend the indication for pulpotomy when there are economic concerns, as some patients are unable or unwilling to bear the expense of a RCT.⁴ According to Swift *et al.*, a successful VA may be

Figs. 1a–d 24-year-old patient, VA 16 (16 July 1993): before VA (a); heavy bleeding from the pulp after N2 VA, 16 July 1993 (b); after VA and amalgam filling (c); X-ray control, 29 September 1999 (d).



expected following traumatic or mechanical carious pulp exposure.⁵ We consider predictable success with the following prerequisites:

- _ non-inflamed pulp;
- _ bacteria-proof closure; and
- _ use of a pulp-compatible capping material.

Seidler states the following regarding the success of VA:²

- _ A higher rate of success is observed in cases of iatrogenic pulp exposure.
- _ Treatment success is reduced in cases of complete root growth.
- _ Molars are more successfully treated than incisors.

For a pulpotomy with Ca(OH)₂, Jensen presupposes that there is no pain existent anamnestically.⁶ Teixeira *et al.* corroborate the significance of pain prior to VA.⁷ In their study of 41 Ca(OH)₂ vitally amputated permanent teeth, anamnesic pain existed in 12 cases. The pulpotomy of these aching teeth led to failure after six to eight months in 50% of the cases ($n = 6$), while all other vitally amputated teeth were considered successfully treated.

McDougal *et al.* report on 73 eugenol pulpotomies on aching permanent molars and premolars.⁴ A clinical success rate of 90% after six months and 78% after 12 months was observed. The teeth, which were free of pain at check-up, were radiologically controlled and it was shown that 49% of the teeth were free of pathological findings after six months and 42% after 12 months.

According to Jensen, pulpotomy is an attempt to stimulate hard tissue healing at the area of amputation.⁶ Fountain and Camp point out that a pulpotomy may result in canal calcification, internal resorption or necrosis of the pulp.⁸ Kozlow and Massler refer to literature that reports the formation of a dentine bridge in rat teeth under non-calcium-containing materials, such as wax, amalgam, acrylic resin and zinc oxide eugenol.⁹ In human teeth, the bridging under Ca(OH)₂ was successful in 43% of the cases and under antibiotics in 23% of the cases. During their own tests on rat teeth, the authors assessed good reparative reactions with complete bridging following pulpotomy with Ca(OH)₂, zinc oxide eugenol, cortisone and silver amalgam.

According to Alacam, various materials are recommended for pulpotomy: Ca(OH)₂, formocresol, glutaraldehyde, ferrous sulphate, zinc oxide eugenol and polycarboxylate cement.¹⁰ Salako *et al.* compared MTA, formocresol, ferrous sulphate and bio-active glass with regard to their pulpotomy compat-

ibility and found MTA to be the ideal pulpotomy agent.¹¹

Agents that contain CH₂O and Ca(OH)₂ are historically established VA agents for deciduous and permanent teeth. Massler *et al.* report a clinical success rate of 92% following VA with Ca(OH)₂.¹² Taking post-operative X-rays into account, the success rate was reduced to 75% after one year and dropped to 65% after two to five years. The authors suggest several reasons for this failure:

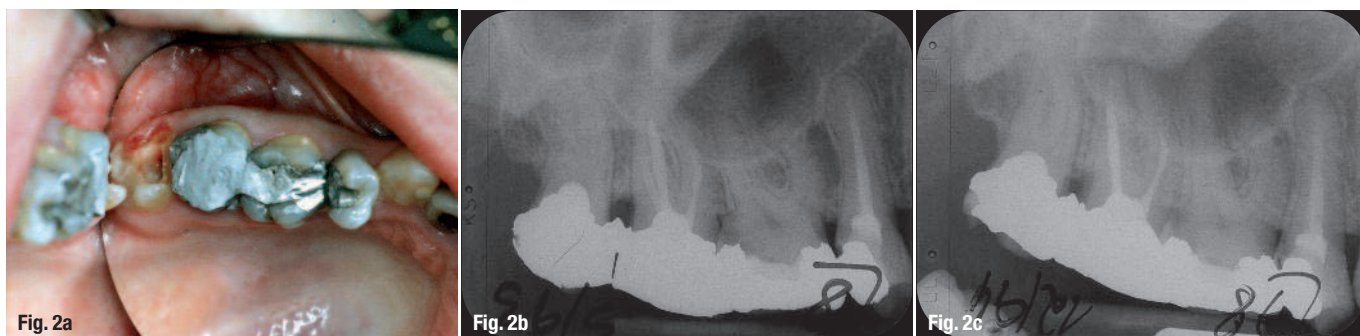
- _ pulp already heavily inflamed initially;
- _ too much pressure applied during application; and
- _ disposal of the blood coagulum via haemostatic agents.

1 st group (31 teeth)	2 nd group (6 teeth)
(no pathological findings radiographically, no anamnesic pain) 17 teeth with complete root growth, 14 teeth with incomplete root growth	3 with periodontal gap enlargement – 2 of them with pain, 3 with apical ostitis, 5 teeth with complete root growth, 1 tooth with incomplete root growth.
Table I	

Mejäre and Cvek performed partial pulpotomies using Ca(OH)₂ on 37 permanent teeth (35 molars, 2 premolars).¹³ The patients were six to 15 years old and their pulpotomy had to be performed at least two years prior to inclusion in the study. Check-ups were performed at an average of 56 months (24 to 140). The teeth were separated into two groups (Table I). Two failures occurred in the first group, in teeth with incomplete root growth (after ten days and 48 months). The other 29 teeth (93.5%) were treated successfully. In the second group, two failures occurred (after 10 and 24 months) in teeth with periodontal gap enlargement (one tooth with complete root growth and the other with incomplete root growth).

Molven states that there were no pathological findings in 1,391 root-filled roots in 51.6% of the cases and in 236 pulpotomized roots in 65% of the cases.¹⁴ Asgary and Eghbal report the successful use of a new VA agent called CEM, a cement mixture enriched with Ca, in 205 pulpotomies on molars.¹⁵ For comparison, 202 molars were extirpated vitally. The root-canal filling (RCF) was performed via lateral condensation with AH Plus (DENTSPLY DeTrey) as sealant. After seven days, 38% of the pulpotomy-treated and 60% of the root-canal-treated patients reported needing analgesics. After six months, 88.94% of the patients underwent a radiological check-up. The pulpotomy patients revealed a significantly higher success rate ($p < 0.001$).

The most frequently used VA agent for deciduous teeth is formocresol, a mix of CH₂O, cresol, glycerine



Figs. 2a–c 30-year-old patient, VA 28 (3 May 1993): prepared cavity (a); after VA and amalgam filling (b); X-ray control, 17 December 1994 (c).

and water. A survey showed that formocresol pulpotomies on deciduous teeth were performed by general dentists in 73% of the cases and by paediatric dentists in 98.2% of the cases.¹⁶ The frequency of use on permanent teeth was lower: 18.9% for general and 55.4% for paediatric dentists.

Frankl considers the advantage of pulpotomy compared with RCT as there being no instrument fractures or perforations during pulpotomy.¹⁹ A possible failure could always be countered with a RCT. He asserts that Ca(OH)₂ pulpotomies can be successful only if teeth are asymptomatic prior to treatment and for accidentally opened pulp and, therefore, bleeding from the pulp.

Powder	Liquid
Zinc oxide 63.0 %	Eugenol 77.0 %
Titanium dioxide 3.6 %	Rose oil 1.8 %
Bismuth subcarbonate 10.0 %	Lavender oil 1.2 %
Bismuth subnitrate 15.0 %	Peanut oil 20.0 %
Paraformaldehyde 7.0 %	
Red lead (lead oxide) 1.4 %	

Table II

Fisch published the results of pulp amputations of 600 teeth, which were performed with the CH₂O-containing preparation Triopaste.¹⁷ Check-ups were done between six months and 18 years after amputation. Examination of the X-ray controls revealed a pathological apex in 9%. Eleven teeth were histologically examined. Hard substance formation was observed in the form of apical foramen closures and apposition at the lateral canal walls, which partially led to obliteration of the canal lumen.

During an accelerated test lasting up to 2.5 months, Overdiek tested N2 as CH₂O-containing VA agent on human teeth. He observed that for several weeks following N2 application there was a possibility of a hard substance barrier forming.¹⁸

Over a period of 12 years, Stern³ carried out 175 N2 pulpotomies under relative isolation on teeth with complete root growth, regardless of possible anamnestic pain. Fifteen per cent of the patients experienced increased pain after treatment, which subsided within 48 hours. Four patients, however, developed pulpitis, which resulted in the extraction of three teeth and conservative RCT of one tooth. Stern was able to track the outcome of 35 vitally amputated teeth over a longer period. During the course of check-ups, two teeth were extracted, one of them due to a fracture. Five years after treatment, Stern observed advancing calcification of the nerve channels.

According to the literature, N2 VA on deciduous teeth renders significantly better results than Ca(OH)₂ pulpotomy. Therefore, Frankl performed N2 pulpotomies on permanent teeth as well.^{19,20} He selected only asymptomatic teeth whose pulp had been accidentally exposed for treatment. The treatment was performed under a rubber dam and thus pulp bleeding did not have any effect. Two hundred and fifty cases were re-examined for up to 13 years. The age of the patients ranged between 22 and 55 years. Failures manifested by pain within 48 hours amounted to 2%. The aim of the following study was to analyse the success and failure rates of N2 VAs on permanent molars, and to compare these rates with vital molar extirpations done within the same period.

Material and method

The study was conducted in my dental practice, which is located in a rural area. Between 1992 and 1998, 795 VAs and 945 vital extirpations (VEs) were performed on molars. After treatment, 85 VA and 93 VE patients did not return to the practice and were thus excluded from the study, leaving 710 VAs and 852 VEs for analysis.

During the treatment period, only N2, which was approved by the district president of Düsseldorf, Germany, on 8 February 1990, was used as therapeutic agent (see Table II for composition).

The root canals were prepared according to the N2 method: relative isolation, no root-canal rinsing and root-canal preparation with reamers only.²¹ For the RCF, N2 mixed to a creamy consistency was applied with a lentulo spiral. The VA cavities were prepared 1 to 2 mm into the canals. N2 mixed to a paste was

FDI World Dental Federation

Leading the World to Optimal Oral Health

2012 Hong Kong FDI Annual World Dental Congress

29 August - 1 September 2012

Join us in Hong Kong, world capital of oral health 2012

for a

- unique global perspective in dentistry and oral health
- face-to-face encounters with your peers worldwide
- range of views from the international experts
- pick of the latest news of groundbreaking dental research
- joint celebration of the 100th FDI Annual World Dental Congress

with featured

top-flight national, regional and international speakers to address the most important challenges and issues in dental practice, enabling dentists and dental teams to transfer cutting edge knowledge into their daily clinical work and management of their practices.

in a

- meeting point of the ancient and the innovative
- world-class focal point of trade, business and technology
- vibrant and bustling city of cultural diversity
- centre of tourism and leisure

and showcasing

the latest technology and equipment development from leading international companies at the world dental exhibition

29 August to 1 September 2012

Hong Kong Convention and Exhibition Centre
Hong Kong, S.A.R. China

Deadline for abstract submission: 30 March 2012
Early Bird registration until 31 May 2012



Leading the world into a new century of oral health

www.fdicongress.org

congress@fdiworldental.org

inserted into the cavity with a filling instrument and lightly pressed with cotton. Minor bleeding was irrelevant. In cases of heavier bleeding, the inserted N2 was removed after a few minutes and then replaced with freshly mixed N2. A synthetic closure of the cavity performed within the same sitting required a lining, which is not necessary for an amalgam closure. X-ray controls were later viewed at double and sevenfold magnification. The apical condition was differentiated as follows: apically without pathological findings, apically uncertain and apically pathological. The root with the worst apical findings was evaluated. This was also applicable for the classification of RCF levels.

Failures without accompanying X-rays were termed Mi1 and failures with accompanying X-rays were termed Mi2. The total failure percentage was not determined by simply adding Mi1 and Mi2, but by adding the number of Mi1s to the number of X-rays taken. The percentage of failures was then determined from this sum. The statistical analysis was performed using SPSS (version 18).

Results

Of the VA patients 47.6% were male and of the VE patients 52.4% were male. The practice owner treated 70.1% ($n = 498$) of the VA patients and 49.1% ($n = 418$) of the VE patients and all the rest were treated by an assistant. The average age of VA patients was 34.6 years and that of VE patients was 30.6 years. The average observation period was 53.8 months (max. 165) for VAs and 49.4 months (max. 169) for VEs. Of the 710 VA cases 504 (71%) and of the 852 VE cases 496 (58.1%) were subject to follow-up X-ray controls.

A total of 61 VA and 77 VE failures were registered and classified as without accompanying X-ray (Mi1) or with accompanying X-ray (Mi2). Fifty-one of the 61 VA

failures were followed-up with X-rays. Not all of the accompanying X-rays of the Mi2 failures revealed a failure.

Two VA failure X-rays and ten VE failure X-rays were wrongly evaluated as negative. Ten VA Mi1 cases were removed because of pain, three of them within a few hours after VA.

In two cases, a granuloma at an extracted root was indicated in the patient files. In two additional cases, the extraction followed after six and 11 days. In 12 of the 16 VE cases, extractions were performed because of pain (one day to 21 months after VE). Patients who visited the practice after pulpotomy made positive a negative reference to anamnestic symptomatic pain 241 times and 157 times, respectively. Subsequently, the failure rate was 10.8% ($n = 26$) in the first case and 7.0% ($n = 11$) in the latter case. The difference was insignificant statistically ($p = 0.114$).

The failure diagnosis after VA was most frequently made for the lower second molar (18.5%) and after VE for the lower first molar (19%). The lower wisdom teeth were conspicuous because the failure rate was only 4.7% after VA, and no failure at all was observed after VE. Not every failure diagnosis led to therapeutic consequences such as extractions.

Altogether, 206 (28.6%) VA and 123 (14.4%) VE teeth were extracted during the follow-up phase (very statistically significant difference; $p = 0.000$). The largest number of extractions, namely 51.9% ($n = 107$) of the VAs and 46.3% ($n = 57$) of the VEs, were performed because the teeth had been destroyed or fractured. The lower wisdom teeth were the most frequently affected in the case of pulpotomy (61.8%; $n = 21$) and the upper second molars in the case of VE (64%; $n = 16$).

Table III Summarised VE results.

Tooth	Σ	I		II		III		Failure IV			V	VI	
		Recall		Extraction		X-ray post VE		IV a Mi 1	IV b Mi 2		IV c Mi 3	X-ray + Mi 1	Fail. Σ
		n	%	n	%	n	%	n	n	%	n	n	%
16/26	269	241	89.6	42	17.4	142	58.9	3	22	15.5	25	145	17.2
17/27	168	152	90.5	25	16.4	89	58.6	4	7	7.9	11	93	11.8
18/28	5	5	100	1	20.0	2	40.0	-	-	-	-	2	-
36/46	274	249	90.9	24	9.6	148	59.4	4	25	16.9	29	152	19.0
37/47	201	177	88.1	25	14.1	97	54.8	3	9	9.3	12	100	12.0
38/48	28	28	100	6	21.4	18	64.3	-	-	-	-	18	0,0
	945	852	90.2	123	14.4	496	58.2	14	63	12.7	77	510	15.1

Tooth	Σ	I		II		III		Failure IV			V	VI	
		Recall		Extraction		X-ray post VA		IV a Mi 1	IV b Mi 2	IV c Mi 3	X-ray + Mi 1	Fail. Σ	
		n	%	n	%	n	%	n	n	%	n	%	
16/26	109	98	89.9	23	23.5	73	74.5	1	7	9.6	8	74	10.8
17/27	202	179	88.6	45	25.1	127	70.9	3	9	7.1	12	130	9.2
18/28	112	100	89.3	41	41.0	72	72.0	2	9	12.5	11	74	14.9
36/46	118	111	93.2	28	27.0	78	70.3	2	8	10.3	10	80	12.5
37/47	140	123	87.6	35	37.8	90	73.2	2	15	16.7	17	92	18.5
38/48	114	99	86.8	34	34.3	64	64.6	-	3	4.7	3	64	4.7
	795	710	89.3	206	28.6	504	71.0	10	51	10.1	61	514	11.9

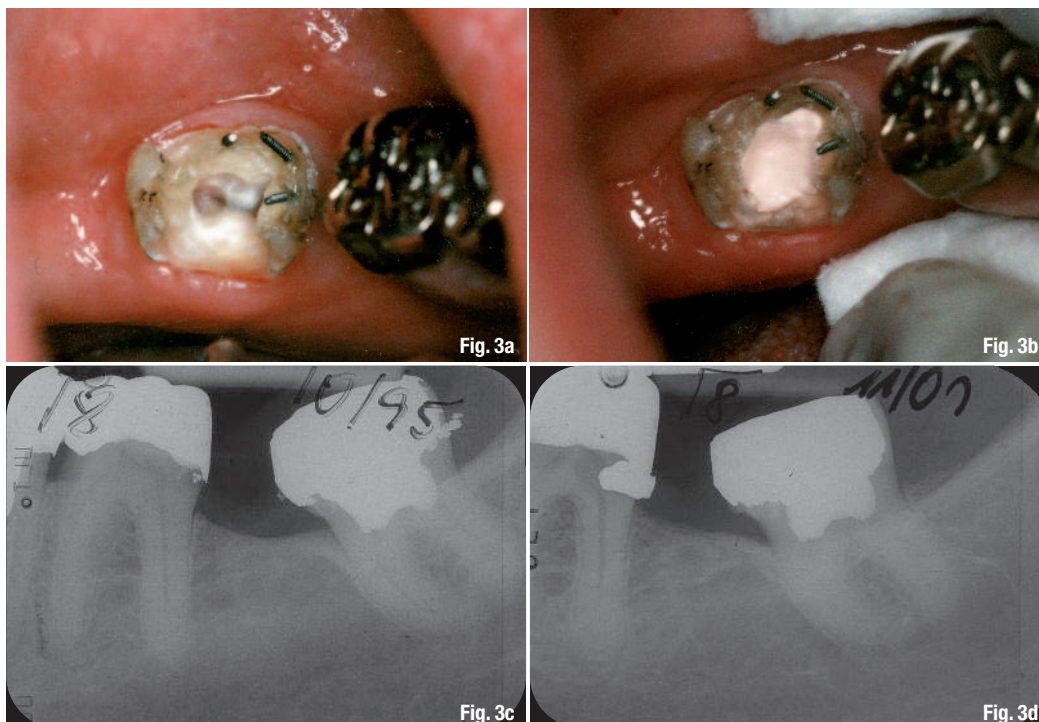
A failure was decisive for the removal of 23.3% ($n = 48$) of the extracted VA teeth and 36.6% ($n = 45$) of the extracted VE teeth. Most frequently extracted due to failure were the vitally amputated upper second molars (34.8%; $n = 8$), and the vitally extirpated lower second molars (54.2%; $n = 13$). The lower wisdom teeth (34 extractions ($n = 3$; 8.8%) in the pulpotomy group) and the upper second molars (42 extractions ($n = 13$; 31%) in the VE group) were extracted least often. The VE and VA results are shown in Tables III and IV.

Furthermore, the question of whether the RCF level following VE had any significance with regard to the failure rate was pursued. The RCF levels were

divided into three levels. The total failures of these three groups were calculated as described under material and method (Table V).

Without considering the indication range, anamnestic symptoms, tooth position and RCF level, the total failure rate was 11.9% for VAs and 15% for VEs (statistically insignificant; $p = 0.644$). The VE failure rate of the RCF level of -4, -3 corresponded exactly to the VA failure rate of 11.9%. There was no statistically significant difference ($p = 0.226$) in failure between RCF levels -4, -3 and -2, -1, 0. The RCF level of -5 showed significantly more failures compared with the RCF levels of -4, -3 ($p = 0.020$) and -2, -1, 0 ($p = 0.002$).

Table IV_Summarised VA results.



Figs. 3a-d_53-year-old patient, VA 38 (31 October 1995): prepared cavity (a); N2 applied (b); after VA and amalgam filling (c); X-ray control after six years (d).

Discussion

A direct comparison between VAs and VEs, especially as regards incomplete root fillings, was only possible within limits, as the number of VAs consisted mainly of a negative selection, which otherwise would have been entrusted to the pliers. The twice as high extraction frequency of vitally amputated teeth compared with that of vitally extirpated teeth (28.6% versus 14.4%) may be attributed to the adverse baseline situation. Fractured or destroyed teeth were the reason for extraction for 51.9% of all extractions in the case of VAs. For VEs, this rate was 46.3%. However, the extraction reason "endodontic failure" was attributed in 36.6% of the extractions to the VA teeth and in 23.3% of the VE teeth.

RCF level	X-ray + Mi1	Failures	
	n	n	%
-5	195	43	22,1
-4, -3	194	23	11,9
-2, -1, 0	124	11	8,9

Table V VE failures of molars according to RCF levels.

Anamnestic pain causing an increased frequency of failure in VA cases, which was also observed by Teixeira *et al.* following Ca(OH)₂ treatment,⁷ was statistically insignificant. Stern³ und Frankl^{19,20} also point out increased pain following VA. This was observable during our study as well. Nevertheless, the total failure rate for vitally amputated teeth was lower (11.9%) than the average rate of 15.1% for vitally extirpated teeth.

The evaluation of pulpotomy cases only with accompanying X-rays revealed a failure rate of 10.1%, which is comparable to the 9% Fisch encountered with the Triopaste.¹⁷ Frankl reports only 2% of failures after N2 VA, although he had done stringent case selection.^{19,20} In contrast, the radiological-pathological findings concerning eugenol pulpotomies in pain-free teeth amounted to 58% after 12 months.⁴ Fifty per cent of all Ca(OH)₂ pulpotomies of aching teeth resulted in failure after six to eight months.⁷ Massler *et al.* observed a total failure of 65%, two to five years after Ca(OH)₂ VAs.¹²

The correlation between failure and RCF level following VEs was investigated. Adequately filled teeth (-2, -1 *ad apicem*) showed a failure rate of 8.9%, heavily underfilled teeth a rate of 22.1%. Hence, the conclusion may be drawn that the success rate of VAs corresponds to the one of properly performed root fillings following VEs, and is far superior to a noticeably underfilled root filling. Molven attributes a more favourable peri-apical situation to pulpotomized than to root-filled roots.¹⁴

In their study, Asgary and Eghbal do not explain the technical performance of the RCF.¹⁵ However, they establish that pulpotomies are statistically significantly superior to RCTs of vital molars, although radiological failure is neither defined nor numerically expressed. Additionally, the follow-up time of six months is considered very brief.

Summary

A comparison of 710 N2 VAs and 852 N2 root-filled molars after VE was done. The average follow-up period was 53.8 months for VAs and 49.4 for VEs. The total failure rate (radiological and clinical) was 11.9% following VAs, which is equivalent to that of VEs with slight underfilling (RCF level -4, -3). Adequately filled root canals led to fewer failures (8.9%) than VAs. With a failure rate of approximately 19%, the lower first VE- and second VA-molars were most frequently affected.

During the follow-up period, 28.6% of all VA and 14.4% of VE teeth were extracted. Fractured or destroyed teeth were the reason for extraction in 51.9% of all VA and in 46.3% of all VE cases. The extraction reason "endodontic failure" occurred less frequently after VA (23.3%) than VE (36.6%).

For the practice

The patient should be advised of possible pain following the subsiding anaesthetic effect. Analgesics are indicated after VA. An N2 VA is more successful than an insufficient root filling after VE. Vital amputation is indicated in cases of almost inaccessible canal systems, open apical foramina and for economic reasons.

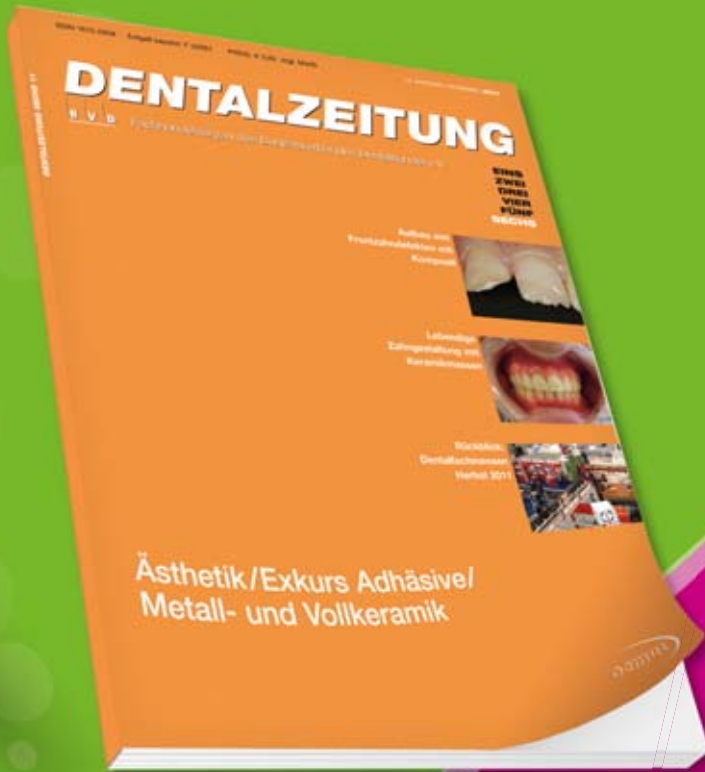Instead of an extraction or the impossibility of a VE with adequate root filling, it is possible to consider—besides a full pulpotomy, which was the subject of the present study—a partial pulpotomy on:

- _ upper molars: VA of the buccal canals, filling of the palatal root;
- _ lower molars: VA of the mesial canals, filling of the distal root; and
- _ deep crown margin caries, partial removal of the pulp cavum.

Editorial note: A complete list of references is available from the publisher.

_contact	roots
	<p>Dr Robert Teeuwen Berliner Ring 100 52511 Geilenkirchen Germany</p> <p>robteeuwen@t-online.de</p>

INNOVATION + INFORMATION



Fax: +49 341 48474-290

You can also subscribe via www.oemus.com/abo

www.oemus.com

I would like to subscribe to **Dentalzeitung** (6 issues per year) for € 34 including shipping and VAT for German customers, € 36 including shipping and VAT for customers outside Germany, unless a written cancellation is sent within 14 days of the receipt of the trial subscription. The subscription will be renewed automatically every year until a written cancellation is sent to OEMUS MEDIA AG, Holbeinstr. 29, 04229 Leipzig, Germany, six weeks prior to the renewal date.

I would like to subscribe to **ZWP** (10 issues per year) for € 70 including shipping and VAT for German customers, € 72 including shipping and VAT for customers outside Germany, unless a written cancellation is sent within 14 days of the receipt of the trial subscription. The subscription will be renewed automatically every year until a written cancellation is sent to OEMUS MEDIA AG, Holbeinstr. 29, 04229 Leipzig, Germany, six weeks prior to the renewal date.

Last Name, First Name

Street

ZIP/City/County

Fon, fax

E-mail

Notice of revocation: I am able to revoke the subscription within 14 days after my order by sending a written cancellation to OEMUS MEDIA AG, Holbeinstr. 29, 04229 Leipzig, Germany.

Signature

Signature