Tooth replacement with one-piece zirconia implants

Laying the foundation for soft-tissue aesthetics

Dr Paul S. Petrungaro, USA

The use of dental implants to replace the failing natural tooth system has become a popular treatment planning choice over the last several decades. Modifications to the conventional multistep protocols initially introduced by Per-Ingvar Brånemark have allowed for treatment times to be shortened and for patients to receive immediate aesthetic provisional restorations in only one surgical appointment. Positive long-term success rates have been demonstrated in the literature. However, owing to the rising incidence of peri-implant mucositis and peri-implantitis being observed in clinical practice and reported on in the literature, titanium as a base material, along with various surface alterations, has undergone scrutiny. Zirconia as an alternative material for the implant–abutment complex has shown to be safe and successful. This article will demonstrate the immediate restoration procedure of one-piece zirconia tapered implants in the maxillary anterior and maxillary premolar regions, and outline the benefits of zirconia as an alternative to titanium in the dental implant discipline.

The use of dental implants to replace the natural tooth system, from single-tooth replacement to full-arch reconstruction, has become commonplace in the contemporary reconstructive and surgical practice.[1–4] The conventional, multistep approach to implant placement and restoration has been a staple procedure for over 40 years and continues to enjoy high success rates.[1,2] However, based on advancements in implant design and surgical and restorative protocols, treatment times have been observed to be shortened, procedures have become less invasive, and single-stage, immediate provisionalisation procedures have become more commonplace.[3–10] High success rates have been reported in the literature regarding these procedures. Additionally, patients can enjoy immediate, stable, functional dentition at the time of implant placement.[3–10]

Numerous variables can affect the success rates of dental implants in the short and long term.[11–13] The amount of attached gingival tissue, the depth of implant placement in relation to another implant and/or adjacent teeth, the implant surface design and alterations, and the volume and quality of bone are all important aspects that can contribute positively or adversely to the

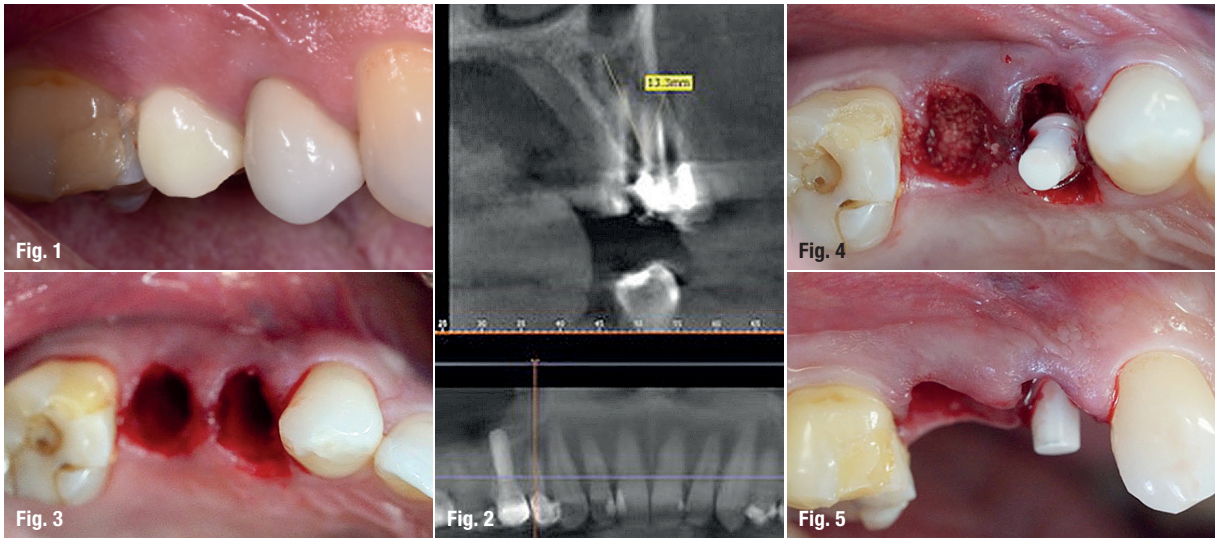

Case 1—Fig. 1: Pre-op clinical view. **Fig. 2:** CT scan serial view of maxillary right first premolar. **Fig. 3:** Implant and tooth removal and debridement. **Fig. 4:** Z-Systems one-piece tapered screw implant placement and Osseolive (curasan) graft complex. **Fig. 5:** Facial view after minimally invasive implant and graft placement.

short- and long-term success of conventional titanium implants.[14–17] In recent years, the growing prevalence of peri-implant mucositis and peri-implantitis has been reported on in the dental literature and become more of a problem in surgical and reconstructive practices.[18–20] The peri-implant mucositis and peri-implantitis disease state is generally caused by bacterial plaque, which, as seen with natural teeth, can accumulate on implant surfaces.[21,22] Additionally, the following factors can all contribute to peri-implantitis disease: lack of proper hygiene;[23,24] lack of attached gingival tissue around dental implants;[25] tobacco use and its effects;[26] and genetic factors and their role in the development of peri-implantitis (similar to periodontitis around natural teeth) have all been shown to lead to inflammation and bone loss around titanium dental implants.[27,28]

Surgical techniques, complications in wound healing and inappropriate placement of dental implants, regarding both depth of placement and spatial arrangement, can also lead to premature bone loss and initiation of peri-implant disease.[29] Additionally, corrosion of the base metal of a titanium implant can cause the destruction of osseous tissue, resulting in peri-implantitis.[30–33] In the aesthetic zone, complications associated with the lack of attached gingival tissue around the final implant-supported restoration can also lead to premature development of peri-implantitis as previously outlined.[34–37] More significantly, however, compromised aesthetics both in natural soft-tissue emergence profiles and in the appearance of dark colours from the implant–abutment complex cause patient dissatisfaction.[38]

Zirconia as an alternative implantable material has been well documented in the dental literature.[34–36] Its use prevents the discoloration of the peri-implant gingival tissue, which in many situations is associated with titanium implants. Additionally, zirconia provides a high level of biocompatibility and fracture toughness.[34–36] Zirconia dental implants have been shown to cause minimal inflammation in the peri-implant area owing to a decrease in the affinity for the formation of a biofilm and reduction in associated plaque levels compared with titanium.[37–39] This results in a reduction in bone loss and inflammatory response in situations where titanium would result in an increase in these destructive situations, leading to increases in peri-implantitis and premature implant loss.[37–39] Blaschke and Volz demonstrated that the soft-tissue response around zirconia implants is superior to that around titanium.[40] Petrungaro demonstrated that peri-implant bone replacement procedures in minimally invasive protocols, with the incorporation of autologous platelet-rich fibrin and Osseolive, a bioactive bone grafting material, have produced similar bone replacement results to the same procedures around titanium implants, in both one-stage immediate restoration protocols.[41]

AD

ARGON
MEDICAL DEVICES & DENTAL IMPLANTS

THE METAL-FREE IMPLANT SOLUTION

Z3Pro®

KONUS DENTAL IMPLANTS

PERI PROTECT® DESIGN

- Two- and one-piece
- Subcrestal positioning
- Steep long cone with 1.0 ° angle for the implant abutment connection
- Conical, anatomical optimized implant design
- Maximum primary stability
- Metal-free implant Z3Pro® zirconium oxides
- Three-stage thread design

Rev. 1.0.2019

ARGON Medical
D-55411 Bingen am Rhein
Fon: +49 (0) 67 21/30 96-0

QUALITY & DESIGN
MADE IN GERMANY

info@argon-medical.com • www.argon-medical.com

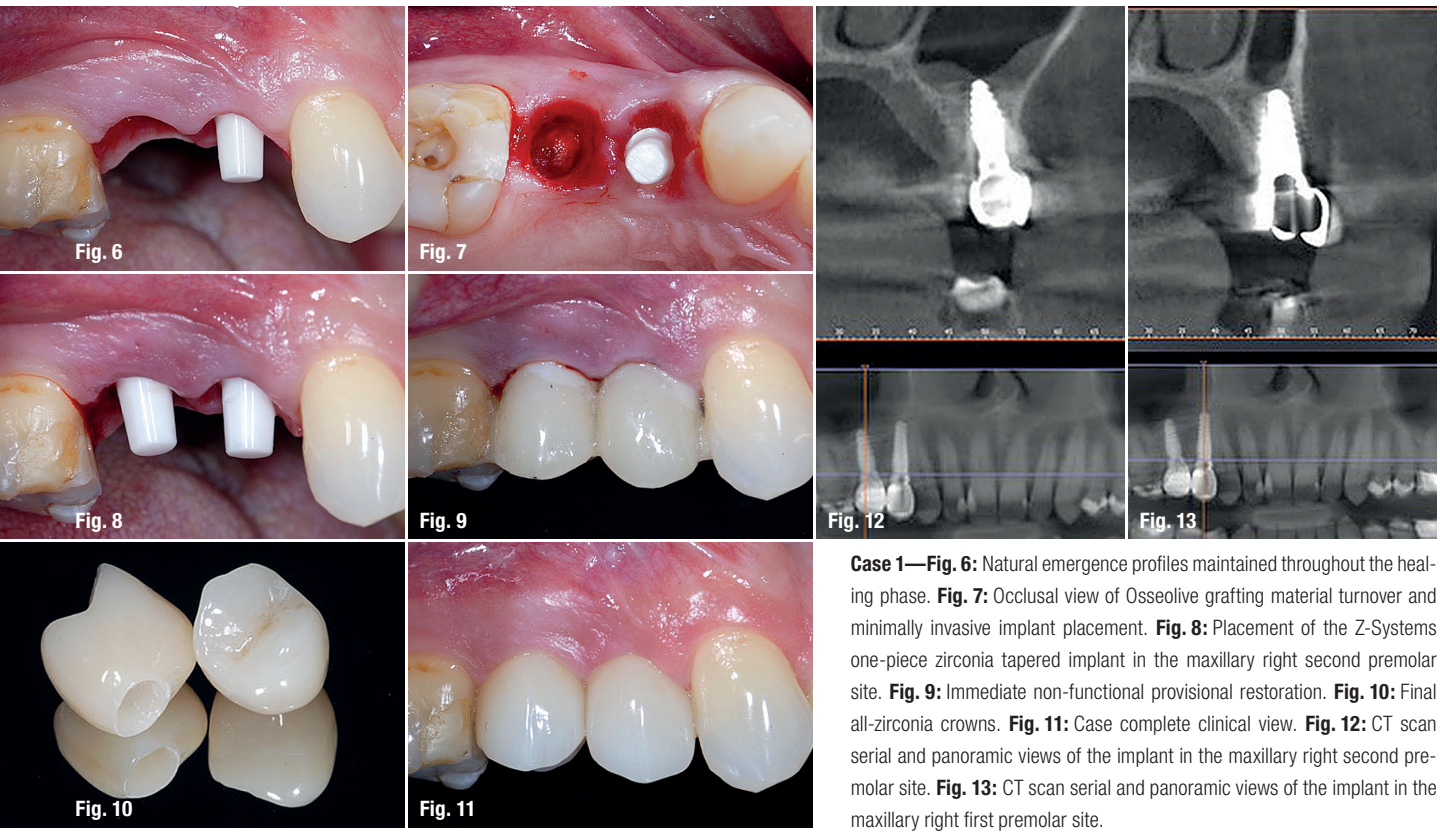

Case 1—Fig. 6: Natural emergence profiles maintained throughout the healing phase. **Fig. 7:** Occlusal view of Osseolive grafting material turnover and minimally invasive implant placement. **Fig. 8:** Placement of the Z-Systems one-piece zirconia tapered implant in the maxillary right second premolar site. **Fig. 9:** Immediate non-functional provisional restoration. **Fig. 10:** Final all-zirconia crowns. **Fig. 11:** Case complete clinical view. **Fig. 12:** CT scan serial and panoramic views of the implant in the maxillary right second premolar site. **Fig. 13:** CT scan serial and panoramic views of the implant in the maxillary right first premolar site.

The aesthetic zone offers multiple challenges. One challenge is the use of one-piece implants, as the positioning, trajectory and depth of placement can all limit the proportions of the final restoration. In a one-piece titanium implant, the ability to prepare the abutment can help to lessen critical placement errors in the aforementioned parameters; however, preparation on the implant itself is not recommended and can lead to aesthetic failure and premature development of peri-implant mucositis and or peri-implantitis.

One-piece zirconia implants offer a more flexible option for the aesthetic zone.[41] Their positioning closer to the critical buccal soft-tissue emergence profile avoids a dark hue at the soft-tissue margin, and depending on the one-piece zirconia implant selected, preparation on the abutment and collar and body of the implant itself allows for a level of flexibility in order to manage any placement complications regarding depth, spatial arrangement and trajectory. This article will present two cases in order to demonstrate the use of the Z-Systems one-piece zirconia tapered screw design in an immediate tooth replacement and provisionalisation procedure in the aesthetic zone.

Case 1

A 48-year-old non-smoking male patient presented for replacement of a failing zirconia implant, placed one year before, in the maxillary right second premolar position and of an endodontically compromised first premolar (Fig. 1). Figure 2 shows the serial view of the failing first premolar and the panoramic view of the zirconia implant in the second premolar region and of the first premolar. After administration of an appropriate local anaesthetic, both the natural tooth and implant were removed atraumatically and the sites debrided of any granulation tissue and remaining periodontal ligament (Fig. 3).

After site evaluation, the decision was made to graft the second premolar site, along with an internal socket and crestal repair, and place a one-piece tapered screw implant of 4 mm in diameter and 12 mm in length (Z-Systems ceramic implant system) in the first premolar site. At placement, an initial torque of 45 Ncm was achieved (Fig. 4). The second premolar site was grafted with 1 cc of Osseolive grafting material (curasan), combined with autologous platelet-rich fibrin (Fig. 4). Figure 5 shows the facial view post-implant placement and grafting of the treatment area. Provisionalisation was then performed using the first premolar implant as an abutment for a cantilevering ovate pontic in the second premolar region to sculpt the soft-tissue contours. The provisional was cemented with a strong temporary cement, with additional bonding to the first molar and canine for added support. The site was allowed to heal for 4.5 months.

WE HAVE LEARNED TO THINK IN CERAMICS

USER COURSE (2 DAYS)

Ceramic Implants and Biological Dentistry – „The Swiss Biohealth Concept" with Dr. Ulrich Volz

CERAMICS ARE EASIER – BUT DIFFERENT

Today we are able to place more than 85% of SDS implants immediately (immediate implantation and immediate restoration with long-term temporary restorations). This requires a special protocol and the corresponding training. In this 2-day course, we will provide you the perfect introduction to ceramic implantology and explain the main differences from titanium implants.

Benefit from the experience of more than 20,000 personally placed ceramic implants from the SDS creator and head of the SWISS BIOHEALTH CLINIC, Dr. med. Ulrich Volz.

DATES:

14./15.	**Jun**	**2019**
26./27.	**Jul**	**2019**
27./28.	**Sep**	**2019**
18./19.	**Oct**	**2019**
15./16.	**Nov**	**2019**
13./14.	**Dec**	**2019**

Complete course program and registration at:
www.swiss-biohealth-education.com

SWISS BIOHEALTH® EDUCATION

SDS SWISS DENTAL SOLUTIONS®
swissdentalsolutions.com

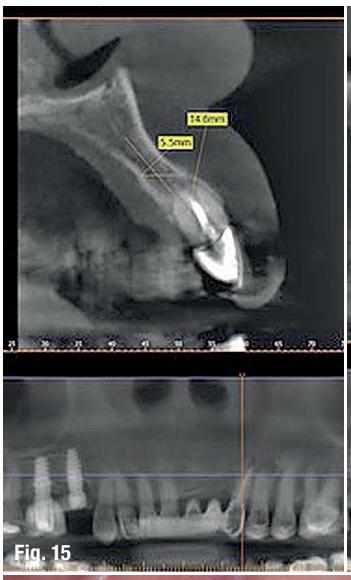

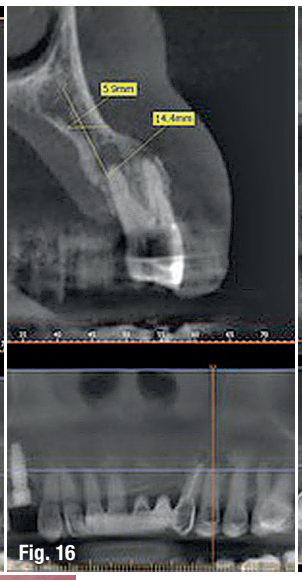

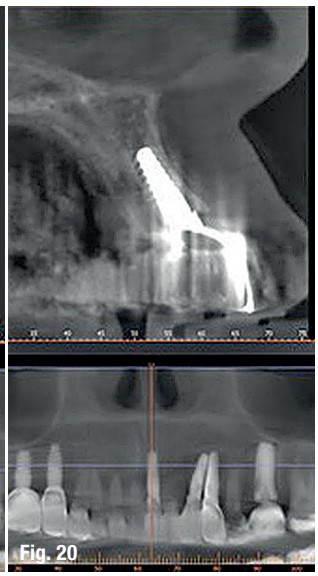

Case 2—Fig. 14: Pre-op clinical view. **Fig. 15:** Pre-op CT scan serial and panoramic views of the maxillary left canine. **Fig. 16:** Pre-op CT scan serial and panoramic views of the maxillary left premolar. **Fig. 17:** Creating sculpted soft-tissue contours prior to minimally invasive implant placement. **Fig. 18:** Z-Systems one-piece zirconia tapered screw implants placed according to minimally invasive protocols. **Fig. 19:** Case complete clinical view. **Fig. 20:** Case complete CT scan serial view of the implant in the maxillary left central incisor site and a panoramic view of the maxillary restorations.

After the prescribed healing phase, the patient was again scheduled for surgery. After administration of an appropriate local anaesthetic, the provisional restoration was removed. Figure 6 shows the natural soft-tissue emergence profiles created by the provisional restoration. Note the quality and quantity of attached gingival tissue maintained and sculpted.

Figure 7 shows the one-piece zirconia implant placed in the second premolar site. Note the remodelling of the Osseolive graft complex at the crest of the ridge. A one-piece zirconia tapered implant of 4 mm in diameter and 12 mm in length (Z-Systems ceramic implant system) was then placed in the second premolar site (Fig. 8), achieving an initial torque of 40 Ncm. A new, non-functional, provisional was then fabricated and cemented with a strong temporary cement, again with additional bonding to the adjacent natural teeth for support throughout the healing phase (Fig. 9). After four months of a prescribed, uneventful healing phase, abutment level impressions were taken and the final all-zirconia restorations fabricated (Fig. 10). Figure 11 shows the one-month post-seating clinical view. Note the natural soft-tissue contours maintained throughout the entire treatment process and in the final aesthetic result. Figures 12 and 13 show the case complete CT scan serial and panoramic views.

Case 2

A 39-year-old non-smoking female patient presented for treatment of a failing bridge in the maxillary anterior region (Fig. 14). Figures 15 and 16 demonstrate the CT scan serial and panoramic views of the maxillary left canine and premolar. Note the thin buccal–palatal dimensions apical to the infected and failing dentition. The patient also had titanium implants in the maxillary right posterior region, and had already undergone treatment for peri-implantitis and refused additional titanium implant placement. After administration of an appropriate local anaesthetic, the anterior bridge was sectioned between the central incisors, and the affected teeth removed and sites debrided. Additionally, a sculpted site at the left central incisor, mimicking an extraction site, was created for minimally invasive implant placement in the left central incisor, canine and first premolar sites (Fig. 17). After site preparation according to minimally invasive protocols, three one-piece zirconia tapered screw implants of 4 mm in diameter and 12 mm in length (Z-Systems ceramic implant system) were placed, achieving an initial torque of 45 Ncm each (Fig. 18).

After the prescribed healing phase of five months post-initial implant placement, abutment level impressions were taken and the final all-zirconia restorations fabri-

cated. Figure 19 shows the clinical view of the final restorations at three months post-seating. Note the natural soft-tissue contours and superior gingival health demonstrated around the final restorations and surrounding peri-implant tissue. Figure 20 shows the serial view of the one-piece tapered screw implant in the left central incisor site, along with a panoramic view of the maxillary restorations.

Discussion

Over the past several decades, dental implant designs have been updated and enhanced to provide for more rapid integration rates, bone level maintenance and enhancement of implant aesthetics. Additionally, as a result of complications observed with titanium as a base metal for implants, zirconia implants were developed and introduced. They offer superior soft-tissue aesthetics to that of titanium in compromised soft-tissue circumstances. Additionally, they have been shown to have less of an affinity for biofilm adhesion and formation, a very important characteristic, as the incidence of peri-implant mucositis and peri-implantitis continues to rise in the clinical practice of implant dentistry in both short- and long-term maintenance programmes. The use of a one-piece zirconia implant, especially one that can be adjusted and prepared to fit a particular situation after placement, offers an additional benefit, as the elimination of the micro-gap, often present with two-piece implant designs, is eliminated. The author recommends that additional studies be performed to further validate the effectiveness of zirconia as an alternative to titanium as an implantable device in the oral cavity and to additionally validate the procedures demonstrated in this clinical article.

Literature

contact

Dr Paul S. Petrungaro
330 W Frontage Rd Ste 2b
Northfield, IL 60093, USA
Phone: +1 855 7697645
drpaul@implantlive.com

Author details

AD

Strong. Aesthetical. Metal-free.

✓Two-piece, reversibly screw-retained ✓100% metal-free ✓Strong connection with VICARBO® screw

An innovation from Switzerland based on 10 years of experience in the development of ceramic implants.
www.zeramex.com

ZERAMEX®