Implant-prosthesis treatment in case of total edentulism

Author: Prof. Massimo Pasi, Italy

Total edentulism is a serious handicap that still affects almost 25 per cent of the population aged 65 years and older. Loss of teeth leads to a severe impairment of life quality of those affected, not only with regard to their ability to chew but also for their social life and their psychological attitude. In case of total edentulism, a prosthesis improves both chewing efficiency and way of life. Since a denture in the maxilla is often well accepted, the minimum of acceptable treatment in the lower jaw are overdentures anchored by two implants.

Introduction

The latest available data on edentulism in Italy dates back to an ISTAT survey of 2005, published in 2008.[1] This work shows that the total absence of teeth affects 22.6 per cent of the population between 65 and 69 years, jumping to 60 per cent of those over 80 years old. Only 52.2 per cent of the subjects have replaced their missing teeth with implants. This is influenced by the fact that edentulism is prevalent among people of lower social status,

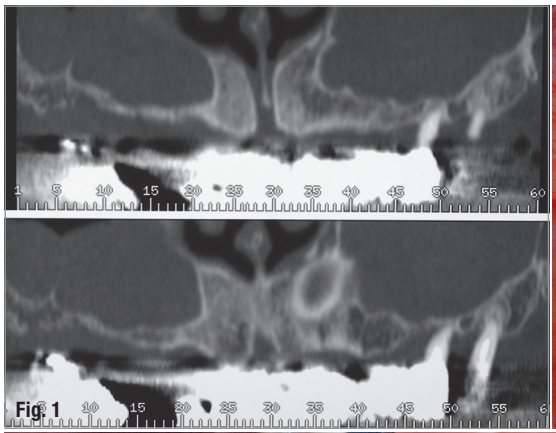
Fig. 1

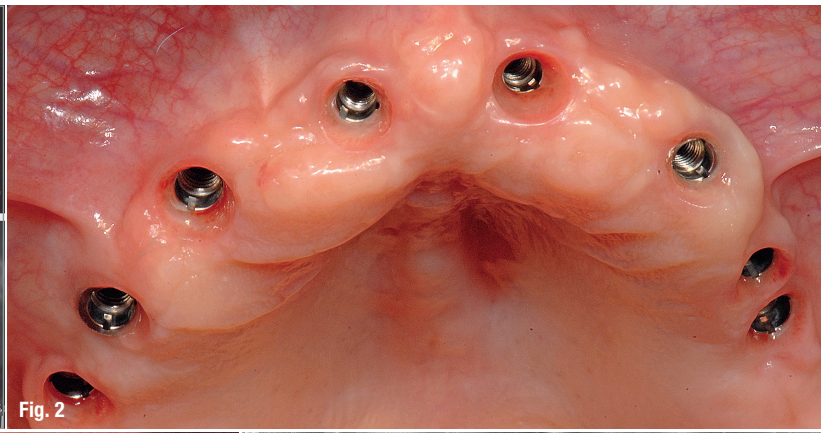
Fig. 2

Fig. 3

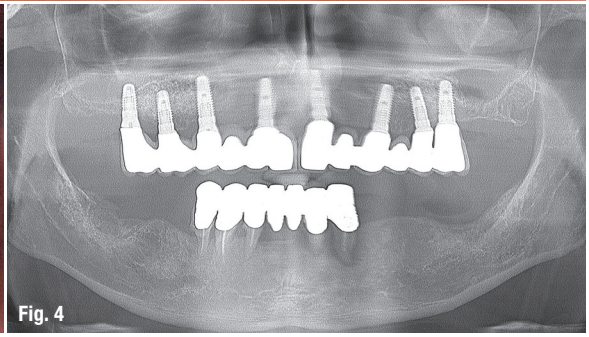
Fig. 4

Fig. 1: CBCT showing iperpneumatic maxillary sinuses and low residual bone in the upper jaw. – **Fig. 2:** Inclusion of eight CAMLOG® implants after rising sinuses maxillary and bone grafts affixing vestibular bilaterally. – **Fig. 3:** Finally fixed prosthesis; small pink flanges in ceramic were sufficient to improve the support of soft tissue without compromising the ability of oral hygiene. – **Fig. 4:** Final radiograph showing bone regeneration.

NOUVAG

We talk Implantology

- **Easy** | Simple device setup
- **Strong** | Powerful and smooth motor
- **Reliable** | High quality finish

Scan me to be linked to the
NOUVAG contact form ▶▶▶

Nouvag AG
St.Gallerstrasse 23 – 25
CH-9403 Goldach
Phone +41 (0)71 846 66 00
info@nouvag.com
www.nouvag.com

SAFETY • PRECISION • RELIABILITY
Swiss made

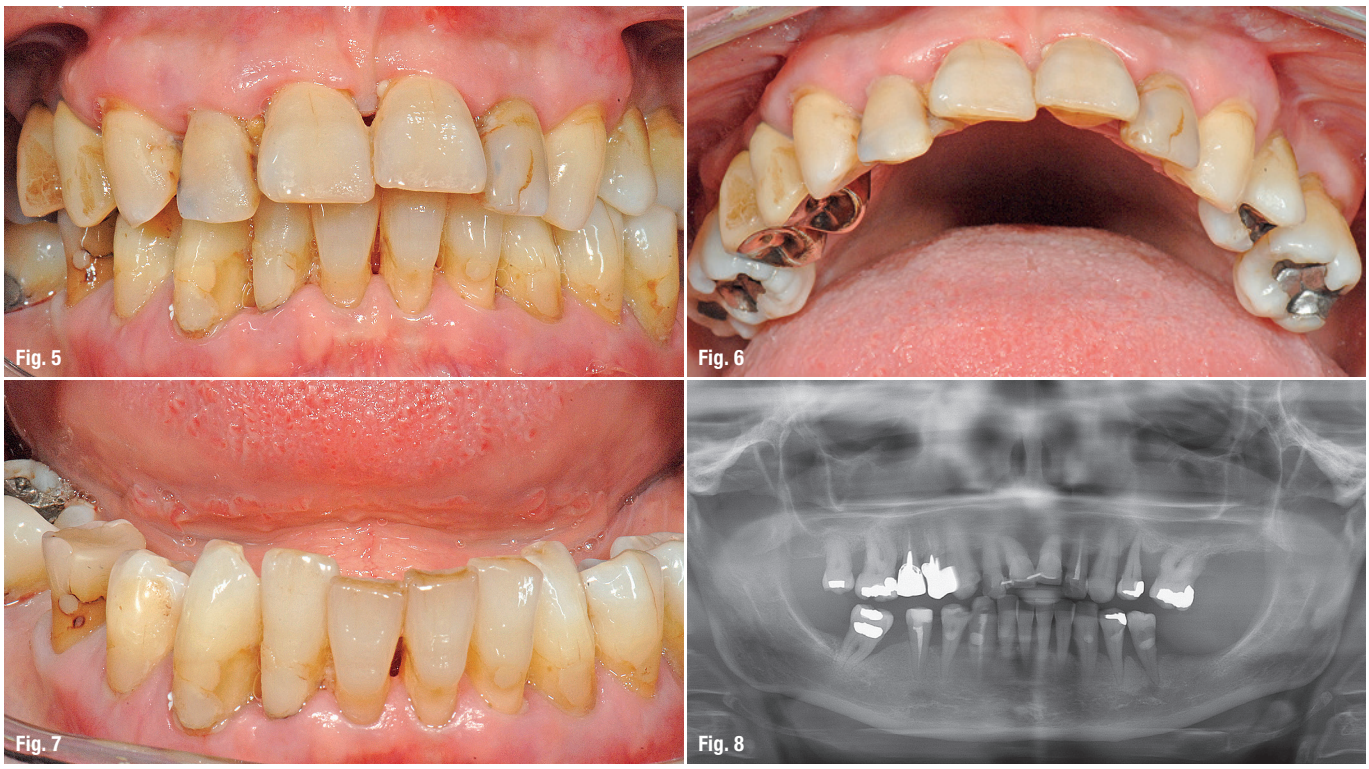

Fig. 5: Initial dental situation after a first professional dental hygiene.
Fig. 6: Upper arch.
Fig. 7: Lower jaw.
Fig. 8: Initial orthopantomography.

which therefore do not have the financial ability and/or cultural demand to replace missing teeth. In such cases, teeth have mostly been lost due to carelessness (caries and periodontitis),[2,3] iatrogenic damage (dental treatments not performed according the state-of-the-art),[4] systemic diseases such as diabetes and immunosuppression,[5] or incorrect lifestyle (eating habits, drug use, smoking)[6].

No prosthesis is able to completely restore the chewing ability,[7] but anyway, life quality of patients with prosthesis is much better than in those cases who have no prosthesis[8-10]. In the maxilla, a high percentage of patients accept a traditional removable prosthesis, while in the lower arch this solution is extremely uncomfortable and not functional. Therefore, it is widely believed in the scientific community that the minimal functional solution in the lower jaw is the inclusion of two implants to stabilise the removable prosthesis.[11–16]

The restoration of edentulism with a fixed implant-supported prosthesis seems to be the best solution. But, especially in the upper arch, this solution is hardly feasible for insufficiency of the remaining bone, for weak support of soft tissues (lips and cheeks) and, consequently, for unsatisfying aesthetics and phonetics. These factors often require pre-implant bone reconstruction with a significant increase of time, costs and morbidity (Figs. 1–4).

The easiest and handiest way therefore seem to be overdentures stabilised by a reduced number of implants. In the upper jaw we can sensibly limit the extent of the palate, improve the general comfort of the patient and his gustatory perception and at the same time decrease inflammatory and/or infectious mucositis.[17,18]

We have already reported that in the edentulous mandible the minimally accepted therapy is an overdenture stabilised by two implants.[11,14] The best results in terms of implant survival and prostheses outcome in the upper jaw is obtained with at least four implants bonded by a bar.[19,20] On the other hand, in the mandible there have not been reported differences regarding implant survival and patient comfort by inserting two or four implants bonded by a bar or using non-bonded implants (ball-attachment or locator).[21] Even scientific publications attested that still today the validity of a removable denture stabilised by implants[22] placed ten years ago were given a further opportunity to resolve total edentulism with a fixed prosthesis supported by a reduced number of implants.

Since the first publication of Maló et al.,[23] the systematic "All-on-4" has gained approval by operators and patients. The concept "All-on-4" allows to have a fixed denture in acrylic resin supported by only four implants of which the two distal inclined as much as possible to displace distal the prosthetic emergency; the prosthesis is screwed to the implants immediately after their placement (within 48 hours). In subsequent years, this method has been confirmed to be safe and reliable.[24-26] By contrast, in severe atrophy

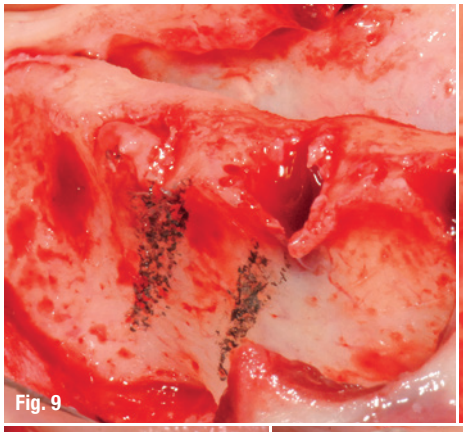
Fig. 9

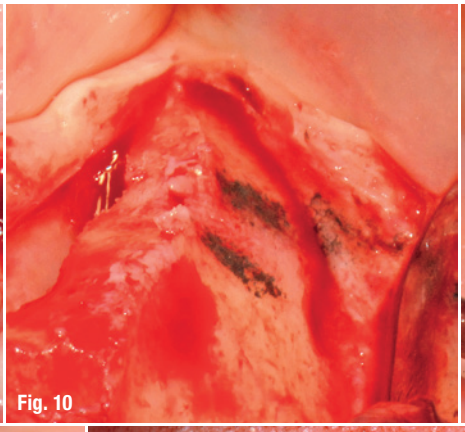
Fig. 10

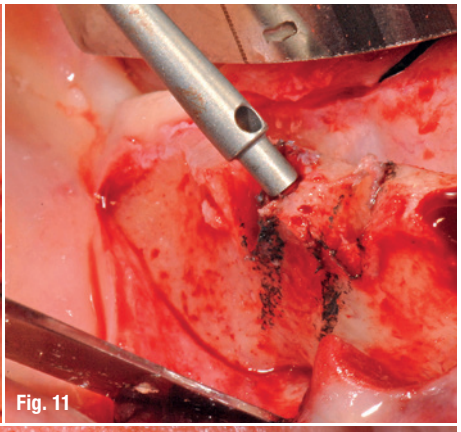
Fig. 11

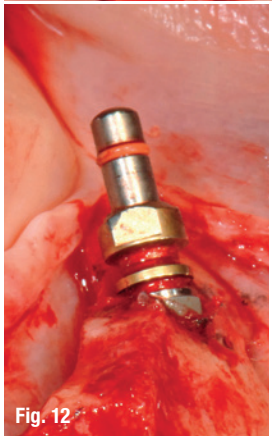
Fig. 12

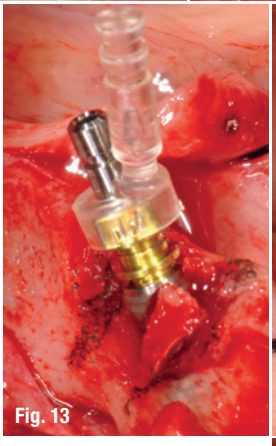
Fig. 13

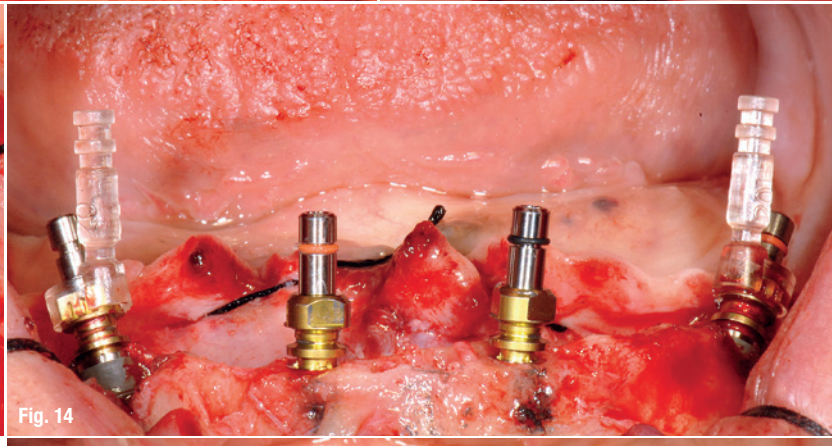
Fig. 14

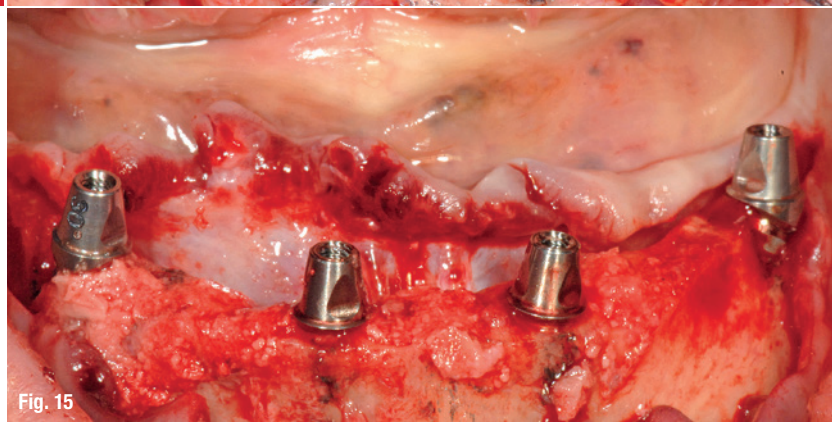
Fig. 15

Fig. 9: Isolation and highlighting of the right foramen and mandibular nerve. – **Fig. 10:** Isolation and highlighting of the left foramen and mandibular nerve. – **Fig. 11:** Preparation of the distal right implant site, tilted by 30°. – **Fig. 12:** Insertion of distal left implant (CAMLOG SCREW-LINE®). – **Fig. 13:** Checking the correct position using the "Vario SR Aligning". – **Fig. 14:** Addition of two mesial implants. – **Fig. 15:** Installation of Vario conical abutments. The internal connection camshafts improve the stability of the abutments.

of the maxilla, to give support to the soft tissue it is necessary to build the vestibular flanges, which often complicates the correct manoeuvres of oral hygiene, since it is impossible for the patient to remove the prosthesis. There we have to keep in mind that oftentimes edentulous patients are elderly and thus their manual ability may not be sufficient to maintain a correct hygiene that ensures a positive long-term outcome.[27] Therefore, the "All-on-4" protocol has to be evaluated with regard to function, aesthetics and the patient's ability to properly maintain the hygiene of the prosthesis.

Clinical case

The patient, 56 years old, has no systemic diseases but has been smoking for the last 30 years (more than 20 cigarettes per day). She reports to have a TMJ pain, tooth mobility with toothache and halitosis for several months now. The patient has a poor oral hygiene, compounded by fear of further dislocation of the teeth while brushing, having already suffered the spontaneous loss of three molars in the months prior to her visit (Figs. 5–8). For professional reasons, the patient has close contact with the public. She thus requests for a solution in a reasonably short time, a less invasive surgery due to her phobia and less time between teeth extraction and prosthesis replacement so that she can continue her job without serious disruption.

Considering the vast bone atrophy of the maxilla, the loss of vertical dimension and the already weak lip support, I proposed an upper overdenture preceded by a removable prosthesis during the months needed for the implants to osseointegrate and a fixed prosthesis in the mandible prepared for immediate loading according to the "All-on-4" con-

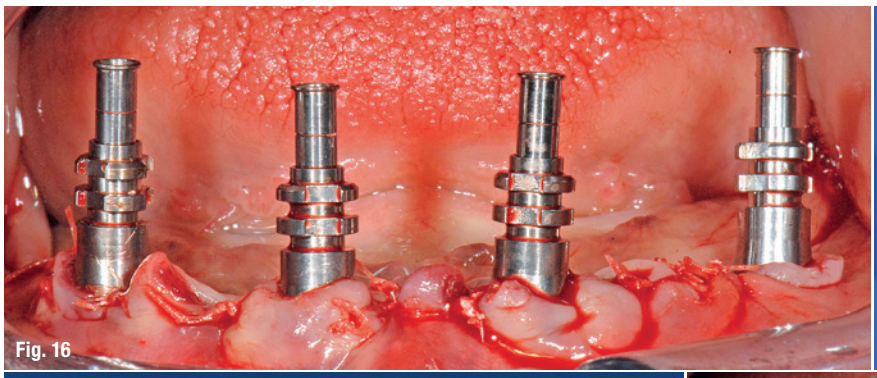
Fig. 16

Fig. 17

Fig. 18

Fig. 19

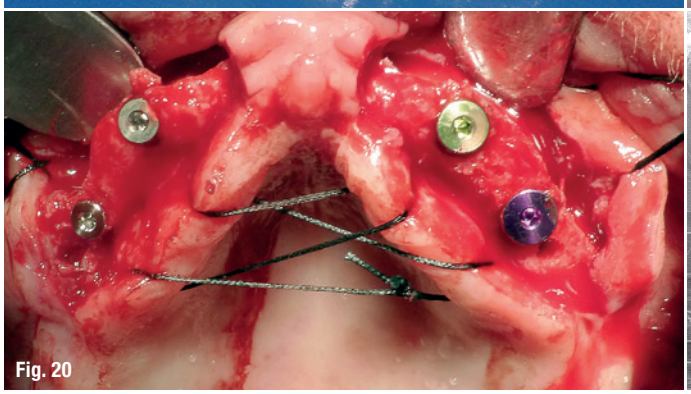
Fig. 20

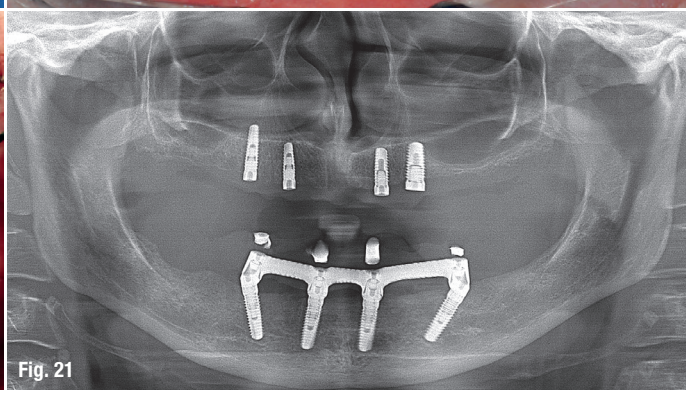
Fig. 21

Fig. 16: Abutments impression.
Fig. 17: Detection of the impression: the four implants appear parallel thanks to the 30°-angled abutment mounted on the two distal, which compensates the inclination of the implants.
Fig. 18: Temporary restoration: in transparency the stabilising bar implant. Notice the smooth surface and convex which allows easy hygiene by means of brush or floss.
Fig. 19: Temporary restoration applied in the mouth.
Fig. 20: Four CAMLOG SCREW-LINE® implants inserted in the maxilla.
Fig. 21: Panoramic radiograph four months after implant surgery.

cept. At the same time, an accurate and professional oral hygiene was done to improve the health of the gums and the patient was instructed on proper oral hygiene at home. With the help of a doctor, she stopped smoking and changed her eating habits, which means the reduction of an excessive consumption of food as well as avoidance of acidifying and sweetened drinks.

We then proceeded with the maxilla tooth extractions and the immediate implementation of a full denture. After a few days of adaptation to the new situation, surgical and prosthetic operation for the application of the lower denture was planned. Once the teeth had been extracted, the bone ridge had been regularised and the mental foramens had been highlighted and isolated, we followed the "All-on-4" protocol by inserting two CAMLOG SCREW-LINE Promote plus® inclined distally with 30°, placed as distally as possible (Figs. 9–13) with the emergency above the foramen. Once checked the correct alignment with the "Vario SR Aligning" device we introduced the two medial implants and the Vario abutments, which will no longer be removed (Figs. 14 & 15).

Once having sutured the wound with an absorbable wire we proceeded with the connection of the impression copings by means of a resin with a very low ratio of contraction (Figs. 16 & 17) and with the polyether impression. The occlusal indexes have been identified beforehand. In the late afternoon of the same day it was applied to the temporary prosthesis with a metal framework to grant rigidity to the implants. The prosthesis was extended up to the second premolar, with this achieving a "protection" of the distal extensions (Figs. 18 & 19). Four months after the implant positioning in the upper arch (Figs. 20 & 21) we took an optical impression for the milling of the bar. After that we took the conventional impression in order to have a good mucous adaptation of the removable prosthesis (Figs. 22–26). For the retention of the prosthesis without the palate four OT Equator® attachments were screwed on the bar.

Membership Application Form

I hereby to apply for membership of the DGZI – German Association of Dental Implantology (Deutsche Gesellschaft für Zahnärztliche Implantologie e.V.).
Please send this form via FAX to +49 211 16970-66.

Do you have experience in implantology? (mandatory)

O Yes O No

I hereby agree to have my personal data processed for all purposes of the DGZI.

O **Full membership** (outside Germany)
⇨ 125 Euro p.a.

O **Assistant doctors** (outside Germany)
⇨ 60 Euro p.a.

O **Students/auxiliaries** (outside Germany)
⇨ free of charge for first-degree students of dentistry

O I have transferred the annual fee to the DGZI bank account c/o Dr Rolf Vollmer:
IBAN: DE33 5735 1030 0050 0304 36 | KSK Altenkirchen | SWIFT/BIC: MALADE51AKI

Personal Data

Name | First Name | Date of birth

Title | Citizenship

Street | City, ZIP code | Country

Phone, Country and Area code | Fax

E-Mail | Homepage

Special qualification | Spoken languages

Payment (by credit card)

Please use your: (Please mark as appropriate)

O Visa O MasterCard

Card holder's name | Card number

Expiry date

Signature | Place, Date

Please complete this application form in block letters.

FOR FURTHER INFORMATION PLEASE CONTACT

DGZI Deutsche Gesellschaft für Zahnärztliche Implantologie e.V.

Deutsche Gesellschaft für Zahnärztliche Implantologie e.V.
Central Office: Paulusstraße 1, 40237 Düsseldorf, Germany
Phone: +49 211 16970-77 | Fax: + 49 211 16970-66 | office@dgzi-info.de | www.dgzi.de

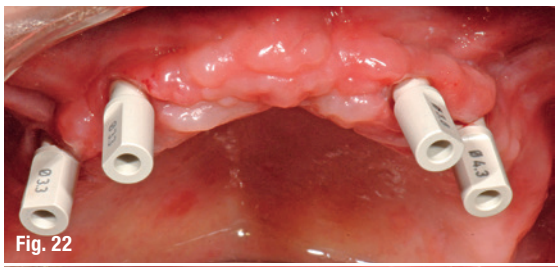
Fig. 22

Fig. 23

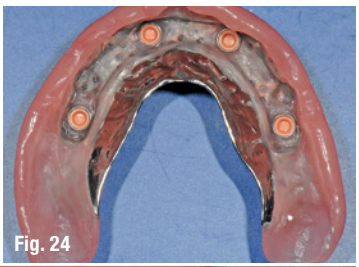
Fig. 24

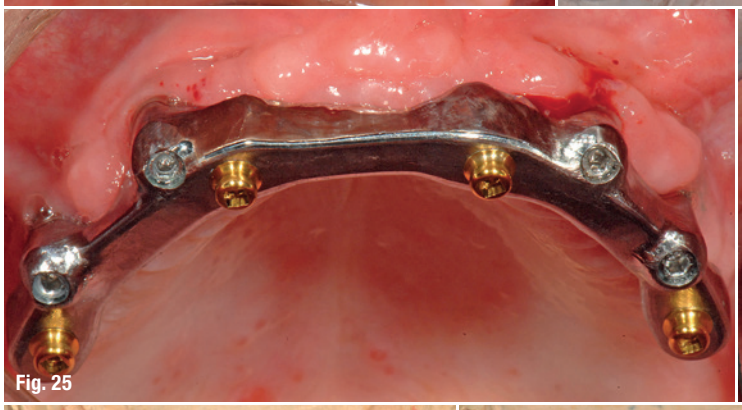
Fig. 25

Fig. 26

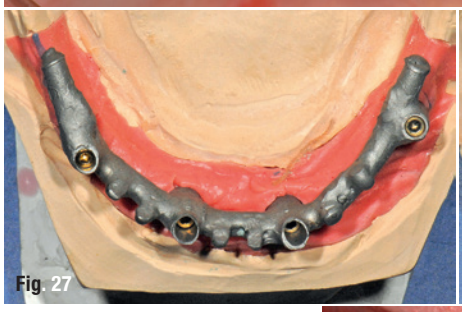
Fig. 27

Fig. 28

Fig. 29

Fig. 30

Fig. 31

Fig. 22: Scan body of the optical impression.
Fig. 23: Milled bar.
Fig. 24: Upper dentures with structure in chrome-cobalt.
Fig. 25: Bar screwed on implants in the upper jaw with the four OT Equator® screwed.
Fig. 26: Upper prosthesis without palate.
Fig. 27: Reinforcement bar of the mandibular permanent prosthesis.
Fig. 28: Mandibular prosthesis ultimately extended to the first molar.
Fig. 29: Overview of the side facing the mucosa.
Fig. 30: Mandibular prosthesis screwed. The holes were closed with composite.
Fig. 31: The two prosthesis in occlusion.

Seven months after insertion of the mandibular implants, we proceeded with the definitive impression of the face bow. The technician proceeded with the construction of the bar and the acrylic prosthesis with a good hygienic mucous (Figs. 27–29). The provisory prosthesis was then replaced by the definitive one with the occlusal extended to the first molar (Figs. 30 & 31). The support of the soft tissues given by the vestibular flange of the upper prosthesis provided a correct vertical dimension and also the healing of the cheilitis that affected the patient before the treatment as well as the protrusion of the lips and a mechanical lifting of the wrinkles (Figs. 32–35). The orthopantomography six months after the treatment confirms the stability of the implant restoration (Fig. 36).

Conclusion

Total and partial edentulism is a serious handicap for people who are affected. Edentulism is oftentimes a self-made problem, beginning early with a careless oral hygiene and unfavourable habits. Thus, as dentists we should encourage our patients at a very early stage of age to follow a healthy lifestyle, including personal hygiene, nutrition, physical activity and regular dental check-ups from elementary school on, involving of course the families. At the moment a person becomes edentulous however, it is our duty to try to improve the quality of his life in restoring his proper chewing function (not to further jeopardise the state of his health) and to improve his social life (not to compromise the psychological situation).

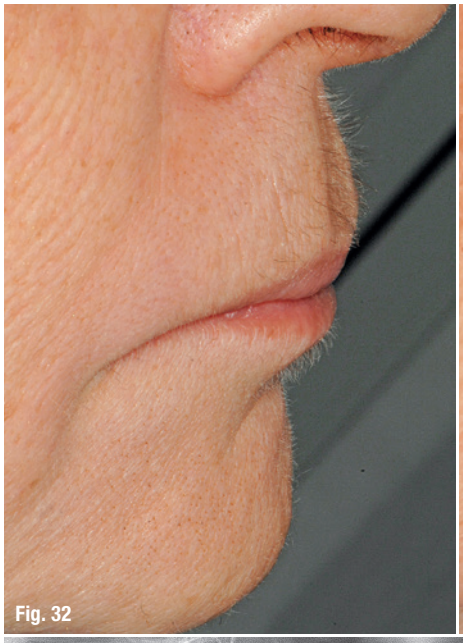
Fig. 32

Fig. 33

Fig. 34

Fig. 35

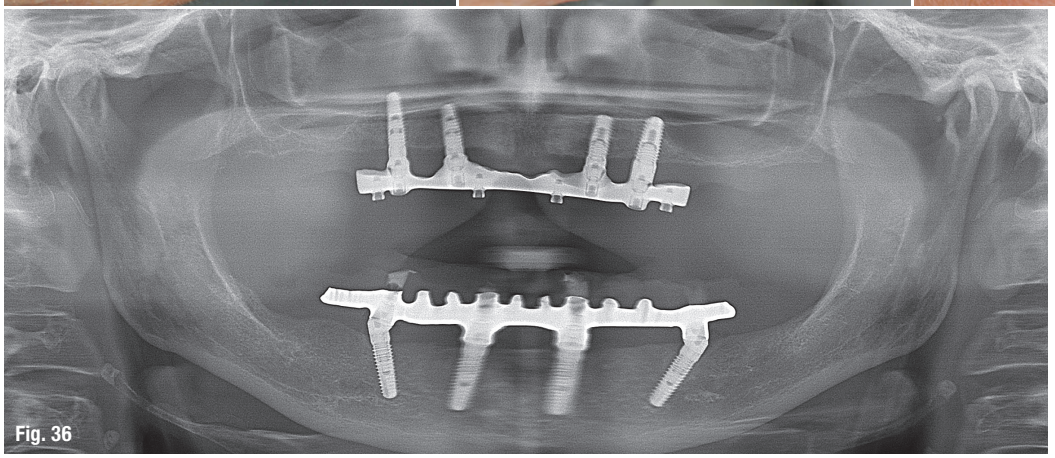
Fig. 36

Fig. 32: Profile of the patient before treatment: note the lack of visibility of the lip vermilion.
Fig. 33: Different lip support at the end of the treatment.
Fig. 34: Angular cheilitis at the beginning of the treatment.
Fig. 35: Healing at the end of the treatment and disappearance of most of the skin wrinkles.
Fig. 36: Orthopantomography control six months after rehabilitation.

The simple replacement of the missing teeth with a full denture may be an appropriate solution in the maxilla for many patients. But a full denture in the lower arch is absolutely incongruous because it does not allow a sufficient chewing efficiency and, because of instability due to a poor tissue support and tongue and cheek movement, often creates soreness and discomfort in social life. Therefore, it is necessary to inform people facing mandibular edentulism that they can regain comfort and masticatory function with the insertion of two implants to stabilise the prosthesis.

Definitely a big step forward in the resolution of edentulism was done with the "All-on-4" systematic, which is surgically minimally invasive, fast and economically acceptable. This solution is however not applicable in all cases, since it is necessary to have good manual skills for a correct maintenance and a proper oral hygiene; it is not always adequate from a functional and aesthetic point of view. Therefore, the solution of edentulism with an overdenture stabilised by four systems can be, especially in the maxilla, the most appropriate therapy without having to perform a surgically invasive operation and regenerative therapy, which both are often not well accepted by patients._

Literature

contact

Prof. Massimo Pasi
Studio Medico Dentistico
Via Francesco D'Ovidio, 1
20131 Milan, Italy
Tel.: +39 2 70633631
mpasi@massimopasi.it

Author details