

Computer-assisted implant rehabilitation of tumour patients

Ioannis Papadimitriou, Dr Petros Almagout, Dr Erich Theo Merholz & Dr Stefan Helka, Germany & Greece

Implantology has become a fundamental, if not routine, component of oral rehabilitation and the most reliable procedure in the discipline's attempt to realise restitutio ad integrum. In modern dentistry, implant-supported restorations are considered to be the usual and best care options. However, particularly in patients with malignancies of the oral cavity, there are fundamental changes to the anatomy of the oral cavity due to the extensive surgical procedures and adjuvant radiotherapy. In the post-irradiated jaw, a purely mucosa-supported prosthesis is not indicated owing to xerostomia and the necrosis risk of irradiated bone. The only practical way to prevent load on the mucosa is the insertion of dental implants and the subsequent incorporation of an implant-supported fixed denture.^{1,2}

Traditionally, determining implant position, size, number, direction and placement depended on the pre-operative diagnostic imaging, which was limited to 2-D radiographs and guiding templates. Three-dimensional imaging and navigational aids offer the treating implantologist enhanced certainty and additional options, especially in high-risk cases, such as patients with extreme alveolar ridge atrophy or patients with malignancies of

the oral cavity. With 3-D imaging, implant prosthetic dentistry has taken a major step forward. The dentist can plan the surgical procedure virtually in combination with 3-D planning programs.⁵⁻⁷ This has been made possible mainly by the steady improvement of specific implant planning programs, such as CTV (computer tomography visualisation) software.

With navigated implantology, it is possible to pass through the alveolar crest, locate structures and assess the existing bone at all levels. On the basis of the available data obtained on computer, the length, inclination, diameter and ideal position of the implants can be determined.¹⁻⁴ Prerequisite for navigated implantology is the use of appropriate imaging techniques, particularly the 3-D radiographic method of cone beam computed tomography (CBCT; Table 1).⁶⁻⁸ This modern 3-D diagnostic enables detailed surgical planning of implantation, taking into account prosthetic considerations. Navigated implantology offers several advantages:⁷⁻⁹

- precisely guides the osteotomy drills, through a secure, reproducible positioning of the template, directing the surgeon on the exact location and angulation to place the implant based on the virtual treatment plan;

	Effective dose in µSv	Multiple doses of a dental panoramic tomogram	Dose as % of annual natural radiation
Dental panoramic tomogram	~6	1	0.2
GALILEOS default	29	5	1.0
ILUMA default	331	52	11.0
I-CAT	68	11	2.3
Planmeca ProMax	210	33	7.0
NewTom	39	6	1.3
CT scan	2,100	323	70.0

Table 1

Table 1: Comparison of radiation exposure of various methods and systems.

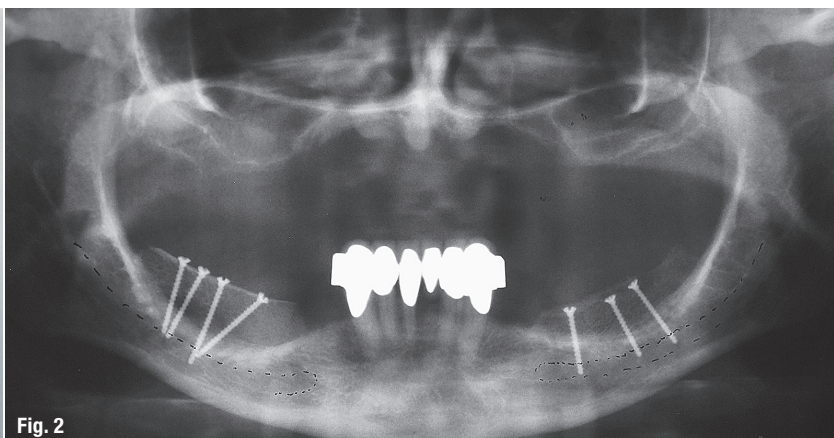
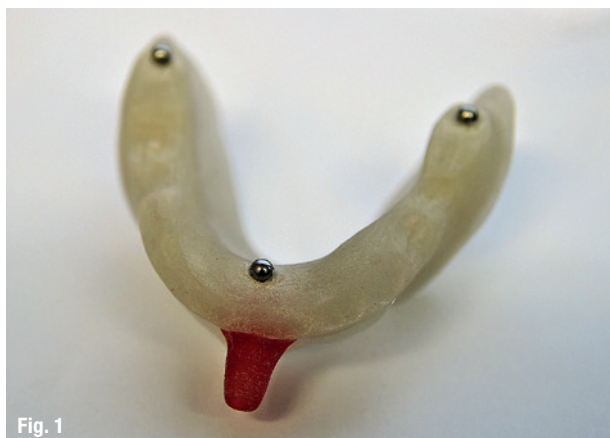

Fig. 1: Radiographic template with three reference balls. **Fig. 2:** Dental panoramic tomogram after augmentation with iliac crest bone.

- allows flapless, minimally invasive surgery, avoiding unnecessary bone exposure, which entails less bleeding, less swelling, and a reduced healing time and post-operative pain;
- low-distortion and detailed radiographic analysis and an improved learning curve for the dentist, surgeon and dental technician team;
- provides greater safety for patients and dentists through 3-D planning, especially with complicated jaw conditions or low bone volume and the risk of post-operative complications is significantly reduced;
- virtual planning provides the conditions for considerably increased accuracy of implant placement and avoidance of vital structures, followed by the prosthetic restoration of masticatory function;
- the operation period is significantly shorter.

However, computer-assisted implant surgery is not free of risks. Navigated implantology also has certain drawbacks and limitations, which have to be considered as well:¹⁰⁻¹²

- problems with the template positioning in edentulous jaws and inaccurate fixation of the surgical guide, resulting in displacement during the surgery;
- fracture of the surgical guide;
- dependence between the guide system and software and usually the learning curve for the dentist, surgeon and dental technician team is complex;
- reduced mouth opening can lead to changed positioning of surgical instruments;
- the total cost of the tools needed, including the software program and surgical templates, is higher in comparison with that of traditional methods;
- intra-operative modification of implant position is not allowed.

In computer-aided implantology, the treatment procedure is very precise, but for a successful outcome and a predictable end result, backward planning is essential, since it allows the implants' alignment in the arch,

helps in treatment predictability, and promotes the maintenance of aesthetic and biomechanical principles.¹¹⁻¹³

The backward planning for a computer-aided implantation includes the following steps:

1. Impression and model fabrication.
2. Planning of prosthetic restoration.
3. Preparation of a scan template with three reference balls (aluminium, 2 mm in diameter; Fig. 1).
4. CT/CBCT scan of the patient with the inserted scan template.
5. Reading the radiographic data into the CTV system and virtual planning of the implantation.
6. Transfer of the planning data to the drilling template.
7. Guided implant placement.

Case presentation

In this section, we present two clinical cases of prosthetic rehabilitation of a patient with extreme alveolar ridge atrophy and a tumour patient with iliac crest bone grafting and computer-aided implantation using the CAMLOG Guide System. The preoperative planning, the operation phases and the patient's postoperative wound healing are described. The study was conducted in the oral and maxillofacial surgery department of St. Lukas Hospital in Solingen, Germany. The patients concerned presented for implant rehabilitation in our department after surgical resection and irradiation and before augmentation of the extreme alveolar ridge atrophy of the lower jaw with iliac crest bone. The insertion of implants was performed after obtaining CBCT scans and virtual planning of the implantation using CTV software.

Case 1

A 67-year-old female patient was referred to our department for implant rehabilitation. She was generally healthy, totally edentulous in the upper jaw and partially edentulous in the lower jaw. The initial clinical examination and the CBCT scan showed a very extensive vertical and horizontal bone defect in regions #34-37

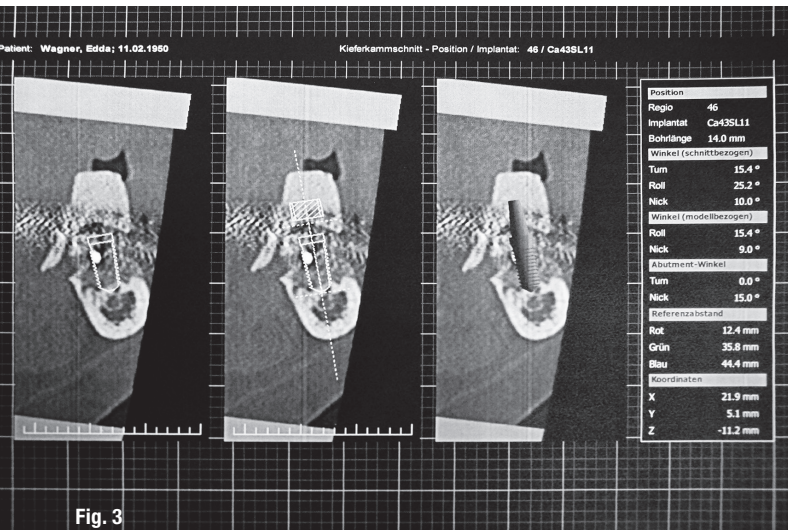


Fig. 3

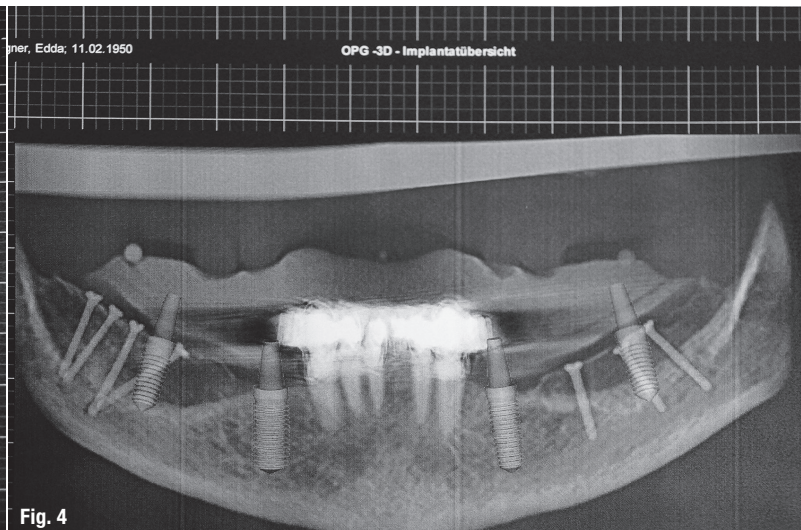


Fig. 4

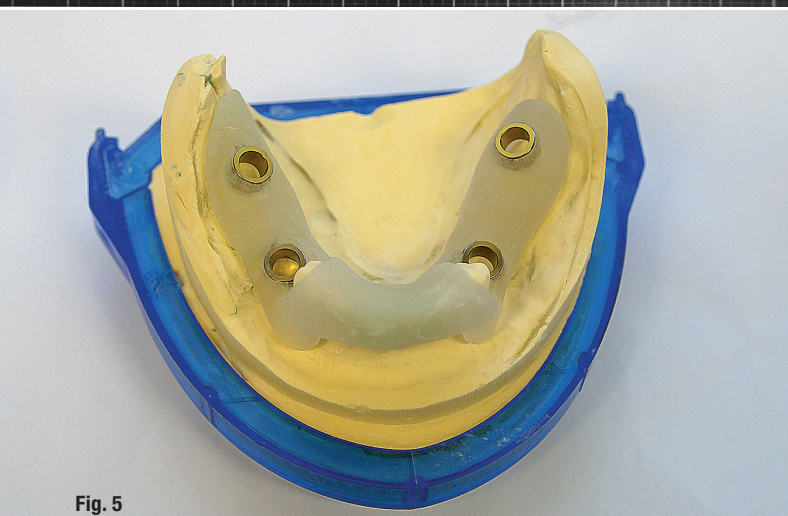

Fig. 5

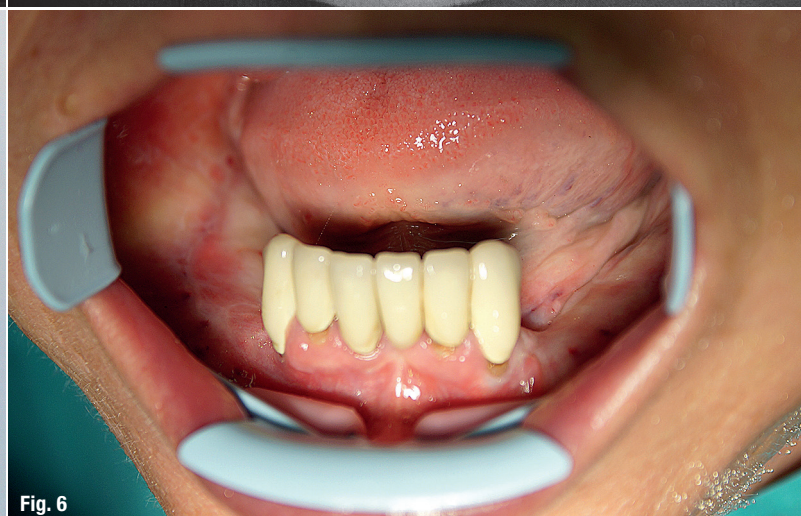

Fig. 6

Fig. 3: Sagittal section in region #46 of the planned implantation. **Fig. 4:** Virtual dental panoramic tomogram with the digitally determined 3-D implant positions. **Fig. 5:** Fully navigated drilling template for the lower jaw after CBCT planning. **Fig. 6:** Preoperative view of the mandible.

and 44–47 as consequence of progressive resorption. After the final diagnosis and planning, we discussed the possible restorative options and alternative solutions. The patient was not satisfied with her removable denture in the lower jaw and wished for a fixed denture.

In order to make treatment possible with bridge constructions on osseointegrated titanium fixtures, bone grafting was necessary in the edentulous regions of the lower jaw. The patient was explicitly informed of the possible risks and dangers from the functional and aesthetic perspective during and after the treatment period and the treatment steps were explained. Five months after the reconstruction of the alveolar jaw with iliac crest bone (Fig. 2), we were able to continue our therapy planning, which included preoperative prosthetic planning and navigated implantation.

After taking impressions, a wax set-up was produced. The aesthetic set-up in wax served for the shape speci-

fication for the preparation of the provisional restoration, the final restoration and the implant planning. The virtual planning followed. The radiographic template for CBCT imaging was prepared on a duplicate of the master model with light-curing tray material. Three radiographic balls made of aluminium were inserted into the radiographic template (Fig. 1). The use of the three balls increased the precision of the planning, because in this procedure, the ball midpoints and not edges were adjusted. A CBCT scan was performed with the patient wearing the radiographic guide. The basis for the implant planning was the data set obtained from the CBCT scan.

The minimally invasive, transgingival implantation was planned using the 3-D data set with the CTV software. Anatomical conditions had to allow the placement of at least four implants in the ideal position for prosthetic rehabilitation (Fig. 3). Once an implant had been planned, it was easy to see the vestibular and lingual cortical bone.

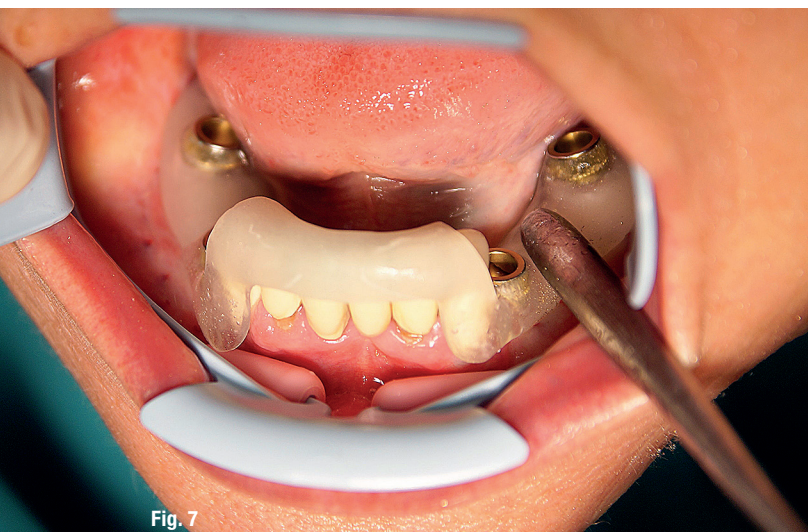


Fig. 7

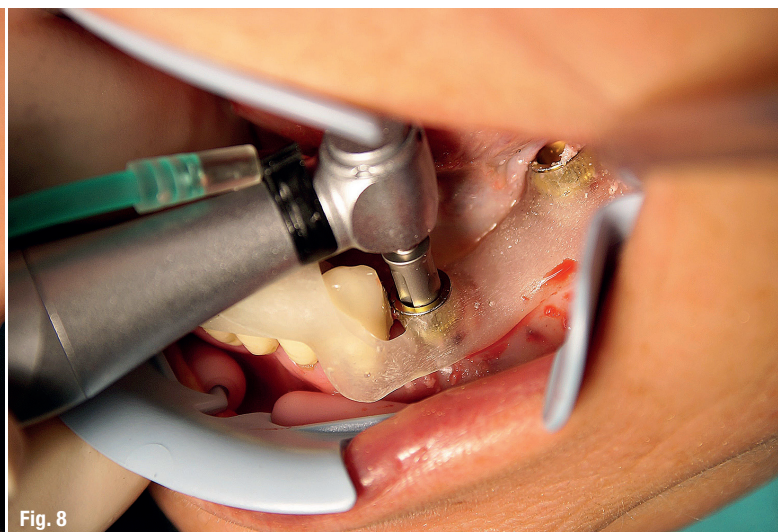

Fig. 8

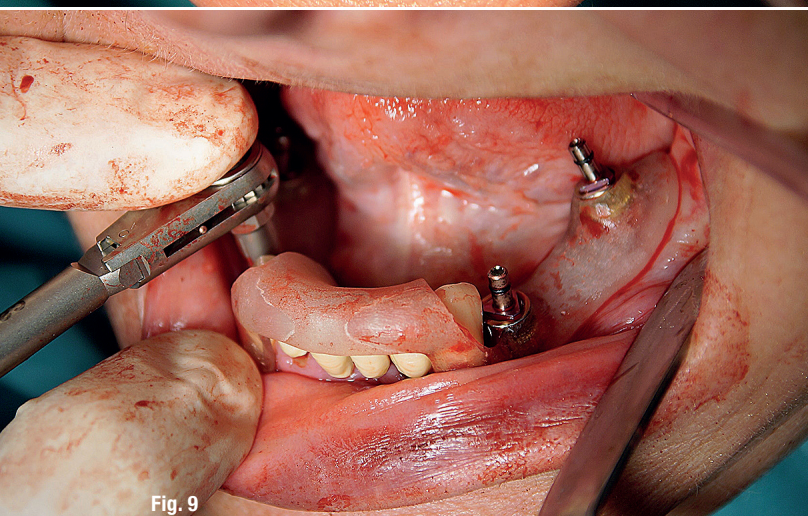


Fig. 9

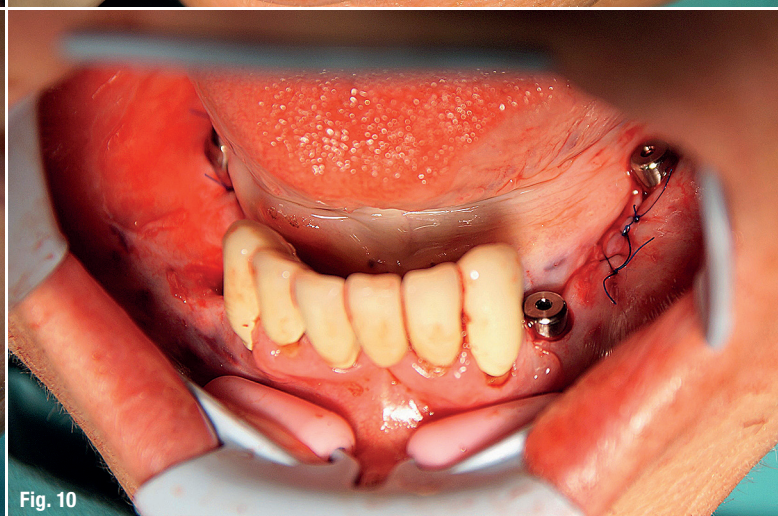

Fig. 10

Fig. 7: Insertion of the template in the lower jaw. **Fig. 8:** Guided drilling through the drilling sleeve according to the surgical protocol. **Fig. 9:** Manual insertion of the guided implants with the locked torque wrench. **Fig. 10:** All guided implants *in situ* with gingiva formers.

After bone volume analysis, implants were planned on the lingual aspect, and the implant platform virtually positioned at the level of the coronal part of the vestibular alveolar crest (Fig. 4). The main feature in the production of the surgical guide was the secure positioning and stable fixation of the drilling sleeves in the template. For the production of the drilling template, the drilling sleeves were placed on the plastic models produced by an additive process (Fig. 5).

The surgical procedure was performed under local anaesthesia with Ultracain® D-S forte 1:100,000. Cefuroxim (500mg) antibiotics were given one hour before surgery and twice a day for six days thereafter. The patient rinsed with chlorhexidine gluconate (0.2%) for one minute before the intervention (Fig. 6).

The surgical template was placed intraorally in the correct position and in relation to the opposing arch. Considerable care was taken when placing the surgical

template (Fig. 7). After correct placement and stabilisation of the surgical template, flapless implant surgery was performed in accordance with the drilling protocol for the type of implant used (Fig. 8). At the regions #34 and 44, two CAMLOG fully guided implants of 4.3mm in diameter and 13.0mm in length were inserted, and in regions #36 and 46 implants of 4.3mm in diameter and 11.0mm in length.

Moreover, two small full-thickness flaps were raised in order to remove the osteosynthesis screws used to stabilise the autogenous bone graft in the previous augmentation surgery (Fig. 9). The insertion of the implants was carried out with the standard placement head and the DRM ratchet to the maximum primary stability, with a preset insertion torque of 35–45Ncm. The gingiva formers were inserted to a torque of 20Ncm (Fig. 10) and the flaps were sutured after the implant insertion with non-resorbable sutures (Prolene 5/0). The sutures were removed after seven days. A postoperative

dental panoramic tomogram showed the inserted implants in the lower jaw and the areas of augmentation on both sides were also clearly recognisable (Fig. 11).

After the operation, the patient was instructed to cool and protect the operating area; a chlorhexidine gluconate mouthwash (0.2%) was prescribed for one minute twice a day for two weeks after surgery and painkillers, if necessary. The patient was instructed on oral hygiene. Scheduled visits after surgery were after one week, two weeks and one month. At these visits, the healing process was found to be very good and painless. The definitive prosthetic restoration was planned for four months after the implantation.

Case 2

A 75-year-old male patient was referred to our department for dental examination and for implant rehabilitation. In 2011, he had been diagnosed with squamous cell carcinoma on the right side of the tonsil. After the tumour resection and neck dissection and an adjuvant radiation therapy of up to 65 Gy, the patient was in the ambulatory tumour follow-up phase of care. This was the case

because the tumour resection was inconspicuous and without signs of recurrence. Through the previous tumour surgery, the anatomy of the oral cavity had changed fundamentally: owing to xerostomia and radiation-induced caries in 2013, all of the remaining teeth in both jaws had had to be extracted.

The first clinical examination in our department found a totally edentulous upper and lower jaw with a loss of taste and xerostomia. The dental panoramic radiograph showed about 10 per cent vertical and 15 per cent horizontal bone loss in both dimensions in the upper and lower jaw. After the final diagnosis and planning, we discussed the possible restorative options and alternative solutions. Because of the post-irradiated jaw, a purely mucosa-supported prosthesis was not indicated, and owing to the xerostomia, the maintenance of a purely mucosa-supported prosthesis was not guaranteed. Therefore, the only medically reasonable and practical solution was the insertion of dental implants, six implants in the maxilla and six in the mandible, with subsequent incorporation of an implant-supported fixed denture.

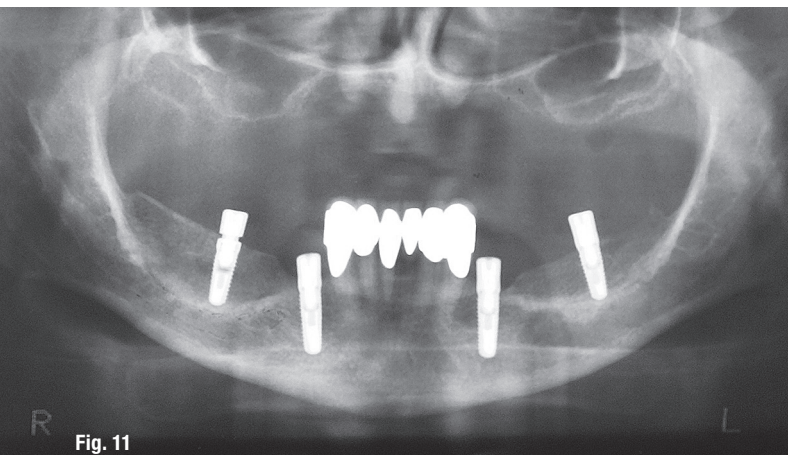


Fig. 11

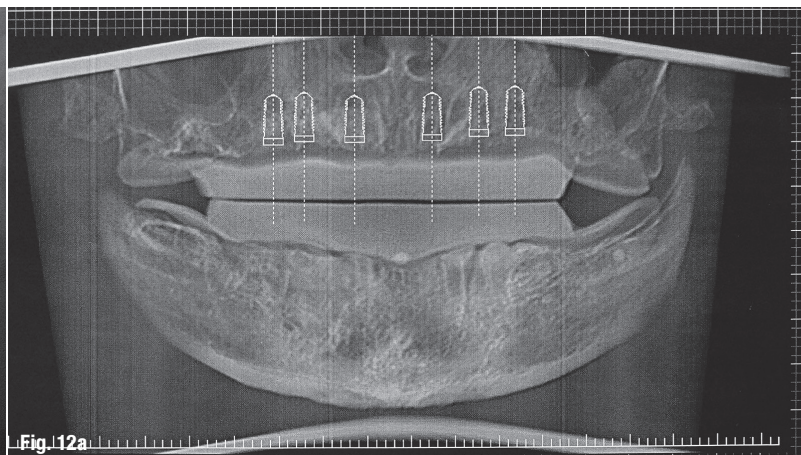


Fig. 12a

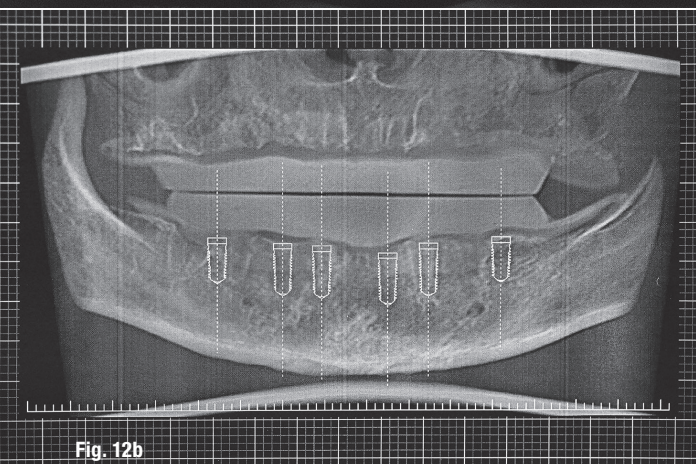


Fig. 12b

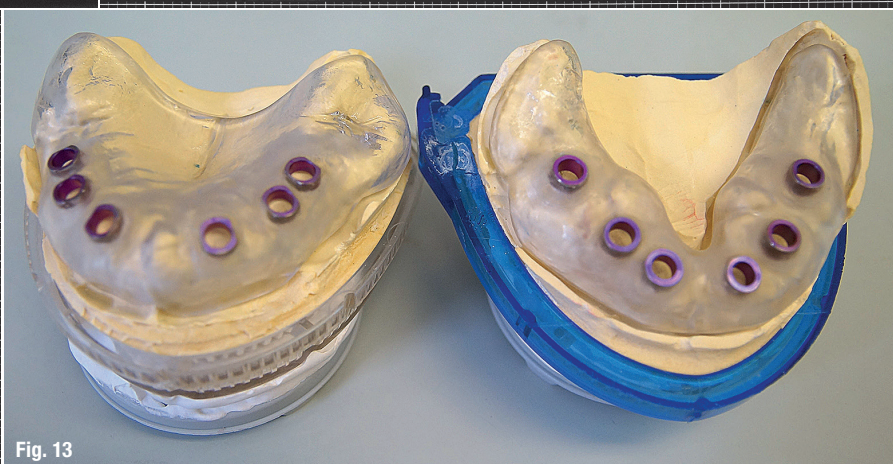

Fig. 13

Fig. 11: Dental panoramic tomogram of the patient after the surgery for control of the implants' positions. **Figs. 12a & b:** Virtual dental panoramic tomogram showing the digitally determined 3-D implant positions in the maxilla (a) and in the lower jaw (b). **Fig. 13:** Fully navigated drilling templates after CBCT planning (drilling sleeves, fully guided 4.3 mm, violet).

After taking the impressions in our department, the master models were made in the dental laboratory in a model tray socket and a wax set-up was produced and customised according to the aesthetic and functional evaluations. The patient was prepared for the computer-guided implant procedure. He underwent a CBCT with the radiographic template and the acquired DICOM images were processed with the aid of the CTV software. The planning with this software produced a report in which the coordinates of each of the three ball midpoints were determined, allowing the laboratory technician to orient and reproduce the surgical template (Figs. 12a & b). The drill guides were produced via a thermoforming technique on a duplicate model of the master model. Subsequently, the drilling sleeves were incorporated with the sleeve holders in the drilling template using the additive-produced plastic model. The transparent base of the template enabled intraoperative assessment of the template placement on the tegument through an even ischaemia due to the contact pressure during implantation (Fig. 13).

The surgical procedure was performed under local anaesthesia with Ultracain® D-S forte 1:100,000. Cefuroxim

(500mg) antibiotics were given one hour before surgery and twice a day for six days thereafter. The patient rinsed with chlorhexidine gluconate (0.2%) for one minute before the intervention. After infiltration anaesthesia in the upper and lower jaw, and bilateral nerve block anaesthesia in the lower jaw and upper palate, the surgical template was carefully inserted and stabilised correctly in the lower jaw.

In the mandible, the mucosa was punched out with a rotating punch at regions #36, 34, 32, 42, 44, and 46 (Fig. 14). After disassembling the template, the gingiva points marked with the punch were cut down and the punches removed in order to obtain a punched and prepared lower jaw (Fig. 15). Thereafter, the drilling template was used again. According to the manufacturer's instructions, cannon drills (6 mm pilot drill; 9, 11 and 13 mm form drills) were used to prepare the implant osteotomies at regions #36, 34, 32, 42, 44 and 46 (Fig. 16).

The insertion of the implants was carried out with the standard placement head and the DRM ratchet to the maximum primary stability, at about 30–35 Ncm (Fig. 17).

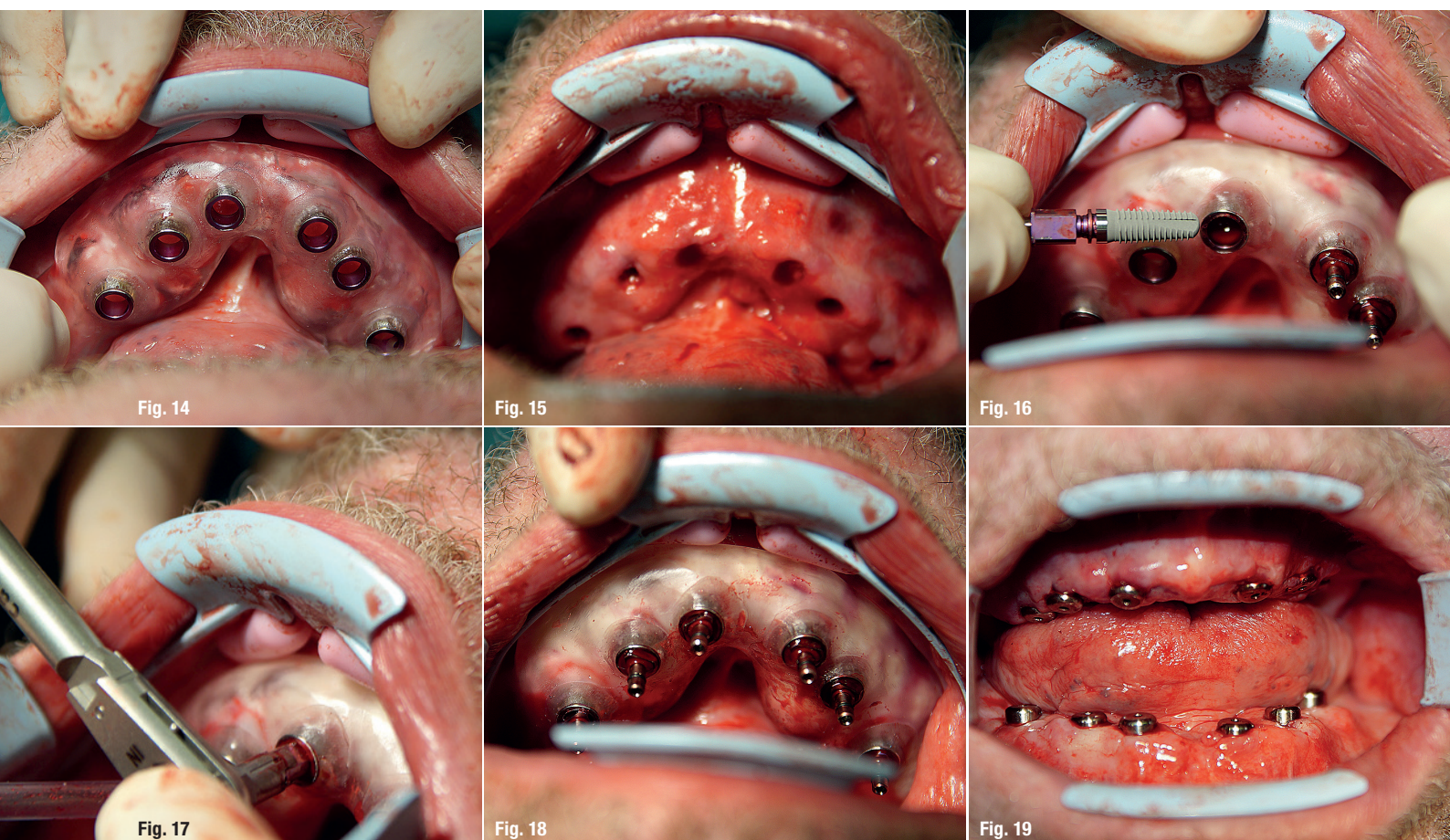


Fig. 14: Insertion of the template in the mandible. **Fig. 15:** Punched and prepared mandible. **Fig. 16:** Implant placement. **Fig. 17:** Manual insertion of the CAMLOG implant with the locked torque wrench. **Fig. 18:** All guided CAMLOG implants in the lower jaw. **Fig. 19:** Implantation result with all of the implants *in situ*.

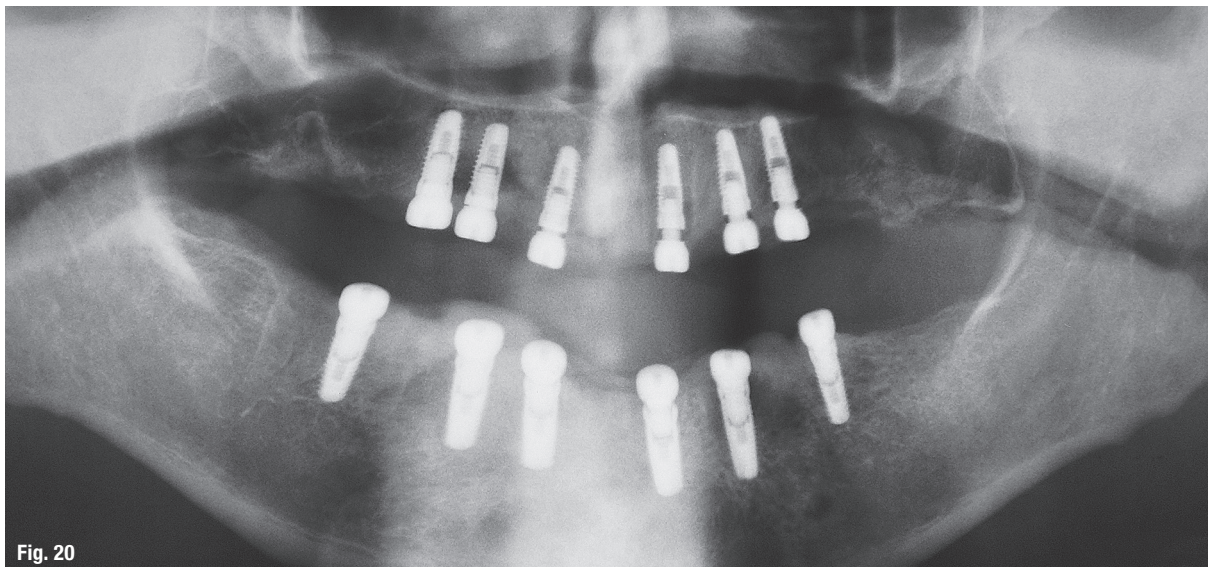


Fig. 20

Fig. 20: Dental panoramic tomogram of the patient for control of the final result.

Subsequently, the implant navigation posts and the surgical template were removed in order to insert the gingiva formers in the maxilla, which were inserted to a torque of 25 Ncm (Figs. 18 & 19). The procedure in the maxilla was analogous to the operative implant bed preparation and insertion of the implants in the lower jaw, where six fully guided CAMLOG implants of 4.3 mm in diameter and 11.0 mm in length were inserted in regions #15, 14, 12, 22, 24 and 25. A postoperative dental panoramic tomogram showed the inserted implants in the maxilla and mandible (Fig. 20).


After the operation, the patient was instructed to cool and protect the operating area; a chlorhexidine gluconate mouthwash (0.2%) was prescribed for one minute twice a day for two weeks after surgery and painkillers, if necessary. The patient was included in our implant maintenance programme and instructed on oral hygiene. Scheduled visits after surgery were after one week, two weeks and one month. At these visits, the healing process was found to be very good and painless. The definitive prosthetic restoration was planned for five months after the implantation.

Discussion and conclusion

The advancements in the field of implantology, such as 3-D imaging, implant planning software, CAD/CAM technology, and computer-guided and navigated implant surgery, have led to the digitalisation of implant dentistry and have taken implant prosthetic dentistry a major step forward. With significant achievements accomplished in the field of digital implant dentistry, implant placement has become highly predictable, even in patients where implant surgery was previously contra-indicated.^{6,7,14}

Modern 3-D diagnostics enable detailed surgical planning of implantation, including prosthetic considerations. This achievement is mainly due to the continued improvement of implant planning programmes such as CTV software. CTV is used to display digital image data for diagnosis and precise prosthetic implant-oriented planning, with subsequent template-based implant placement.^{8,13,14}

In conclusion modern implant navigation is based on sound systematic, prosthetic and surgical knowledge. It can optimise implant treatments and safely achieve the desired result, but it can never compensate for a lack of knowledge and surgical skill of the operator.^{11,12,14}



contact

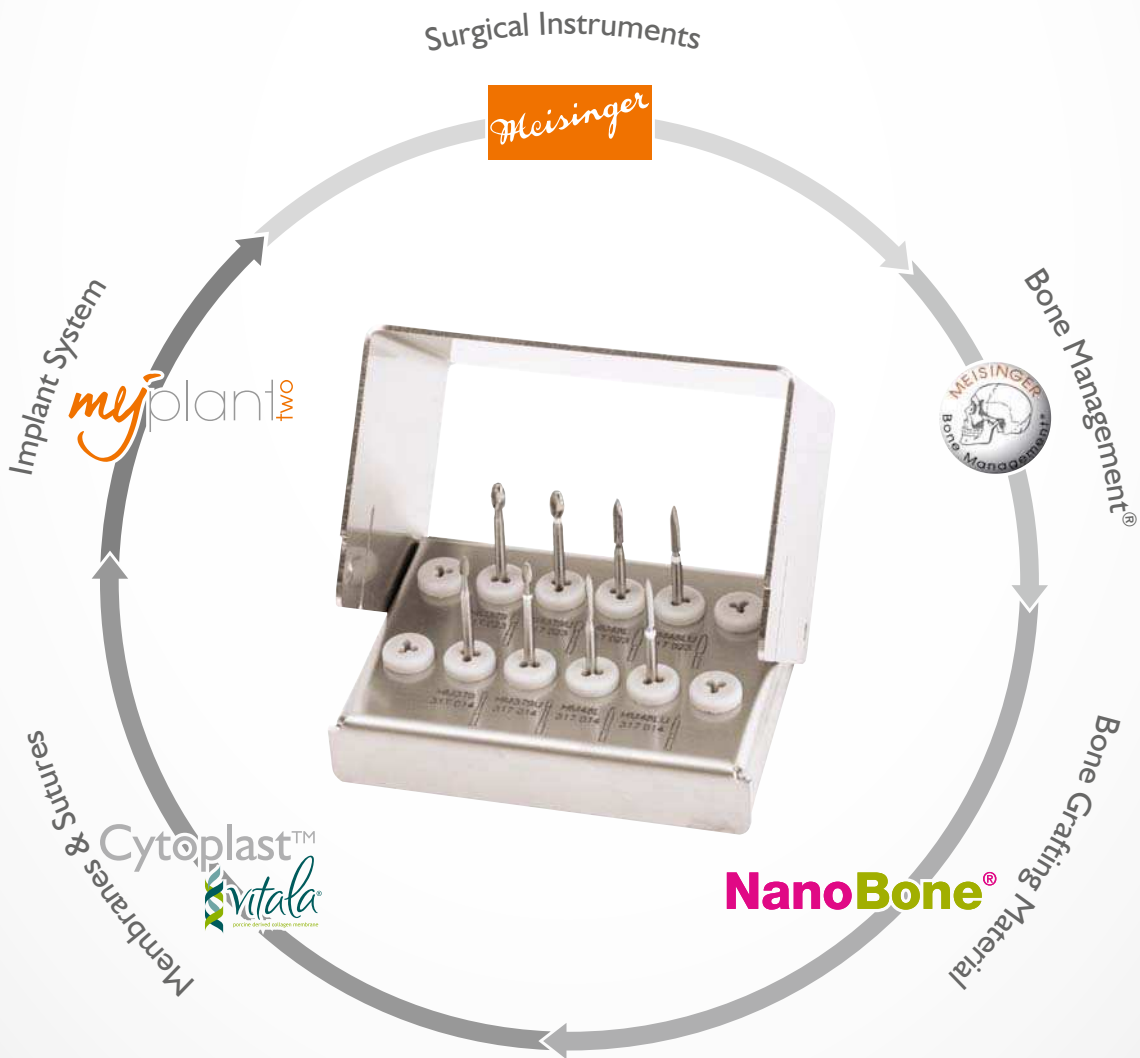
Ioannis Papadimitriou

St. Lukas Hospital
 Department of Oral and
 Maxillofacial Surgery
 Schwanenstraße 132
 42697 Solingen
 Germany
 giannis.papadimitriou_4@hotmail.com



MEISINGER

PERFECT SURGICAL SOLUTIONS



MEISINGER Periimplantitis Kit

Long Tungsten Carbide instruments for ideal peri-implantitis treatment (2575)