L-PRF in different intraoral applications

Part II: Open-flap debridement & ridge preservation

Prof. Nelson R. Pinto[1], Dr Andy Temmerman[2], Ana B. Castro[2], Simone Cortellini[2], Prof. Dr Wim Teughels[2] & Prof. Dr Marc Quirynen[2]

[1] Department of Periodontology and Oral Implantology, Faculty of Dentistry, Universidad de Los Andes, Santiago, Chile
[2] Department of Oral Health Sciences, Section of Periodontology, KU Leuven & Dentistry, University Hospitals, KU Leuven, Leuven, Belgium

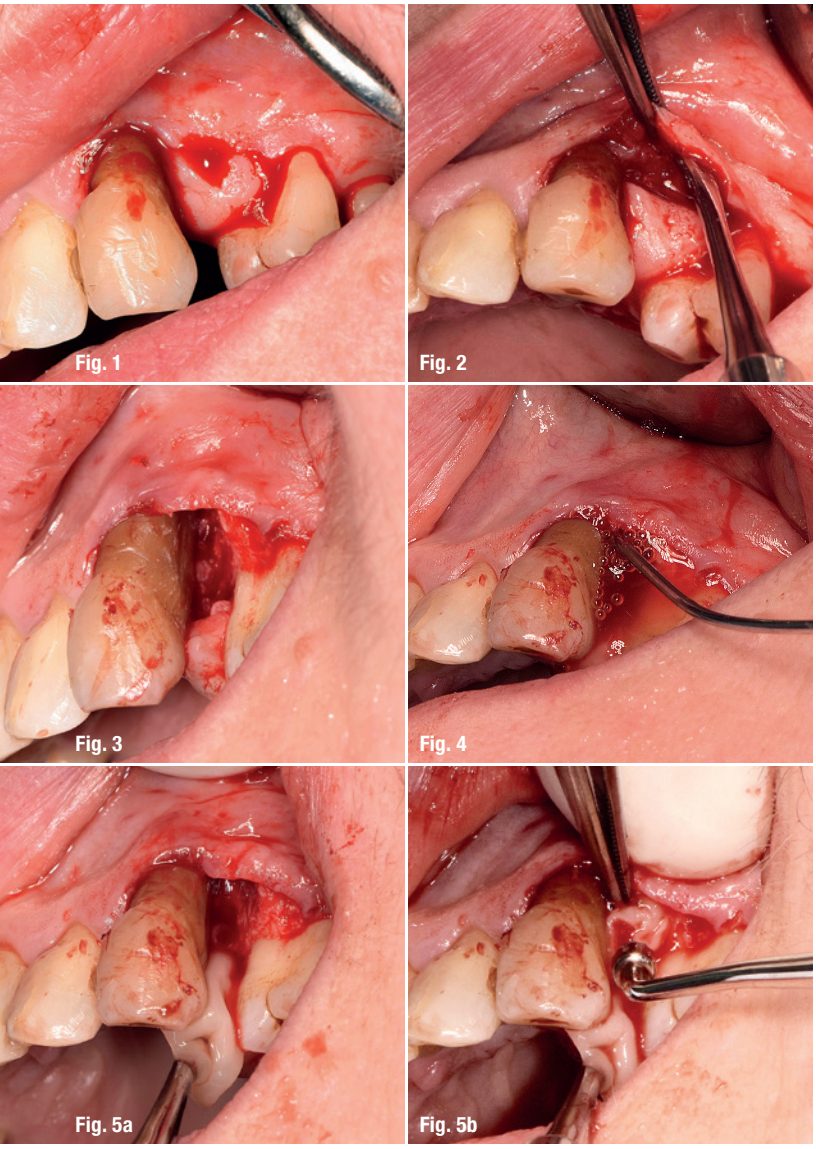

Fig. 1: Intrasulcular incision with papilla preservation. **Fig. 2:** Minimal flap elevation (palatally pediculated). **Fig. 3:** Defect after root planing. **Fig. 4:** Rinsing intrabony defect with L-PRF exudate. **Figs. 5a & b:** Application of chopped L-PRF membranes into the defect (preferably face side towards the bone).

Recent research clearly indicates that wound healing in both soft and hard tissue can be significantly enhanced by L-PRF (leukocyte- and platelet-rich fibrin). This second generation of platelet concentrates may even have the potential to replace substitutes like growth factors and biomaterials in many situations. A further benefit is its easy and inexpensive preparation, lowering the treatment cost also for the patient.

Major indications for the use of L-PRF and the step-by-step preparation of L-PRF clots, membranes and plugs were introduced in the first part of this article series in *implants 1/18*.

In this second part, two treatment approaches for platelet concentrate protocols will be presented. The focus will be on L-PRF application in the regeneration of intrabony defects during open-flap debridement and in ridge preservation.

L-PRF in treatment of periodontal and/or bone defects

The use of L-PRF in the treatment of periodontal and/or bone defects can be described as natural tissue regeneration and natural bone regeneration, by analogy to guided tissue regeneration and guided bone regeneration. With natural tissue regeneration and natural bone regeneration the defect is filled with L-PRF—optionally combined with a biomaterial, to prevent collapse—and sealed with L-PRF membranes. These membranes have a protective function (induction of the periosteum) and serve as a competitive barrier. Epithelium and connective tissue are kept away from the intrabony crater so that the cells of the periodontal ligament or periosteum have the time to regenerate cementum, bone and ligament. These cells can also migrate through the membranes, which results in rapid neo-angiogenesis. L-PRF also promotes the proliferation and differentiation of osteoblasts and bone marrow stromal cells *in vitro*.

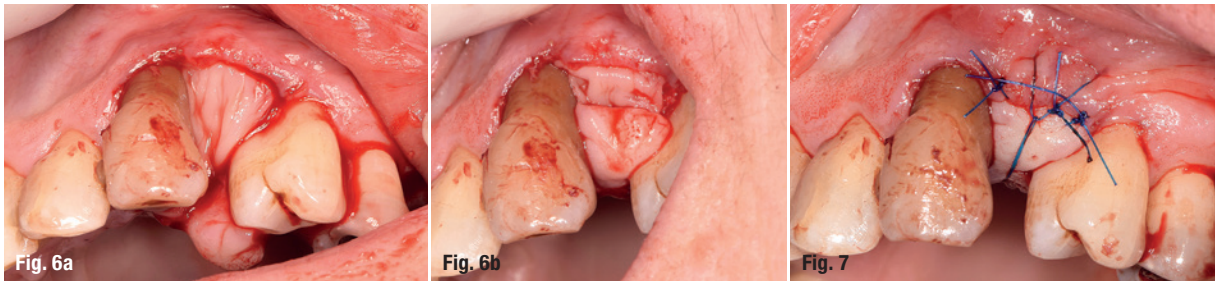

Figs. 6a & b: Coverage of bony defect with two or more layers of L-PRF membranes. **Fig. 7:** Tension-free flap suturing, preferably with primary closure of the interdental papilla.

This stimulation appears to be dose-dependent with leucocytes playing a key role.[1]

A series of clinical studies has evaluated the benefits of applying L-PRF alone during open-flap debridement.[2] They all reported an adjunctive improvement when L-PRF was used, on parameters like probing pocket depth reduction (1.1 ± 0.5 mm extra reduction), clinical attachment gain (1.2 ± 0.6 mm extra gain) and bone defect fill (1.5 ± 0.3 mm or 46 ± 12.8 % extra bone fill).[2]

In some studies, L-PRF was combined with a bone substitute, and even here an additional benefit could be observed.[2] When L-PRF was compared with enamel matrix proteins, similar improvements were reported.[2]

Step-by-step approach for regenerative treatment of intrabony defects with L-PRF

Protocol for L-PRF as sole biomaterial for intrabony defect regeneration during open-flap debridement

- Intrasulcular incision with maximal preservation of gingival complex (Fig. 1).
- Minimal flap elevation and degranulation of intrabony defects (Fig. 2).
- Optimal root planing (Fig. 3).

- Rinsing defect with L-PRF exudate (collected at the bottom of the Xpression box [Intra-Lock International] after compressing the clot; Fig. 4).
- Application of an L-PRF membrane (or only a part of it) into the defect (preferably with the face part of the membrane pointing towards the bone; Figs. 5a & b).
- Coverage of the bone defect with approximately two layers of L-PRF membranes, running ≥ 2 mm over the bony borders underneath the periosteum in order to seal the socket and to force the soft tissue to grow over instead of underneath the membranes (Figs. 6a & b).
- Tension-free flap suturing in seeking to provide primary closure of the interdental papilla (Figs. 7 & 8).

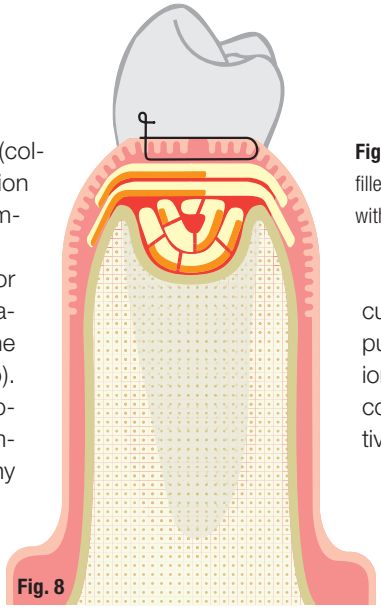

Fig. 8: Graphic representation of an intrabony defect filled with chopped L-PRF membrane parts and covered with L-PRF membranes. Primary closure is not required.

Postoperative care
- Soft food intake, no biting/chewing in treated area, no mechanical cleaning of the treated area,
- 0.12 % chlorhexidine twice a day for one minute for at least three weeks,
- medication with painkillers, as necessary.

L-PRF for ridge preservation

After tooth extraction and loss of the bundle bone, the alveolar ridge undergoes a remodelling process in both vertical and horizontal directions. This process often complicates the placement of implants in an ideal position. In recent years, many surgical techniques have been developed to prevent, or at least minimise, this bone resorption.

Different bone grafts or bone substitutes have been developed to be used in extraction sockets, with or without the addition of a soft-tissue graft or soft-tissue substitute to seal the alveolus. A recent systematic review by Vignoletti et al., however, concluded that there is no clear guideline currently on which technique to use for this purpose.[3] According to the authors' opinion the use of L-PRF in extraction sockets could be a less costly, simplified and effective treatment alternative.

A recent split-mouth comparison between natural healing of extraction sockets and sockets filled with L-PRF in 22 patients confirmed the above mentioned benefits with significant less horizontal and vertical resorption, increased socket fill, higher bone quality and faster soft-tissue and bone healing.[4] This was reported even at sites with bone dehiscences.[4] The observed reduction in bone resorption was comparable to the best-performing clinical procedures using bone substitutes in combination with connective tissue grafting and/or the placement of a membrane.[4]

Step-by-step approach for ridge preservation with L-PRF

In this approach, L-PRF is used as a filling material for a tooth socket, aiming at maintaining the alveolar bone dimensions (Figs. 9a & b).

Protocol for ridge preservation with L-PRF
- Atraumatic tooth extraction with maximal preservation of the alveolar bone.
- Accurate removal of inflamed and granulation tissue (if needed with a bur; Fig. 10).
- Preparation of envelope (approx. 2 mm in width) between bony borders of the socket and surrounding soft tissue needed to slide in the L-PRF membranes at the end in order to prevent the fast ingrowth of connec-

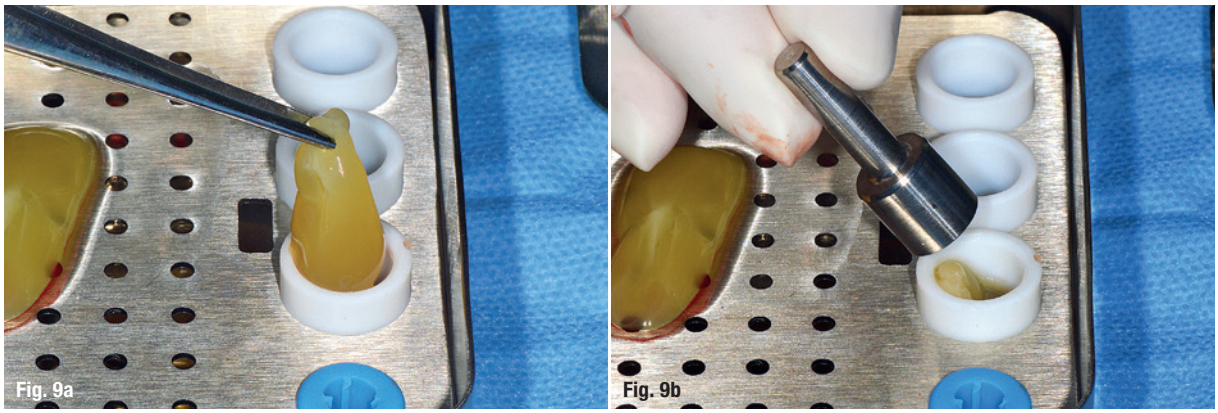

Figs. 9a & b: Preparation of L-PRF plugs with Xpression kit.

Aadva™

GC Implants: Quality derived from tradition

GC

www.gctech.eu

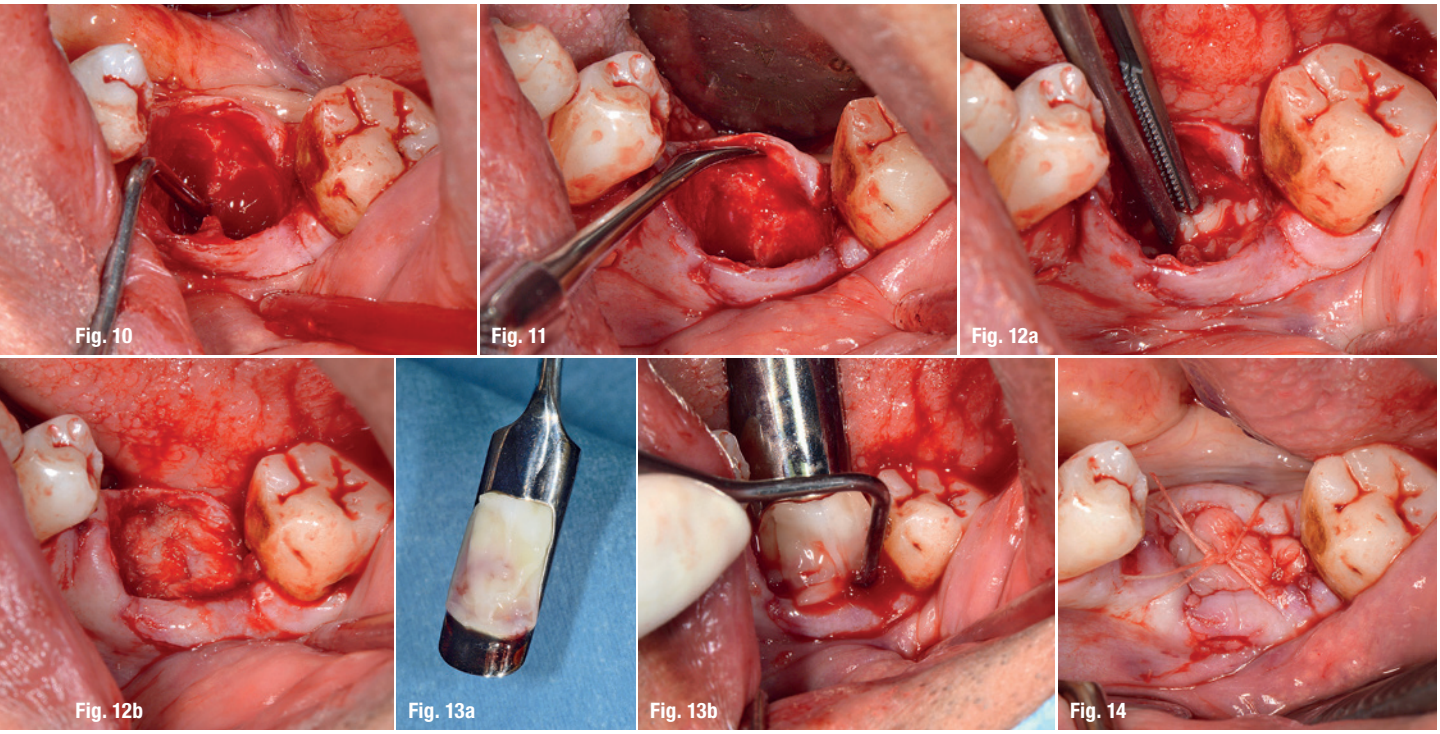

Fig. 10: Accurate removal of all inflamed and granulation tissue. **Fig. 11:** Envelope preparation (approx. 2 mm in width) between bony borders of the socket and surrounding soft tissue. **Figs. 12a & b:** One-by-one placement of L-PRF plugs/membranes into the socket and vigorous compression. **Figs. 13a & b:** Coverage of socket with at least a double layer of L-PRF membranes (sliding borders of membranes into prepared envelope). **Fig. 14:** Tension-free suturing with, for example, a modified internal or external mattress technique, primary closure is not required.

tive tissue and to force the epithelium to grow over the membranes (Fig. 11).

- If applicable, L-PRF exudate (aspirated into a sterile syringe), obtained after compression of clots, is used to irrigate and clean the socket.
- Placement of three to five L-PRF plugs/membranes into the socket one by one, compressing vigorously with the amalgam condenser and absorption of superfluous serum with a gauze (Figs. 12a & b).
- Coverage of the socket with at least a double layer of L-PRF membranes with their margins slid between soft and hard tissue around the socket (envelope) to seal the socket and to prevent epithelial infiltration (Figs. 13a & b).
  - Suturing with, for example, a modified internal or external mattress technique, not with the intention to close the wound, but to keep the membranes in place without tension. Sutures have to be supported by alveolar bone in order to prevent the L-PRF from being pushed out (Figs. 14 & 15).

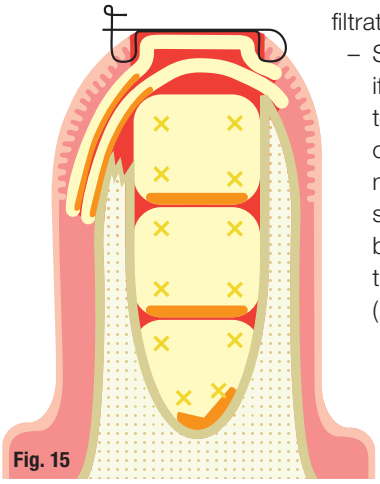

Fig. 15: Graphic representation of an extraction socket filled with L-PRF plugs/membranes and sealed with two layers of L-PRF membranes.

Postoperative care

- No use of chlorhexidine during the first two days, in order not to disturb initial soft-tissue healing.

Editorial note: The third part of this article will be published in implants 3/18 and cover application approaches for sinus floor elevation.

Further information on the topic can be obtained during the 2nd European Meeting on Enhanced Natural Healing in Dentistry in Leuven, Belgium, from 7 to 9 September. Further details can be found at: www.enhd2018.be.

Literature

contact

Prof. Dr Marc Quirynen
University Hospitals Leuven
Periodontology & Oral Microbiology
Kapucijnenvoer 7 blok a – box 7001
3000 Leuven, Belgium
Tel.: +32 163 32483
marc.quirynen@kuleuven.be

Author details



Astra Tech Implant System®

Our world is not flat

Neither is the anatomy of your implant patients

Your world is already full of clinical challenges so why work harder because of conventional thinking? Instead of augmenting sloped ridges to accommodate flat-top implants, it's time to discover a simpler solution by using an implant that follows the bone. Because sloped-ridge situations call for anatomically designed sloped implants.

OsseoSpeed® Profile EV – It's time to challenge conventional thinking

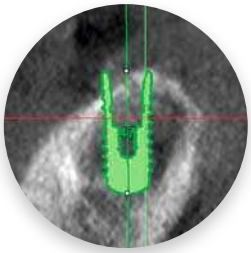

Conventional vs innovative approach

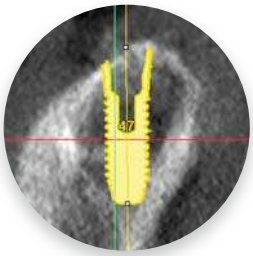

www.profiledentalimplants.com

Dentsply Sirona Implants