Full-arch implant rehabilitation

Dr David García Baeza, Spain

Introduction

An implant-supported restoration is a good alternative to conventional complete prostheses for patients with edentulism. This treatment has been performed successfully in recent years and constitutes a high-value clinical reality.

Oral implantology has undergone great advances in recent years, as it allows lost teeth to be replaced with a high degree of satisfaction on the functional and aesthetic level. A partial or total loss of teeth affects not only facial aesthetics but also vital functions, like chewing and phonation. A prosthodontic rehabilitation with a high success rate can be obtained for this type of patient. The prosthetic options for rehabilitating an edentulous patient with dental implants are divided into two categories: fixed and removable restorations.[1]

Fig. 1: Frontal view of the initial patient situation. **Fig. 2:** Intraoral view of the initial situation.

A hybrid prosthesis consists of a cast metal framework covered by acrylic, which supports artificial fixed teeth. The original design of the hybrid prosthesis (fixed-removable) was developed by Swedish researchers using the two-stage endosseous implant system developed by Per-Ingvar Brånemark. The prosthesis consisted of a gold alloy framework attached to the copings of the implants, and on this framework conventional acrylic resin denture teeth were secured with acrylic resin.[2]

The factors that determine the type of implant-supported restoration for a completely edentulous patient are the amount of space from the bone to the occlusal plane (prosthetic space) and the lip support. The prosthetic space needed for a hybrid prosthesis is a minimum of 11 mm and a maximum of 15 mm, with lip support given by the bone structures. When a space of 10 mm or less is available and there is lip support, a porcelain-to-metal restoration is suggested. When there is more than 15 mm of prosthetic space and absence of lip support, a type of implant-supported overdenture restoration is recommended, which will give the lip support not provided by the bony structures of the patient.[1] Cox and Zarb described the treatment of severely resorbed completely edentulous maxillae with a hybrid prosthesis using a metallic structure with acrylic and artificial teeth, with prosthetic spaces larger than 15 mm.[3]

An incorrect adaptation between metal structures and implants can cause bone loss and failure of osseointegration, which is clinically decisive. It is generally accepted in the literature that the passive fit of a prosthesis is required for maintenance and long-term success of an implant treatment. In addition, the literature has implied that incorrect adaptation of metal structures is a decisive and significant factor, causing mechanical and biological complications. The loosening of both the prosthesis and the abutment screws and even the fracture of various system components have been attributed to the lack of adjustment and adaptation of the prosthesis.

In this article, the clinical case of a patient with a completely edentulous maxilla and advanced periodontal dis-

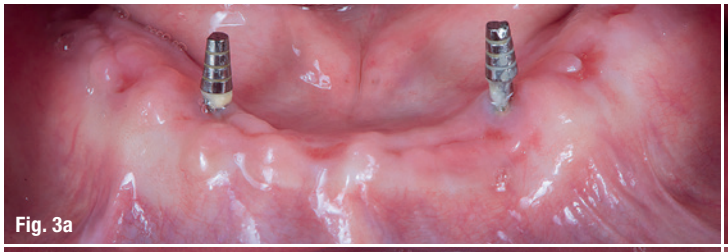
Fig. 3a

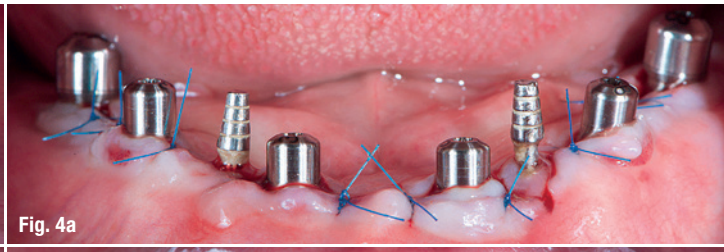
Fig. 4a

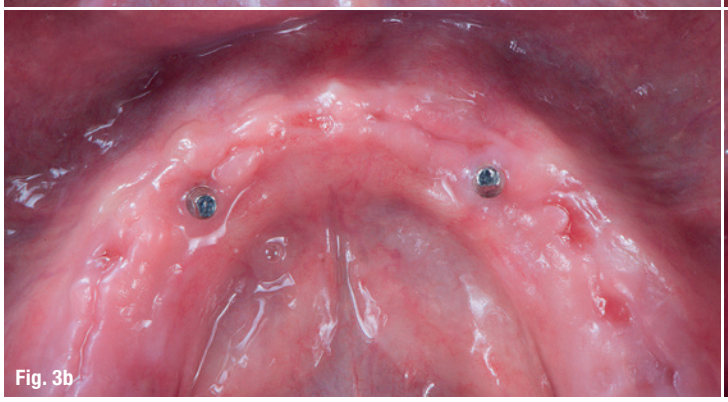
Fig. 3b

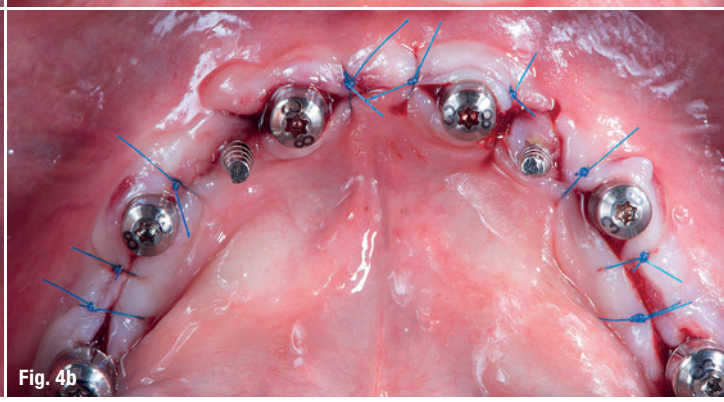
Fig. 4b

Figs. 3a & b: After extractions: **a)** Frontal and **b)** occlusal view. **Figs. 4a & b:** Healing abutments: **a)** Frontal and **b)** occlusal view.

ease in the mandible is presented. The patient's mandible was rehabilitated with a hybrid prosthesis on six implants. The implant-supported prosthetic treatment that was performed to restore the patient's aesthetics and functionality, thereby improving his quality of life, is described step by step, as is the preparation process of the prosthesis.

Case presentation

A 68-year-old patient presented to our facility with a complete maxillary mucosa-supported denture, with which he was relatively comfortable. He had all of his original teeth on the lower arch, but with very advanced periodontal disease, which had caused him a loss of support of more than 80 per cent. These teeth presented with Class II and III mobility, which made it very difficult to chew (Figs. 1 & 2).

The proposed treatment plan for the patient was to extract the mandibular teeth and rehabilitate the lower arch using implants and a fixed prosthesis to maintain the same feeling as with his natural teeth. In addition, it was decided to replace the complete denture of the upper arch.

Normally, when teeth are extracted from a complete arch and an immediate restoration is placed, it creates a problem of adaptation for the patient, especially in the mandibular area. To help the patient during this period of healing and osseointegration of the implants, it is recommended to place two provisional implants.


Fig. 5


Fig. 6

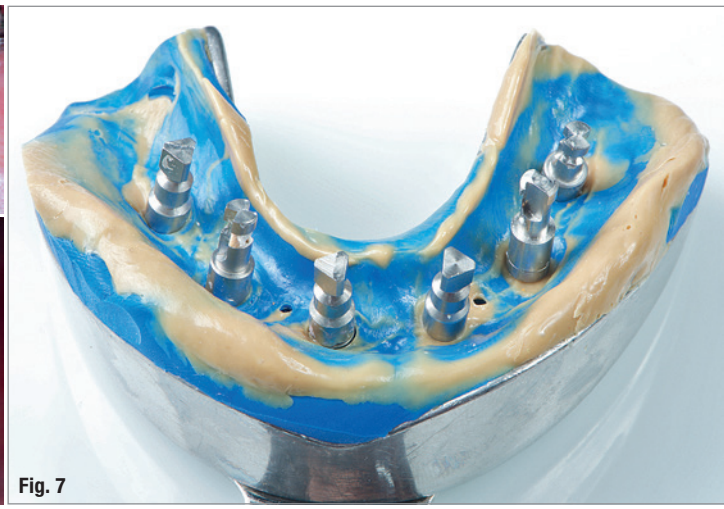
Fig. 7

Fig. 5: SR Abutments at gingival level. **Fig. 6:** Impression taking with closed-tray copings. **Fig. 7:** Preliminary impression.

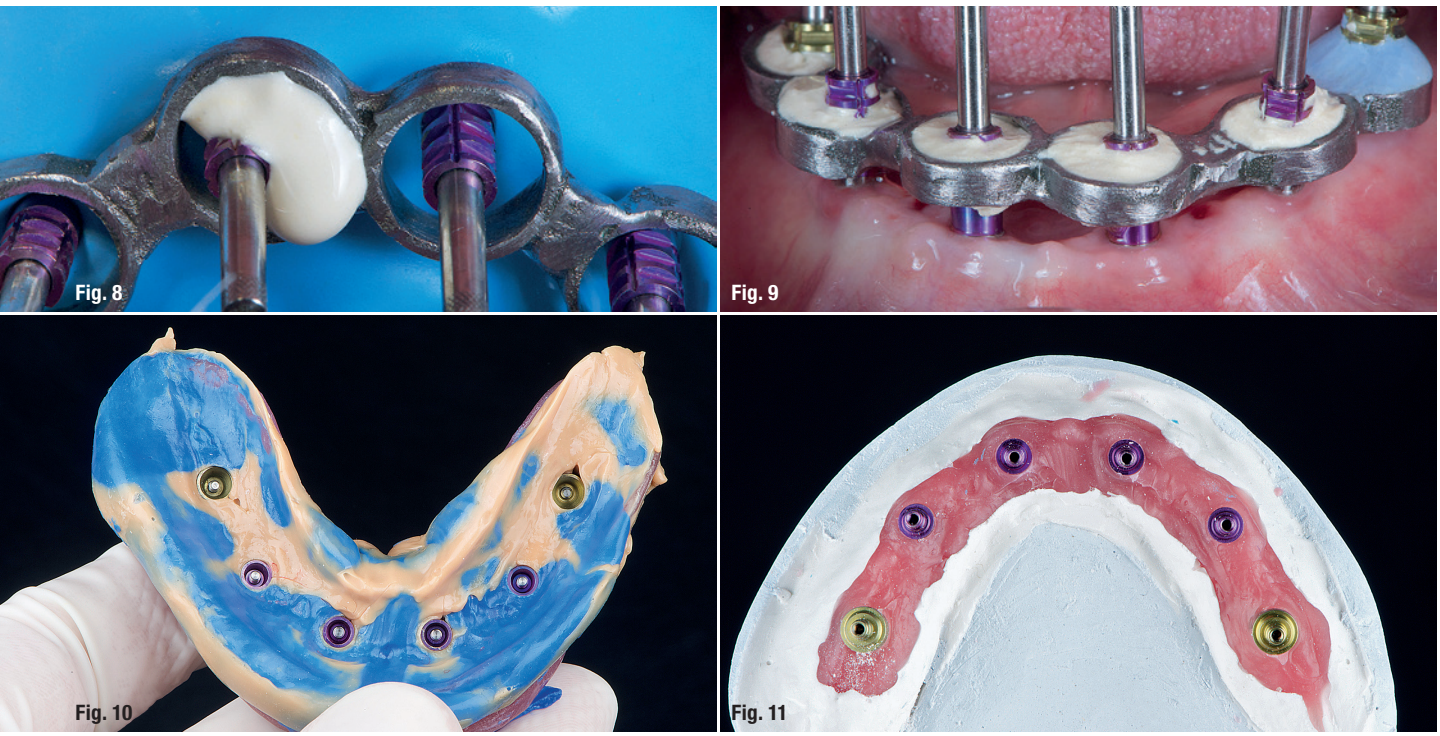

Fig. 8: Rigid metal tray impression taking: Fixing with plaster. **Fig. 9:** First step of final impression taking. **Fig. 10:** Final impression. **Fig. 11:** Master model.

Once the extractions had healed, six Aadva tapered implants (GC Tech.Europe) of 4 mm in diameter and 10 mm in length were placed in the position of the molars, first premolars and central incisors (Figs. 3a & b). The bone quality and quantity were good, and once the expected osseointegration time had passed, transitional abutments were placed. In this case, two abutment diameters were used, narrower (SR Abutment of 3.8 x 2.0 mm, GC Tech.Europe) for the incisal and premolar areas, where there was less inserted gingival tissue, and wider (SR Abutment of 4.3 x 2.0 mm) in the posterior area (Figs. 4 & 5).

Before beginning with the prosthetic phase, there was a waiting period for the tissue to mature. For this, an impression was taken with closed-tray copings, which is very simple, but does not give a very exact model (Figs. 6 & 7). This was subsequently used to make a rigid impression tray that was made of metal and was secured with plaster to only one of the implants (Fig. 8).

Once the rigid impression tray was placed in the mouth, open-tray copings were then used and they were splinted to the structure with a special plaster mixture; once this had hardened, everything was registered with

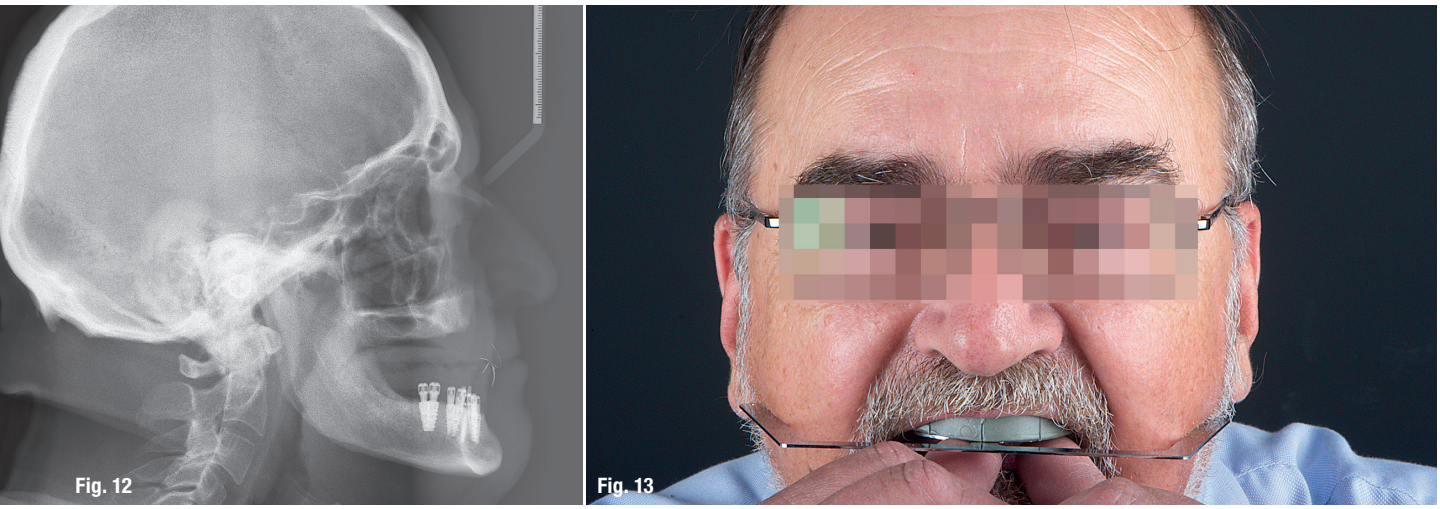

Fig. 12: Lateral radiograph taken with lead foil on the old denture for radiographic evaluation. **Fig. 13:** Fox plane test.

a polyvinylsiloxane impression (Figs. 9 & 10). This technique yields a very reliable master cast, ensuring a very good structure fit (Fig. 11).

Once the final model with the different analogues was ready, the planning started. First, the old complete maxillary denture was analysed. In this type of case, it is very useful to perform a lateral analysis, thus photographs and radiographs were taken. A step that differentiates our technique from other dentists' is that a narrow lead foil strip is placed on the maxillary and mandibular central incisors. This provides extra information to see the relationship between the position of the anterior teeth and the bone (Fig. 12).

With the lateral radiographs, the situation of the transitional abutments can be visualised, which is very important, as all the manipulation based on the different tests that need to be done will be carried out far from the head of the implant.

Once the fulcrum points and the inclination of the maxillary incisors for lip support had been analysed, the new upper arch was designed in order to give the patient a new occlusal plane and a new incisal position. The Fox plane helped us to obtain the correct plane and then we used the Kois Bow for the cranial-maxillary reference (Fig. 13).

Once the models had been placed in the articulator and the parameters taken from the patient, the laboratory technician began to make a set of test teeth from wax for both the upper and lower arches so that the correct fit could be assessed, including the patient's occlusion and aesthetics (Figs. 14 & 15).

As Figures 16 to 19 show, the upper arch was narrower than the lower one because those teeth were lost much earlier, which meant that, for correct functioning of the complete maxillary prosthesis while chewing, the posterior areas were to be placed at a crossbite. That way, the axis of force when chewing food would fall on the alveolar process and not displace the prosthesis.

Once confirmed that everything worked properly, the next step was constructing the metal structure that would be closely linked to the wax tooth design (Figs. 20 & 21). This was once again checked with the teeth in position to give a last confirmation before the final manufacturing. At that time, confirmation of the modifications made could be carried out again by using the lead foil strip, as well as confirmation of the occlusion, in case there was any variation (Fig. 22).

Subsequently, the final prostheses were made. The maxillary one was made as wide as possible in the posterior area so that it would be as stable as possible, and the mandibular one was placed on implants. Confirmation and small adjustments had to be performed in the mouth to counterbalance the small misalignments that normally occur in manufacturing (Figs. 23–25).

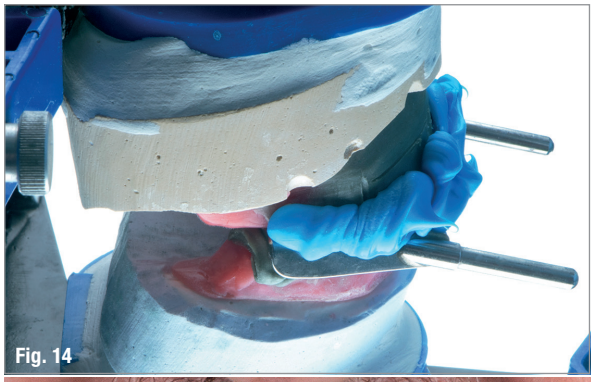

Fig. 14: Panadent articulator phase. **Fig. 15:** Wax test confirming smile parameters. **Figs. 16a–c:** Wax try-in: **a)** Left, **b)** right and **c)** frontal view.

Discussion

The treatment of a completely edentulous patient with an oral restoration on implants begins by discussing treatment expectations, followed by an accurate clinical

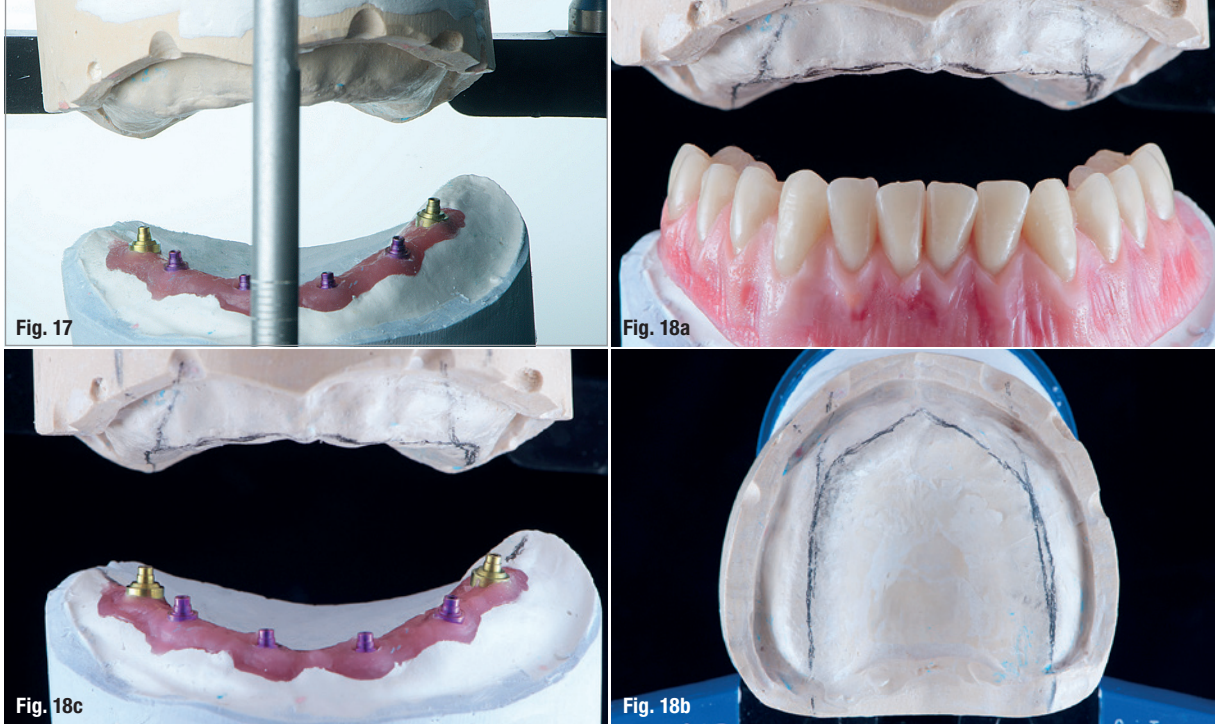

Fig. 17: Models in final position. **Figs. 18a–c:** Models in the articulator.

evaluation. Thus, a detailed intraoral and extraoral examination are performed following a work plan to help in the diagnosis. This includes studying patient photographs and radiographs, which have evolved remarkably in recent times, using models on a semi-adjustable articulator and following the protocol for the design of a proper prosthetic restoration on implants, choosing from overdentures, or hybrid or fixed prostheses. The choice will depend on what the dentist plans using a multifunctional guide—tomographic/surgical/prosthetic—for implant placement and a suitable type of oral restoration.

Rehabilitation with implant-supported hybrid prostheses is a fixed treatment in completely edentulous jaws where the prosthetic space is 11 mm or 15 mm,[3] but where the need for lip support for prosthetic restoration is not a determining factor.[4] An implant-supported hybrid prosthesis can be a questionable alternative treatment when a fixed restoration of porcelain and metal does not meet the patient's requirements for aesthetics, good phonetics, proper oral hygiene and oral comfort.[5,6]

Bidra and Agar proposed a classification system for edentulous patients for using implant-supported fixed prostheses, classifying them into four classes according to the following factors:

1. amount of tissue loss;
2. position of the anterior teeth in relation to the location of the residual ridge;
3. lip support;
4. smile line; and
5. need for prosthetic material for gingival colouring (pink acrylic).[4]

Class I includes patients who require gingiva-coloured prosthetic material such as pink acrylic to obtain aesthetic tooth proportions and optimal prosthetic contouring to attain adequate lip support. Class II patients require pink acrylic only to obtain aesthetic tooth proportions and for prosthetic contouring. Lip support is not a consideration, since the difference in lip projection with or without any prosthesis is generally insignificant. Class III contains patients who do not require gin-

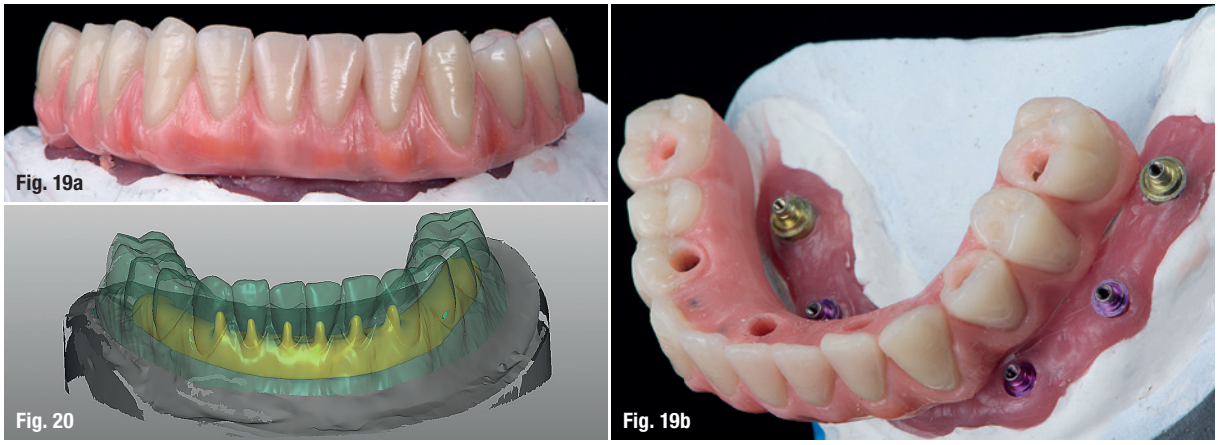

Figs. 19a & b: Final wax test. **Fig. 20:** Aadva software: Structural design.

Fig. 21: Anterior view, final test. **Fig. 22:** Lead foil test for the new design. **Figs. 23a & b:** Final restorations: **a)** Lateral and **b)** frontal view. **Fig. 24:** Final smile. **Fig. 25:** Final restoration.

giva-coloured prosthetic material. Class IV is assigned to patients who may or may not require pink acrylic, depending on the result obtained after surgical intervention.[4] Following this classification, the patient in this report was determined as Class II.

The fabrication of hybrid dentures in patients with adequate interocclusal space provides the dentist with several advantages regarding the aesthetic appearance, including replacement and decrease of soft-tissue support owing to the bulkiness of the metal substructure and in the height of crowns compared with a metal-supported porcelain prosthesis. In addition to these aesthetic advantages, hybrid prostheses work as shock absorbers, reducing load forces on implants.[7]

The success rate of implant-supported hybrid prosthetic treatments is high, as demonstrated by a systematic review published in 2014, which included 18 studies for evaluation. In a period of five to ten years, high survival rates of 93.3–100 per cent for the prostheses and of 87.9–100 per cent for the implants were found.[8]

In a retrospective study evaluating the main complications after rehabilitation with an implant-supported hybrid prosthesis, it was observed that the main complication was mucositis, which affected 24 per cent of the cases, followed by problems with the prosthetic screws in 13.7 per cent of the cases, including thread wear or loss, and the same percentage was found for fracture of the prosthetic teeth or prosthesis detachment. These problems were related to an incorrect record of vertical dimension, inadequate occlusion or a lack of passive fit of the metallic structure. Another problem encountered concerned the access to the entrance holes of the prosthetic screws (7.8 per cent).[9]

Conclusion

A lower jaw hybrid restoration is a good option for the rehabilitation of an edentulous mandible, and it should be included in the treatment options when evaluating a patient, as it improves aesthetics, functionality and proprioception. It is furthermore easy to clean, requires less prosthetic maintenance, and can be removed at any time and repaired at a very low cost.

Literature

contact

Dr David García Baeza
CIMA private dental practice
Laguna Grande 4
28034 Madrid, Spain
clinica@cimadental.es

Author details