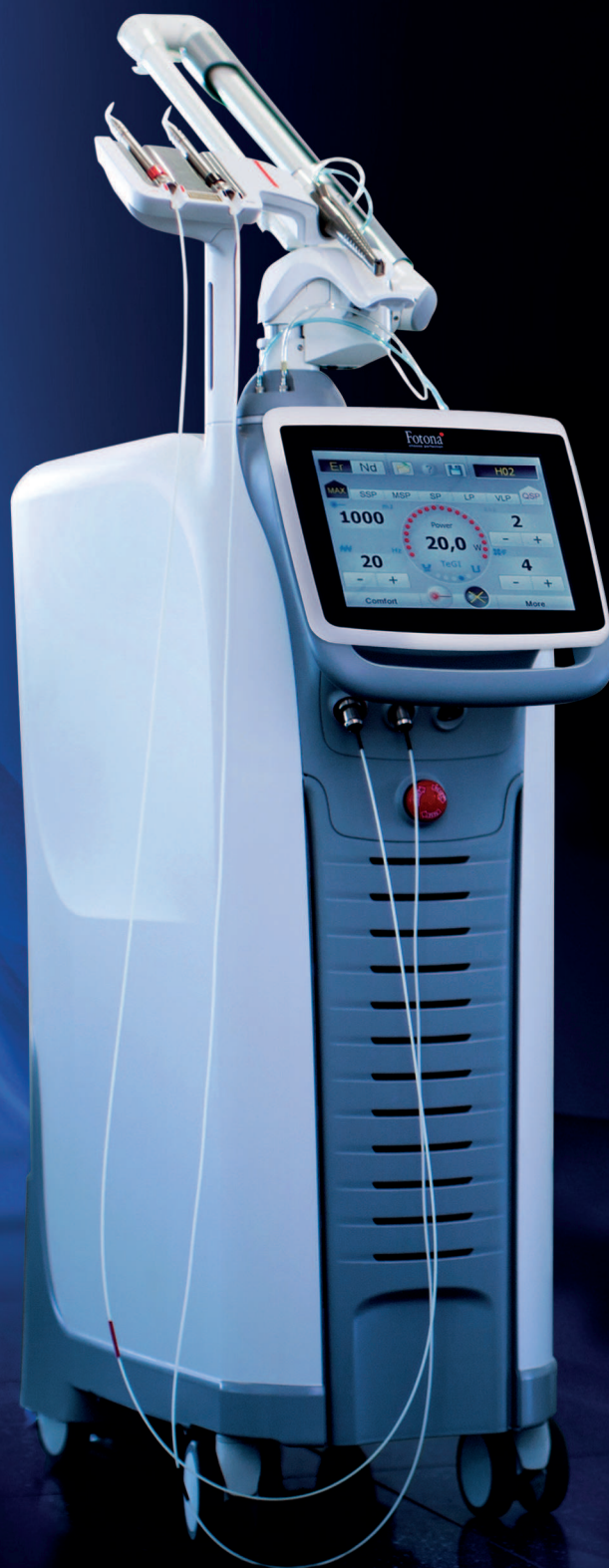

laser



international magazine of laser dentistry

4²⁰¹⁶



research

Blue light laser-assisted
crown lengthening

research

Thermal damage behaviour
dental pulp stem cells

case report

Haemostasis in oral soft
tissue and extraction socket

damus



Master of Science (M.Sc.) in Laser in Dentistry

Next Start: **16th October 2017** | Aachen, Germany | 4 semesters



Become part of the International Dental Elite

- Create new economic potential for your practice
- Two year career-accompanying postgraduate programme at the University of Excellence RWTH Aachen
- Combination of lectures, skill training sessions, live ops, tutorials, and practical workshops
- Internationally accepted and accredited by the German Government, the European Union, the Washington Accord and the Bologna Process
- Science-based and practice-orientated on highest national and international level
- Increased patient satisfaction: minimal contact reduced vibration and pain

**RWTH INTERNATIONAL
ACADEMY
AACHEN UNIVERSITY**

RWTH International Academy
Kackertstraße 10 | 52072 Aachen | Germany
phone +49 241 80 23543 | fax +49 241 80 92525
info@academy.rwth-aachen.de
www.academy.rwth-aachen.de

AALZ

Aachen Dental Laser Center

AALZ GmbH
Pauwelsstraße 17 | 52074 Aachen | Germany
phone +49 241 47 57 13 10 | fax +49 241 47 57 13 29
info@aalz.de
www.aalz.de



PROFESSIONAL EDUCATION PROGRAMMES

Your contact for more information: Leon Vanweersch • vanweersch@aalz.de - www.aalz.de



Prof. Dr Norbert Gutknecht

Review & outlook

Dear colleagues,
Dear laser society members,
Dear friends of laser technology,

With this year's last issue of *laser international magazine of laser dentistry*, I would like give a brief summary of the most important events in 2016. Without a doubt, this year's highlight was the WFLD World Congress in Japan with Prof. Kenjy Yoshida as the scientific head. Both scientists from various colleagues and laser users from the dental practice met here in order to discuss the latest research results, therapy concepts and practical experiences.

What took the international stage in Japan was transferred to many smaller venues in various countries around the world. All these events illustrated how new wavelengths have been introduced to dentistry and, moreover, how the already established lasers systems can be applied in new therapeutic fields.

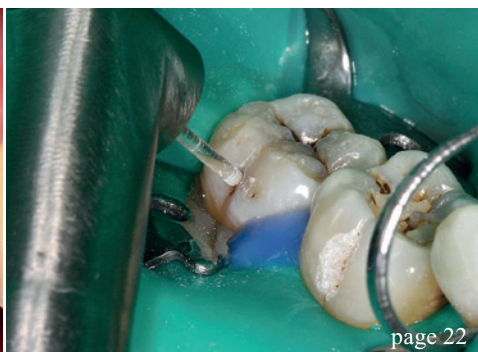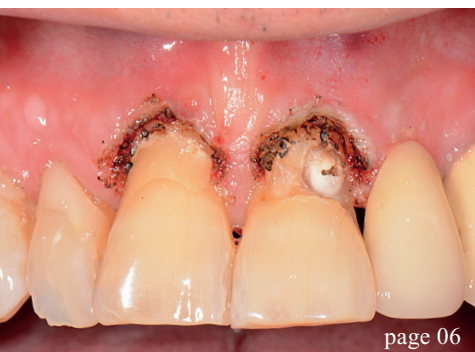With respect to 2017, I am looking forward to seeing which technical innovations from the field of laser technology will be introduced to the market at IDS (International Dental Show, Cologne, Germany).

In the meantime, the old year will come to an end and a new year is going to start, which is why I would like to send you my best wishes for 2017.

In addition, I would like wish all readers of *laser international magazine of laser dentistry* celebrating Christmas peaceful and blessed Christmas Holidays.

Yours,

Prof. Dr Norbert Gutknecht



| editorial

- 03 Review & **outlook**
Prof. Dr Norbert Gutknecht

| research

- 06 **Blue light** laser-assisted crown lengthening in **restorative dentistry**
Prof. Dr Matthias Frentzen *et al.*
- 10 **Thermal** damage behaviour of **human dental** pulp stem cells
Prof. Dr Karsten König & Dr Anton Kasenbacher

| case report

- 16 A variety of **photocoagulation** techniques
Sajee Sattayut *et al.*

| industry

- 22 Er:YAG **caries** treatment according to **minimally invasive** therapy
Swietłana Kozaczuk & Kinga Grzech-Leśniak
- 26 An **all-rounder** with three wavelengths
Dr Talat Qadri

| practice management

- 30 Eleven **tips for success** in your dental clinic
Dr Anna Maria Yiannikos
- 32 **Lasers** as an **asset** in both daily **practice** and **marketing**
Dr Imneet Madan

| events

- 36 **25th International Annual DGL Congress**
Dr Georg Bach

| news


- 40 **manufacturer news**
- 41 **news** international

| DGL

- 43 Rückblick & **Ausblick**
Prof. Dr. Norbert Gutknecht
- 44 **Abstracts zur 25. Internationalen Jahrestagung der DGL**

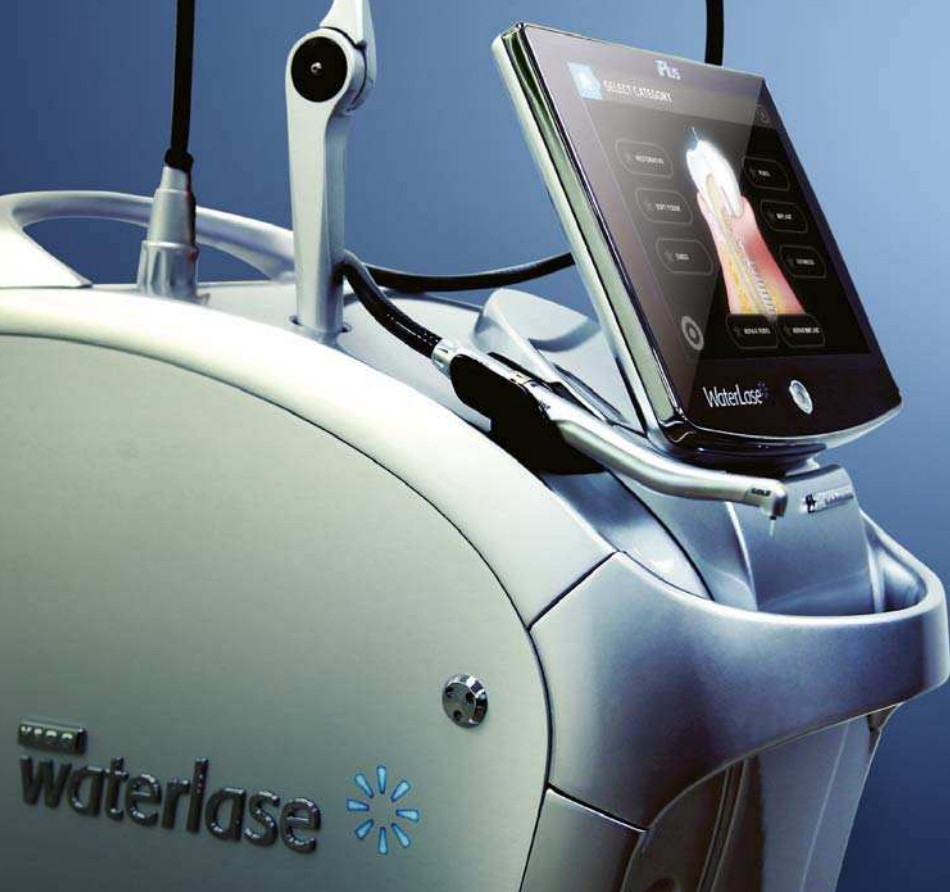| about the publisher

- 50 Imprint



Cover image courtesy of Henry Schein Dental
www.henryschein-dental.de
Original Background: © keren-seg/Shutterstock.com

Trade Up to Waterlase iPlus and Epic 10



Limited time offer!
**Trade in your old diode or all-tissue laser
towards a Waterlase iPlus or Epic 10.***

SURGERY, WHITENING AND PAIN RELIEF ...ALL AT YOUR FINGERTIPS

- ✦ Faster treatment and healing
- ✦ Easy to use
- ✦ Exceptional value and ROI
- ✦ Clinical versatility for complete patient care
- ✦ Portable for easy transport
- ✦ ComfortPulse™ modes for the ultimate patient comfort



THE WORLD'S MOST TRUSTED ALL-TISSUE LASER

- ✦ Cut Hard-Tissue 250% Faster with Less Sensitivity¹
- ✦ World's first turnkey apps to assist in the management of periodontitis and peri-implantitis
- ✦ Unrivalled versatility, providing unmatched results in treatment outcomes and outstanding ROI
- ✦ Open a new world of clinical capabilities with the most intuitive and easy-to-use graphic user interface
- ✦ SureFire™ Delivery System, ergonomically designed for enhanced flexibility, increased precision, and maximum uptime
- ✦ ComfortPulse™ modes for the ultimate patient comfort

WaterlaseiPlus***



BIOLASE

biolase.com

Contact your BIOLASE Authorised Distributor to learn how you can upgrade your practice to Waterlase or Epic Dentistry. Visit go.biolase.com/contact

© 2016 BIOLASE, Inc. All rights reserved.

*Trade-in programme available for a limited time. Epic 10 availability will vary by country. ¹ Data on file.

Blue light laser-assisted crown lengthening in restorative dentistry

Authors: Dr Philipp Skora, Dr Dominik Kraus, PD Dr Jörg Meister & Prof. Dr Matthias Frentzen, Germany

Abstract

Basic investigations of the laser-tissue interaction of a new type of laser device with a wavelength of 445 nm—the blue light spectrum—promise considerable advantages in comparison with infrared laser systems due to the known optical parameters of oral soft tissue. The procedure for a comprehensive laser-based gingivectomy before restorative treatment using this new type of laser is presented in the following case report. Due to the outstanding haemostasis with the blue light laser, both gingivectomy and adhesive filling treatment were possible in only one session. The follow-up examination showed the rapid healing of the wound with no complications and with no post-operative gingival recession. The treatment led to a very good aesthetic result at a moderate effort.

Figs. 1a–e: X-rays of the upper jaw.—Subgingival carious lesions at 11 and 21.

Introduction

Blue light-emitting diode lasers present an innovative alternative to the already established diode laser systems with wavelengths within the infrared spectrum. Due to the strong absorption of blue laser light in oral soft tissue¹, the cutting capacity is improved when comparable laser parameters are used. Blue light lasers have very powerful coagulation effects that enable blood-free work.² In addition, the high antimicrobial effect of blue light has been demonstrated in many fundamental studies.^{3,4} Due to these specific characteristics, blue light lasers are extremely suitable for corrective periodontal surgery in terms of gingivectomies. In contrast to electrosurgery, laser-assisted plastic-aesthetic periodontal surgical procedures do not cause problems of electro-magnetic interactions that could in turn present a contraindication in the

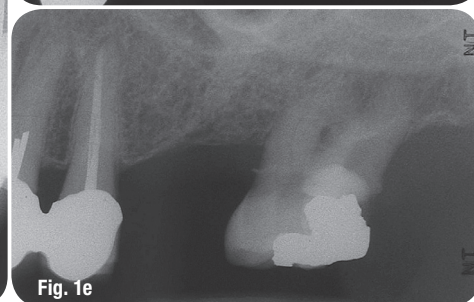
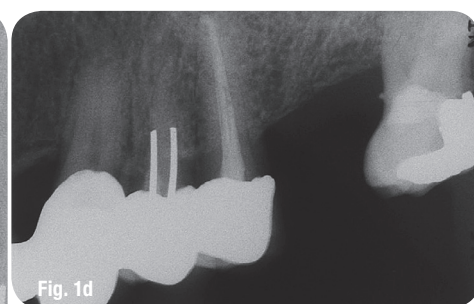
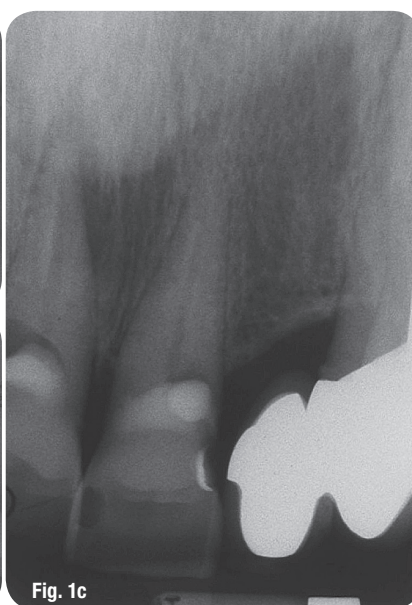
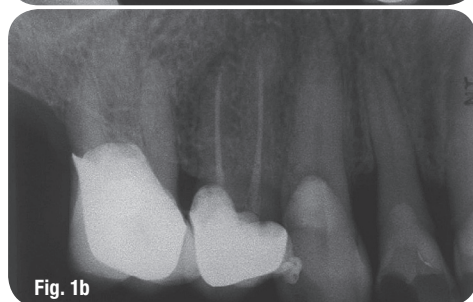
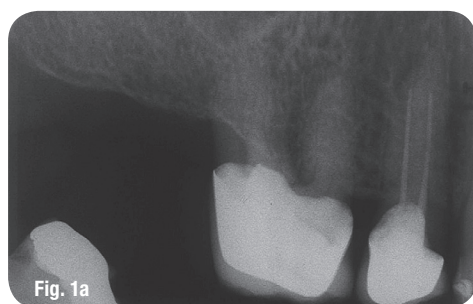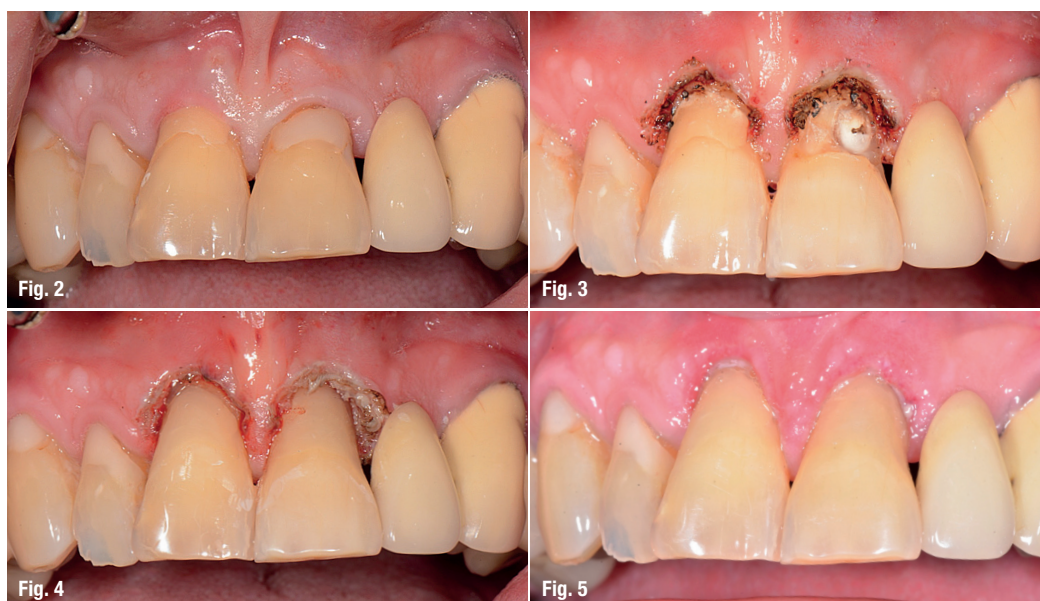




Fig. 2: Pre-operative situs.

Fig. 3: OP-situs after laser surgery (gingivectomy).

Fig. 4: Situation after adhesive composite restauration following laser surgery.

Fig. 5: Post-operative recall after 7 days.

case of patients with symptoms of cardiac disease. In the case of multimorbid patients who are frequently prescribed anticoagulants, the danger of secondary haemorrhage can be minimised. In addition, in these cases, a bloodless surgical field can be created ad hoc, so that moisture-sensitive restorative measures (adhesive dentistry) can be carried out.

In general, for multi-morbid patients it is important that restorative procedures can be carried out in a short time and that the use of anaesthetics should be reduced to a minimum. Excision wounds should heal in a short time period. A dry environment is advantageous, in particular when a dental rubber dam cannot be used.

In case of extended subgingival loss of dental hard tissue, e.g. as a result of carious defects, it is always necessary to enable a visual inspection of the preparation margin before the restoration can be placed. Furthermore, a bloodless, clean, and dry adhesive surface must be guaranteed before application of restorative material. Here, laser-assisted procedures provide a fundamental advantage in comparison to classical surgical procedures. Adequate haemostasis after soft tissue excision with the scalpel, scalers and cuvettes is often not achievable by styptics.

This case study presents a treatment protocol for restorative and endodontic treatment of patients with extensive subgingival carious lesions in the anterior tooth area.

Case report

A 72-year-old patient visited the Dental School of the University of Bonn to obtain a dental consultation regarding prostodontic aspects. The medical history was unremarkable. The patient did not suffer pain.

Among other things, insufficient composite restoration in the anterior tooth regions of the upper jaw were noticeable at the initial examination. In addition, subgingival probing showed defects in dental hard tissues at 11 and 21. For tooth 11, a fistula and an apical radiolucency were found in the vestibular marginal area in the X-ray image (Figs. 1a–e). Teeth 12 and 21 reacted positively to a sensitivity test, in contrast to tooth 11. The probing depths of the teeth 11 and 21 were 4–5 mm.

The treatment plan was explained thoroughly to the patient. In the first session, tooth 11 was trepanated as part of an emergency procedure. After exposure of the root canal, it was rinsed with NaOCl and calcium hydroxide was applied. Ahead of this emergency endodontic procedure, the carious lesions on 11 and 21 were excavated incompletely and treated temporarily with glass ionomer cement.

The patient came for further treatment five days later. The fistula on 11 had closed, clinical symptoms were no longer present (Fig. 2). After an infiltration anaesthesia (1.8 ml UDS), the subgingival carious defects in teeth 11 and 21 were visualised in a gingivectomy (Fig. 3). For both teeth, approximately 4 mm of soft tissue had to be removed to expose the affected area. The gingivectomy was carried out using a 445 nm diode laser (Sirona K-Laser blu, Sirona, Bensheim, Germany) with a power output of 1.5 W in cw mode and an application tip with a diameter of 320 µm. This device is a pre-serial model equivalent to SIROLaser Blue (Sirona, Bensheim). The resection was carried out in six minutes. The surgical procedure was performed with no pain. After finishing the gingival excision, the surgical field was bloodless and dry (Fig. 3), so that the temporary fillings at 11 and 21 could be removed and the caries completely excavated under visual control. The defects were treated with adhesive

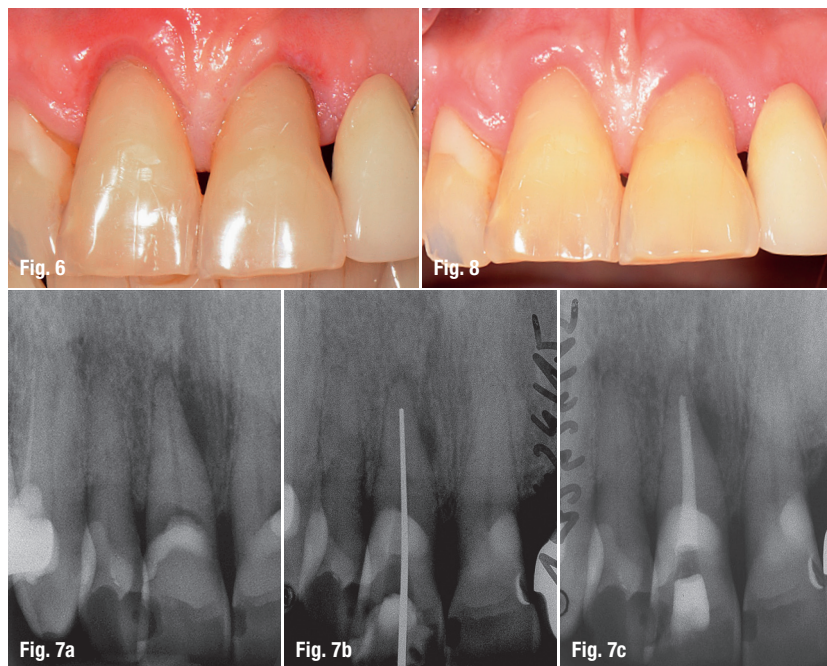


Fig. 6: Follow-up inspection after 14 days.

Figs. 7a–c: X-rays documentation of the endodontic treatment of 11.

Fig. 8: Post-operative recall after 3 months.—Healthy gums and aesthetic restoration of the carious lesions at 11 and 21.

restorations with a composite material in a multi-layer technique (Herculite®; A3,5). Figure 4 shows the situation after the restoration had been completed, including finishing and polishing of the aesthetically complex restoration. After laser treatment, haemostatic measures were no longer necessary for all subsequent treatment steps. In the post-operative recall after seven days (Fig. 5), the patient reported that there was no post-operative pain. After the procedure, the patient did not find it necessary to use the analgetics that had been made available.

After 14 days (Fig. 6), the excision wounds had healed to a very great extent. There was still slight redness in the marginal area. No swelling occurred in the entire post-operative phase. At this time, endodontic treatment was also performed for the devitalised tooth 11. After preparation and sealing of the root canal, the trepanation cavity was closed using a composite material (Figs. 7a–c). Three months after the operative procedure, the endodontic treatment of tooth 11 resulted in no further clinical symptoms. In the treated

area, the probing depth was 1.5 mm. No bleeding was found during probing. No further recession of the gingival margin was found after the primary healing, approximately two weeks after treatment or at the follow-up inspection after three months. Gingival colour and surface texture (gingival stippling) corresponded to a healthy appearance (Fig. 8). To ensure long-term good oral hygiene and to prevent approximal gingival recession at 11/21 in a further step a frenectomy (laser-assisted) should be performed.

Discussion

The presented treatment protocol for laser-assisted gingivectomy enabled the badly destroyed teeth 11 and 21 to be restored in an aesthetically satisfactory manner. Due to the safe procedure and the drying of the surgical field after laser-assisted excision, adhesive fillings were placed in the same session and exhibited no discolouration in the marginal zone, even after three months. This indicates a good bonding between the restorative material and the dentin. There was only little discomfort for the 72-year-old patient which derived from this complex therapy. After an emergency treatment, definitive rehabilitation, including adhesive restorations and endodontics, was carried out in two sessions. The patient did not report any discomfort related to the laser treatment. The patient's aesthetic appearance in the anterior teeth of the upper jaw was restored with moderate means. This treatment procedure improves the patient's compliance, because it allows the patient to partake in a systematic care and treatment concept, which enables the continuation of additional necessary treatment measures.

contact

Prof. Dr Matthias Frentzen
Welschnonnenstraße 17
53111 Bonn, Germany
Tel.: +49 228 287-22470
frentzen@uni-bonn.de

Author details



Literature

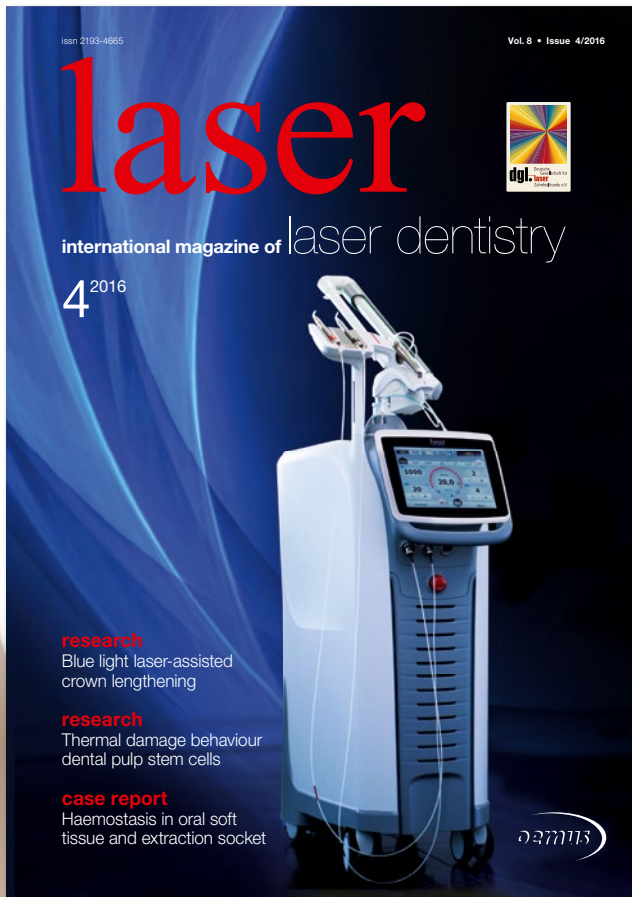


Kurz & bündig

Grundlegende Untersuchungen zur Lasergewebeinteraktion eines neuen Lasertherapiegerätetyps mit einer Wellenlänge von 445 nm – blaues Farbspektrum – versprechen aufgrund der bekannten optischen Parameter orale Weichgewebe nachhaltige Vorteile gegenüber infraroten Lasersystemen. Im Rahmen eines Fallberichts wird das Vorgehen bei umfassenden laserbasierten Gingivektomien vor restaurativer Therapie mit diesem neuen Lasertyp vorgestellt. Gingivektomie und adhäsive Füllungstherapie waren in einer Sitzung aufgrund der hervorragenden Blutstillung mit dem Blaulichtlaser möglich. Die Nachkontrolle zeigte eine schnelle Ausheilung der Wunde ohne Komplikationen und ohne postoperative Gingivaretraktion. Die Therapie führte bei moderatem Aufwand zu einem sehr guten ästhetischen Ergebnis.

Publish your expertise!

Become an author for **laser**—international magazine of laser dentistry



Please contact:

Georg Isbaner · Editorial manager
g.isbaner@oemus-media.de

Thermal damage behaviour of human dental pulp stem cells

Authors: Prof. Dr Karsten König & Dr Anton Kasenbacher, Germany

Objective

This study was designed to examine the influence of temperatures ranging from 37 to 65 °C on the cell morphology of DPSC stem cells via light and electron microscopy, a synthesis of Heat Shock Proteins (HSP) with fluorescence-marked antibodies and vitality via the Life/Dead Fluorescence Kit.

Material and methods

DPSC were cultivated at 37 °C and 5% CO₂ in sterile cell chambers (MiniCeM, JenLab GmbH, Jena, Germany). The cells were irrigated with pre-heated culture medium (Eagle's MEM, Gibco BRL, Paisley, Scotland, 37 °C) with 20% FCS, 2 mM L-Glutamin and 100 µM L-Ascorbate-2-Phosphate in order to remove cellular debris previously to the temperature trials. Filling the chamber with the culture medium followed and a preheated water bath of different temperatures was introduced. Up to an incubation temperature of 46 °C, the experiments were conducted with temperatures rising every 2 °C and 0.5 °C in the sensitive temperature scale of 46 °C to 58 °C. In addition, trial series were carried out at 60 °C

Table 1: Life/Dead Assay 1 hour und 24 hours after thermal treatment.
Fig. 1: Vitality test of thermally treated DPSC.

Temperature	Letality %	
°C	1 h	24 h
37	0	0
39	0	0
42	0	0
45	0	0
46	0,5	2
47	10	17
48.5	18	29
50	17	27
55	24	59
56.5	48	54
58	100	100
60	100	100
65	100	100

Table 1

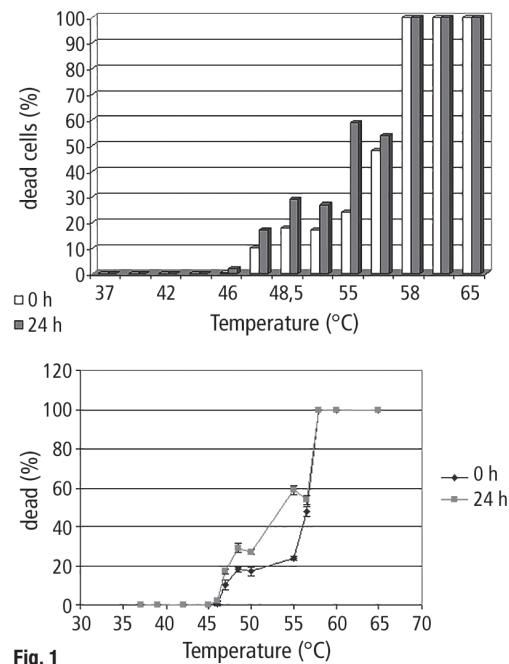


Fig. 1

and 65 °C. After a total of 15 min of thermal treatment, the cells were cooled down in the incubator at a temperature of 37 °C for 1 hour.

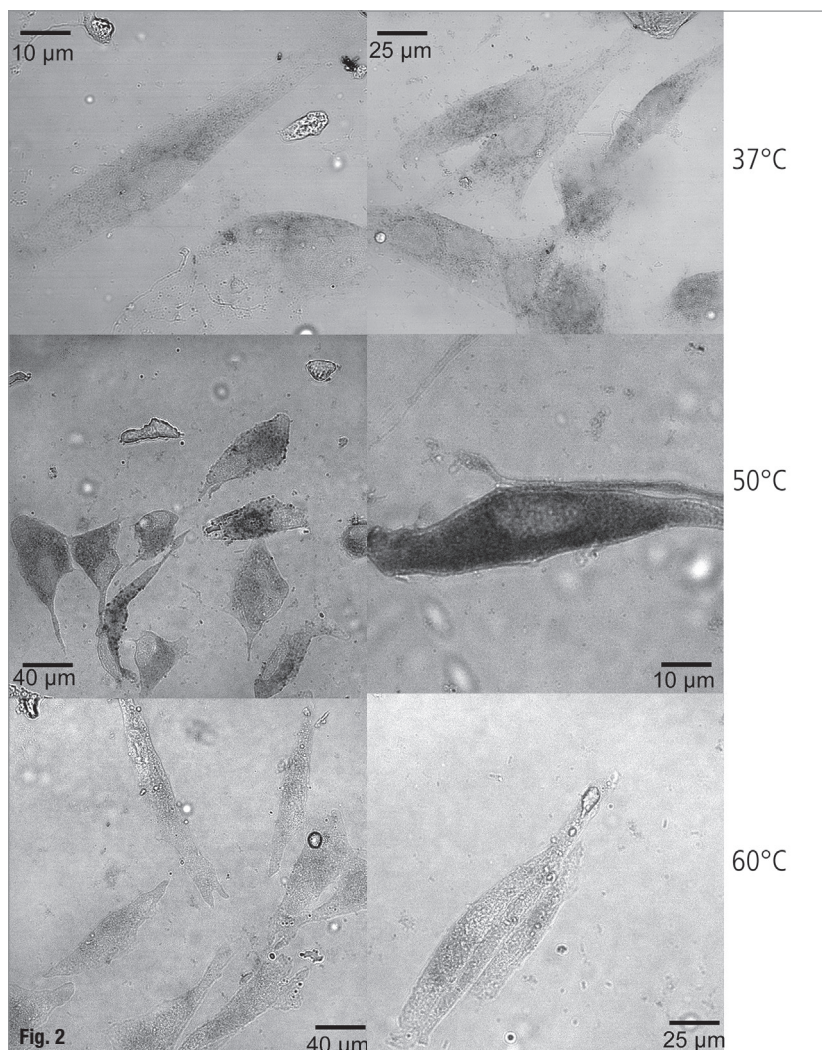
Some of the cells which had undergone thermal treatment were examined with the Life/Dead Fluorescence Assay (Molecular Probes, Eugene, OR, USA) in order to assess vitality via fluorescence microscopy and Axiovert 200 (ZEISS, Jena) after incubation. A mixture of 2 µM Calcein AM and 4 µM Ethidium-homodimer-D1 was added to the cells which were slowly cooling down at 37 °C in the incubator either 1 h or 24 h after thermal treatment and incubated for 10'. Vital cells exhibited a green fluorescence caused by calcein, while lethal cells showed a red core fluorescence (Ethidium-homodimer-D1 and coupled DNA). 100 cells of each type were enumerated.

In order to examine the synthesis of HSP proteins, the cells having undergone thermal treatment were processed as follows:

- Opening of the chamber and removal of the coverslip containing the cells
- Suction of the nutritive medium, two rinses with PBS (isotonic: 67 mM phosphate buffer pH 7.2–7.4, 0.5 % NaCl)
- 12' fixation in 2 % paraformaldehyde in 0.1 M cacodylate buffer pH 7.2; Rinse: 3 x PBS, 2 x TBS (Tris buffered saline, 50 mM Tris-HCl buffer, 1.25 % NaCl)
- Parting of the coverslip with Pap-Pen pen (oil pen), possibly correct with paraffin
- Incubate one half of the coverslip overnight at 4 °C with 1:500 diluted antibody AK HSP25, Rabbit (Biomol), diluting solution: fish gelatin 1 %, Triton x 100 1 % in TBS)
- Cover the other half of the coverslip exclusively in diluting solution (without AK)
- Wash in TBS for 3 x 10'
- Conjugate with the second antibody AK Anti-Rabbit-Alkaline Phosphatase for two hours at room temperature (Ziege, dilution: 1:50 with fish gelatine 1 % and Triton X 100 1 % in TBS)
- Wash in TBS for 3x10'
- 15' Alkaline-Phosphatase verification with 3 mM Levamisol in Chedium (induces blue-brown colouring according to Seidel).

In order to perform examinations with scanning electron microscope, the cells were processed as follows:

- Washing of the cells in cacodylate buffer (0.1 M)
- Fixation with 2.5 % Glutaraldehyde in cacodylate buffer for 20'
- Washing with cacodylate buffer for two times, followed by two washings with Aqua dest
- Dehydration with increasing alcohol concentration: 20 %, 30 %, 50 %, 70 %, 90 %, 2x in 100 % EtOH for 10' each



- Further processing of the samples at the Centre for Electron Microscopy (Critical Point Drying and sputtering with gold; SCD 005, BAL TEC AG, Liechtenstein)
- Microscope: Zeiss EM 902 A.

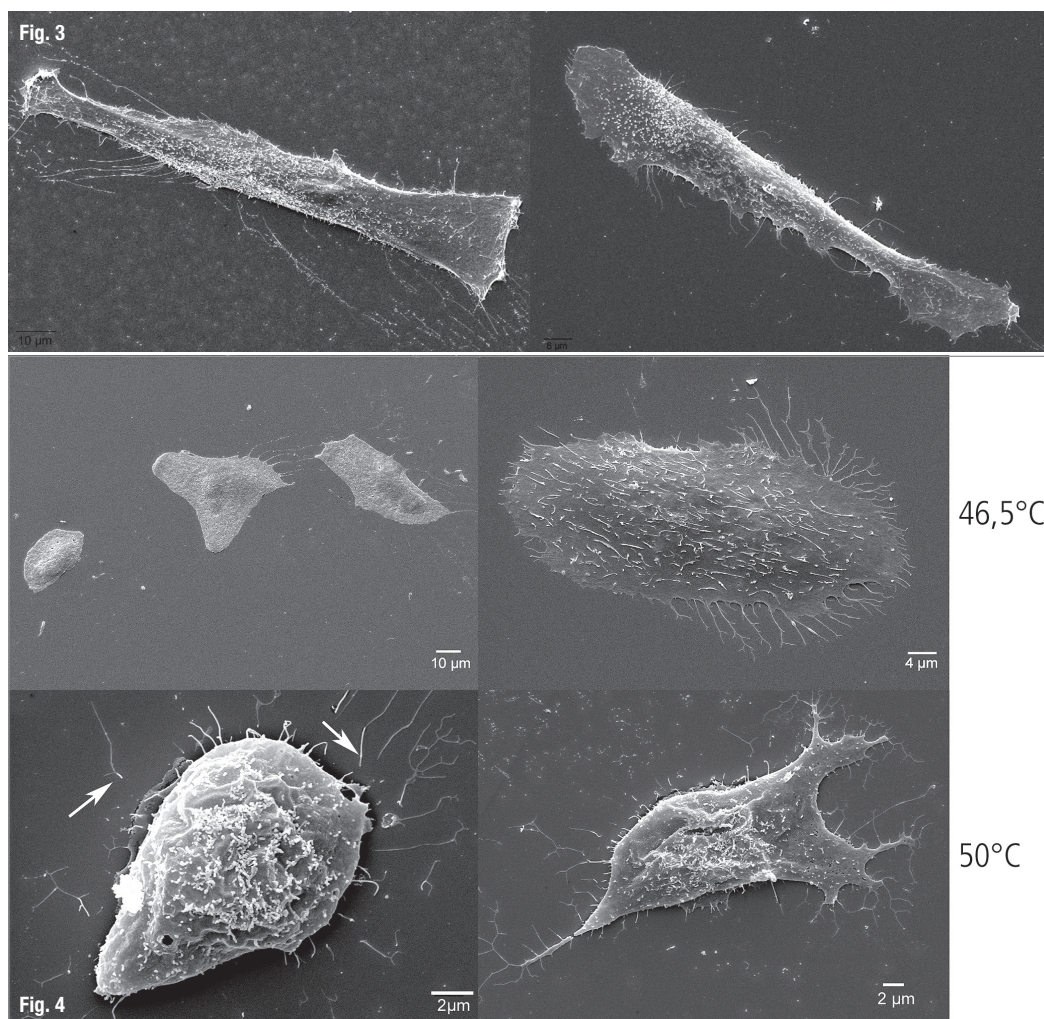
Examinations with the transmission electron microscope were conducted:

- Washing of the cells with cacodylate buffer (0.1 M) with 6.8 % Sucrose
- Fixation of 30' with 1 % glutaraldehyde
- Washing with cacodylate buffer
- Contrasting with 1 % Osmiumtetroxyde and 1 % potassium ferrocyanide for two hours
- Rinsing with cacodylate buffer for three times as well as with Aqua dest.
- Dehydration with increasing alcohol concentration: 20 %, 30 %, 50 %, 70 %, 90 %, 2x in 100 % EtOH for 10' each
- Embedding in Epon (epoxy resin), polymerisation for four days at 60 °C
- Ultramicrotomy, ultra-thin sections (70 nm; Leica Ultracut S, Leica Mikrosysteme GmbH, Bensheim, Germany)

Fig. 2: HSP-detection caused by an antibody color reaction.

Fig. 3: Control cells exhibited a normal appearance at 37 °C under REM. Cell processes, microvilli-like structures on the cell surface (their numbers seems to depend on the level of cell activity) as well as the elongated cell shape are clearly visible.

Fig. 4: REM: Thermally treated DPSC showed external signs of cellular damage at 46.5 °C: The cell usually changes its elongated shape and starts to round. At 50 °C, an increased rounding can be observed. The cell seems to contract so fast that a part of the cytoplasm processes tears off (arrows). The surface structure of the cells is effected as appearance and number of microvilli change.



- Dyeing of the sections with 1% Uranyl acetate in methanol and 1 drop of acetic acid for 10'
- Microscope: Zeiss EM 906.

Results


Light microscopy and vitality test

The cells received thermal treatment at temperatures ranging from 37 °C to 60 °C and varying intermediate temperature levels. Light microscopy examinations showed significant morphological changes at temperatures from 46.5 °C ± 0.5 °C.

At temperatures from 37 °C to 45 °C, all cells exhibited a green calcein fluorescence. At temperatures of 46 °C and above, lethal results were detected in some of the cells that had undergone thermal treatment. The number of lethal cells increased in correspondence to a rise in temperature.

At temperatures of 46 °C to 56.5 °C, the number of lethal cells had almost doubled 24 h after thermal treatment in comparison to the number of lethal cells one hour after thermal treatment (Table 1, Fig. 1). Starting at 56.5 °C, this phenomenon ceased, with

Fig. 5: REM: Thermal treatment at 60 °C. While the exterior shape remains mostly intact, their surface does not exhibit any structuring anymore.



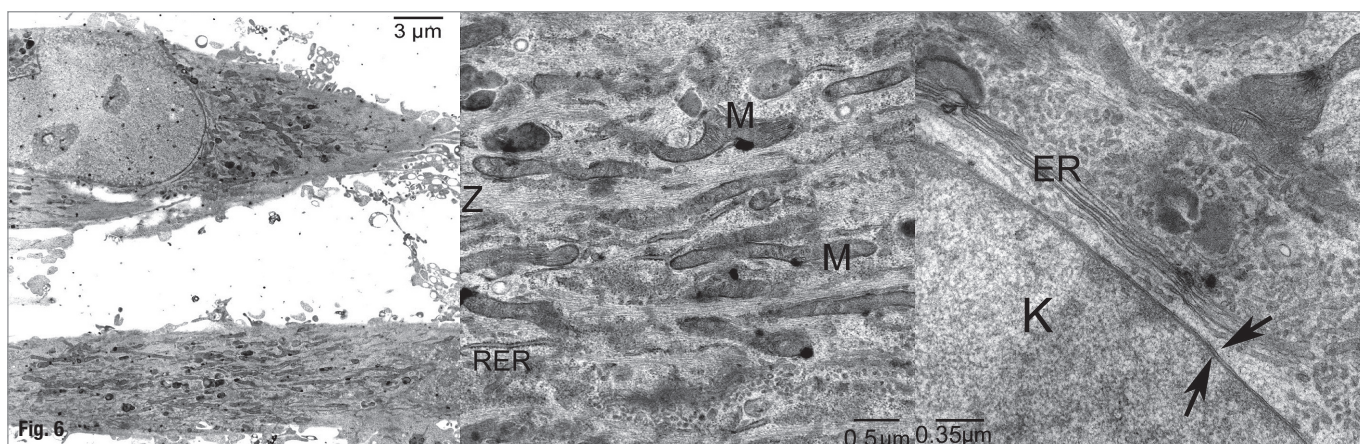


Fig. 6: TEM: Control cells at 37 °C. K: Nucleus; ER: endoplasmic reticulum, RER: rough endoplasmic reticulum; M: mitochondria; Z: cytoskeleton; arrows: markers of the nuclear membrane.

about the same number of lethal cells. This temperature of 56.5 °C corresponded to the LD50 value (50 % lethality). No cell survived thermal treatment at 58 °C.

HSP production

Examinations with regard to the production of HSP via light microscope or transmission laser microscopy showed a slight, unspecific colouring of the cells after incubation of 37 °C (control, Fig. 2). An increase in HSP production (intense colouring) was noted at a temperature of 50 °C, while thermal treatment at 60 °C again resulted in slight, unspecific colouring of the cells.

REM

Scanning electron microscopy showed a typical flat, long distribution of the control cells (37 °C cells, Fig. 3). These cells exhibited many processes and microvilli-like structures. In addition, cell-to-cell connections with neighbouring cells were observed.

The successive rise in temperature resulted in the first critical temperature level of 46.5 °C \pm 0.5 °C. From this level onwards, significant initial changes of the cells were registered via light and electron microscope, especially an initial deformation and rounding of the cells. The cell structure (microvilli-like structures) was reduced. However, microvilli were observed at temperatures of up to 50 °C (Fig. 4). At 50 °C (chance of survival > 70 °C according to Life/Dead Assay), the cells left distinct cytoplasm protuberances on the base of the coverslip (Fig. 4, arrow), probably caused by a rapid contraction or rounding.

Incubation at a temperature of 60 °C, at which none of the cells survived, resulted in a different outcome. There was no apparent deformation or rounding of the cells, with the original cell shape remaining mostly intact and some small reductions. The cells appeared to have been "thermally fixed" instantly. Neither microvilli nor other surface structures were visible. Cell processes in contact with the coverslip remained intact, but exhibited denaturation and fixation caused by rapid heating (Fig. 5).

TEM

The fibroblast-like DPSC cells (Fig. 6) exhibited long, extended mitochondria (M) within the 3-D network of the cell at 37 °C (control). The nucleus (K) appeared to be undivided and to have a normal nuclear envelope (arrows). ER/RER, free ribosomes as well as the Golgi apparatus did not show any anomalies. A significantly expressed cytoskeleton (Z) whose filaments were aligned parallel to the longitudinal axis (probably microfilaments) was observed. The cells featured a number of inclusions.

At 50 °C, cell rounding became irreversible (Fig. 7). Mitochondria (M) exhibited structural changes, especially an inflation which concurred with the destruction of the cristae alignment, the parallelism of which got lost. There was no longer a three-dimensional network. The Golgi apparatus was significantly deformed and hardly any vesicles were constricted. The cytoskeleton was partially disintegrated and could no longer be detected. The cell membrane appeared to have increased vacuolisation. The nucleus (K) appeared to be damaged irreversibly. The nuclear envelope was inflated and partially disintegrated (*). The nuclear plasma condensed at the chromatin, resulting in a reduction of the euchromatin-areas which condensed at the heterochromatin. The nucleus exhibited segmented chambering (arrow).

Contrarily, the external shape of DPSC cells incubated at 60 °C (Fig. 8) remained mostly intact. However, cytoplasm was hardly detectable. Mitochondria (M) were destroyed, membranes and cristae were partially wound up (arrows). Golgi apparatus and cytoskeleton were not detected. The euchromatin areas were reduced at the nucleus (K) and condensed at the heterochromatin (*). The nuclear membrane was significantly vesiculated.

Discussion

The first indications to a temperature-related damage of the DPSC were seen in the Life/Dead Assay.

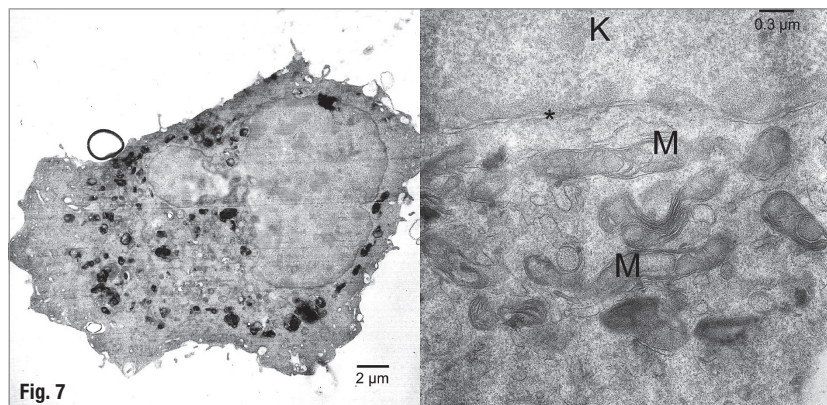


Fig. 7: TEM: Due to thermal treatment at 50 °C, the cells are rounded and the cell membrane forms vesicles (left). Mitochondria exhibit a disrupted structure of the cristae, while the nuclear plasma starts to condense and the nucleus (K) itself often appears to be uncharacteristically flapped (arrow). The nuclear membrane (*) seems to be partially inflated or dissolved.

Calcein is able to penetrate the membrane and is only converted to a fluorescent colouring agent inside of an intact cell. If the cell membrane becomes permeable as a result of damages, calcein will not remain inside the cell. As a consequence, Ethidium-homodimer-D1 will enter the cell in exchange. This substance is not permeable for intact membranes and will fluoresce red when combined with DNA.

Interestingly significant thermally-induced damages were only observed at temperatures ranging from $46.5^{\circ}\text{C} \pm 0.5^{\circ}\text{C}$. Starting at this temperature, cell membranes are destroyed apparently. Temperatures from $56.5^{\circ}\text{C} \pm 0.5^{\circ}\text{C}$ form another threshold at which the 50% lethality limit was reached.

If the vitality test was conducted 24 h after thermal treatment, almost twice as much lethal cells as observed 1 h after incubation were seen at temperatures from 46.5°C to 56.5°C . It appears that repairing processes cannot eliminate the thermal damage. Contrarily, thermal treatment will result in a lethal reaction even 1 h later.

Starting at 56.5°C , most cells died immediately, probably due to denaturation of the proteins (coagulation). Usually, a temperature level of 62°C is given as the starting point for coagulation in the literature.

However, the Life/Dead Assay does not allow any conclusions on the effects of the damages on the cell organelles, compartments or physiological reactions such as protein production. Consequently, HSP tests and electron microscopic examinations of the ultrastructure were conducted additionally.

Heat-Shock-Proteins (HSP) were detected very well at 50°C by an antibody reaction. The cells were distinctly coloured, which implies a significant reaction of the cell on the temperature-related stress. These cells were still able to synthesise the proteins and to survive for some time. Controls only showed only a light colouring, which may be the result of an unspecific reaction of the antibody with different cell proteins as well as a production of HSP which is not related to thermal stress.

Similarly, a temperature level of 60°C only lead to light colouring, which can be explained by the immediate lethal effect resulting in a missing time scale for the biosynthesis of HSP. In general, it should be noted that the first HSP examinations did not exhibit the expected intracellular resolution due to a low specificity.

The results of REM and TEM at the different guide values of 37°C , 46.5°C , 50°C , 60°C and 65°C fit very well with the results from light microscopy. The effects of a sudden and massive heating to more than 46°C on the exterior cell shape (rounding and partial reduction of external structures) are distinctly visible. The extremely fast contraction of the cells at temperatures around 50°C might result in the observed tearing of cytoplasm-processes. Thermally-related membrane openings were not detected via REM even at temperatures of 60°C and above. These high temperatures probably resulted in an immediate coagulation of membrane proteins and other intracellular proteins, which lead to a "conservation" or fixation of the cells in their current shape. While the external cell shape was maintained because of the lacking time window for morphological modification, irreversible damages

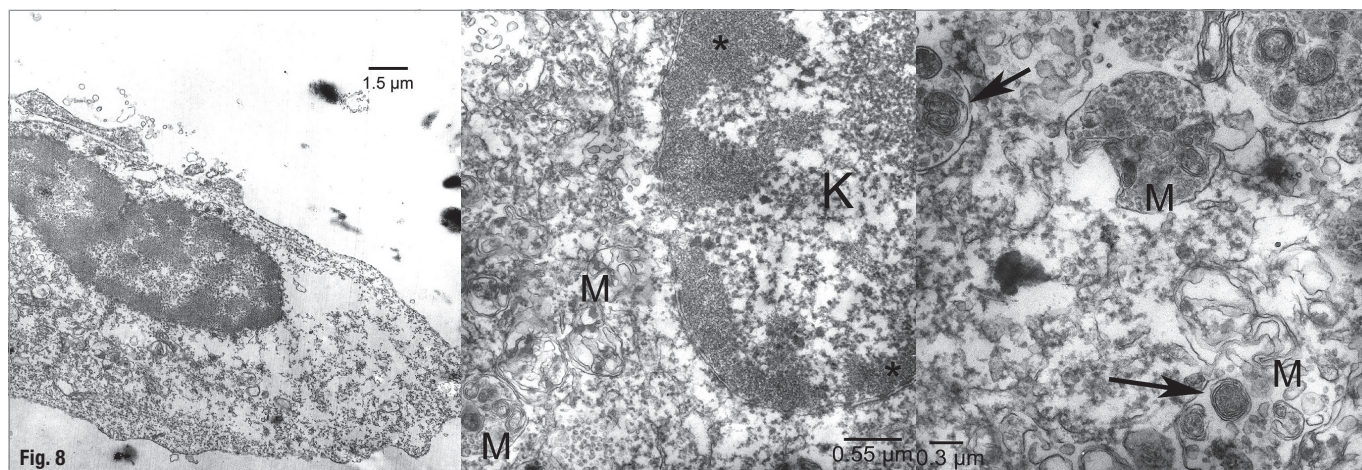


Fig. 8

to the organelles, nuclear membranes, nuclei and cytoplasm were detected electron-microscopically.

Starting at a temperature of 46.5 °C, a vacuolated cell membrane was observed via TEM in the rounded cells. Nucleus, organelles and cytoskeleton were subject to beginning morphological changes.

The cells reacted differently on heating, probably because their differences in physiological age, activity and cycle states influenced immediately visible effects. For example, the cells differed in the level of microvilli reduction.

If the survival of thermally treated cells will prevail for a time span of more than 24 h and if there are thermally-related damages of the reproductive behaviour remains to be examined by further studies. However, it may be postulated with caution that the presented data indicate a chance of survival of the examined DPSC up to a temperature of 46 °C. These results on the thermal damage behaviour of human dental pulp stem cells are important for the development of ultrashort dental laser systems.

Acknowledgements: The authors would like to thank Dr Walter Richter, Dr Iris Riemann and Mr Helmut Hörig (Clinical Centre of FSU Jena, Germany) for their support in producing electron microscopic and light microscopic images.

contact

Prof. Dr Karsten König

Saarland University
Campus A5.1, Room 2.35
66123 Saarbrücken
Tel.: +49 681 3023451
Fax: +49 681 3023090
k.koenig@blt.uni-saarland.de

Author details



Dr Anton Kasenbacher

Obere Hammerstr. 5
83278 Traunstein
Tel.: +49 861 4692
Fax: +49 861 12853
a.k@ts-net.de

Author details



Kurz & bündig

Es soll der Einfluss von Temperaturen im Bereich von 37 °C bis 65 °C auf Änderungen der Morphologie mittels licht- und elektronenmikroskopischer Aufnahmen, der Synthese von Heat Shock Proteinen (HSP) mittels fluoreszenzmarkierter Antikörper und der Vitalität mittels Life/Dead-Fluoreszenzkit von DPSC Stammzellen untersucht werden.

DPSC wurden bei 37 °C und 5 % CO₂ in sterilen Zellkammern (MiniCeM, JenLab GmbH, Jena) kultiviert. Für die Temperaturversuche wurden die Zellen mit vorgewärmtem Kulturmedium (Eagle's MEM, Gibco BRL, Paisley, Scotland, 37 °C) mit 20 % FCS, 2 mM L-Glutamin und 100 µM L-Ascorbat-2-Phosphat gespült, um Zelldebris zu entfernen. Anschließend wurde die Kammer mit Medium aufgefüllt und in ein vortemperiertes Wasserbad unterschiedlicher Temperatur eingebracht. Bis zu einer Inkubationstemperatur von 46 °C fanden die Versuche in Temperaturschritten von 2 °C statt, im sensiblen Bereich (46 °C – 58 °C) in Schritten von 0,5 °C. Zudem fanden Versuchsreihen bei 60 °C und 65 °C statt. Nach insgesamt 15 min Wärmebehandlung wurden die Zellen im Brutschrank bei 37 °C langsam für 1 Stunde heruntergekühlt.

Ein Teil der wärmebehandelten Zellen wurden nach Inkubation mit einem Life/Dead-Fluoreszenzassay (Molecular Probes, Eugene, OR, USA) zur Überprüfung der Vitalität fluoreszenzmikroskopisch mittels Axiovert 200 (ZEISS, Jena) untersucht. Ein Gemisch aus 2 µM Calcein AM und 4 µM Ethidium-homodimer-1 (EthD-1) wurde entweder 1 Stunde oder vergleichend 24 Stunde nach der Wärmebehandlung zu den langsam bei 37 °C im Inkubator abgekühlten Zellen in die Zellkammern gegeben und für 10' inkubiert. Vitale Zellen zeigten durch das Calcein eine grüne Fluoreszenz, letale Zellen eine rote Kernfluoreszenz (Ethidium-homodimer-1 an DNA gekoppelt). Es wurden jeweils 100 Zellen ausgezählt.

Die Zellen reagierten etwas unterschiedlich auf die Erwärmung, möglicherweise nahmen ein unterschiedliches physiologisches Alter und verschiedene Aktivitäts- und Zyklusstadien einen Einfluss auf die sofort sichtbaren Effekte, z.B. war die Reduktion der Mikrovilli nicht überall gleich stark ausgebildet.

Ob das Überleben der wärmebehandelten Zellen über einen größeren Zeitraum als 24 Stunden gegeben ist und inwieweit thermisch bedingte Schäden des Reproduktionsverhaltens vorliegen, müssten weiterführende Studien untersuchen. Eine teilweise Überlebenschance der untersuchten DPSC bis zu einer Temperatur von 46 °C könnte aus den vorliegenden Daten jedoch vorsichtig postuliert werden.

A variety of photo-coagulation techniques

Haemostasis in oral soft tissue and extraction socket

Authors: Chaivasan Malakam, Nuttakarn Rungrojwittaya, Nattaya Sanposh & Sajee Sattayut, Thailand

Introduction

There is a variety of surgical procedures, such as soft tissue biopsy and surgical extraction, which usually results in difficulties for haemostasis. One of the major concerns in oral surgery is to minimise bleeding and postoperative complications. Currently, a number of laser wavelengths have been used in oral surgery and dentistry, including CO₂ laser, Nd:YAG laser, argon laser, diode lasers in various wavelengths, Er:YAG laser and potassium titanyl phosphate (KTP) laser. Their applications were soft tissue procedures, such as gingivectomy and gingivoplasty, excision of tumors and lesion, incisional and excisional biopsies, frenectomy, control of bleeding in vascular lesions,

arthroscopic temporomandibular joint surgery, caries diagnosis and removal.^{1,2}

The photothermal reaction, which depended on the tissue absorption of the laser energy, played an important part in the laser-surgery procedure with haemostasis.³ This reaction was mainly applied in soft tissue surgery comprising 1) photoablation, 2) photovaporisation, and 3) photocoagulation. Each reaction or a combination of reactions occurred with varied laser parameters and procedures.

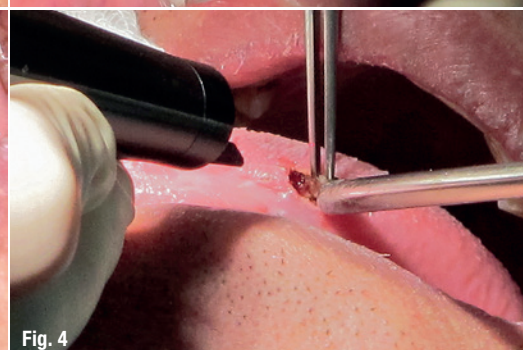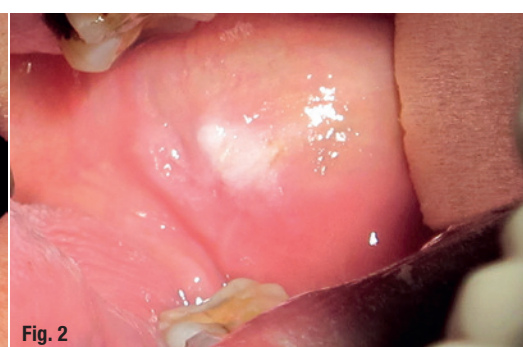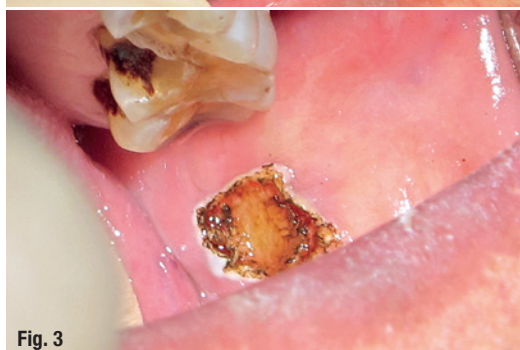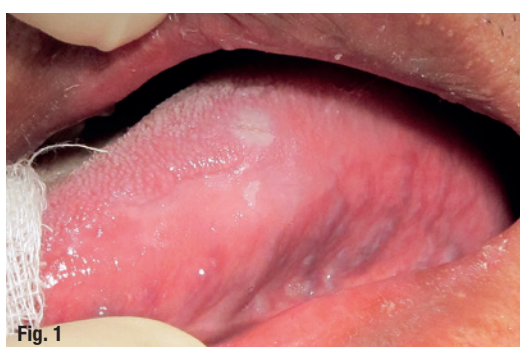Regarding the procedure with pure photocoagulation, there have been various techniques of laser application^{4,5} or light-emitting diodes in dental prac-

Fig. 1: Left lateral border of the tongue with 6 mm and 2 mm in diameter of leukoplakia in the tongue.

Fig. 2: Buccal mucosa with a 7-mm diameter and whitish moderate-thickening lesion.

Fig. 3: Post-CO₂ excision of the lesion was completed with no active bleeding.

Fig. 4: Intra-operation of CO₂ excisional biopsy (photoablation).



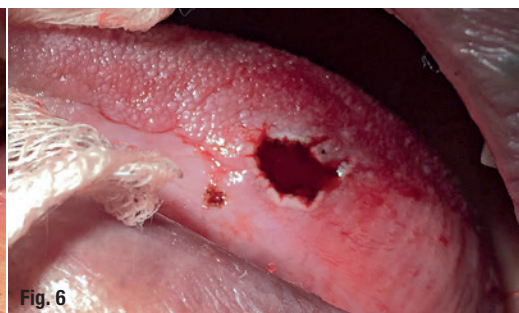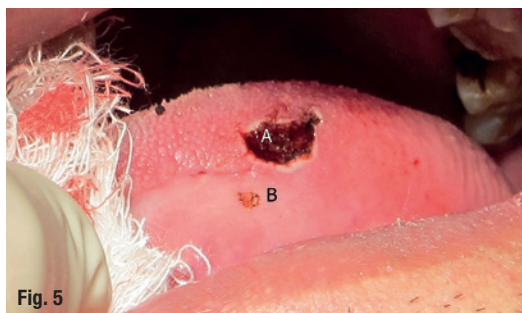


Fig. 5: Immediate postoperative view; **A)** oozing in the surgical area after CO₂ laser photoablation; **B)** coagulative surgical area after CO₂ laser vapourisation.

Fig. 6: Immediate post-photocoagulation using LED showed an initial blood clot formation without oozing.

tice⁶, which were well absorbed by haemoglobin for achieving haemostasis after oral surgery. In the following case reports, we present a variety of photocoagulation techniques in cases of soft tissue biopsy, simple extraction socket and surgical removal of the wisdom tooth involving hard tissue surgery. The clinical outcomes of haemostasis and patient satisfaction are also reported.

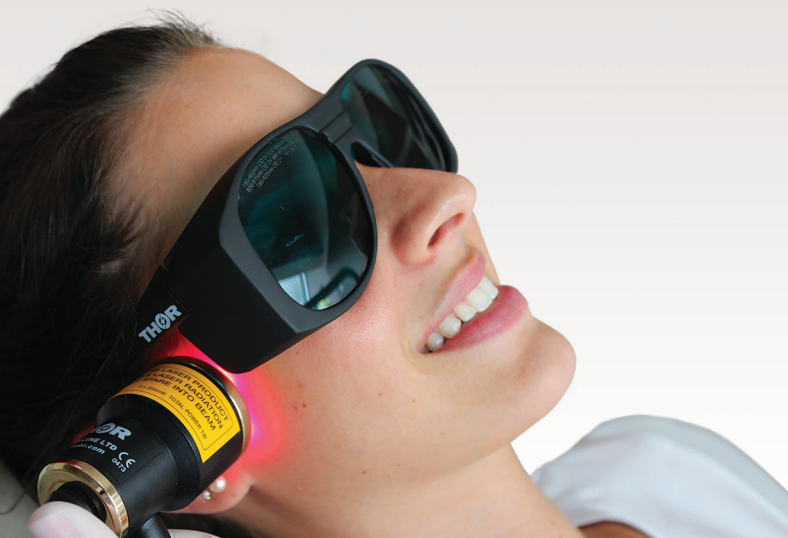Case 1: Photocoagulation for soft tissue haemostasis in excisional biopsy by LED light unit

A 65-year-old male patient presented at the Department of Oral and Maxillofacial surgery, Faculty of

Dentistry Khon Kaen University, with a whitish lesion at the left lateral border of the tongue. In the past three months, the patient was treated with low intensity laser therapy and topical steroid for the chronic ulceration at the left lateral border of the tongue. The ulcer was healed with a coverage of the whitish patches. There was also a whitish lesion at the buccal mucosa of the left cheek with intermittent pain on palpation.

The clinical examinations showed three non-scrapable whitish lesions as follows: 1) a moderate thickening whitish patch at the left lateral border of the tongue, measuring approximately 6 mm in diameter; 2) a mild thickening whitish lesion at the left ven-

AD



Do More with THOR
www.thorlaser.com

THOR
THE FUTURE OF MEDICINE

When the drugs don't work

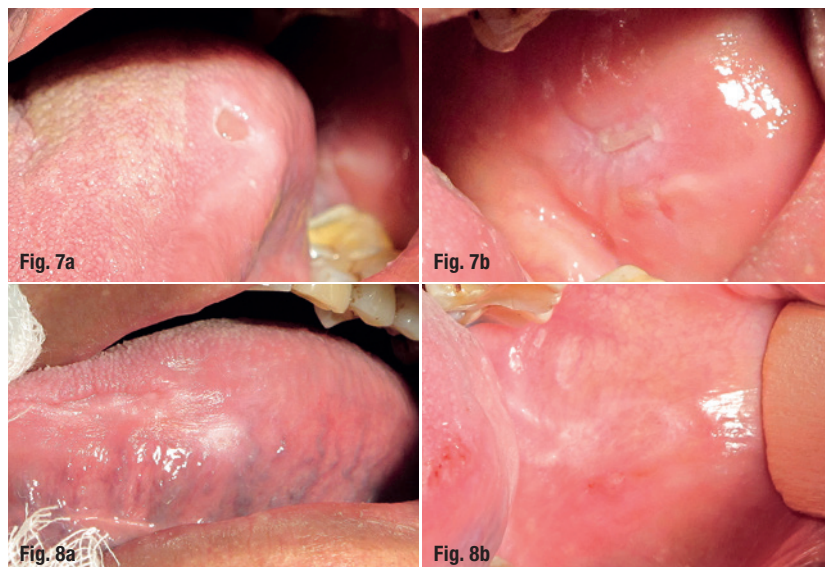Low Level Laser and LED Photobiomodulation

Low Level Laser and LED Photobiomodulation does something that drugs and surgery don't, **this treatment actually heals the patient**. Nerve injuries, wounds that will not heal, neuropathic pain, dry mouth, inflammatory pathologies that do not respond to drug therapies often respond well to this treatment. Our large online treatment library makes it easy to use, which means it can be delegated to the dental nurse / technician.

TMD
Iatrogenic nerve injury repair
Dentin hypersensitivity
Burning mouth syndrome
Oral lichen planus
Trigeminal neuralgia
Post operative pain
HSV
Osseointegration titanium implants

Orthodontic tooth movement
Periodontitis
Dentin formation
Gingivitis
Denture stomatitis
Oral mucositis
Xerostomia & hyposalivation
Dysphagia
Radiation dermatitis
BRONJ





Figs. 7a & b: Two-week post photoablation biopsy and the healing with coagulum coverage.

Figs. 8a & b: Five-week follow-up after photoablation biopsy, complete coverage with mild whitish mucosa.

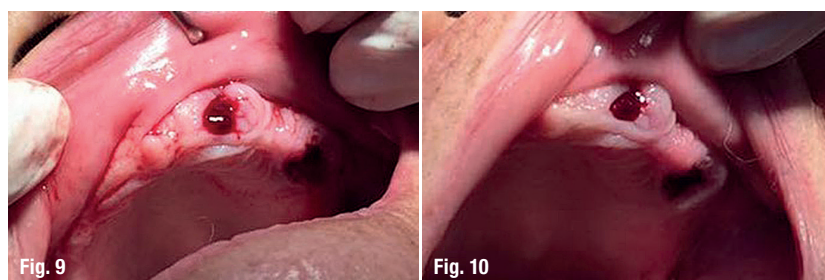
tral side of the tongue, measuring approximately 2 mm in diameter (Fig. 1); and 3) a moderate thickening whitish patch at the buccal mucosa of the left cheek, measuring approximately 7 mm in diameter (Fig. 2).

The surgical procedure involved local anaesthesia (2% lidocaine with epinephrine 1:100,000) and excisional biopsy of the lesions at the buccal mucosa by using 10,600 nm CO₂ laser at 5W and continuous wave. Then tissue coagulation for haemostasis was undertaken using a defocused CO₂ laser at 3W and continuous wave. The ablation with haemostasis was easily achieved (Fig. 3).

At the left lateral border of the tongue, the photoablation was undertaken using a 10,600 nm CO₂ laser at 5W and continuous wave (Fig. 4). After excisional biopsy, there was an active bleeding over the lesion because of a highly vascularised tissue (Fig. 5-A). A blue light-emitting diode (LED) for dental practice (WOODPECKERTM LED light unit; a single blue light source non-heat producing, energy density 1,000-1,200mW/cm²) was irradiated for 5 seconds to the oozing area. This was repeated for four episodes to gain an initiating blood clot (Fig. 6). For the smaller lesion at the ventral side of the tongue, the vapourisation technique was applied using 10,600 nm CO₂ laser at 3W and continuous wave. There was no active bleeding at the surgical site (Fig. 5).

Fig. 9: Oozing at the sockets of bleeding after tooth extraction.

Fig. 10: Immediate post-photocoagulation using LED showed an initial blood clot formation.



Clinical results

The outcome after using laser for surgical removal of the soft tissue lesion showed ablation with haemostasis except the lesion at lateral border of the tongue, a site with high vascularity. In this case, the irradiation of LED at the active bleeding area promoted blood clot formation without producing any clinical soft tissue destruction. Furthermore, soft tissue biopsy using laser had many advantages, for example, providing a dry clean surgical field enhancing visibility for the operator and reducing operation time. At the two-week follow-up, there was soft tissue healing with some coagulum coverage and no clinical signs of inflammation or infection (Figs. 7a & b). The histopathology investigation was obtainable. In this case, epithelial keratosis was diagnosed. The five-month follow-up after excisional biopsy showed complete healing of the mucosal coverage with some thin whitish areas and without tethering of the scar (Figs. 8a & b). Based on the histopathological finding, these should be in a condition for observation.

Patient satisfaction

Without any efforts to stop bleeding such as biting on gauze pads, he felt more confident with regard to the operation being necessary and agreed with routine follow-up. There was still no pain and bleeding interfering routine activities after laser surgery.

Case 2: Photocoagulation for hard tissue haemostasis after routine tooth extraction by LED light curing unit

The second case study was a 66 year-old woman who had a history of diabetes mellitus and hypertension. The upper left canine and second premolar were diagnosed "chronic periodontitis". The tooth extraction was requested as a treatment. Routine tooth extraction was performed under local anaesthesia; 2% mepivacaine with 1:100,000 epinephrine. The LED at an energy density of 1,000-1,200 mW/cm² was irradiated at the extraction socket for 5 sec per cycle for a total of four episodes.

Clinical results

There was an oozing of bleeding after extraction (Fig. 9). An initial clot occurred in the bony socket immediately after LED photocoagulation procedure (Fig. 10).

Patient satisfaction

The patient seemed to be anxious about the operation at the beginning. After using LED light photocoagulation to accelerate blood clot formation into the sockets, she seemed more comfortable and satisfied with the procedure with no need to be worried about pressure compression by biting a gauze.

Case 3: Photocoagulation for surgical site after surgical removal of impacted tooth by 790 diode laser

A 19 year-old woman with no systemic disease presented with a lower right third molar partial bony impaction. This needed to be removed by surgical extraction. The standard procedure including flap operation, osteotomy and tooth section was conducted under local anaesthesia; 2% mepivacaine with 1:100,000 epinephrine. After the tooth was delivered, there was bleeding in the bony socket (Fig. 11). A 790 nm diode laser at 0.3 W was used to irradiate the socket and wounded area for 30 sec per cycle, for a total of two episodes. An initial blood clot was found (Fig. 12).

Clinical results

There was no active bleeding, but an immediate haemostasis in the surgical removal area, which was different compared to our experiences of using standard technique. Also the healing in a week was favourable (Figs. 13a & b).

Patient satisfaction

The patient seem to be satisfied with immediate haemostasis after the operation.

Case 4: Photocoagulation for bony socket and soft tissue haemostasis after surgical removal of soft tissue impaction by 808 nm diode laser

A 26 year-old woman with no systemic disease had a chief complaint of a lower right third molar soft tissue impaction. The surgical removal was required for treat-

ment. The standard procedure including flap operation osteotomy and tooth section was conducted under local anaesthesia; 2% mepivacaine with 1:100,000 epinephrine. After the tooth was delivered, there was bleeding in the bony socket (Fig. 14). An 808 nm diode laser at 0.5 W was used to irradiate the socket and wounded area for 5 sec per cycle and a total of four episodes. The initial blood clot with some carbonisation was found (Fig. 15).

Clinical results

There was no active bleeding and an immediate haemostasis in the surgical removal area, which was different from our experiences of using standard technique.

Patient satisfaction

The patient seem to be satisfied that there was no bleeding after the operation.

Discussion

Although the CO₂ laser was commonly used in the surgical removal of intraoral lesions due to the limitation of lateral damage, which made specimen available for histopathological investigation together with the ability of sealing of vessels up to 500 micron in diameter,⁷⁻⁹ we experienced insufficient tissue coagulation at the lateral border of the tongue in case 1. In this case, we used the LED photocoagulation in order to avoid photoablation and carbonisation effect.

The benefits of using lasers in oral surgical procedures were clinically significant to both the dental surgeons and the patients. All techniques and wave-

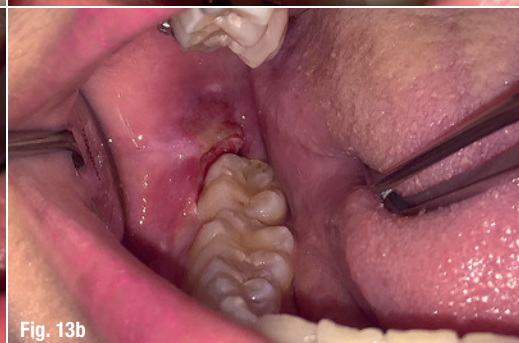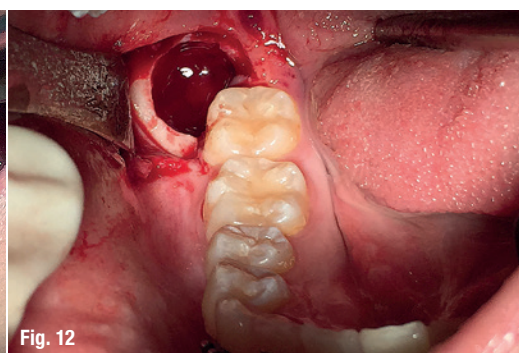
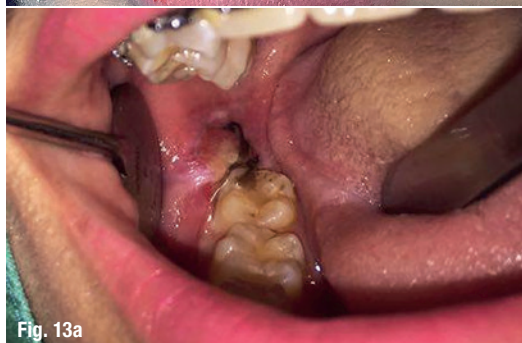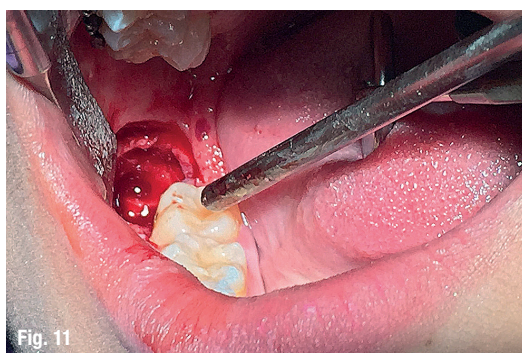


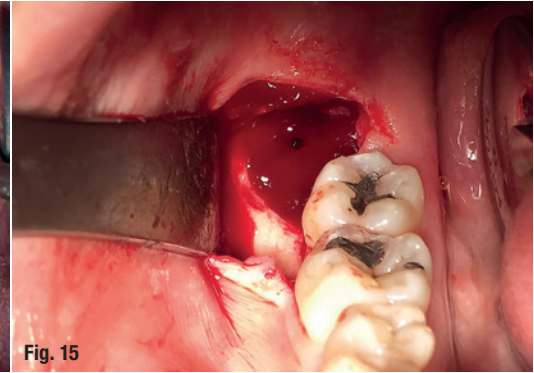
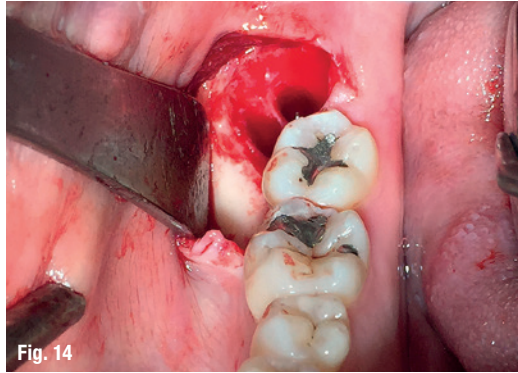
Fig. 11: After surgical removal of the lower right third molar impaction, it was oozing via the bony socket.

Fig. 12: Initial blood clot formation without oozing was found immediately after post-photocoagulation using a 790 nm diode laser.

Figs. 13a & b: One week after operation, there was no complication. Surgical wound healing was observed.

Fig. 14: After surgical removal of the lower right third molar impaction, it was oozing via the bony socket.

Fig. 15: Initial blood clot formation without oozing was found immediately after post-photocoagulation using 808 nm diode laser.



lengths used in these case reports were able to create immediate haemostatic effect on soft tissue and bone socket without any complication. It was noticed that, using 808 nm diode laser, at least the parameter used in case 4 was able to produce some carbonisation, while LED and 790 nm did not show such an effect. Therefore, using 800 nm diode laser for photocoagulation may make reducing irradiation time or power necessary to avoid a photovapourisation effect.

With regard to wound healing, the results from soft tissue laser biopsy were favourable. These were supported by in vivo studies showing laser wounds found a significantly lower number of myofibroblast and inflammatory cells, resulting clinically in less wound contracture and less post-operative complication for inflammation.^{10,11} In our reports, these clinical benefits were also found in the cases limited to photocoagulation such as case 3.

Conclusion

Both LED (single blue light source, non-heat producing) and diode laser of 790 nm at 0.3 W and 808 nm at 0.5 W were able to produce localised coagulation and enhance haemostasis in soft tissue after excisional biopsy and bone-socket due to tooth extraction and surgical removal. The results showed successful manage-

ment in terms of clinical outcome of haemostasis and healing together with patient's satisfaction.

Acknowledgement

We absolutely thank Dr. Rattiya Hathaidechadusadee, postgraduate student in oral and maxillofacial surgery, Faculty of Dentistry, Khon Kaen University, for being an operator in the surgical removal of impaction and all members of staff in LDRG-KKU and Faculty of Dentistry, Khon Kaen University. We are also very thankful for every patient who trusted us and permitted data to be reported.

contact

Assoc. Prof. Sajee Sattayut DDS, PhD

Lasers in Dentistry Research Group,
Khon Kaen University
Department of Oral and Maxillofacial Surgery,
Faculty of Dentistry, Khon Kaen University
123 Mittraphap Rd. Amphur Muang
Khon Kaen, KhonKaen,
Thailand 40002
Tel.: +66 0935466178
Fax: +66 43202862
sajee@kku.ac.th

Author details



Literature



Kurz & bündig

Im Rahmen von Laseranwendungen mit Hämostase spielen photothermale Reaktionen in Abhängigkeit vom Absorptionsvermögen des Gewebes für Laserenergie eine entscheidende Rolle. Diese Wechselwirkungen finden vor allem in der Weichgewebschirurgie mit Photoablation, Photovaporisation und Photokoagulation Anwendung. Jede Gewebsreaktion oder eine Kombination dieser tritt dabei bei unterschiedlichen Laserparametern und -anwendungen auf. In den hier vorgestellten Fallberichten erläutern die Autoren eine Vielzahl von Techniken der Photokoagulation bei Weichgewebsbiopsie, an der Extraktionsalveole oder im Rahmen der chirurgischen Entfernung eines Weisheitszahns im Zusammenhang mit der Hartgewebschirurgie. Zusätzlich berichten die Autoren auch über Hämostase und Patientenzufriedenheit bei verschiedenen Laseranwendungen und -wellenlängen. Dabei konnten sowohl LED (einfache blaue Lichtquelle ohne Wärmeentwicklung) als auch Diodenlaser mit 790 nm und 0,3 W sowie 808 nm und 0,5 W eine lokalisierte Koagulation erzielen und die Hämostase verbessern. Die Ergebnisse zeigen ein erfolgreiches Management der klinischen Ergebnisse in Bezug auf Hämostase, Heilungsverlauf und Patientenzufriedenheit.

Dear authors, thank you for your contributions in 2016.
Looking forward to working with you in 2017!




1/16



2/16



3/16



*Happy
New Year*

2017

© ciccino77/Shutterstock.com

Please contact:

Georg Isbaner · Editorial manager
g.isbaner@oemus-media.de

Er:YAG **carries** treatment according to **minimally invasive** therapy

Authors: Kinga Grzech-Leśniak & Swietłana Kozaczuk, Poland

Main MiCD principles are based on the following five rules:

1. "The-sooner-the-better"—Early diagnosis of illness or the cavity allows minimising the need of invasive treatment in the future.
2. Smile Design Wheel—the procedure taking into account the psychological, health, functional, and aesthetic situation of the patient.
3. "Do-no-harm"—One should choose therapeutic methods which saves healthy tissues of teeth to a maximum extent.
4. "Evidence-based approach"—The choice of materials and instruments should be based on the results of scientific research.
5. "Keep-in-touch"—more attention should be paid to regular check-ups and examining the patients carefully, explaining to them why this is so important.

Tooth decay is one of the most prevalent infectious diseases, and continuous progress of knowledge, development of new techniques of treatment in the early stages cause that physicians face new challenges and opportunities.

Currently, the patient also expects from the clinician an interdisciplinary, innovative and minimally invasive approach. Over the years, a significant change of the approach of surgical treatment for so-called biological treatments has been made. Biological treatment presupposes the elimination of bacterial infection (by the use of ozone or laser, for example) and impermeability of fillings, relying on the adhesion properties of the restorative materials. This concept is also based on the selective removing of the decayed tissues without unnecessary preparation of healthy tissues surrounding the defect.

Thus, the concept of minimally invasive therapy and early diagnosis correlate with the innovative idea of treatment involving laser techniques.

In conservative dentistry, in order to prepare decayed hard dental tissue and replace dental fillings, high-energy Er:YAG laser is used.² Er:YAG eliminates many harmful experiences of the patient (vibration, overheating of the tissues during preparation, unpleasant sound)³, introducing him/her to a new dimension of treatment. No pressure occurs, as unpleasant experiences of the patient are fully eliminated, and thus, the patient is motivated to further cooperation. Moreover, pain sensation is limited. In the case of Er:YAG laser, there is very short pulse duration and nerve endings are often not stimulated.

In many clinical trials, limited use of anesthetics was reported and full acceptance of this therapy method by the patients was demonstrated. The technique of laser preparation of the cavity allows performing the procedure painlessly, or with a mild pain sensation (NRS—Numerical Rating Scale <3) for profound tooth decay in 59.8%, and medium tooth decay—at 94.8%.⁵

The use of laser technology in restorative dentistry refers to the action scheme described below. Er:YAG laser radiation at 2,940 nm is preferably absorbed by water and hydroxyapatite. This process of a non-thermal nature is based on "evaporating" the tissue by short light pulses of high energy (photoablation). The key role is played by the water molecules incorporated in the crystalline structure of the mineralised tooth tissue. Water, activated by the supplied energy, is converted into steam, and the pressure within the mineral structure of teeth increases rap-

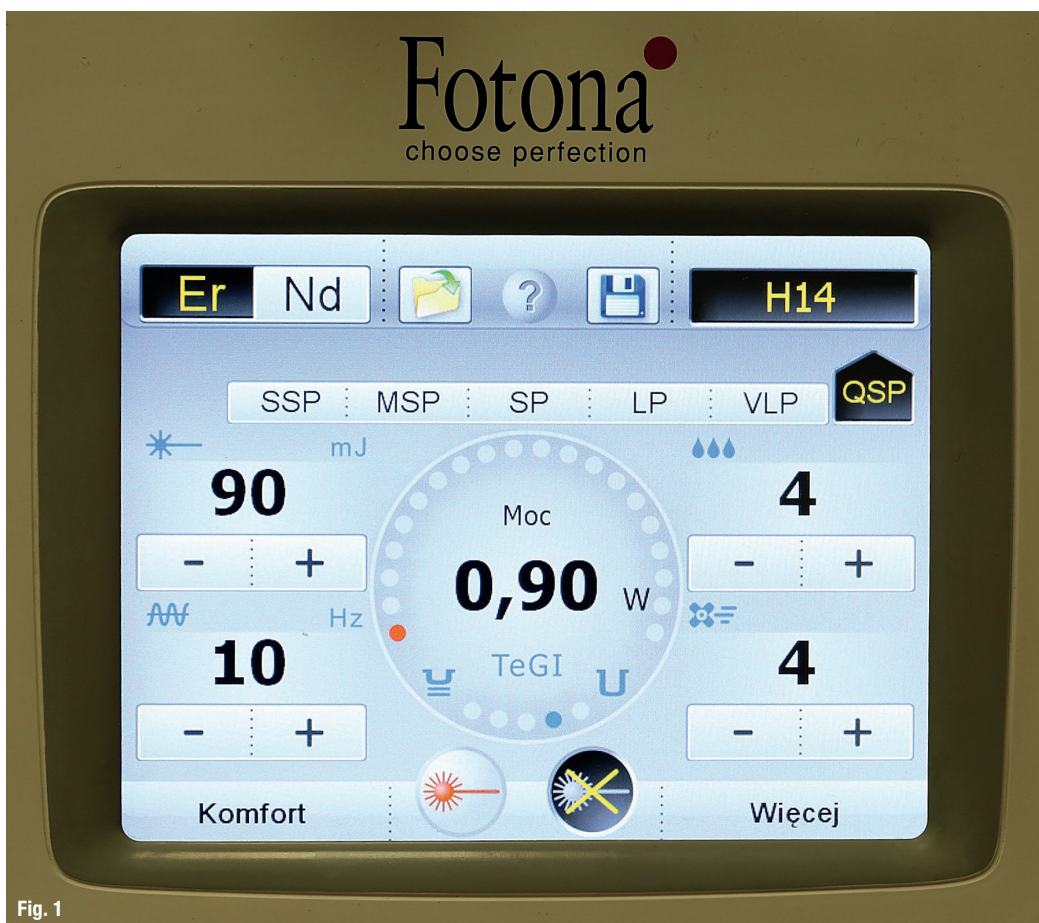

Fig. 1: Laser screen. The parameters of Er:YAG laser: H14/conical tip, QSP, 0,90 W/90 mJ, 4 W/4 A.

idly, leading to microexplosion heard in the typical form of a short acute sound.⁶ During work, a certain amount of heat is emitted, being dispersed together with the removed material. Only its small part is transferred to the surrounding tissue. This process, based on maximal reduction of the thermal effects, has been tested for more than 30 years, and still focuses on determining the most optimum parameters of the laser beam for minimally invasive work.⁷⁻⁹ The thickness of the evaporated surface layer (the depth of ablation) depends on the tissue parameters (the depth of absorption of laser radiation, thermal conductivity coefficient, temperature diffusion coefficient, and heat evaporation coefficient), and the

laser beam parameters (wavelength, energy density and duration of the laser pulse).

At high energies and pulses of short duration the entire laser energy is consumed in the so-called cold ablation because ablation speed is higher than the speed at which the heat passes into the tissue. However, using too little energy and/or too long pulse duration leads to an increased heat transfer to the deeper layers of the tooth.¹⁰ Thermal effects become more pronounced and therefore we are dealing with the so-called warm and hot ablation, bearing in mind that this is an undesirable phenomenon. In the precise and safe procedures of the therapeutic work

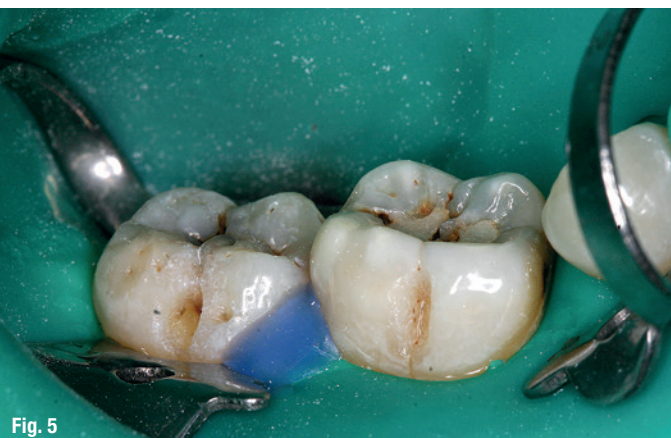
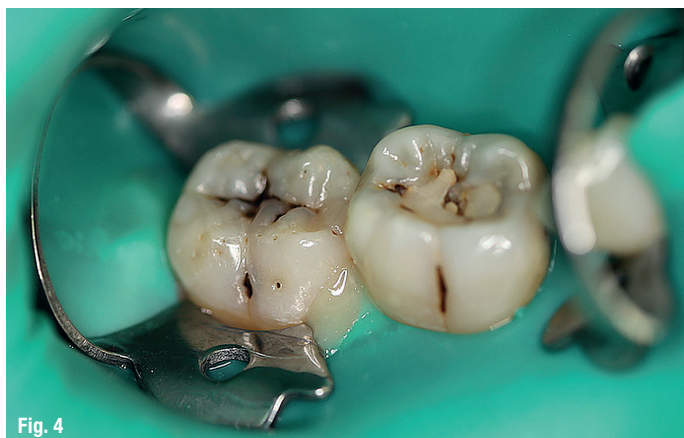
Fig. 2




Fig. 3

Figs. 2 & 3: Tips dedicated to preparation of the cavity.



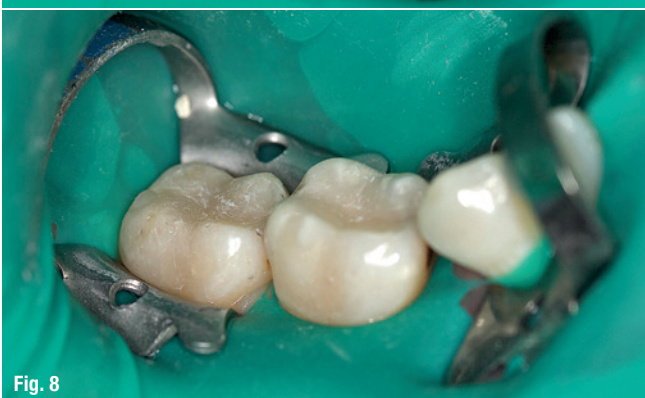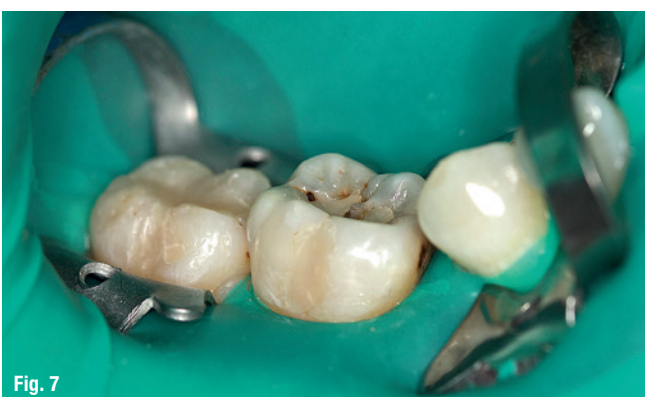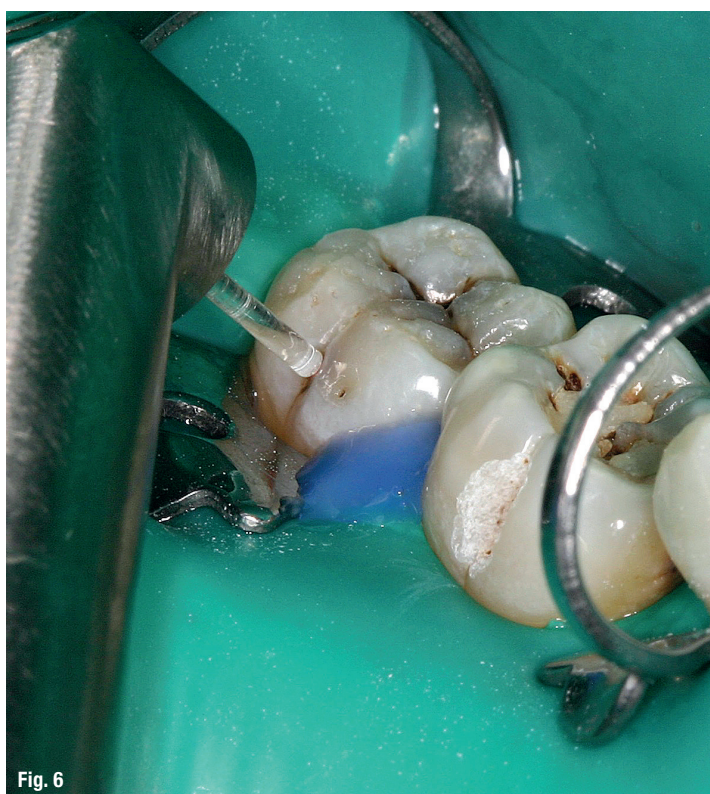Figs. 4 & 5: Caries on tooth 47.

on hard tissues—both on enamel and dentin, it is recommended to work at energies and pulse durations that are significantly above the threshold value of ablation.¹¹ Moreover, efficiency and the safety level of work with the Er:YAG laser can be increased by spraying the water spray on the target tooth surface.¹² This also improves the efficiency of the cavities preparation. The radiation penetrates into the water molecules, causing the molecules vibrations to increase and therefore raising the pressure and temperature in the area of application, thus initiating the ablation process. Note, however, that a thick layer of water can cause the opposite effect—

isolation of the laser beam from the tissue. Properly prepared tissue has a microporous structure. A macroscopic view of cavity prepared with the use of drill shows its smooth walls, compared to the image of the ablation with Er:YAG laser, where the edges and walls of the cavity are of irregular shape.¹³ After laser preparation, we get the characteristic view of craters with smooth walls with no carbonised areas, pre-melted enamel and dentin, or the smear layer. Surface of the enamel obtains micro retention structure, enamel prisms are clearly recognizable, dentine tubules are open and free from the smear layer, allowing the bonding material to penetrate deeply and enhancing the adhesion of the composite material to the cavity walls.^{14–16} Er:YAG laser operating speed depends not only on the laser beam parameters and the operator's skills,

Figs. 6–8: Cavity of 47 and 48 healed.

Preparation of tissue without water can lead to raising their temperature, causing surface carbon-



but also on the tissue's chemical composition. The enamel contains 95 per cent of hydroxyapatite ($\text{Ca}_{10}(\text{PO}_4)_6(\text{OH})_2$), 4 per cent of water and 1 per cent of collagen fibres. Dentine consists of 70 per cent of hydroxyapatite, 20 per cent of collagen fibres and 10 per cent of water.¹⁷ Decayed tissue contains more water than healthy tissue.

The above information suggest that the speed of Er:YAG laser preparation of dentine is higher than of enamel, and diseased tissue is more easily removed than healthy tissue. This should be kept in mind during the cavity preparation, in order to safely and consciously control the scope of the cavity according to the concept of minimally invasive therapy. The light of laser shows antibacterial properties, and it acts through overheating and disruption of bacteria cell.¹⁸ Er:YAG laser is a promising tool for the cavity preparation in primary teeth due to the reduction of pain perception and antibacterial effect.¹⁹ The contraindications to the use of Er:YAG laser are cutting crowns and the removal of amalgam fillings. There are no restrictions on the removal of cement and composite fillings; however, in these cases, because of the modest speed, take advantage of the combined approach and use the turbine additionally. The big advantage of Er:YAG laser is its low invasiveness, which allows to work according to the concept of minimally invasive therapy.^{20–21} Simultaneously, it is characterized by the efficiency and safety at work,²² and is well perceived by patients.

Clinical case

A 23-year-old, non-smoker, generally healthy patient visited the clinic. The following was reported in a clinical study: numerous carious focuses in the buccal grooves of 46 and 47, the primary decay on the occlusal surface of 47 and recurrent decay on the occlusal surface of 46. The patient reported no pain of these teeth. During the

preparation according to the concept of minimally invasive therapy, various techniques of Er:YAG laser application with the same parameters were used (H14 conical tip, QSP, 0.90 W/90 mJ/10 Hz, 4 W/4 A). The average caries in the buccal groove of the tooth 46 was prepared using a non-contact technique (head H0_2). No pain during the preparation (NRS = 0). Deep caries in the buccal groove of 47 was prepared using a contact technique (head H14, cylindrical tip). Moderate sensation of pain during the preparation (NRS = 4). Deep caries on the occlusal surface of the tooth 47 was prepared using a combined method—a turbine (diamond drill) and Er:YAG laser (H14 head, cylindrical tip). During the preparation, severe pain was experienced (NRS = 8), infiltration anaesthesia was administered (Ubistesin forte 1/2 of ampoule) and the preparation was completed. Direct reconstruction of hard tissues of tooth was performed with the use of composite material (Gradia A3/NT).

Author details



contact

Dr n. med. Kinga Grzech-Leśniak

— specjalista periodontolog, Polskie
Towarzystwo Stomatologii Laserowej PTSL
www.periocare.pl
www.laser.org.pl

Kurz & bündig

In ihrem Artikel beschreiben die Autoren die fünf Prinzipien der Kavitätenpräparation und Kariesbehandlung: 1) So schnell wie möglich, 2) Beachtung von physiologischen, gesundheitlichen, funktionalen und ästhetischen Faktoren, 3) Minimalinvasive Behandlung, 4) Evidenzbasierte Behandlungsansätze, 5) Regelmäßige Check-ups und Recall-Intervalle. Im Anschluss gehen sie näher auf die Kariestherapie mithilfe des Er:YAG-Lasers ein, der zur Präparation des betroffenen Hartgewebes für den Austausch dentaler Füllungen genutzt werden kann. Gleichzeitig zeigen sie die Vorteile der dentalen Lasertherapie auf: Schmerzreduktion aufgrund geringer Vibrationen und Wärmeentwicklung, kurzer Pulsdauer und der Vermeidung einer Stimulation der Nervenenden sowie eine Minimierung der für manche Patienten angstausslösenden Geräusche. Dies habe zur Folge, dass die Patienten stärker für die weitere Zusammenarbeit motiviert werden können. Neben umfassenden Erkenntnissen aus der Literatur führen die Autoren auch einen kurzen Fallbericht an, um die Vorteile der Er:YAG-Kariestherapie zu belegen.

Literature



An all-rounder with three wavelengths

Efficient treatment with a new diode laser

Author: Dr Talat Qadri, Sweden

One dental laser, three diodes, more than 20 indications

Diode lasers have long been established in dentistry. Thanks in part to their broad indication spectrum, they are considered dental "all-rounders." In the following article, Dr. Talat Qadri (Enköping, Sweden), explains why he is convinced of the diode laser technology. As Doctor in Odontology in Laser and Periodontology, he holds his own clinic and is a lecturer at the Karolinska Institute for Laser Dentistry; therefore, he is very familiar with the technology that has been in use since 1990 for treating periodontitis and peri-implantitis, during surgery, for germ reduction in endodontics, as soft laser therapy and even for treating herpes simplex. Furthermore, Dr. Qadri will talk about the advantages of using the new SIROLaser Blue for patients and users.

In my specialisation—periodontology and peri-implantitis—daily adjuvant use of a diode laser has become an essential tool for treating patients in a contemporary manner. Even though applications could be replaced by conventional dental treatments, the use of laser therapy ensures the following can mostly be conducted:

- Faster healing after surgery and extraction.
- Less pain for patients but simultaneously less need for anesthesia.
- Generally no need for sutures following surgery.
- Swelling and the post-operative intake of analgesics are rare.

Having actively followed the development of this technology for almost 30 years, I have an abundance of experience in the use of dental lasers. Diode lasers have proved particularly successful in dentistry because they cover the widest treatment spectrum and

Figs. 1a & b: The clinical situation and dental X-ray show, amongst others, the remains of the root of tooth 12.

Fig. 2: The clinical situation following extraction of the root remains of tooth 12 prior to treatment with the SIROLaser Blue.

Figs. 3 & 4: The clinical situation after use of the SIROLaser Blue (Fig. 5) with the red diode, wavelength: 660 nm, 8 mm probe/6 J. Lasing was conducted at 2 J buccally and lingually in contact mode, occlusal at a distance of approx. 0.5 cm at 100 mW with an 8 mm probe for 20 seconds on each side.

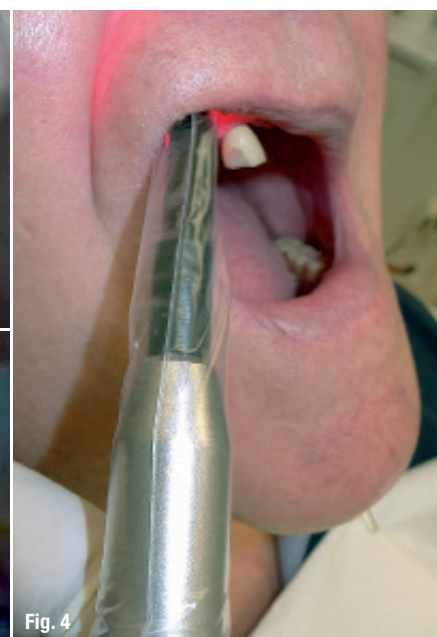
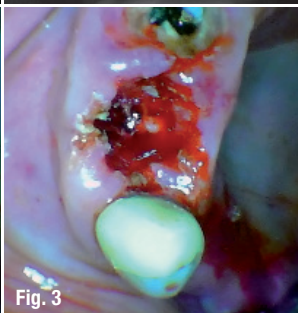
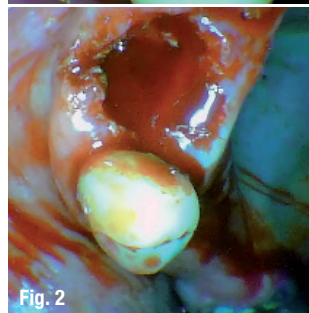
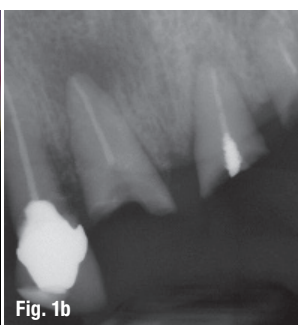
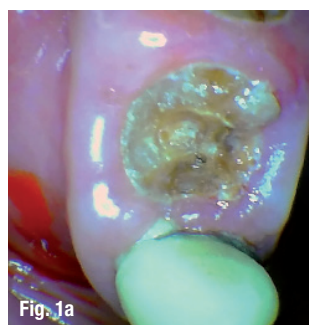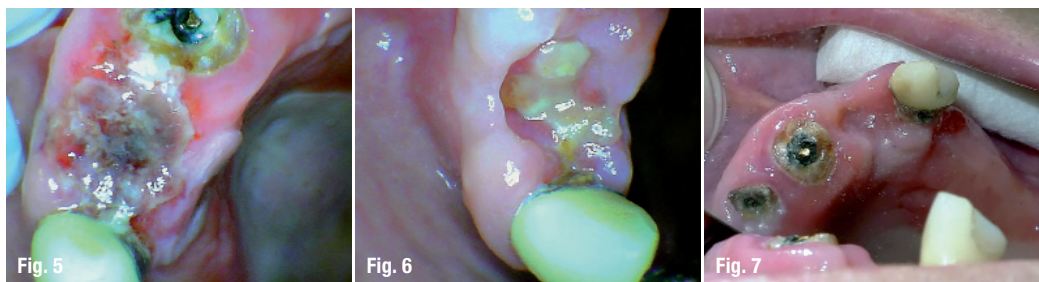




Fig. 5: The clinical situation following LLLT around the extracted tooth 12 after one day.

Fig. 6: The clinical situation of tooth 12 one week after surgery.

Fig. 7: The clinical situation of tooth 12 three weeks after surgery.

have the aforementioned advantages. In the meantime, we now have convincing long-term studies for diode lasers as well as numerous scientific studies that have shown positive results. Diode lasers are suitable for all patients, including those fitted with heart pacemakers (in contrast to electrosurgery). Additionally, patients can avoid being unnecessarily anaesthetised. The lasers are also extremely cost-effective and long lasting.

The advantages of the new three-diode laser

The SIROLaser Blue (made by Dentsply Sirona) is a third-generation laser and the world's first dental laser equipped with a blue (445 nm), infrared (970 nm) and red (660 nm) diode. In my view, combining three wavelengths in a single device that now only weighs a little more than 1 kg makes the new model user friendly. According to the manufacturer, it is suitable for 20 medical indications, and in terms of the treatment provided at my clinic, that includes primarily periodontitis, peri-implantitis, dentine hypersensitivity, herpes infection, endodontics, minimal-invasive laser surgery, the treatment of abscesses, for haemostasis and for gingivectomy. One practical feature is that the device can be programmed individually, although even the factory default settings save time and effort.

In my clinic, we mostly use red laser light (660 nm), as part of soft laser applications like low-level laser therapy (LLLT) and biostimulation. I use the infrared light (980 nm) for reducing germs in periodontology and endodontics. The blue 445 nm diode is used for incisions and advanced laser surgery. Every week I treat about 30 patients for periodontitis or peri-implantitis. Therefore, we prefer using curettage and de-epithelialisation. During surgery, I use the wavelengths 445 nm and 980 nm. To help wounds heal more quickly, I then follow up with the red laser light (660 nm) again.

Safe and precise contact-free incisions

Because blue light is absorbed much better by perfused soft tissue, the new 445 nm blue laser can also make better incisions at lower power than the infrared

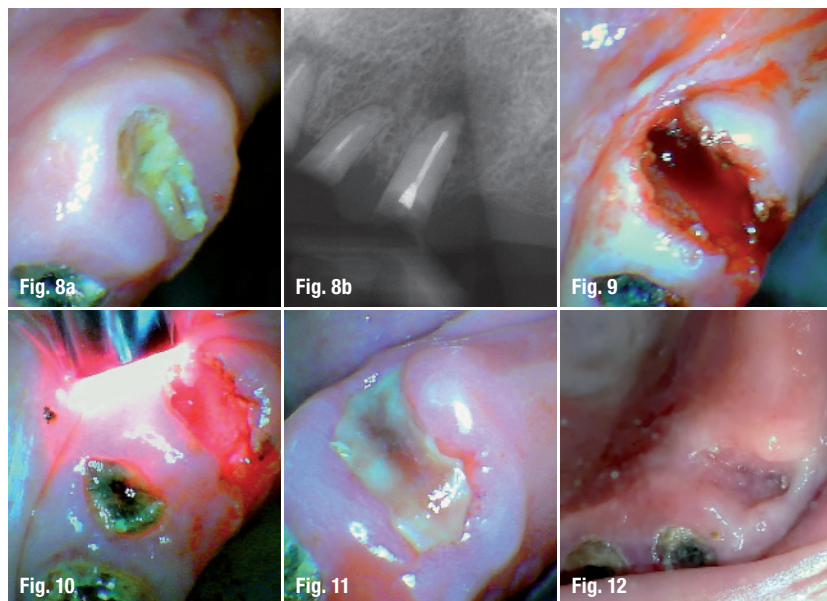
laser light. Non-contact incision is particularly practical because it means no coagulation at the instrument tip, more precise incisions and less bleeding. That makes it ideal for frenulum operations, for example. I also use the blue laser light for faster reliable light-curing of composites. In my opinion, the diode laser provides everything you need for the treatment of soft tissues and much more. A good example is the effective germ reduction in root canals. The diode laser provides more limited treatment opportunities when working with hard tissues such as bones and teeth. However, other types of lasers are available for this purpose.

Remarkable results: red light with low power

The red 660 nm diode is used for what are known as soft-laser applications (LLLT and biostimulation). When the wavelength is absorbed in the mitochondria and cytoplasm, a chemical reaction occurs. Therefore, the biological effect of low-level visible light therapy happens through photochemistry (probably by the photo activation of enzymes). This chemical reaction leads to biostimulation. Abergel et al. (1984) found that the irradiation of fibroblasts in culture at 633 nm stimulated the synthesis of collagen, which helps close the wound and prevent post-operative complications.¹ Furthermore, it was shown that the diode was beneficial in reducing the pain (Walker et al. 1987).² All in all, the positive effects of the red diode have been scientifically proven for 30 years, as recent reviews have shown.^{2,3}

Some studies by Tina Karu, an internationally recognised leader in the science of laser phototherapy, even showed that LLLT improves ATP production as well as DNA + RNA synthesis in the mitochondria.⁴ A study from Franca CM (2009) demonstrated a positive effect of low intensity red laser (660 nm) by preventing an oral mucositis.⁵ Tacon K C (2011) observed a faster wound healing after using the 660 nm diode.⁶

I absolutely agree with that. In my opinion, wounds heal much faster and with fewer complications after using red laser light, and the wound area is cleaner with less scarring. The risk of intimal hyperplasia is reduced and my patients generally no longer require



Figs. 8a & b: The same patient, remains of root of tooth 23 in situ, X-ray of the remains of root of tooth 23.

Fig. 9: Extraction of the remains of the root of tooth 23. Pre-treatment: before removing the remains of the root of tooth 23, the patient was lased with 445 nm laser light (800 mW, 25 Hz, 50 % duty cycle circular) to remove the remaining tissue around the root and prevent greater damage to the surrounding tissue.

Fig. 10: This was followed by lasing using red laser light (LLLT) for biostimulation (Fig. 10).

Fig. 11: The clinical situation one day after surgery.

Fig. 12: The clinical situation two weeks after surgery Figs. 11 and 12 highlight the speed of healing.

painkillers after surgery/extraction. Accustomed oral hygiene practices can be restarted again sooner. The swelling that often follows tooth extraction has also become rare at my clinic.

Red laser light can generally be used in many ways. As early as the 1990s, scientific studies showed it produced good results with dentine hypersensitivity (for current data: Gärtner 2013).⁷ LLLT is also successful for use in conjunction with xerostomia because it stimulates the salivary glands while at the same time promoting their regeneration.

In implantology, using LLLT after surgery causes less swelling, infection and pain and can stimulate wound healing (Heinemann & Braun 2013).⁸ The only side effect that I have observed so far is a possible reddening of the treated area due to the stimulation of blood flow.

Practical case study

For a patient of mine, an elderly man aged 82 (high blood pressure, medication with anticoagulants, diabetes), I conducted LLLT for biostimulation and thus better wound healing following the extraction of teeth 12 and 23. I also used it to avoid possible complications that would constitute even greater stress for his body. The individual steps are as follows:

- Following the extraction of tooth 12, the wound was lased within the framework of LLLT for 60 seconds using the red diode (660 nm) at 100 mW dose 6 J with an 8 mm probe at a distance of approximately 2 mm. Specifically, this meant lasing at 2 J buccal and lingual in contact mode, occlusal at a distance of approx. 0.5 cm for 20 seconds on each side (Figs. 1–4).
- Figures 5, 6 and 7 show the rapid healing of the wound one day, one week and three weeks after surgery.

- Figure 8 shows the initial situation for the same patient with the remains of the root of tooth 23.
- Here, I conducted the following pre-treatment: Before removing the remains of the root of tooth 23, the patient was lased with 445 nm laser light (800 mW, 25 Hz, 50 % duty cycle circular) to remove the remaining tissue around the root and prevent greater damage to the surrounding tissue (Fig. 9).
- This was followed by lasing using red laser light (LLLT) for biostimulation (Fig. 10).
- Figures 11 (the following day) and 12 (two weeks after surgery) highlight how quickly the wound healed.

The wounds did not need to be sutured. The patient subsequently did not experience any swelling and painkillers did not need to be administered. The older patient reacted positively and was pleased with both the procedure and the outcome of the extractions. He was happy to have been pain-free.

Conclusions for practice

Diode lasers (e.g. SIROLaser Blue, made by Dentsply Sirona) are suitable not only for treating inflammatory periodontal diseases, of which about one-third of today's adults suffer, but laser therapy is also valued by patients and users alike in surgery and restorative dentistry (e.g. endodontics, dentine hypersensitivity or fissure sealing). The new SIROLaser Blue model combines three diodes (blue, red and infrared) for different applications, for instance for precise cutting in non-contact mode during surgical procedures (blue diode at 445 nm). I regularly use the red diode (660 nm) for its biostimulatory effect. It speeds the healing of wounds, reduces postoperative complications such as pain and swelling and can even remove the need to suture wounds in some situations. User-friendly default settings and a compact design facilitate efficient use in dental practice for the patient's benefit.

contact

Dr Talat Qadri

Fjärdhundragatan 41 B
74530 Enköping, Sweden
Tel.: +46 17131261
info@Kamidental.se

Author details



Literature





CROIXTURE

PROFESSIONAL MEDICAL COUTURE



NEW COLLECTION

EXPERIENCE OUR ENTIRE COLLECTION AT WWW.CROIXTURE.COM

Eleven tips for success in your dental clinic

Part VI: Video Testimonials and R.A.P.P.O.R.T.

Author: Dr Anna Maria Yiannikos, Germany & Cyprus

Welcome to the sixth part of the series 'Eleven tips for success in your dental clinic'. Today I will teach you the last tip of this amazing series that I encourage you to use at your clinics in order to gain the power and control that you deserve.

Introduction

Due to the experience that I have gained from practicing dentistry over the last 25 years and drawn from my studies and research in medical business, today, I will present you an amazing new age tool: How to receive video testimonials from your patients—a tool with zero costs but a huge impact to

the patients' preference. Remember always to use your own patients and clinic for promotion. It has zero expenses and the best outcomes. By the end of this article, I will have given you all the answers concerning why are video testimonials important for us, how can we ask a patient to give us a video testimonial, what should the content be, when should we ask for it and finally and most critical the R.A.P.P.O.R.T. protocol.

Video Testimonials

Let me start with the concept of Video Testimonials. Why is this an essential promotion tool for us?



Research has proven that over 70 per cent of customers/patients look at a product/service review before accepting the service. A survey sponsored by Zendesk found that 90 per cent of participants were influenced in their buying decisions by positive reviews, which is an enormous amount of people. But how do you ask your patient for a video testimonial? Start with an email. This gives you the opportunity to make your request without any interruptions, without forgetting any details and most importantly: without putting your beloved patient on the spot.

I will provide you now with a significant sample of creative questions that you can use for your video testimonial in order to ensure its success:

1. For which reason did you choose us?
2. How have you experienced our services?
3. Can you think of a word or phrase that best describes your relationship to us? Why did you choose that particular word or phrase?
4. Why would you recommend us to someone else?

Now, you will ask me: When is the best time to ask a patient for a video testimonial? Right after a successful treatment, of course—when everyone is still on an emotional high level.

R.A.P.P.O.R.T protocol

Last but not least, I will introduce to you the R.A.P.P.O.R.T protocol which is the acronym of the words:

- R** for Reward them
- A** for Ask creatively (run a contest)
- P** for never be Pushy
- P** for ask for a written Permission
- O** for give them the script of the testimonial One day before
- R** for Run (post/share) it
- T** for videoTape it

The above tool is a very small part of the tools, ideas and protocols of the presentation skills module which is one of the ten modules that I teach during the DBA—Dental Business Administration Master-ship course. DBA is a mini MBA that will not only teach you ten different modules in only ten days but will also give you examples and exercises based on our routine dental life. It is the only educational programme that can show you how to gain the business success that you deserve. If you want to take your dental clinic to the next successful level, you have a choice—register now! I am looking forward to seeing you all.

During the next issue of laser magazine we will introduce a new series of business concepts that as always will assist you in revealing the opportunities and real potential of your dental clinic and staff. Until then, remember that you are not only the dentist of your clinic, but also the manager and the leader. You can always send me your questions and requests for more information and guidance at dba@yiannikosdental.com or via our website www.dbamastership.com. Looking forward to our next trip of business growth and educational development!_

contact



Dr Anna Maria Yiannikos

Adjunct Faculty Member of AALZ
at RWTH Aachen University
Campus, Germany
DDS, LSO, MSc, MBA
dba@yiannikosdental.com
www.dbamastership.com

Author details



Kurz & bündig

Im sechsten und letzten Teil der Serie „11 Tipps zum wünschenswerten Erfolg in Zahnkliniken“ geht die Autorin auf die Vorteile einer Patientenempfehlung via Videoaufnahme sowie das R.A.P.P.O.R.T PROTOCOL ein. Denn, wie zahlreiche Studien belegen, entscheiden sich die meisten Menschen auf Basis von Empfehlungen für einen Service bzw. ein Produkt. Um den Patienten nach einer erfolgreichen Behandlung nicht zu überrumpeln, empfiehlt die Autorin, eine Anfrage für die Aufnahme einer Videoempfehlung per E-Mail zu verschicken. Darüber hinaus formuliert sie vier kreative Fragen, die den Erfolg der Videoaufnahme garantieren sollen. Das R.A.P.P.O.R.T PROTOCOL bietet dabei eine effektive Anleitung zur erfolbringenden Umsetzung von Patientenempfehlungen.

In der nächsten Ausgabe der *laser* international magazine of laser dentistry beginnt eine neue Serie der Autorin. Hier wird sie in gewohnter Weise Tipps und Konzepte präsentieren, die Praxisinhaber dazu verhelfen sollen, die Möglichkeiten und das Potenzial ihrer Zahnarztpraxis voll auszuschöpfen.

Lasers as an asset in both daily practice and marketing

Author: Dr Imneet Madan, UAE



In the era of advanced technologies, patients' expectations are multiply increasing: They want to have the least invasive treatment procedure with only minimal bleeding, more effective healing, greater precision and the least number of appointments.

For many years now, lasers have been proven to be an effective device for a minimally invasive treatment. Nevertheless, any dental office that wants to implement lasers in its daily practice has to keep in mind several issues. These issues are:

- Safety
- Employee education
- Marketing
- Revenue channels
- Advantages.

Amongst the issues mentioned here, marketing is one that is very pivotal but in most cases not yet well prioritised. Although, current trends in practice do focus a lot on marketing. The winning edge of today's practice lies in a formula saying: "I project who I am." This philosophy brings forth the transparency of laser-based practice. Since the costs incurred to the patients are higher with laser treatments, the imperative as well as the benefits coming with lasers needed to be well known by the patients.

The Blue Ocean Strategy

Most corporations do smart things and also less smart things from time to time. In order to improve the quality of success, it is important to evaluate what has made the positive difference and understand how to replicate this in a systematic manner. It is also understood that the strategic move that matters centrally is to create blue oceans. The Blue Ocean Strategy challenges companies to break out of red oceans of conventional approaches and competition by creating uncontested market space that finally leaves any competition irrelevant.¹

Most corporations do smart things and also less smart things from time to time. In order to improve the quality of success, it is important to evaluate what has made the positive difference and understand how to replicate this in a systematic manner. It is also understood that the strategic move that matters centrally is to create blue oceans. The Blue Ocean Strategy challenges companies to break out of red oceans of conventional approaches and competition by creating uncontested market space that finally leaves any competition irrelevant.¹

The Blue Ocean Strategy in Dentistry

As stated by Masahiro Fujita, President of Sony's System Technological Laboratories: "The risk of not innovating is greater than the risk of innovating."

The success of brands relies on cutting an edge in the existing market. The introduction of dental lasers

is the most practical application of the principles of Blue Ocean strategy in the dental business. Marketing and treatment protocols can be well shaped in lines of this principle. Even though laser can prove to be a high end investment, the success and uniqueness that follows has been well researched and documented by several practitioners around the globe.

Investment above investment

The investment in laser devices for a company is an extra mile. Combining both hard and soft tissue lasers could add up to about 100,000 US\$ to the total cost of investment. Even though this amount sounds substantial in the initial stage, the return on investment with lasers can range between 280 to 600 per cent.² These kind of returns are possible when we successfully combine technological benefits with appropriate marketing strategies.

Changing patients' trends

The patients walking into the practice these days are "Drone Patients". Prior to their consultation, they like to read about possible procedures, optional treatments and latest advances. Since patients are partly aware of the technology, stating further benefits enhances their knowledge. Hence, decisions are made more easily and naturally in favour of lasers.

Benefits of lasers

The usage of laser in the daily dental practice is undoubted. From a practitioners point of view there are several benefits which basically can be divided into intangible and tangible benefits. Intangible benefits refer to the high technological status of lasers and the subsequent referrals that its reputation generates. Lasers do make the procedure easier and more comfortable for the patient. Almost all hard tissue procedures can be done without using anaesthesia. This certainly reduces the stress for the patient who normally relates dentistry with needles and drills. The most important factor in private practice is "Time Management", which ranks amongst tangible benefits. With lasers, multiple restorations can be performed in the same appointment as there is no numbness involved. Additional procedures like hygienist appointment and exam schedule with specialists can be also accommodated at the same time. This directly adds on to saving time and increasing profitability.³

More benefits of laser usage in the dental practice are:

Fear factor control

Most patients walking into the practice have dental fears or phobias for various underlying reasons. Their fears could be caused by negative past experi-

ences, a shared experience from someone close or just the anticipation of needles and drills. With lasers, the approach to dentistry becomes different. The need for anaesthesia is either completely ruled out or substituted by only a few drops of intergingival infiltration.

More certain prognosis

When it comes to the treatment of endodontically compromised teeth, lasers work quite accurate in combination with conventional treatment approaches. A recent approach of combining Diode and Erbium lasers has given vast success rates in grossly decayed teeth with peri-apical infections.

No drill dentistry

Since laser is a non-contact procedure, there is no pressure or touch sensation involved; this increases the patients' acceptance of the treatment.

No antibiotics after minor procedures

It has been a common trend to prescribe antibiotics after any kind of surgical intervention or in endodontically compromised teeth. With laser there is no scar formation, tissue healing is faster, site of interventions is more sterile; hence the need of antibiotics has decreased.

Marketing Fundamentals

Dr Philip Kotler defines marketing as "the science and art of exploring, creating, and delivering value to satisfy the needs of a target market at a profit. Marketing identifies unfulfilled needs and desires."⁴

Marketing, in simple terms, is a management process through which goods and services move from concept to customer. It includes the coordination of four elements called the four P's of marketing:

1. Identification, selection and development of a product,
2. Determination of its price,
3. Selection of a distribution channel to reach the customer's place, and
4. Development and implementation of a promotional strategy.

Changing trends

Over the years, marketing has evolved through three stages: Marketing 1.0, 2.0 and 3.0.

Marketing 1.0 was selling the factory's output of products to all who wanted to buy them. The products were quite basic and designed to serve a mass market. The goal was to standardise productions' costs so that goods could be priced lower and made be more affordable to buyers. This marketing strategy was part of the product-centric era.

Doctor ENGINEER an ARTIST

© artskvortsova/Shutterstock.com

Marketing 2.0 is the principle attached to marketing in current times which is information age where the core is information technology. Thereby, the job of marketing no longer stays simple. The golden rule of marketing 2.0 is: "Customer is King." Customers are better off as their needs and desires are prioritised.

Marketing 3.0 denotes a "Value Driven" era. This concept of marketing uplifts into the arena of human aspirations, values and spirits. It believes that consumers are complete human beings whose complete needs and hopes should never be neglected. Therefore, this principle complements emotional and human spirit marketing.

Lasers as a tool for Marketing 3.0

Marketing 3.0 incorporates lasers pretty well as it keeps in consideration the benefits to the patients, the producers credentials, and the high end technological status. The current age also follows the new Wave technology which enables connectivity and interactivity of individuals and groups. This enables the customers and the dentists to be well aware of the advances in lasers availability.

FDA approval for dental laser marketing

Applications for and research on lasers in dentistry continues to expand since their introduction to the dental profession. Dental laser systems are cleared for marketing in the United States via the Food and Drug Administration (FDA) Premarket Notification [510(k)] process. The review team de-

termines whether the product under review meets relevant criteria for "substantial equivalence" to a predicate device (the term "predicate" is used to describe any device that is marketed for the same use as the new device, even if the actual technologies are not the same).⁵

There are three key points in the marketing of dental lasers:

1. Efficiency: In a dental practice, efficiency is one of the key factors that draw the thin line between growth and failure. Efficiency is based on the application of technology. The more we succeed in incorporating the latest advances, the more we ensure that our practice is increasing revenues, enhancing patient experiences and expanding referrals. Efficiency in a practice accounts to increase the happiness quotient of both patient and dentist.
2. Reduced chair time: Speed is another major variable to consider when choosing the dental laser. Lasers are certainly a bit slower than the conventional drill, but this lapse of time does get well compensated with the fact that there is no waiting period of numbing involved.
3. Improved patient experience: Drill-free and no anaesthetic procedures are always more welcoming to the patients. Dental lasers create a virtually pain-free experience, which is a definite game-changer for the vast majority of patients.

The above mentioned points can be easily used as key markers in promoting dental lasers. Since there are umpteen amounts of data supporting these facts, patients can also be encouraged to search around online before booking in their appointments. Relevant information can be communicated by different forms of media:

- Social Media such as Facebook, Twitter, Snapchat, Instagram
- Advertisements through Radio or TV Channels
- School Screenings: information leaflets on lasers can be included along with the school dental reports. This makes information reach home and triggers the first step of curiosity to get to know more and use the service if or when required.

Laser marketing and practice

Dental lasers add a lot on the functioning of dental practices. They not only boost up the revenues, primarily due to the cost differences between laser and conventional treatments, but also improve the actual functioning of the practice in several manners.

Significant decrease in missed appointments

Pain is certainly an abstract phenomenon and its perception changes from one patient to another.

Having lasers in the dental practice with their added advantages certainly decreases the perception of pain to a large extent. Patients are no longer afraid to sit in the chair and receive the care they need. This helps decreasing the number of missed appointments.

Increased new patient volume

Satisfied patients add a lot to any practice. Dental lasers give dentists the opportunity to increase new patient referrals because of the unique experience lasers enable for existing patients. Patients feel so positively motivated that they talk about their experience to family and friends, thereby spreading the name of practice by word of mouth.

More referrals

Being unique projects the practice as a cut above the rest. This helps increasing the referrals from other practices and also from colleagues in the same practice. When the practice comes to be known as laser specialty practice, it becomes a known referral base for specific procedures and also for those who are technology-friendly.⁶

New procedures

Laser equips the dentist to perform a wide variety of procedures that could not be handled otherwise. The lack of anaesthesia, blood, sutures and minimal post-operative discomfort enables dentists to perform procedures such as labial and lingual frenectomies, fibroma removals to exposures, crown lengthening and much more. New procedures get added to a dentist's repertoire that would previously have been referred out or untreated. Many of these procedures can be performed during the same visit; thereby, increasing revenue growth without having to add a second appointment.

Conclusion

There has been a long road between the times when lasers were taken as the adjunct only for high end practices and procedures, to the current times, where laser is used as a regular armamentarium. In the world of marketing, lasers have brought dentistry to Blue Ocean. The frequent use of a laser by offices has resulted in a higher level of patient comfort, increased case acceptance for routine care, larger cases, and improved doctor productivity.⁷

Following the principles of the Blue Ocean Strategy, practices that offer compassionate care using advanced technologies such as lasers will be the offices that experience the largest influx of new patients in the future.

contact

Dr Imneet Madan

Specialist Pediatric Dentist
MSc Lasers Dentistry (Germany)
MDS Pediatric Dentistry
MBA (Hospital Management)
Children's Dental Center, Dubai
Villa 1020 Al Wasl Road, Umm Suqeim 1, Dubai,
United Arab Emirates
Tel.: +971 506823462
imneet.madan@yahoo.com
www.drmmichaels.com

Author details



Kurz & bündig

Patient und Behandler profitieren gleichermaßen von den positiven Eigenschaften einer Lasertherapie, auch wenn der Laser in der Anschaffung teuer und die Behandlung für den Patienten mit höheren Kosten verbunden ist. Umso wichtiger ist es daher, den Patienten umfassend über die Notwendigkeit und die Vorteile einer Laserbehandlung zu informieren. Hier hilft ein gut durchdachtes Marketing-Konzept.

Im Artikel stellt die Autorin die Blue-Ocean-Strategie vor. Diese soll Unternehmen dazu anregen, gewohntes Terrain zu verlassen und neue, innovative Wege in der Vermarktung ihrer Leistungen zu gehen. Der Dentallaser lässt sich dabei gut mit den Prinzipien der Blue-Ocean-Strategie verbinden. Für ein gewinnbringendes Laser-Marketing sind dabei vor allem drei Aspekte wichtig: die Herausstellung der Effizienz einer Lasertherapie, die verkürzte Behandlungszeit sowie das verbesserte Patientenerlebnis. Diese drei Aspekte lassen sich weiter ausbauen und anhand von Fakten belegen. Über verschiedenste Kanäle wie soziale Medien und Werbung in Radio oder TV werden die Informationen an den Patienten herangetragen. Unter Verwendung der Blue-Ocean-Strategie werden Zahnarztpraxen, die fortschrittliche Technologien wie den Laser in ihrem Praxisalltag selbstverständlich einsetzen, in Zukunft den größten Zulauf an Patienten haben.

Literature





Fig. 1

25th International Annual DGL Congress

Laser technology continues to fascinate

Author: Dr Georg Bach, Germany

When a dental society celebrates its 25th annual congress, this constitutes a significant event, as only a few societies are granted to prevail for a quarter of a century. If, moreover, a dental laser society celebrates its 25th annual congress, it is a remarkable event: compared to other European dental laser societies, the DGL assumes a unique position, both by being active

for 25 years and by being soundly established as a member of the DGZMK (German Society for Dental and Oral Medicine).

Therefore, DGL President and co-founder Prof. Dr Norbert Gutknecht insisted on organising this special anniversary congress. And it was not long until the well-earned success became visible: The lecture hall was brimming with more than 250 participants and many DGL associates and renowned speakers from Germany and abroad followed Prof. Dr Gutknecht's call to the Bavarian metropolis Munich.

The path towards laser dentistry

"Rocky and with small detours now and then"—the path towards laser dentistry (in Germany) can be described in those terms. Much like in implantology, the first impulses for this discipline derived from the daily practice and, another parallel to implantology, they were regarded with a sceptical eye and sometimes even criticised by universities. In spite of that, laser dentistry prevailed, mostly in the form of a renunciation of the "all-round laser", which can be applied universally in all fields of dentistry, and after defining lasers as an adjunct, highly effective tool for



Fig. 2



Fig. 3



Fig. 4

Fig. 1: A large audience presented at the two-day event on Munich's last Oktoberfest weekend.

Fig. 2: On Friday, 30 September, long-standing DGL members were awarded a certificate for their dedication, among them also Prof. Dr Norbert Gutknecht and Prof. Dr Mathias Frentzen.

Fig. 3: Parallel to the 25th anniversary congress, LASER START UP 2016 was held. Its scientific leader Dr Georg Bach opened the traditional education event on Friday.

Fig. 4: Dr Detlef Lutz and Dr Angela Wilke-Lutz were also among the awardees for long-standing membership.

special applications. The activities of RWTH Aachen University proved a special case of luck for the German laser users in dentistry, as Prof. Dr Gutknecht and Prof. Dr Angelika Lampert promoted scientific, evidence-based standards early on, thus providing credibility to the then-young discipline of laser dentistry.

These efforts were awarded with acceptance of the DGL by the DGZMK (German Society for Dental and Oral Medicine), which must be seen as one of the highlights of DGL's 25-year-old history.

The congress makers paid special tribute to this unique success story on the first congress day themed "From the origins of the DGL to new horizons".

DGL international

Almost 50 per cent of the speakers on this first congress day had travelled to Munich from abroad, which speaks for DGL's international attractiveness. As the DGL is among the world's oldest dental societies such as those in Japan and Brazil, the congress' list of speakers read like the Who is Who of international laser dentistry.

Dr Kenneth Luk from Hong Kong started the international contributions with his speech on the influence of different pulse durations on the microstructure of titanium implants. As is shown by the latest S3-Guideline "Periimplantitis" of the DGZMK and a number of implantological dental societies, the Er:YAG laser more and more forms the central part of laser applications in implantology.

The predominance of hard-tissue lasers (Er:YAG and Er,Cr:YSGG) in the scientific programme of the first congress day was noteworthy, with conservation forming the focal point of the contributions (Dr Riman Nasher, Sannaa, „Entfernung des Smearlayers mit dem Er,Cr:YSGG", Dr Ana Nogueira da Silva, Lissabon, „Composite auf laservorbereitete Zahnoberflächen", Dr Berchem Kalender, „Präparation im Hartgewebe" and Dr Tamara Al. Karadaghi, Bagdad, „Dentinpermeabilität nach Laserbestrahlung").

Basic research

The influence of laser wavelengths which are able to remove dental hard tissue and bone tissue on implant surfaces was discussed controversially. A working group from Aachen, Germany, led by Prof. Dr Gutknecht and Dr Fahlstedt succeeded in arguing that Er:CR:YSGG laser light will not cause root surface changes even at an irradiation of 0.75 and 1 Watt. The second "hard tissue wavelength", the Er:YAG laser, was investigated by another working group led by Dr Luk, with an energy density of 10.6 J/cm² leading to irreparable damages of the implant surface.

A very active working group formed by DGL veteran Dr Michael Hopp (Berlin, Germany) attested that 445 nm diode lasers, Er:YAG lasers and CO₂ lasers played only a minor role in tissue damages following laser cutting, whereas Nd:YAG lasers and diode lasers of a wavelength of 810 and 980 nm caused pronounced damage zones with continued bleeding at the incision margins. Conclusion: healing included an (desirable) primary healing prompted by Er:YAG laser application as well as a defect healing caused by other laser types (which should be avoided).

News from the realm of wavelengths

Prof. Dr Matthias Frentzen (Bonn, Germany), who has been among Germany's most important members of the DGL, has been the society's general secretary for many years. He also has been doing research on the development short-pulse laser applications in dentistry, which is why he decided to contribute a concise overview to the congress speeches.

The audience proved receptive for Prof. Frentzen's main message: research and development of new ultrashort-pulsed lasers, which will replace the more complicated and less efficient excimer-lasers in the removal of dental hard and bone tissues, has been accelerated in such a way that soon high-performance and compact short-pulse laser sources will be available. The associated findings will have a positive influence on the further development of Er:YAG and CO₂ lasers.




Fig. 5



Fig. 6

Fig. 5: And the winner is ... Eva Speck (DGL) and Sebastian Kiehne, Sales Manager Instruments at congress sponsor Dentsply Sirona, were happy to announce the winner of the SIROLaser Blue prize draw.

Fig. 6: The scientific congress was completed by an extensive industry exhibition.

Prof. Dr Andreas Braun (Marburg, Germany) has also been exploring new territory. He reported on the clinical application of the latest diode-laser wavelength. While until recently only diode lasers of a wavelength of 810–980 nm were available, a semiconductor laser of 445 nm has now been introduced to the market. This new diode laser wavelength from the blue spectre can promote the coupling of energy to pigmented tissue cells, thus ensuring a good surgical cutting at lower penetration depths and a reduced risk of damage to underlying tissues.

Dr René Franzen (Aachen, Germany) and colleagues introduced their research results on the 445 nm diode laser when applied endodontologically, attesting strong bactericidal properties to the blue wavelength in their in-vitro study.

Dr Ralf Borchers and Prof. Marcia Marques also dedicated their speeches to diode lasers, if under different circumstances. While Dr Borchers compared the effect of diode laser light when applied in cw and superpulse mode on soft tissues and noted significant advantages in the superpulsed diode lasers, Prof. Marques illustrated a special diode laser treatment: low-level laser therapy (low energy), which is mainly used to treat wound-healing disorders and pain.

The working group led by Prof. Dr Heinrich Wehrbein (Mainz, Germany) took up the cudgels for LLLT applications by noting a significantly reduced retention time and relapse rate after palatal expansion and LLLT application.

Parts of the first congress day as well as the complete second day were dedicated to indications of current laser dentistry. Let me say that much: it is simply incredible what has happened in this field during the last quarter of a century. The variety of laser-aided therapies is remarkable. In particular since those new forms of therapy are not just laser-aided applications in hard-tissue (tooth and bone) such as laser-aided endodontics and implantology (periimplantitis treatment).

The assiduous Aachen working group uses Er,Cr:YSGG laser to remove implants that cannot be saved. This approach is, according to the group, superior to conventional methods (Trepan) and guarantees best possible tissue protection. Although most of the scientific contributions at the 25th annual congress of the DGL concerned conventional approaches, there was a clear orientation towards new horizons: laser systems are being growingly employed in areas such as orthodontics (Dr Peter Kleemann, Luxembourg), oral and maxillo-facial surgery (Prof. Siegfried Jänicke, Osnabrück) and diagnostics (Dr Thorsten Kleinert, Berlin).

Dr Kleemann, a colleague from Luxembourg, presented laser-aided procedures in orthodontics with various wavelengths, thus showing a real cornucopia of laser applications with the suitable laser equipment.

Laser procedures in various specialized areas

If a certain procedure or technique, for example the dental laser, becomes an accepted dental discipline, it is inevitable that combination therapies are formed which will spread to other specialized areas. This phenomenon can be observed with laser dentistry. Hence, Prof. Frank Liebaug talked about the combination of laser and hyaluronic acid (he sees in this promising duet the chance to revolutionize periodontitis therapy). In addition, Dr. D. Moghtader presented his findings on laser-aided snoring therapy and went into questions of its legal legitimacy.

Looking back on the days spent in Berlin, one thing is certain: 25 years of DGL and a stimulating and multi-layered congress made travelling to the capital utterly worth it!_

contact

Dr. Georg Bach
Fachzahnarzt für Oralchirurgie
Rathausgasse 36
79098 Freiburg im Breisgau

Author details



Return address:

Deutsche Gesellschaft für Laserzahnheilkunde e.V.
c/o Universitätsklinikum Aachen
Klinik für Zahnerhaltung
Pauwelsstraße 30
52074 Aachen, Germany

Tel.: +49 241 8088164
Fax: +49 241 803388164
Credit institute: Sparkasse Aachen
IBAN: DE56 3905 0000 0042 0339 44
BIC.: AACSD33

Membership application form



Name/title: _____
Surname: _____
Date of birth: _____
Approbation: _____

Status: ☐ self-employed ☐ employed ☐ civil servant ☐ student ☐ dental assistant

Address:

Street: _____ Phone: _____
ZIP/city: _____ Fax: _____
Country: _____ E-Mail: _____

With the application for membership I ensure that

- ☐ I am owning an own practice since _____ and are working with the laser type _____ (exact name).
☐ I am employed at the practice _____
☐ I am employed at the University _____

I apply for membership in the German Association of Laser Dentistry (Deutsche Gesellschaft für Laserzahnheilkunde e.V.)

Place, date

Signature

Annual fee: for voting members with direct debit € 150

In case of no direct debit authorisation, an administration charge of € 31 p.a. becomes due.

DIRECT DEBIT AUTHORISATION

I agree that the members fee is debited from my bank account

Name: _____ IBAN: _____
BIC: _____ Credit institute: _____

Signature of account holder

This declaration is valid until written notice of its revocation

BIOLASE

New diode laser introduced at GNYDM

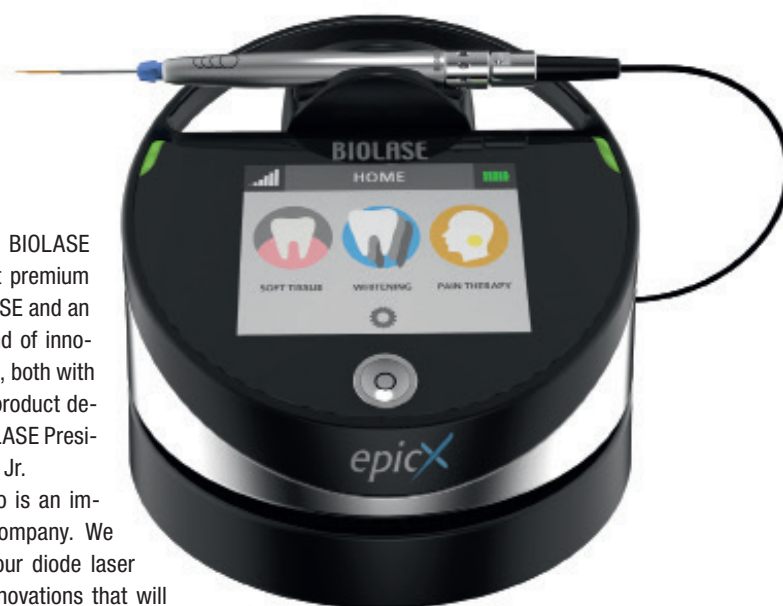BIOLASE has introduced Epic Pro, an all-new innovative dental diode laser system, at the upcoming Greater New York Dental Meeting (GNYDM) on Nov. 25–30 in New York. According to the company, the Epic Pro offers the most laser power of any diode laser in dentistry and is the first product resulting from BIOLASE's strategic development agreement with laser technology specialist IPG Photonics.

The newest addition to the EPIC series of dental soft-tissue lasers features new superpulse technology for more precise, enhanced laser tissue cutting; real-time automatic power control to enhance speed and consistency when performing surgery; and pre-initiated, bendable, disposable tips with new smart tip technology to ensure tip performance and quality.

Compared with other products currently available on the market, the new system will provide a more predictable, minimally invasive solution

for soft-tissue management, BIOLASE stated. It represents the first premium grade diode laser from BIOLASE and an important example of the kind of innovation BIOLASE is working on, both with IPG and through its internal product development efforts, noted BIOLASE President and CEO Harold C. Flynn Jr.

"The introduction of Epic Pro is an important milestone for our company. We are proud to be expanding our diode laser range to incorporate new innovations that will allow dental professionals to manage soft tissue with lasers in a way that no other diode laser has achieved," Flynn said. "Epic Pro represents our ongoing commitment to elevating the standard of care in dentistry, and achieving better patient reported outcomes while enabling clinicians to realize better business returns. We are very excited about the possibilities offered to



our customers by this new technology addition to our portfolio."

BIOLASE, Inc.
4 Cromwell
Irvine, CA 92618, USA
www.biolase.com

LASOTRONIX

SMART™ dental diode laser—Versatile and functional

LASOTRONIX is proud to present the diode-based laser platform especially designed for dentistry, the SMART™ series. SMART™ laser is offered

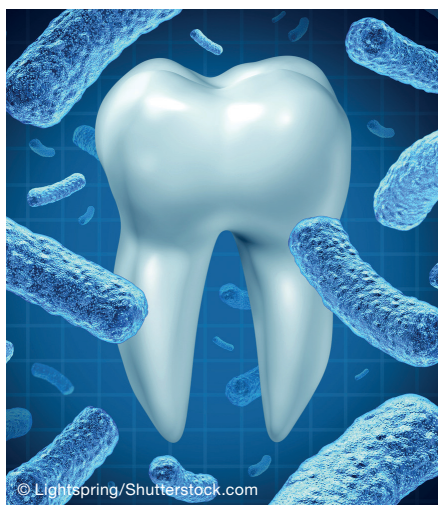as a combination of two lasers in one package: 10W at 980nm wavelength for a wide range of applications in microsurgery, endodontics, perio-

dontology, pain therapy and whitening as well as 400 mW at 635 nm wavelength for cold therapies like biostimulation and PAD (Photoactivated Disinfection). Combining two wavelengths in one device made SMART™ laser a unique and advanced application for all soft tissue procedures in dentistry.

Thanks to thoughtful design that allows integration with the dedicated workstation or a dental unit, SMART™ laser meets the needs of every dental office and assures perfect operation comfort. In addition, accessories such as a wide range of fiber delivery systems, application end tips and a variety of surgical handpieces provide maximum versatility. As a result, the SMART™ laser is suitable for a vast number of therapies. If you want to join us and promote our innovative products please kindly contact us via E-Mail: mp@lasotronix.pl.



LASOTRONIX
Żytnia 1 str.
05-500 Piaseczno, Poland
www.lasotronix.com



New organic toothpaste may

Inhibit harmful bacteria

A Seoul dentist has developed an all-natural toothpaste that aims to reduce the health risks posed by *Streptococcus gordonii*, an oral bacterium that initiates dental plaque formation. Once in the bloodstream, which it may enter through bleeding gingivae, for example, the bacterium also causes blood clots, which can lead to life-threatening conditions such as infective endocarditis, heart attack or stroke.

South Korean dentist Dr Hyung-Joo Moon, head of the Moon Dental Hospital in Seoul, recently obtained the patent for his bacteria-inhibiting organic formula from the Korean Intellectual Property Office. Inspired by a joint study by the Royal College of Surgeons in Ireland and the University of Bristol, which found that *S. gordonii* can trigger an infection of the inner lining of the heart when entering the bloodstream, Moon started developing a toothpaste that especially inhibits the growth of these bacteria.

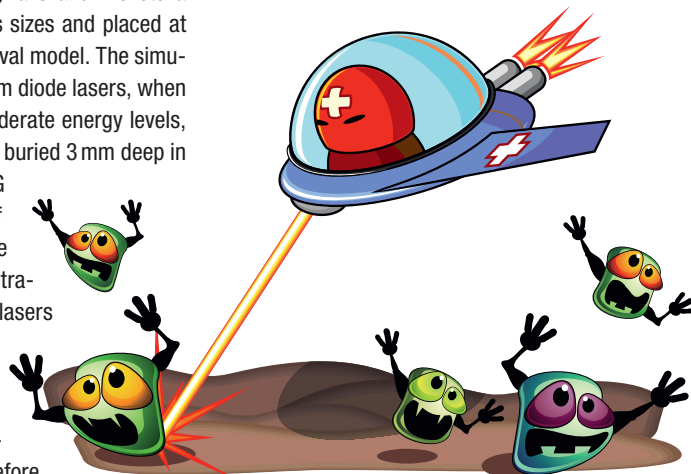
The toothpaste's anti-inflammatory ingredients include neem and castor oil, herbal extracts made from psyllium seed, Japanese star anise, and Japanese cornelian cherry. As the oral mucosa is very susceptible to absorbing harmful substances into the body, it is especially important to use natural ingredients for oral care products, he emphasised. Tested among his patients, the toothpaste's formula proved to help relieve inflammation, as well as sore gingivae and toothache. The toothpaste is not available for purchase yet, but Moon is working on releasing it to market soon.

Computer simulations show

Lasers effective in killing oral bacteria

A team of researchers at the New York Institute of Technology in the US has developed a computer model that demonstrates how dental lasers attack oral bacterial colonies in gingival tissue. Based on the optical characteristics of gingival tissue and pathogenic microorganisms, the researchers developed a mathematical model that simulates the periodontal procedure of laser subgingival debridement. The virtual colonies, consisting of *Porphyromonas gingivalis* and *Prevotella intermedia*, were of various sizes and placed at different depths in the gingival model. The simulations indicated that 810 nm diode lasers, when set to short pulses and moderate energy levels, are able to destroy bacteria buried 3 mm deep in the gingival tissue. Nd:YAG lasers with a wavelength of 1,064 nm also proved to be effective with similar penetration depth. Moreover, both lasers spare the healthy tissue, the researchers found. Their simulations showed minimal heating of the surrounding tissue and therefore

minimal thermal damage, which leads to faster healing, Reinisch explained. According to him, the simulations validate the effectiveness of dental lasers in removing oral bacteria and contributing to better oral health after periodontal treatment. The study, titled "Selective photoantiseptics," was published in the October issue of *Lasers in Surgery and Medicine*, including video depictions of the computer simulations.



© Mjak/Shutterstock.com

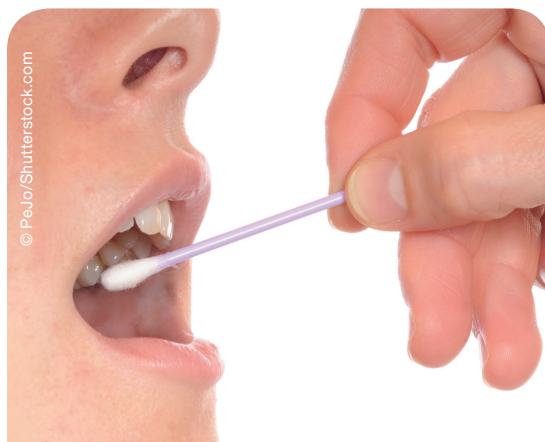Japanese company introduces

Five-minute dental screening

New saliva test from Japan analyses various oral parameters in a matter of minutes. According to Lion Corporation, which developed the Salivary Multi Test together with Aichi Gakuin University's School of Dentistry, the device can identify markers associated with oral health, such as the quantity of cavity-causing bacteria and number of white blood cells, using just a small sample of saliva. In addition to the Sali-

vary Multi Test Meter—the actual measuring instrument—a computer, a printer, test paper and software (available for Windows and macOS) are needed for analysing the saliva samples. After applying the saliva to the test paper, the patient's individual results are visualised in a radar chart on the computer monitor.

Items tested include salivary acidity, leukocyte count, ammonia values and the presence of fungi. According to Lion, six items can be measured simultaneously in one analysis and test results can be obtained within 5 minutes. More information about the system is available on the company's website, lionpro.lionshop.jp (in Japanese only), through which the system is exclusively sold.



© PeJo/Shutterstock.com

NEUERSCHEINUNG

Jahrbuch Laserzahnmedizin 2017

Interdisziplinär und nah am Markt

BESTELLUNG AUCH
ONLINE MÖGLICH



www.oemus.com/abo



Lesen Sie im aktuellen
Jahrbuch folgende Themen:

Klinische Fallberichte

Aktuelle Forschungslage

Gesamtübersicht Detallasermarkt

Vorstellung Dentallaser/
Photodynamische Systeme

Weihnachtsaktion

Preis pro Jahrbuch 2016

ab **24,50 €***

statt ab 49 €

gültig bis 31.12.16

Fax an **0341 48474-290**

Senden Sie mir folgende Jahrbücher zum angegebenen Preis zu:

Bitte Jahrbücher auswählen und Anzahl eintragen.

_____	Laserzahnmedizin 2017	49,00 Euro*
_____	Endodontie 2017	49,00 Euro*
_____	Digitale Dentale Technologien 2016	24,50 Euro*
_____	Prävention & Mundhygiene 2016	24,50 Euro*
_____	Implantologie 2016	34,50 Euro*

*Preise verstehen sich zzgl. MwSt. und Versandkosten. Entseigelte Ware ist vom Umtausch ausgeschlossen.

Name/Vorname

Telefon / E-Mail

Unterschrift

Praxisstempel

laser 4/16

Rückblick & Ausblick



Prof. Dr. Norbert Gutknecht

Sehr geehrte Frau Kollegin, sehr geehrter Herr Kollege,
liebe Mitglieder der verschiedenen Gesellschaften,
liebe Freunde der Lasertechnologie,

in dieser letzten Ausgabe des *laser international magazine of laser dentistry* möchte ich einen kurzen Rückblick über das vergangene Jahr 2016 halten. Den Höhepunkt bildete der Weltkongress der WFLD in Japan unter der Leitung von Prof. Kenji Yoshida. Hier trafen sich sowohl wissenschaftlich tätige Kollegen aus den verschiedensten Universitäten als auch praktisch tätige Kollegen, um neuste Forschungsergebnisse, Therapiekonzepte und praktische Erfahrungen auszutauschen und zu diskutieren.

Was auf großer Bühne in Japan international stattfand, wurde auch in vielen Ländern auf nationaler Ebene durchgeführt. Dabei konnte man sehr gut feststellen, dass nicht nur neue Laserwellenlängen in die Zahnheilkunde eingeführt wurden, sondern dass auch mit den bereits etablierten Lasersystemen neue therapeutische Felder belegt werden können.

Im Ausblick auf das neue Jahr 2017 bin ich gespannt, inwieweit wir auf der IDS (Internationale Dental-Schau, Köln) weitere technische Neuheiten im Lasersegment bewundern werden können.

In der Zwischenzeit wird das alte Jahr zu Ende gehen und ein neues beginnen, weshalb ich ihnen an dieser Stelle alles erdenklich Gute für das Jahr 2017 wünschen möchte.

Allen Leserinnen und Lesern, die das Jahr mit dem Weihnachtsfest ausklingen lassen, wünsche ich auch eine harmonische und gesegnete Weihnachtszeit.

Ihr

Prof. Dr Norbert Gutknecht





Wundheilung nach Inzision oraler Schleimhaut mit einem 445 nm Diodenlaser

Dr. Dr. Paul Günther Baptist Heymann, Dr. Dr. Thomas Ziebart, Dr. Anne Attrodt, Dr. Dr. Christine Moll,
Dr. Dr. Frank-Hendric Kretschmer, Dr. Johannes-Simon Wenzler, Prof. Dr. Dr. Andreas Neff,
Prof. Dr. Andreas Braun, Marburg, Germany

Im Rahmen der Studie sollte die Schneideffizienz und die Wundheilung nach Inzision mit einem neuartigen dentalen Halbleiterlaser (Wellenlänge 445 nm) untersucht werden. Im Fokus stand die Beurteilung von Behandlungszeit als auch das Heilungsverhalten nach Laserinzision im Vergleich mit dem Skalpell.

Im Rahmen der Studie wurden zwei vergleichbare operative Eingriffe bei 15 Patienten im Mundraum durchgeführt. Studienarm I beschreibt die Inzision der Mundschleimhaut mit einem Skalpell versus Studienarm II: Inzision der Mundschleimhaut mit einem 445 nm Halbleiterlaser (445 nm, cw, 2 W). Im Rahmen der Nachuntersuchung wurden die Parameter „verbliebene Wundfläche“ (VWF), Gewebekolorimetrie (GK), Behandlungsdauer und Patientenempfindung erfasst. Die Wundfläche wurde anhand standardisierter Fotografien (Helligkeit, Abstand und Winkel) zu den Zeitpunkten direkt nach

dem Eingriff sowie eine Woche, zwei Wochen, einen Monat und zwei Monate nach dem Eingriff festgehalten.

Es zeigte sich eine signifikant erhöhte Behandlungsdauer bei Laserinzision im Vergleich zur Inzision mit dem Skalpell. Postoperativ wurde eine Reduktion des Schmerzempfindens bei Laserinzision im Vergleich zur Skalpelinzision beobachtet. Bei Begutachtung der klinischen Situation nach Laserinzision wurde eine Verminderung von postoperativen Komplikationen wie Infekten und Dehiszenzen beobachtet.

Die im Rahmen der Studie gewonnenen Ergebnisse zeigen, dass eine Inzision oraler Schleimhaut mit einem dentalen Halbleiterlaser der Wellenlänge 445 nm im Vergleich zu einer Skalpelinzision länger dauert, allerdings postoperativ zu geringeren Schmerzen und weniger Infekten sowie Dehiszenzen führt.

Welchen zusätzlichen Wert hat das neue Scanhandstück des Fotona LightWalker Er:YAG Lasers in der Implantatchirurgie?

Dr. Ingmar Ingenegeren, M.Sc. M.Sc., Bottrop, Germany

Ziel der Arbeit: Die Evaluation der Anwendungsmöglichkeit des Er:YAG-Scanhandstücks zur Erlangung einer präziseren Knochenkavität zur Implantatinserion.

Material und Methode: Der Fotona LightWalker AT mit Er:YAG und Nd:YAG (2.940 nm und 1.064 nm) mit dem neuen Scanhandstück (nach der Universität Aachen erste Installation in einer Praxis in Deutschland) wurde erprobt an Eiern, Knochen, Fleisch und *in vivo* bei der Implantatbettpräparation bei mehreren Patienten, um den erhofften Vorteil des Scanners zu testen. Es wurde in allen Bereichen mit unterschiedlichen Parametern gearbeitet, um eine optimale Einstellung herauszufinden. Pulslänge von MM (max mode) zu SSP (super short pulse) und Leistung von 0 bis 1.500 mJ. Des Weiteren wurde zur Implantatbettpräparation das tiplose Er:YAG-Handstück und das Er:YAG-Handstück mit Tips angewandt, um einen Modus zur Verbesserung der Präzision der Knochenkavität zu finden.

Ergebnisse: Auf der Eierschale produzierte der Scanner korrekte quadratische oder runde Stellen, wie im Prospekt gezeigt. Auf kompaktem kortikalem Knochen (D1, D2) wurden runde Krater erzielt, mit voreingestellter Tiefe von 1–2 mm und im spongiosen Knochen (D3, D4) waren die Kavitäten weniger definiert, verursacht durch die offene trabekuläre Struktur. Nur mit dem MM konnten tiefere Krater

erreicht werden. Sie waren konisch und bis 10 mm tief und somit geeignet für Kompressionsimplantate. Auf Fleisch fand lediglich eine oberflächliche Karbonisation statt.

Diskussion: Für eine transgingivale Knochenpräparation ist der Scanner nicht geeignet: Es wird lediglich eine oberflächliche Weichgewebeschicht ablatiert, was aber geeignet ist für eine Deepithelisation oder Karbonisation. In eine aufgeklappte Wundsituation ist Geschicklichkeit vonnöten, um das relativ große Scanhandstück zu manipulieren, sodass jeder Scanzzyklus den vorherigen exakt überlappt, um eben die gewünschte Kavitätsform zu erreichen. Die erreichte Tiefe ist begrenzt und das Vorgehen wird eindeutig durch Blut und Patientenbewegungen beeinträchtigt. Durch das umständliche Hantieren *in vivo* ist es nicht möglich, gleiche, oder annähernd ähnliche Resultate wie bei einer Labortestaufstellung zu erhalten. Der konische Krater, geeignet für ein Kompressionsimplantat, hat keine exakten vorhersagbaren Abmessungen. Durch die unsichere Richtungsbestimmung und die erschwerte präzise Aufsetzung ist der MM *in vivo* (noch) nicht anwendbar. Obwohl für Schmelz- und Dentinpräparation, KFO und Schnarchtherapie das Scanhandstück seine Berechtigung hat, lässt sich kein zusätzlicher Wert für die Implantatbettchirurgie erkennen.



Einfluss eines 445 nm Diodenlasers auf das Debondingverhalten von Keramikbrackets

Dr. Steffen Stein, Prof. Dr. Heike Korbmacher-Steiner, Prof. Dr. Andreas Braun, Marburg, Germany

Ziel: Untersuchung zum Einfluss eines 445 nm Diodenlasers auf das Debondingverhalten von Keramikbrackets.

Material und Methode: 30 Keramikbrackets wurden auf planen, standardisierten Schmelzoberflächen von 15 extrahierten und kariesfreien Weisheitszähnen standardisiert geklebt. Jeweils ein Bracket einer Probe wurde vor der Entfernung mit einem 445 nm Diodenlaser standardisiert und verblindet bestrahlt (Lasergruppe; n=15), das andere Bracket wurde ohne Laserapplikation entfernt (Kontrollgruppe; n=15). Vor der Bracketklebung (T0), nach der Bracketentfernung (T1) und nach der Entfernung der Kunststoffreste (T2) mittels rotierender Instrumente auf der Zahnoberfläche wurden mikroskopische Aufnahmen der Schmelzoberfläche in 10x und 20x Vergrößerung zur Bestimmung von Schmelzausrissen und des Adhesive Remnant Index (ARI) angefertigt. Sieben Proben jeder Gruppe wurden zu den genannten Zeitpunkten abgeformt, um die

Schmelzoberfläche auf Schmelzausrisse im Rasterelektronenmikroskop unter 200x und 500x Vergrößerung zu begutachten.

Ergebnisse: Der ARI-Score wurde bei 10x und 20x Vergrößerung in der Lasergruppe im Vergleich zur Kontrollgruppe statistisch signifikant ($p < 0,05$) reduziert. Schmelzausrisse wurden unter 10x und 20x Vergrößerung in beiden Gruppen nicht gefunden. Unter 200x und 500x Vergrößerung im Rasterelektronenmikroskop wurden vermehrt Schmelzausrisse und Schleifspuren in der Kontrollgruppe zum Zeitpunkt T2 gefunden.

Schlussfolgerungen: Durch die Anwendung des 445 nm Diodenlasers vor der Bracketentfernung wird das Debondingverhalten signifikant beeinflusst und es kommt zu weniger Restadhäsiv auf der Schmelzoberfläche. Dieses Ergebnis ist von klinischer Relevanz, da das Risiko von Schmelzschäden und die Behandlungszeit während der Bracketentfernung reduziert werden können.

Können Hyaluronsäure und Laser die regenerative Parodontitistherapie revolutionieren? – Klinische Beobachtungsstudie über zwei Jahre

Prof. (Jiaoshou, Shandong University, China) Dr. med. Frank Liebaug, Ellen Institut, Steinbach-Hallenberg, Germany

Hyaluronsäure ist aufgrund ihrer Eigenschaften in vielfältiger Weise auch für die Zahnheilkunde sehr interessant. In den letzten Jahren hat es im Bereich der allgemeinen zahnärztlichen, aber auch insbesondere der parodontologisch und oralchirurgisch orientierten Praxis dank Lasereinsatz bemerkenswerte Therapie-

strategien und positive Ergebnisse gegeben. Wie die additive Applikation von Hyaluronsäure die klinischen Ergebnisse im Rahmen der Parodontitistherapie beeinflusst, soll eine klinische Beobachtungsstudie über zwei Jahre und der Einbeziehung von mehr als 1.500 Zahnfleischtaschen näher beleuchten.

Antibakterielle laserinduzierte Photodynamische Therapie – Geschichte, Grundlagen, Anwendung

Dr. Hubert Stieve, Rendsburg, Germany

Inhalt:

- Geschichte der PDT, Tappeiner, München
- PDT ist in etlichen medizinischen Fachbereichen eine etablierte Standardbehandlung
- Antibiose-Problematik generell und spezifisch bei dentaler Plaque
- Keimresistenzen Laser-Basics
- Interaktion Wellenlänge-Zielgewebe/Zielorganismus
- Vorbedingungen und Schritte der Anwendung bei Gingivitis/marginaler Parodontitis/Periimplantitis 810 nm Diodenlaser/Smart Laser
- Bedingungen für Delegierbarkeit der PDT
- weitere kleinere Indikationen für den Einsatz von 810 nm Lasern
- Benefit für Praxis und Patienten



Implantologie – von der Freilegung zum fertigen Zahn in einer Sitzung

Dr. Thorsten Kuypers, M.Sc., Köln, Germany

Durch das Zusammenspiel des Lasers und der CEREC Omnicam sind Freilegung und Versorgung eines eingeleiteten Implantates nun in einer Sitzung möglich. Bei ausreichendem Angebot an Weichgewebe ist die Freilegung mittels Erbiumlaser bei uns Mittel der Wahl. Durch die aktuelle Soft- und Hardware des CEREC-Systems kann dann di-

rekt im Anschluss die fertige Restauration hergestellt und definitiv eingesetzt werden. Die Vorgehensweise dieses Verfahrens soll anhand eines üblichen Falls dargestellt werden. Eine perfekte Passung, begeisterte Patienten, eine enorme Zeitersparnis und Wirtschaftlichkeit machen diese Behandlung zu einer kleinen Revolution.

Kontamination von optischen Fasern im Rahmen endodontischer Laserapplikation

Dr. Marcus Krema, Hachenburg, Germany

Based on the results available, the infection of root canals from teeth with pulpa necrosis with or without periapical lesions are evidence-based. Therefore, the risk of a cross-contamination during an endodontic treatment between different root-canals of the same tooth is given. The aim of the study was to examine if there is a contamination of the surface of a laser-fibre after conventional chemo-mechanical endodontic treatment and as a consequence a risk of cross-contamination by these optical fibres.

Materials and methods: 45 parts of an optical fibre were contaminated with *E. faecalis* in an *in-vitro* study to evaluate effective methods of disinfection. Five groups were built. A control-group without any disinfections arrangements, wiping disinfection, the insertion in alcohol 70 % for 15 min, the combination of these two methods and the sterilisation process by an autoclave. In the *in-vitro* study, ten teeth by nine patients with suspicion of pulpa necrosis with or without periapical lesions were examined. Five groups were established. Before the root-canal treatment (rct) a sterile paper point was put into the root canal and than placed on an Agar-Plate. After the chemo-mechanical rct with a modified

technique of the ProTaperNext™ system, a further sterile paper-point was examined. Than the optical fibre was disinfected, used in the root-canal for disinfection of the wall and the underlying dentin. After three treatments each, the fibre was scratched out on the Agar-Plate.

Results: The *in-vitro* study showed a heavy infection on all fibre parts in the control-group. All other disinfection-methods were effective for a bacterial issue (one failure in the combination group). The *in-vitro* study showed that a heavy infection of each root-canal was present before the endodontic treatment. There is no additional growth of bacteria neither on the paper point after conventional root-canal treatment nor on the optical fibre scratches.

Conclusion: There is no contamination on the surface of the fibre after using it for the decontamination of the root-canal and the underlying dentin following the described chemo-mechanical root-canal treatment and disinfections methods. Therefore, by using the described methods, a cross-contamination by an optical fibre between two root-canals of the same teeth of one patient is probably not given.

Ist eine Laserschnarchtherapie für Zahnärzte rechtlich zulässig?

Dr. Darius Moghtader, Oppenheim, Germany

Immer mehr Zahnärzte beschäftigen sich mit der Schlafmedizin und damit auch mit der Therapie des Schnarchens. Eine anerkannte Methode ist die Vorverlagerung des Unterkiefers mit einer Protrusionsschiene. Dabei ist es unstrittig, dass die Schnarchtherapie mit Schienen von Zahnärzten durchgeführt werden darf. Neben dieser symptomatischen Therapie werden neuerdings auch kausale Therapieformen mit Laser

entwickelt. Diese Lasertherapien zielen darauf ab, erschlafftes Gewebe zu straffen und damit das Schnarchen zu reduzieren oder zu verhindern. Nun stellt sich die Frage, ob diese neuen Therapieformen im Rahmen des Zahnheilkundengesetzes ausgeübt werden dürfen. Dieser Vortrag analysiert am Beispiel des SNORE3-Verfahrens der ellexion AG den Status quo und gibt erste Antworten auf rechtliche Fragen.

FÜR JEDE KLINISCHE INDIKATION DAS OPTIMALE SYSTEM

LASER EINFACH, SICHER & SANFT



www.henryschein-dental.de

HENRY SCHEIN DENTAL – IHR PARTNER IN DER LASERZAHNHEILKUNDE

Wir bieten Ihnen ein breites und exklusives Sortiment marktführender Lasermodele verschiedener Hersteller an.

Unsere Laserspezialisten beraten Sie gern über die vielfältigen Möglichkeiten und das für Sie individuell am besten geeignete System.

Laser ist nicht gleich Laser und genau hier liegt bei uns der Unterschied:

Sie, Ihre Patienten und Ihre gemeinsamen Bedürfnisse stehen bei uns an erster Stelle.

Bei Henry Schein profitieren Sie vom Laserausbildungskonzept!

Von der Grundlagenvermittlung über hochqualifizierte Praxistrainings und Workshops zu allen Wellenlängen bis hin zu Laseranwendertreffen.

Unsere Laser-Spezialisten in Ihrer Nähe beraten Sie gerne.

FreeTel: 0800-1400044 oder FreeFax: 08000-404444

Erfolg verbindet.

 **HENRY SCHEIN®**
DENTAL



Laserunterstützte Kariesdiagnostik – Evidenz und klinische Relevanz

Olaf Oberhofer M.Sc., Erwitte, Germany

In den letzten zwei Jahrzehnten hat sich die Prävalenz von Karies als Resultat erfolgreicher Präventionsprogramme verändert. Das Erscheinungsbild von Karies hat sich ebenfalls verändert. Die meisten beginnenden kariösen Läsionen entstehen unterhalb des intakten Schmelzes oder in den Approximalkontaktstellen, welche im frühen Stadium mit den klassischen Diagnostikhilfsmitteln wie Spiegel, Sonde oder Bissflügelaufnahmen objektiv und quantitativ nur schwer diagnostizierbar sind. Mit dem Paradigmenwechsel in der Kariestherapie ändern sich zudem die Anforderungen an Kariesdiagnostikmethoden. Sie müssen schnell, sicher, mit geringen Kosten und geringen Belastungen für Patienten sein. In der Praxis ist eine hohe Sensitivität und Spezifität an den Messmethoden zu fordern.

Karies soll sicher und reproduzierbar auch im Anfangsstadium erkennbar sein. Ein sicheres Kariesmonitoring, eine Unterscheidung von passiver und aktiver Karies muss möglich sein. Frühzeitige Erkennung von Karies war und ist das Ziel laserbasierter Kariesdiagnostik. Seit nahezu zwanzig Jahren werden dafür geeignete Lasersysteme für die Praxis entwickelt. Welche Relevanz haben die laserbasierten Kariesdiagnostikmethoden für die Praxis? Sind sie einfach in der Praxis integrierbar? Welchen wissenschaftlichen Hintergrund für diese Methoden gibt es? Ist die Anwendung dieser Methoden rechtlich abgesichert? Diese Fragen werden im Vortrag beantwortet. Es werden klinische Beispiele verschiedener Laserdiagnostikgeräte gezeigt und dazu die wissenschaftlichen Hintergründe aktuell dargestellt.

Innovative Wege in der Zahnmedizin: Er:YAG- und Diodenlaser im Einsatz – Anwendungsbeispiele

Dr. Dr. (UMF Bukarest) Simona Baur, Zirndorf, Germany

Der Laser hat in der Zahnheilkunde inzwischen einen hohen Stellenwert erreicht. Die Bedeutung des Dentallasers als sinnvoll genutzte Behandlungsalternative in der minimalinvasiven Zahnheilkunde wird in diesem Beitrag herausgearbeitet. In ausgewählten Falldokumentationen wird zum einen gezeigt, wie der Er:YAG-Laser (2.940 nm) in der Kavitätenpräparation (Kariesentfernung im Schmelz und Dentin) und chirurgischen Behandlungen effektiv genutzt werden kann. Zum anderen kommt der Diodenlaser (810 nm) in Beispielen der chirurgische Behandlung, Parodontalbehandlung und Bleaching zum Einsatz. Die Fallberichte umfassen verschiedene Therapiemöglichkeiten bei Patienten mit diversen Erkrankungen von Hart- und Weichgewebe im Mundbereich. Pre- und postoperative klinische Symptome, postoperative Entwicklung und das Wohlbefinden der Patienten im Zusammenhang

mit den angewandten Arbeitsmethoden werden im Detail herausgearbeitet. Besonders in der Kinderzahnheilkunde hat die lasergestützte Therapie (Kariesentfernung, Frenektomie, Freilegung etc.) signifikante Vorteile gegenüber den konventionellen Therapiemethoden. Die klinischen Ergebnisse zeigen bei der Verwendung von Er:YAG- und Diodenlaser eine optimale Effizienz der Behandlung sowohl im Hart- als auch im Weichgewebe. Gerade in Kombination mit dem richtigen klinischen Prozedere ist die Akzeptanz bei Kindern und Erwachsenen sehr hoch. Laserunterstützte Chirurgie, Parodontalbehandlung, Kariesentfernung und das Bleaching ermöglichen vor allem einen erhöhten Patientenkomfort und Reduzierung der Dauer der Operation mit verkürzter Abheilungszeit. Dadurch kann der Einsatz des Lasers klinische und wirtschaftliche Vorteile bieten

Die DIAGOcam im Praxiseinsatz

Dr. Thorsten Kleinert, Berlin, Germany

Mit dem Einsatz der DIAGNOcam erhöht der Zahnarzt die Diagnose-sicherheit bei der Erfassung kariöser Läsionen. Somit ist ein Kariesmonitoring ohne zusätzliche Strahlenexposition für den Patienten möglich. Die anschließende Versorgung der Zahnläsionen wird präventiv

oder kurativ minimalinvasiv erfolgen. Im Vergleich zum DIAGNOOpen und DIAGNOdent existiert ein bildgebendes Verfahren, das mit einer Röntgenaufnahme vergleichbar ist. Eine quantitative Aussage wird jedoch nur in Kombination beider Verfahren möglich sein.

Antwort:

Deutsche Gesellschaft für Laserzahnheilkunde e.V.
c/o Universitätsklinikum Aachen
Klinik für Zahnerhaltung
Pauwelsstraße 30
52074 Aachen

Tel.: 0241 8088164
Fax: 0241 803388164
E-Mail: sekretariat@dgl-online.de
Bank: Sparkasse Aachen
IBAN: DE56 3905 0000 0042 0339 44
BIC: AACSD33

Aufnahmeantrag

Name/Titel: _____
Vorname: _____
Geb.-Datum: _____
Approbation: _____



Status: ☐ selbstständig ☐ angestellt ☐ Beamter ☐ Student ☐ ZMF/ZA

Adresse:

Straße: _____ Telefon: _____
PLZ/Ort: _____ Fax: _____
Land: _____ E-Mail: _____

Aufgrund des bestehenden Assoziationsvertrages zwischen der DGL und der DGZMK fällt zusätzlich ein reduzierter Jahresbeitrag für die DGZMK an (85,00 € p.a., falls Sie noch nicht Mitglied der DGZMK sind). Der Beitragseinzug erfolgt durch die DGZMK-Geschäftsstelle, Liesegangstr. 17a, 40211 Düsseldorf. Sie werden hierfür angeschrieben.

Mit der Stellung dieses Aufnahmeantrages versichere ich, dass ich

- ☐ seit dem _____ in der eigenen Praxis
mit einem Laser des Typs _____ arbeite (genaue Bezeichnung).
☐ in der Praxis _____ beschäftigt bin.
☐ in der Abt. der Universität _____ beschäftigt bin.

Ich beantrage die Aufnahme in die Deutsche Gesellschaft für Laserzahnheilkunde e.V.

Ort, Datum

vollständige Unterschrift

Jahresbeitrag: Für stimmberechtigte Mitglieder bei Bankeinzug 150,00 €.

Sofern keine Einzugsermächtigung gewünscht wird, wird ein Verwaltungsbeitrag von 31,00 € p.a. fällig.

EINZUGSERMÄCHTIGUNG

Ich bin einverstanden, dass der DGL-Mitgliedsbeitrag von meinem Konto abgebucht wird.

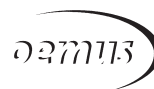
Name: _____ IBAN: _____
BIC: _____ Geldinstitut: _____

Unterschrift des Kto.-Inhabers

Diese Erklärung gilt bis auf schriftlichen Widerruf

laser

international magazine of laser dentistry



Publisher

Torsten R. Oemus
oemus@oemus-media.de

CEO

Ingolf Döbbecke
doebbecke@oemus-media.de

Members of the Board

Jürgen Isbaner
isbaner@oemus-media.de

Lutz V. Hiller

hiller@oemus-media.de

Editor in Chief

Norbert Gutknecht
ngutknecht@ukaachen.de

Coeeditors in Chief

Samir Nammour
Matthias Frentzen

Managing Editors

Georg Bach
Leon Vanweersch

Division Editors

Umberto Romeo
European Division

Melissa Marchesan
North American Division

Carlos de Paula Eduardo
South American Division

Toni Zeinoun
Middle East & Africa Division

Ambrose Chan
Asia & Pacific Division

Senior Editors

Aldo Brugneira Junior
Kenji Yoshida
Lynn Powell
Dimitris Strakas
Adam Stabholz
Marcia Martins Marques

Editorial Board

Peter Steen Hansen, Aisha Sultan,
Ahmed A Hassan, Antonis Kallis,
Dimitris Strakas, Kenneth Luk, Mukul Jain,
Reza Fekrazad, Sharonit Sahar-Helft,
Lajos Gaspar, Paolo Vescovi, Ilay Maden,
Jaana Sippus, Hideaki Suda, Ki-Suk Kim,
Miguel Martins, Aslihan Üsümez,
Liang Ling Seow, Shaymant Singh Makhan,
Enrique Trevino, Blanca de Grande,
José Correia de Campos, Carmen Todea,
Saleh Ghabban Stephen Hsu, Antoni Espana Tost,
Josep Arnabat, Alaa Sultan, Leif Berven,
Evgeniy Mironov Ahmed Abdullah, Boris Gaspirc,
Peter Fahlstedt, Ali Saad Alghamdi, Alireza Fallah,
Michel Vock, Hsin-Cheng Liu, Sajee Sattayut,
Anna-Maria Yannikou, Ryan Seto, Joyce Fong,
Iris Brader, Masoud Mojahedi, Gerd Volland,
Gabriele Schindler, Ralf Borchers, Stefan Grümer,
Joachim Schiffer, Detlef Klotz, Jörg Meister,
Rene Franzen, Andreas Braun,
Sabine Sennhenn-Kirchner, Siegfried Jänicke,
Olaf Oberhofer, Thorsten Kleinert

Editorial Office

Georg Isbaner
g.isbaner@oemus-media.de

Claudia Jahn
c.jahn@oemus-media.de

Product Manager

Timo Krause
t.krause@oemus-media.de

Executive Producer

Gernot Meyer
meyer@oemus-media.de

Designer

Sandra Ehnert
s.ehnert@oemus-media.de

Theresa Weise

t.weise@oemus-media.de

Customer Service

Marius Mezger
m.mezger@oemus-media.de

Published by

Oemus Media AG
Holbeinstraße 29, 04229 Leipzig, Germany
Tel.: +49 341 48474-0
Fax: +49 341 48474-290
kontakt@oemus-media.de
www.oemus.com

Printed by

Silber Druck oHG
Am Waldstrauch 1, 34266 Niestetal, Germany

laser international magazine of laser dentistry
is published in cooperation with the World
Federation for Laser Dentistry (WFLD).

WFLD Headquarters

University of Aachen Medical Faculty
Clinic of Conservative Dentistry
Pauwelsstr. 30, 52074 Aachen, Germany
Tel.: +49 241 808964
Fax: +49 241 803389644
ngutknecht@ukaachen.de
www.wfld-org.info

www.laser-magazine.com

Copyright Regulations

laser international magazine of laser dentistry is published by OEMUS MEDIA AG and will appear in 2016 with one issue every quarter. The magazine and all articles and illustrations therein are protected by copyright. Any utilisation without the prior consent of editor and publisher is inadmissible and liable to prosecution. This applies in particular to duplicate copies, translations, microfilms, and storage and processing in electronic systems. Reproductions, including extracts, may only be made with the permission of the publisher. Given no statement to the contrary, any submissions to the editorial department are understood to be in agreement with a full or partial publishing of said submission. The editorial department reserves the right to check all submitted articles for formal errors and factual authority, and to make amendments if necessary. No responsibility shall be taken for unsolicited books and manuscripts. Articles bearing symbols other than that of the editorial department, or which are distinguished by the name of the author, represent the opinion of the afore-mentioned, and do not have to comply with the views of OEMUS MEDIA AG. Responsibility for such articles shall be borne by the author. Responsibility for advertisements and other specially labeled items shall not be borne by the editorial department. Likewise, no responsibility shall be assumed for information published about associations, companies and commercial markets. All cases of consequential liability arising from inaccurate or faulty representation are excluded. General terms and conditions apply, legal venue is Leipzig, Germany.

SUBSCRIBE NOW!


international magazine of laser dentistry

Interdisciplinary & transparent & market orientated

ONLINE
SUBSCRIPTION HERE



www.oemus.com/abo



stay updated:

research

**Blue light laser-assisted
crown lengthening**

research

**Thermal damage behaviour
dental pulp stem cells**

case report

**Haemostasis in oral soft
tissue and extraction socket**

Fax **+49 341 48474-290**

I would like to subscribe for the following journals:

- ☐ laser – international magazine of laser dentistry 4 issues p.a. 44.– €*
- ☐ implants – international magazine of oral dentistry 4 issues p.a. 44.– €*
- ☐ Implantologie Journal (german) 10 issues p.a. 99.– €*
- ☐ Oralchirurgie Journal (german) 4 issues p.a. 44.– €*

Terms & Conditions: The subscription may be cancelled in written form without due justification within 14 days of order by contacting OEMUS MEDIA AG, Holbeistr. 29, 04229 Leipzig, Germany. Dispatching notification in good time will suffice. The subscription is automatically extended by another twelve months if it is not cancelled in written form 6 weeks prior to the end of the reference period.

*All prices include VAT and shipping (within Germany).
Conditions for international subscriptions upon request.

Last Name, First Name

Company

Street

ZIP/City/County

E-Mail

Signature

☐ PayPal

☐ Credit Card

Credit Card Number

Expiration Date

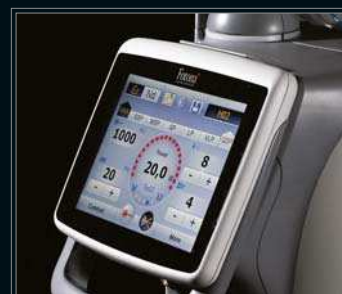
Security Code

The universe at your fingertips.

TwinLight[®] Peri-implantitis Treatment

A simple and effective laser procedure that offers the power to treat peri-implantitis – an increasing threat to oral health.

- Minimally-invasive technique
- Fast regeneration/healing
- Reduced inflammatory response
- Highly effective treatment
- No antibiotics needed



Peri-implantitis treatment video

